



JOHNS HOPKINS
M E D I C I N E

Leveraging pembrolizumab in advanced stage NSCLC - Cases

Benjamin Levy, MD FASCO

Associate Professor, Johns Hopkins School of Medicine

Clinical Director, Johns Hopkins Sidney Kimmel Cancer Center, National Capital Region

*O número do registro profissional do(a) palestrante não foi inserido por ter sido obtido no exterior

Conflito de interesses (*Conflict of interests*)

– Dr Benjamin Levy

•De acordo com a Norma 1595/2000 do Conselho Federal de Medicina e com a RDC 96/2008 da ANVISA, declaro:

•*In accordance with Norm 1595/2000 of the Federal Council of Medicine and RDC 96/2008 of ANVISA, I declare:*

- Honorários Recebidos por Aulas Médicas (*Fees Received for Medical Lectures*):
NONE
Apoio para participação de congressos (*Sponsorship for Medical Conferences*):NONE
- Participação em Advisory Board / Consultoria (*Participation in Advisory Board / Consulting*): Jansen, Daiichi Sankyo, AstraZeneca, Pfizer, Merck, Eli Lilly, Genentech, Takeda, Guardant 360, BMS, Novartis, Novocure
- Research involvement: Jansen, Daiichi Sankyo, AstraZeneca, Merck, BMS,

Clinical Case

- Age 71, Caucasian Female
- Local art store owner
- Married, no children
- Former smoker, 40 pack year smoker, quit 1 year prior to presentation.
- No significant family history

Comorbidities

Past Medical History

- Herpes Zoster
- Limited scleroderma
- Hypertension
- Hypothyroid

Surgical History

- Patellar surgery
- Tonsillectomy

Allergies/Medications

Allergies:

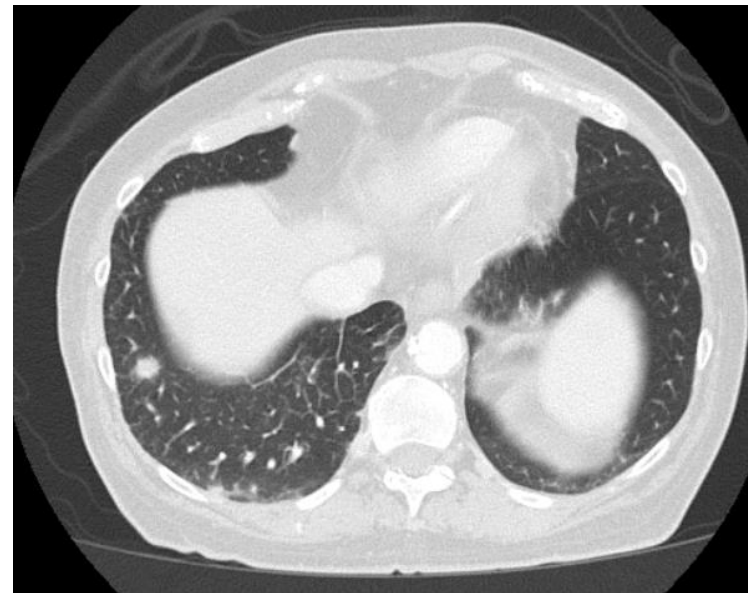
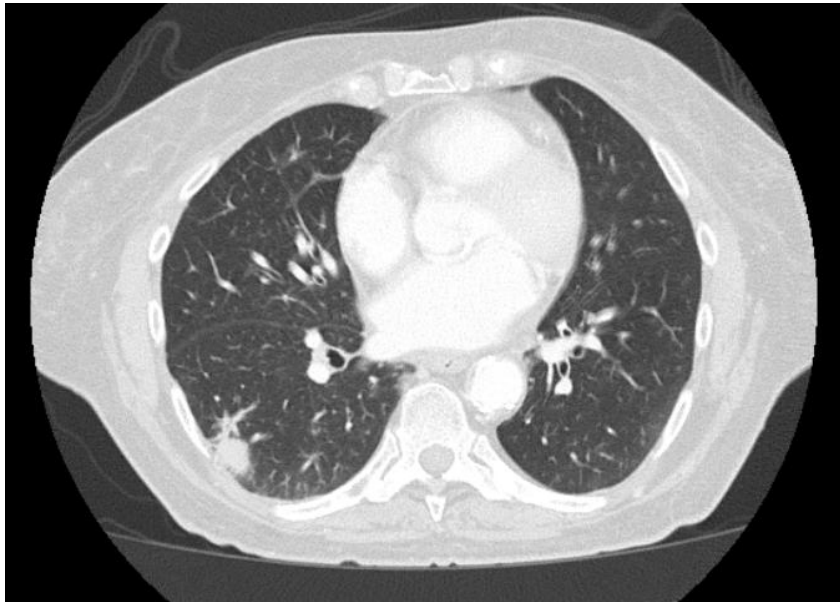
None

Medications:

Synthroid, Metoprolol

Initial Presentation

- In November 2018 began complaining of worsening cough, chest heaviness and exertional dyspnea
- Patient's PCP ordered a CXR followed by a CT scan due to abnormal findings



CT C/A/P

- Right lower lobe nodule
- Bilateral hilar adenopathy
- Multiple sclerotic lesions

Biopsy and further work up

CT guided biopsy demonstrates

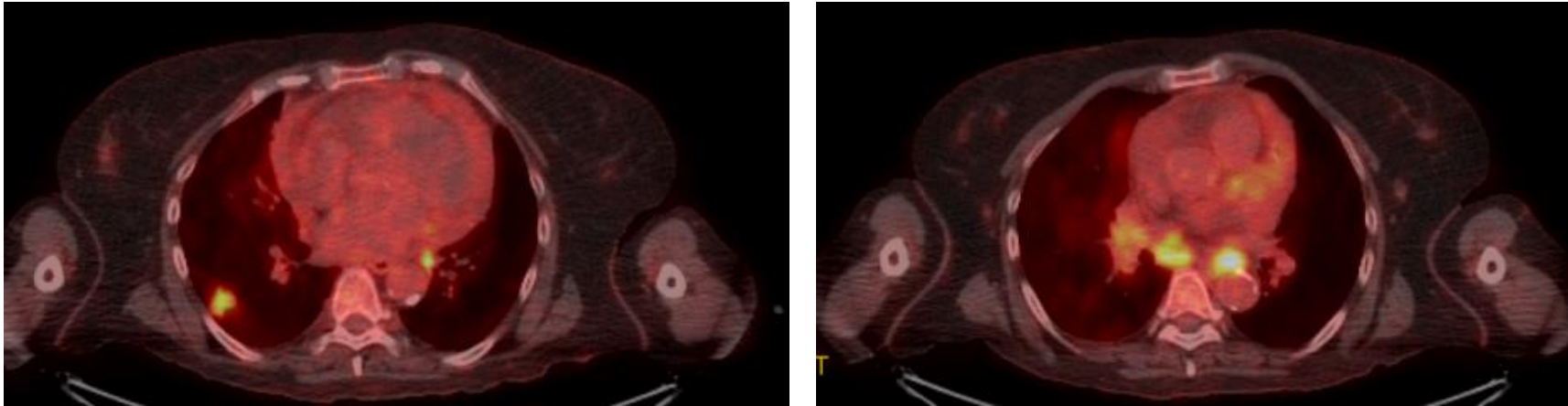
TTF + adenocarcinoma

PD-L1 < 1%,

KRAS G12c with co-altered KEAP1

MRI brain negative for intraparenchymal metastasis

PET SCAN



1. Hypermetabolic right lower lobe nodule,
2. Extensive mediastinal, bilateral hilar and bilateral supraclavicular metastatic lymphadenopathy.
3. Metastatic lymphadenopathy extends into the abdomen with involvement of pericardiophrenic, gastrohepatic, retroperitoneal lymph nodes and left inguinal,
4. Multiple sites of osseous metastatic disease

Questions?

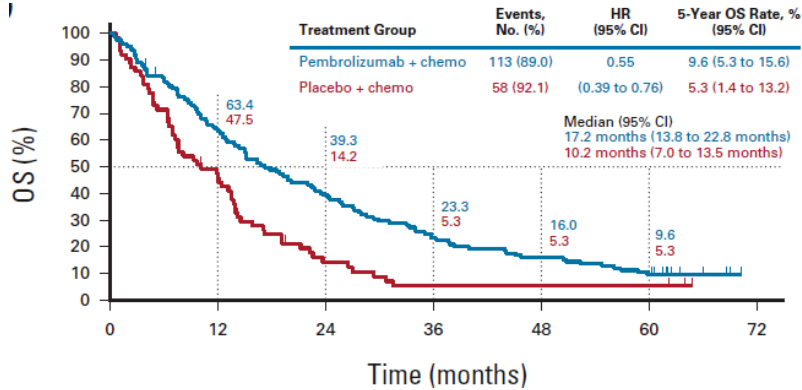
- What therapy options exist for this patient?
- Should patient's tumor with a PD-L1 < 1% be taken into consideration with selecting therapy?
- What if this patient was STK11 rather than KEAP1?
- What if this patient had brain mets? Would that impact on your decision making regarding systemic therapy?

Questions?

- What therapy options exist for this patient?
- **Should patient's tumor with a PD-L1 < 1% be taken into consideration with selecting therapy?**
- What if this patient was STK11 rather than KEAP1?
- What if this patient had brain mets? Would that impact on your decision making regarding systemic therapy?

KEYNOTE 189

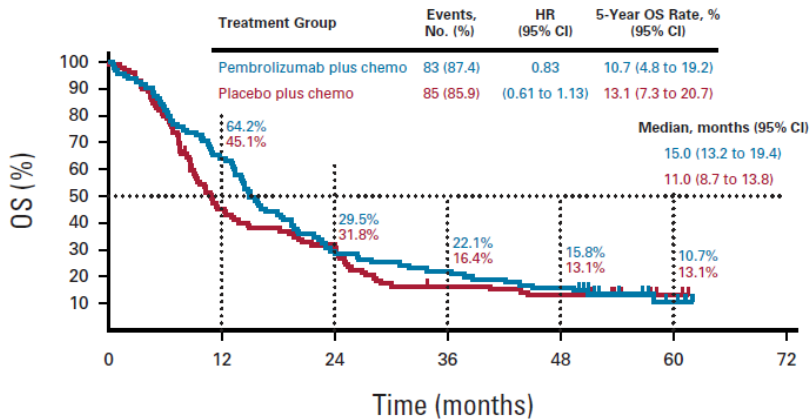
5-year outcomes PD-L1 TPS<1%



Garassino MC, et al. J Clin Oncol 41:1992-1998. 2023

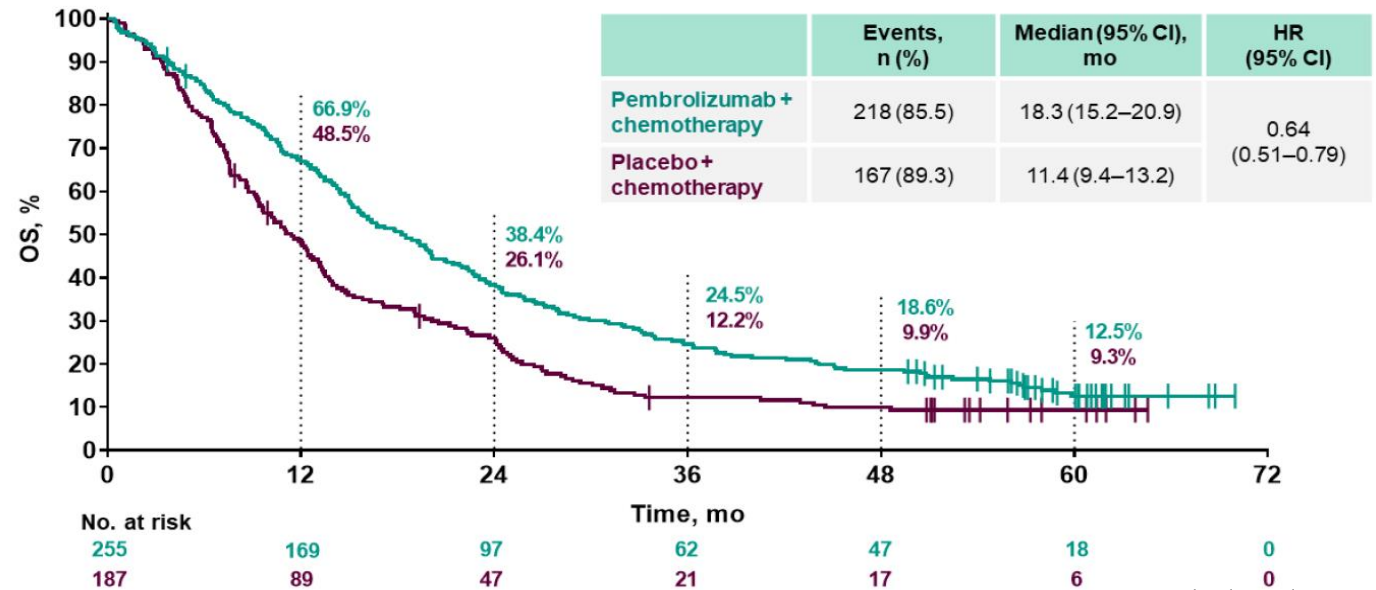
KEYNOTE 407

5-year outcomes PD-L1 TPS<1%



Novello S, et al. J Clin Oncol. 2023

Pooled Analysis KN-189 and KN-407 - 5-year outcomes PD-L1 TPS<1%



Gadgeel S, et al. WCLC 2023.

What is the most effective first-line therapy for patients with stage IV NSCLC with **non-SCC**, and **negative** or unknown **PD-L1 status** (TPS 0-49%), and PS 0-1?

Recommendation	Type	Evidence Quality	Strength
2.1. clinicians should offer pembrolizumab/carboplatin/pemetrexed	EB	H	S

What is the most effective first-line therapy for patients with stage IV NSCLC with **SCC**, and **negative** or unknown **PD-L1 status** (TPS 0-49%), and PS 0-1?

Recommendation	Type	Evidence Quality	Strength
4.1. clinicians should offer pembrolizumab/carboplatin/(paclitaxel or nab-paclitaxel).	EB	I	S

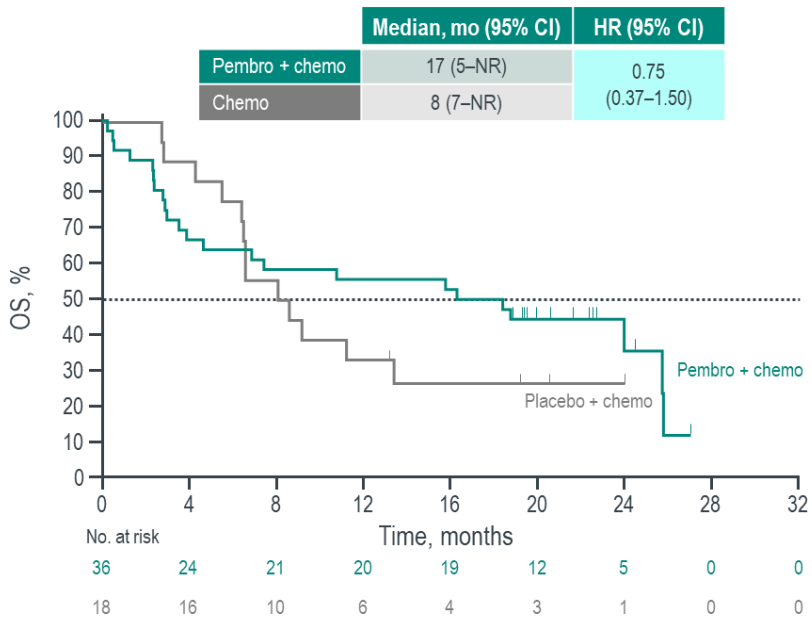
Abbreviations.
 EB, evidence based;
 H, high;
 I, Intermediate;
 S, strong;
 SCC, squamous cell carcinoma.

Questions?

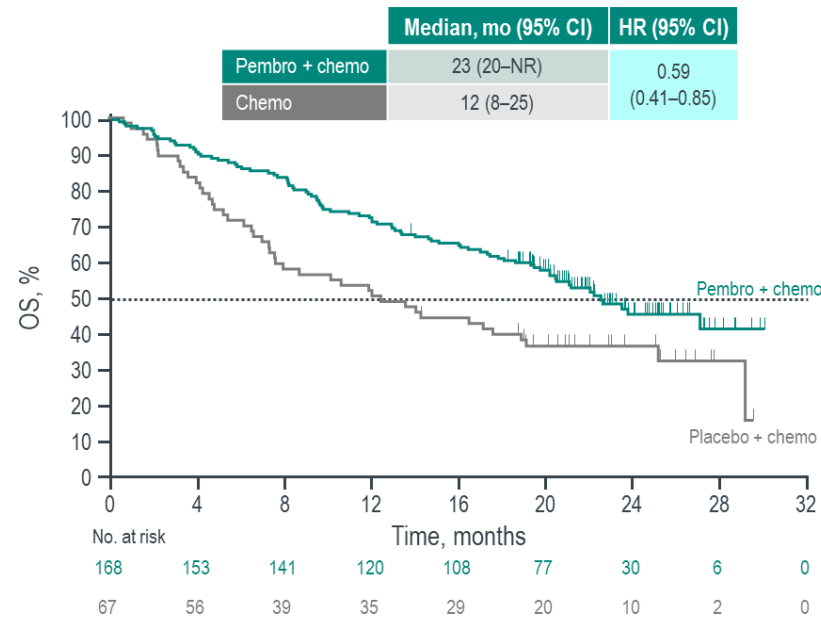
- What therapy options exist for this patient?
- Should patient's tumor with a PD-L1 < 1% be taken into consideration with selecting therapy?
- **What if this patient was STK11 rather than KEAP1?**
- What if this patient had brain mets? Would that impact on your decision making regarding systemic therapy?

KN-189: Association of STK11 Mutations With OS and ORR (Exploratory Analysis)

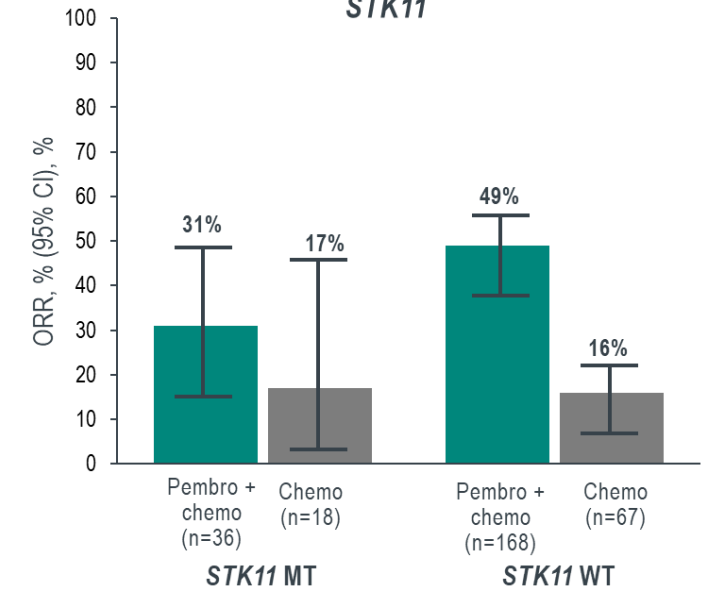
SKT11 MT



SKT11 WT

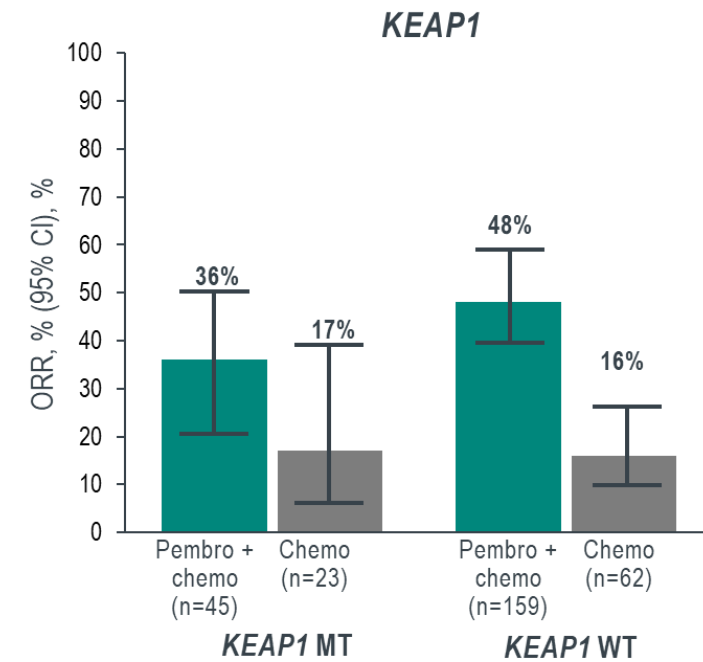
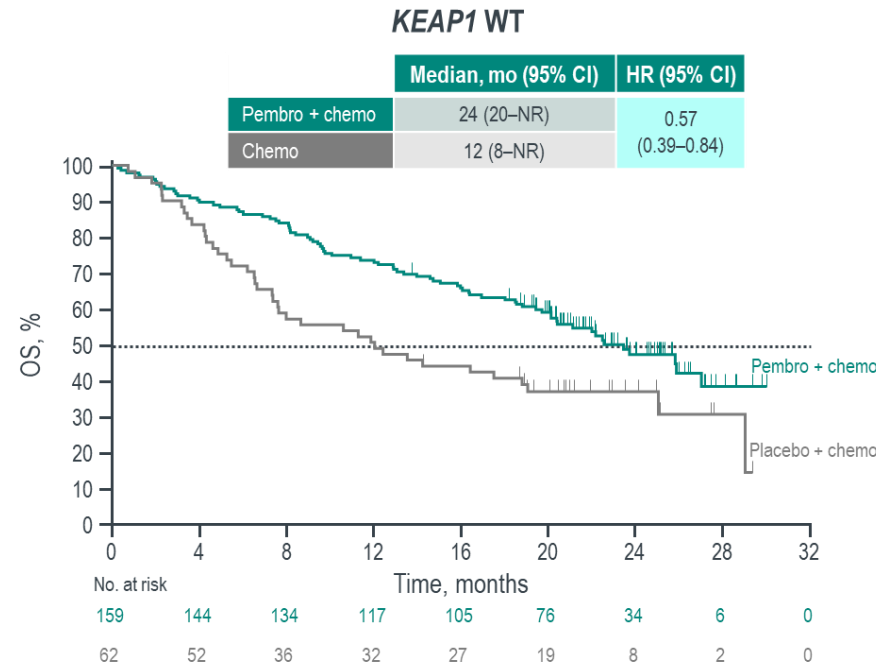
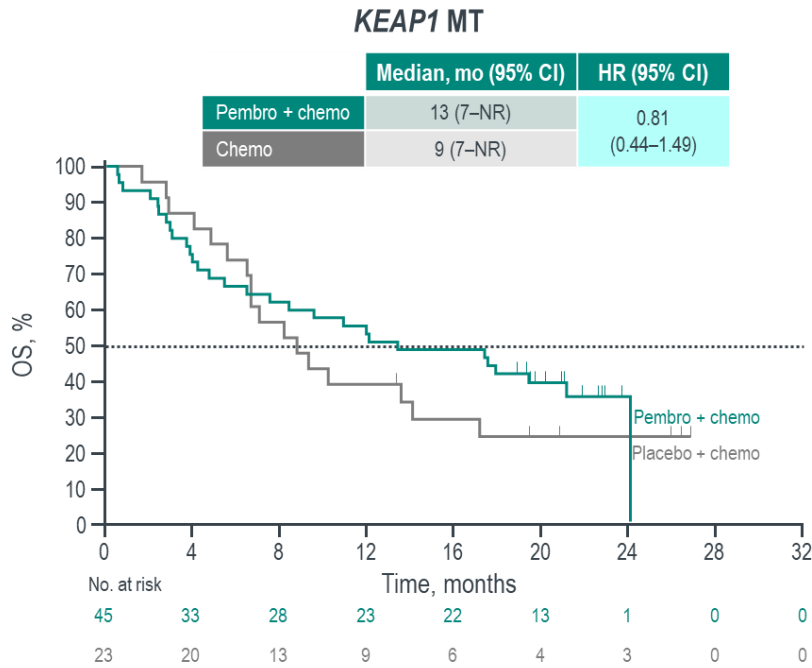


SKT11



Gadgeel, AACR 2020

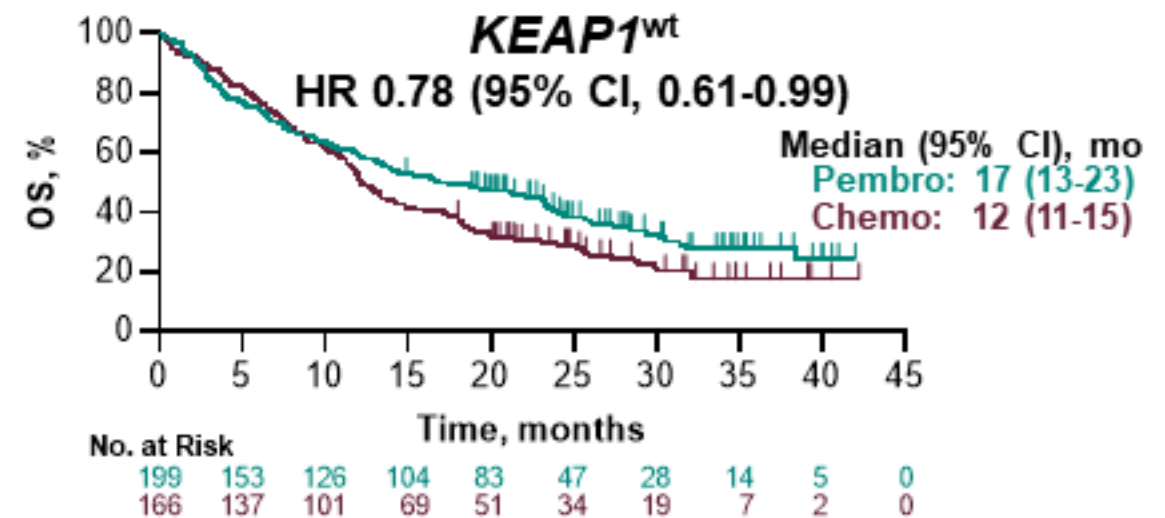
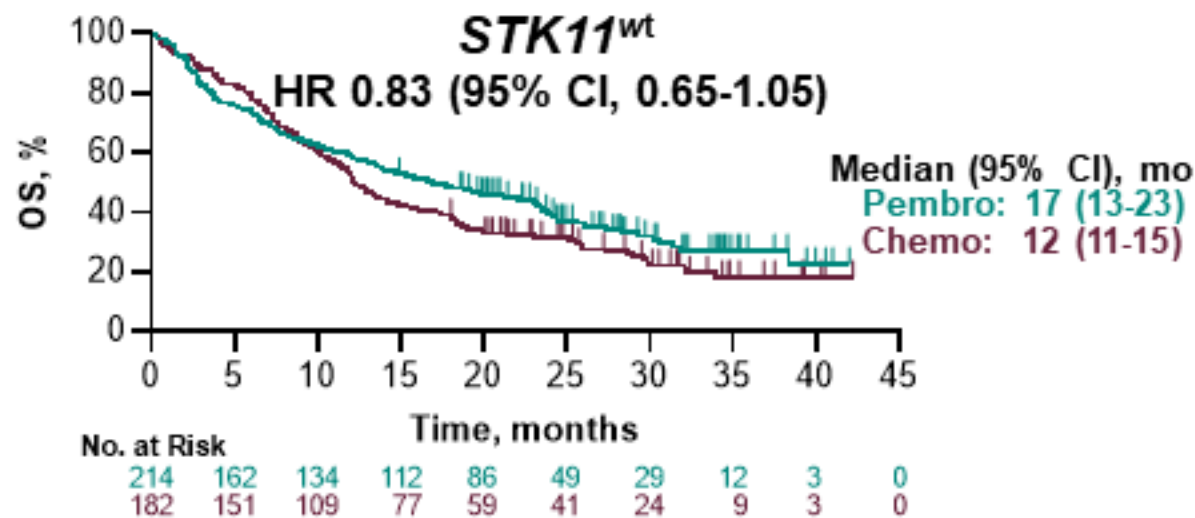
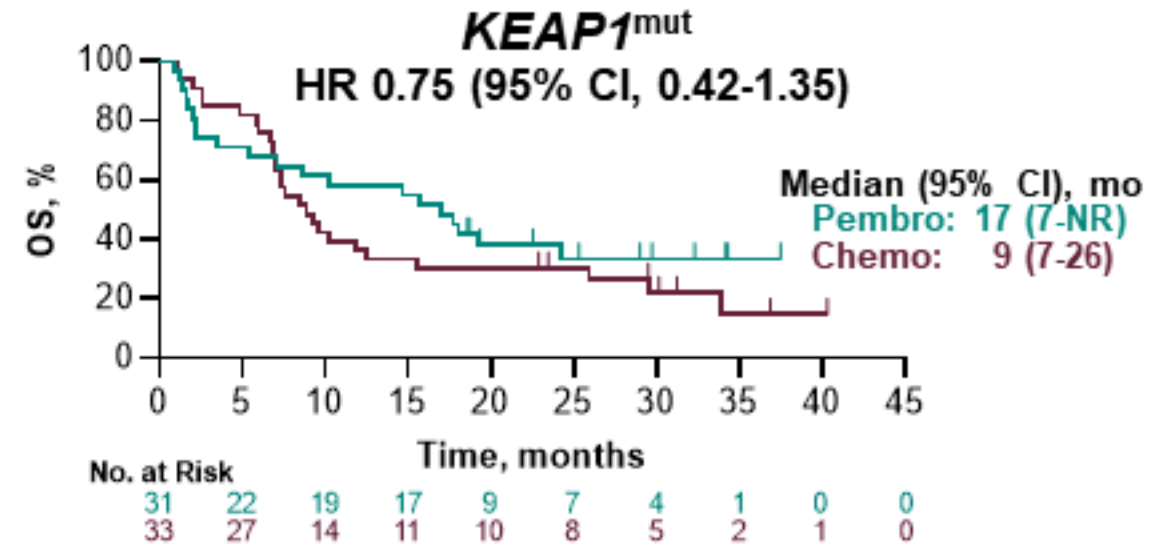
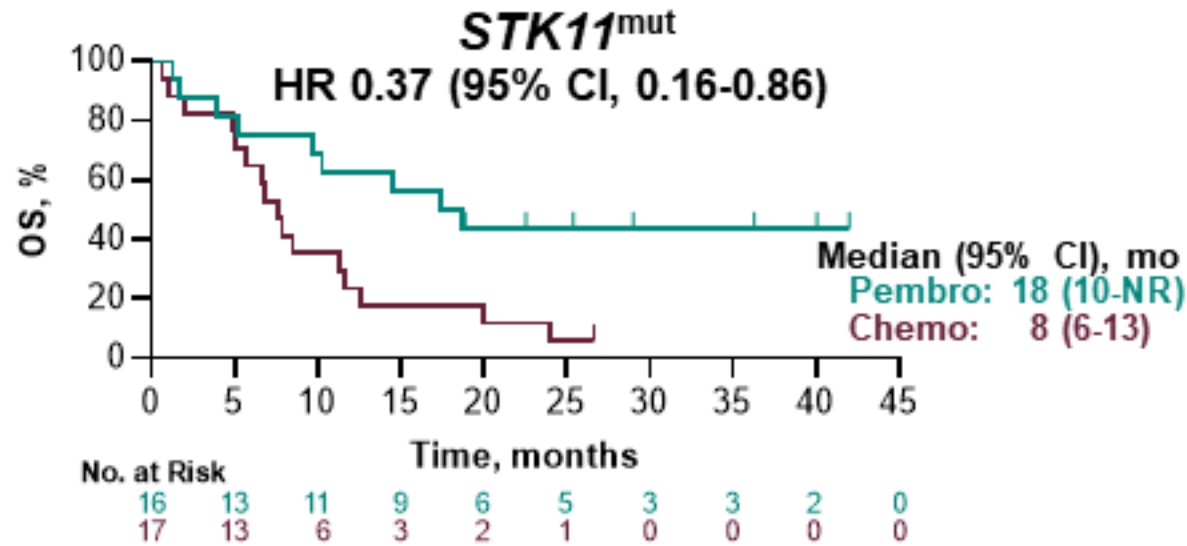
KN-189: Association of *KEAP1* Mutations With OS and ORR (Exploratory Analysis)



Gadgeel, AACR 2020

Association of *STK11* and *KEAP1* Status With OS

KEYNOTE 042 analysis



All participants had PD-L1-positive tumors (TPS ≥1%).
 Data cutoff date: Sep 4, 2018.

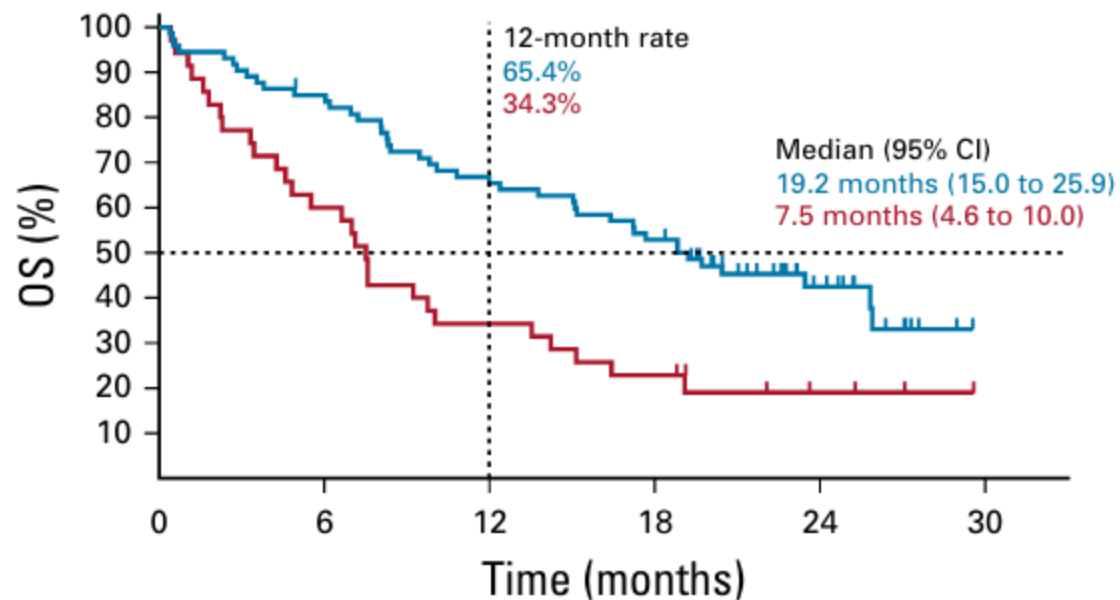
Questions?

- What therapy options exist for this patient?
- Should patient's tumor with a PD-L1 < 1% be taken into consideration with selecting therapy?
- What if this patient was STK11 rather than KEAP1?
- **What if this patient had brain mets? Would that impact on your decision making regarding systemic therapy?**

KN-189: OS by Brain Metastasis Status

With Brain Metastases

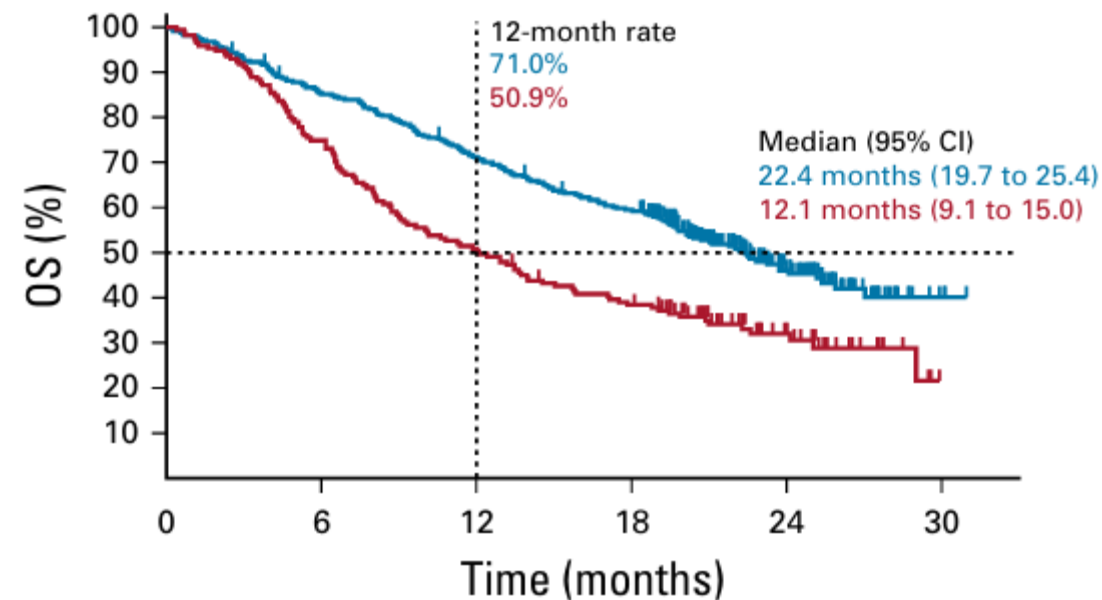
	Events, n/N (%)	HR (95% CI)
Pembrolizumab combination	42/73 (57.5)	0.41
Placebo combination	28/35 (80.0)	(0.24 to 0.67)



No. at risk:	0	6	12	18	24	30
Pembro	73	61	47	38	14	0
Placebo	35	21	12	8	3	0

Without Brain Metastases

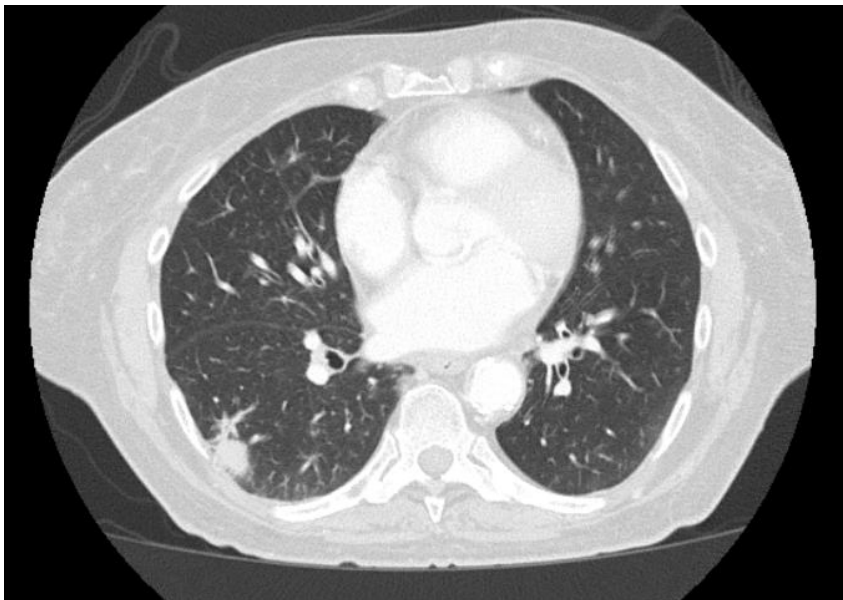
	Events, n/N (%)	HR (95% CI)
Pembrolizumab combination	171/337 (50.7)	0.59
Placebo combination	116/171 (67.8)	(0.46 to 0.75)



No. at risk:	0	6	12	18	24	30
Pembro	337	285	236	196	65	2
Placebo	171	128	87	64	23	0

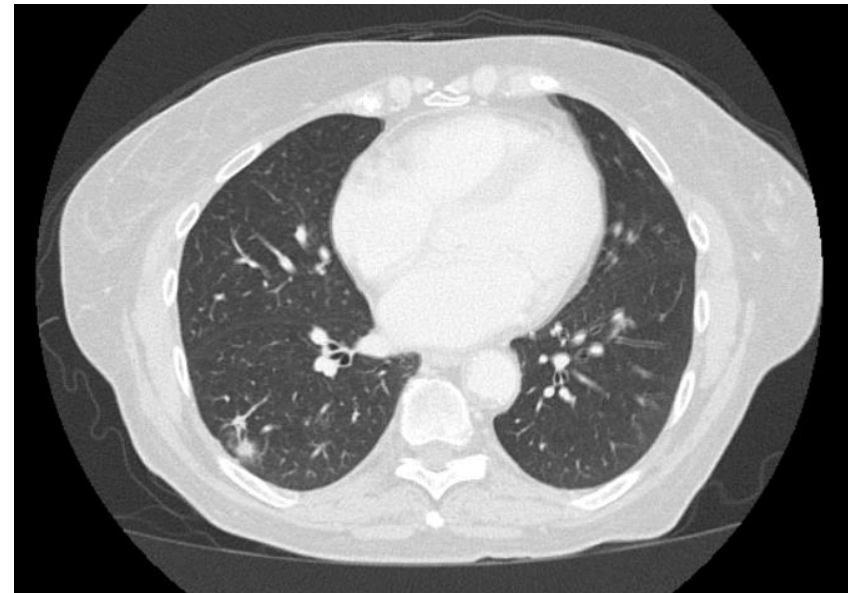
Hospital course and discharge

- Decision was made to give chemotherapy with Carboplatin AUC 5, Pemetrexed 500mg/m², Pembrolizumab 200mg every three weeks
- With denosumab 120mg IM every every six weeks
- After four cycles of therapy, repeat CT C/A/P shows marked response to therapy in both primary mass and lymph nodes



November 2018

4 cycles
Carbo/Pem/Pem



January 2019

Treatment continuum

- Patient is continued on maintenance pemetrexed 500mg/m² and pembrolizumab 200mg IV every three weeks for another 2 years
- Patient makes the decision to stop therapy and has remained with stable disease since that decision

Case 2

- Age 82, Caucasian Female
- Married, 5 children
- Former smoker, 20 pack year smoker, quit 40 year prior to presentation.
- Family hx of both lung cancer and breast cancer

Comorbidities

Past Medical History

- Hypertension
- IBS
- Hyperlipidemia

Surgical History

- None

Allergies/Medications

Allergies:

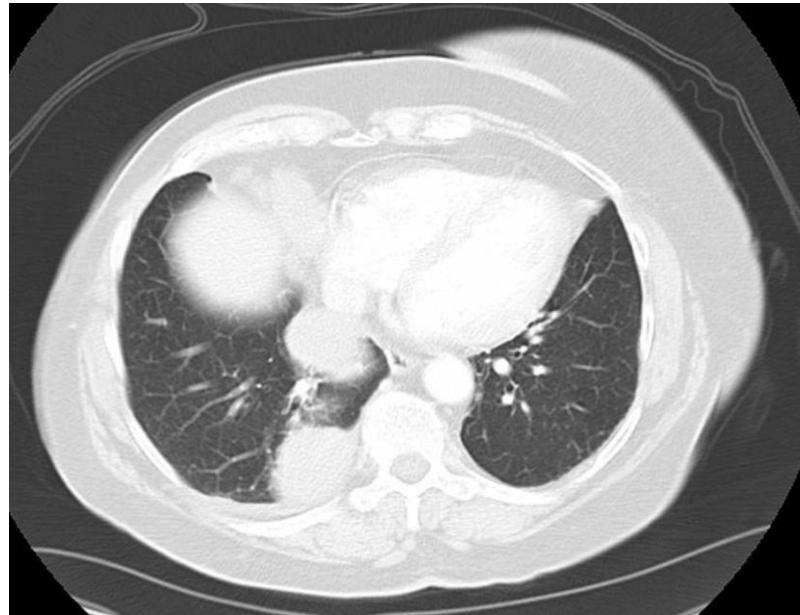
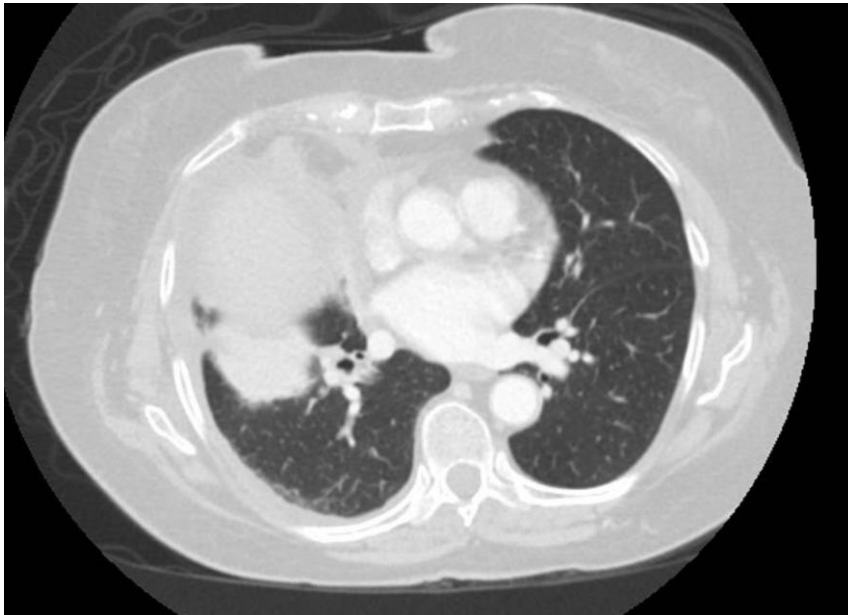
None

Medications:

Lipitor, Aspirin, Cardizem, Losartan

Initial Presentation

- In December 2021 began progressive shortness of breath on her morning walks
- Patient's PCP ordered a CXR followed by a CT scan due to abnormal findings



- 9.7 cm mass in the right upper lobe invading the pleural and chest wall
- 5.4 cm mass in the right lower lobe abutting the pleura

Biopsy and further work up

CT guided biopsy demonstrates

Necrotizing squamous cell carcinoma

PD-L1 5%,

NGS: p53, PTEN

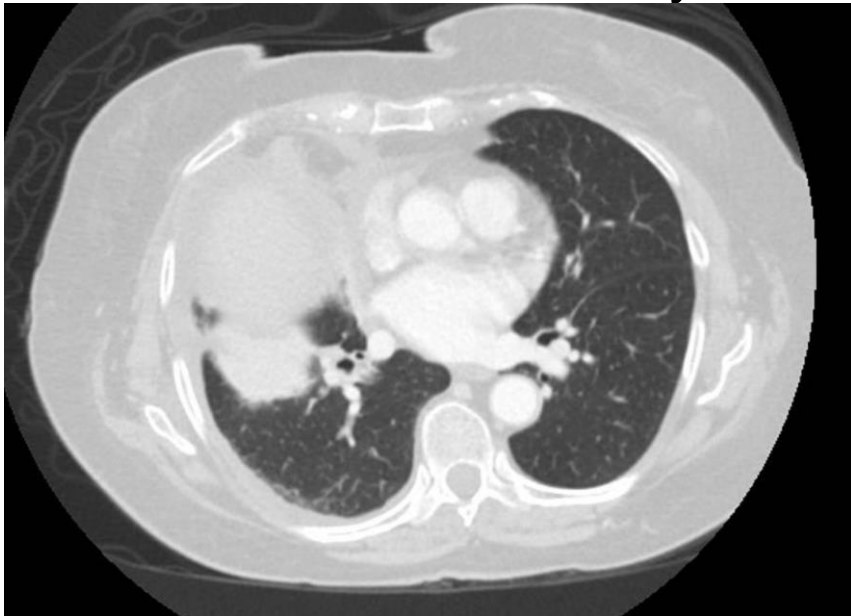
MRI demonstrates a small 3mm focus in the right temporal lobe and 2 mm focus in the left frontal lobe

Case continued

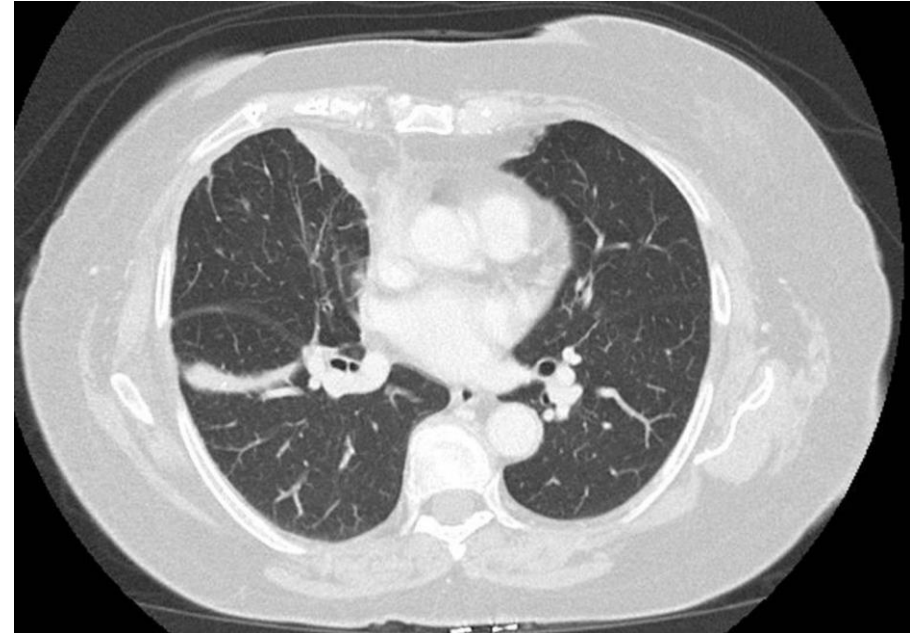
- Patient is referred to radiation oncology and the decision is to monitor brain closely given small size and patient's desire not to have radiation to the brain

Clinical Course

- Decision was made to give chemotherapy with Carboplatin AUC 5, Paclitaxel 200mg/m², Pembrolizumab 200mg every three weeks
- After four cycles of therapy, repeat CT C/A/P demonstrates complete response.
- Patient feel remarkably better and shortness of breath resolves



4 cycles
Carbo/Pac/Pem



Treatment continuum

- Repeat brain MRI after four cycles demonstrates resolution of sub-centimeter lesions
- Patient is on pembrolizumab 200mg IV every three weeks and had remained on drug for the past three years
- MRI continues to demonstrate NED

Case 3

- 72-year-old male
- Former remote smoker
- Retired construction worker
- No significant family history

Case 3

Past Medical History

- Hypertension
- Hyperlipidemia
- Diabetes
- Glomerulonephritis

Medications

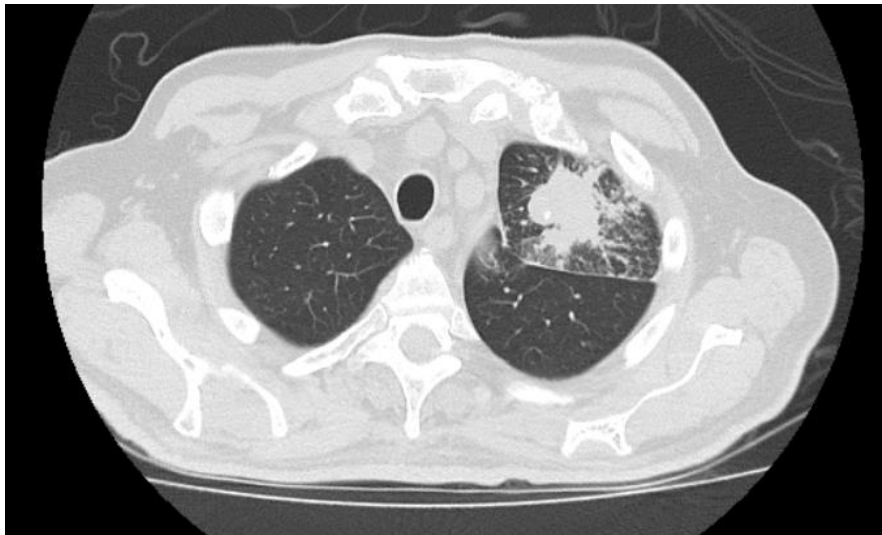
- Simvastatin, Olmesartan, Janumet, Amlodipine

Clinical Presentation

- Initial presentation in July 2023
 - Increased shortness of breath
 - Slight cough
 - 30 lb weight loss over 6 months
- Treated with several rounds of antibiotics by PCP for presumed bronchitis
- No improvement so eventually presented to the ED

In the Emergency Room

CT imaging



- Left apical mass extending to the pleural and fissure with lymphangitic carcinomatosis
- Left hilar adenopathy
- Multiple lucent bone lesions
- Small liver lesions too small to characterize

Labs

🚨 Comprehensive metabolic panel	
Status: Final result Visible to patient: Yes (My)	
Component	4mo ago (8/8/20)
⊗ Sodium	125 ↓
135 - 143 mmol/L	
⊗ Potassium	6.1 ↑
3.6 - 5.0 mmol/L	
⊗ Chloride	87 ↓
98 - 107 mmol/L	
⊗ Carbon Dioxide	30 ↑
23 - 27 mmol/L	
⊗ Urea Nitrogen	26 ↑
7 - 20 mg/dL	
⊗ Creatinine	0.76
0.50 - 1.60 mg/dL	
⊗ Glucose	63 ↓
71 - 99 mg/dL	
⊗ Calcium	12.4 ↑
8.4 - 10.2 mg/dL	
Comment: Checked, called, Results Taffy Tessema at 14:16 08/08/2	
⊗ Total Protein	6.1
5.9 - 8.1 g/dL	
⊗ Albumin	3.2 ↓
3.5 - 5.0 g/dL	

9/21/2024

BR-KEY-04478

BR-LAM-00438

Clinical Course

- Admitted for management of presumed lung cancer and electrolyte imbalance
- MRI of brain without evidence of disease
- Hyponatremia
 - Consistent with hypovolemia, dehydration, not SIADH
 - Given fluid challenges and improved
- Hypercalcemia
 - PTrP normal
 - Secondary to bony mets
 - Given pamidronate

Clinical course (con't)

- Patient has CT guided biopsy with sufficient tissue which is sent for NGS and PD-L1
- Liquid biopsy sent out
- Still weak, but discharged for future management
- PET scan done as an outpatient confirms left upper lobe mass, diffuse axial and appendicular skeleton
- Comes to clinic one week later for follow up to discuss PD-L1 and liquid biopsy

Tissue Biopsy

Liquid Biopsy

Diagnosis

1. Left lung biopsy #1:
Adenosquamous carcinoma
2. Left lung biopsy #2:
Adenosquamous carcinoma
3. Left lung biopsy #3:
Adenosquamous carcinoma
4. Left lung biopsy #4:
Adenosquamous carcinoma

Note: There are two population of malignant cells. On block 4A, most malignant cells are positive for P63, P40 and CK7, and small focus of malignant cells are positive for TTF-1 and Napsin-A. And all negative for CK20. On block 2A, part of malignant cells are positive for P40 and other are positive for TTF-1. The findings support the diagnosis. PDL-1 and solid tumor panel to follow.

Note: This case was reviewed at the Daily Intradepartmental QA Conference.

Addendum

Addendum

PD-L1 Immunohistochemical Analysis

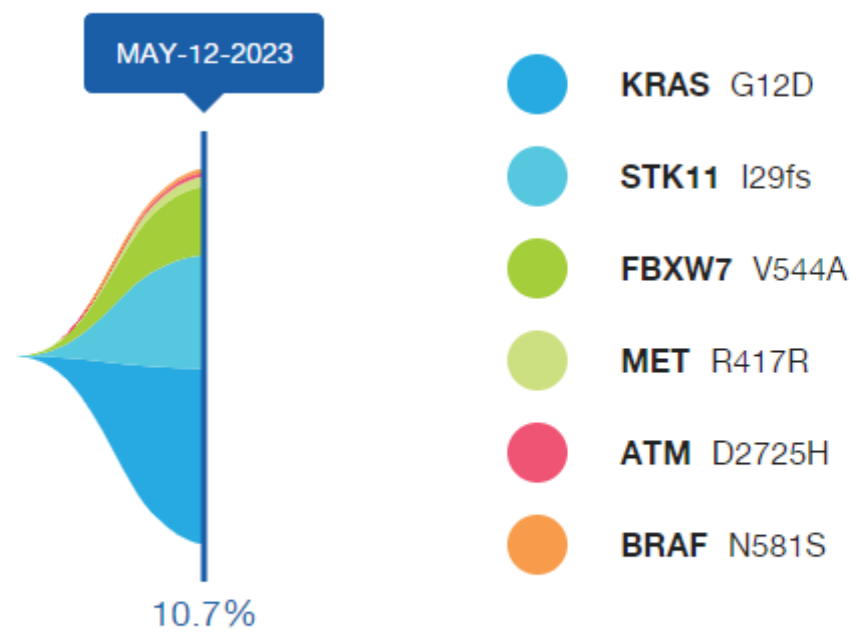
Quantitative Assessments:

Part/Block	2A
Site	LEFT LUNG
Antibody	22C3
TPS	60-70

Tumor Positive Score (TPS) - conventional assessment of the percentage of tumor cells that are positive for PD-L1 staining, and is evaluated from at least 100 tumor cells.

Interpretation for Lung Adenocarcinomas:

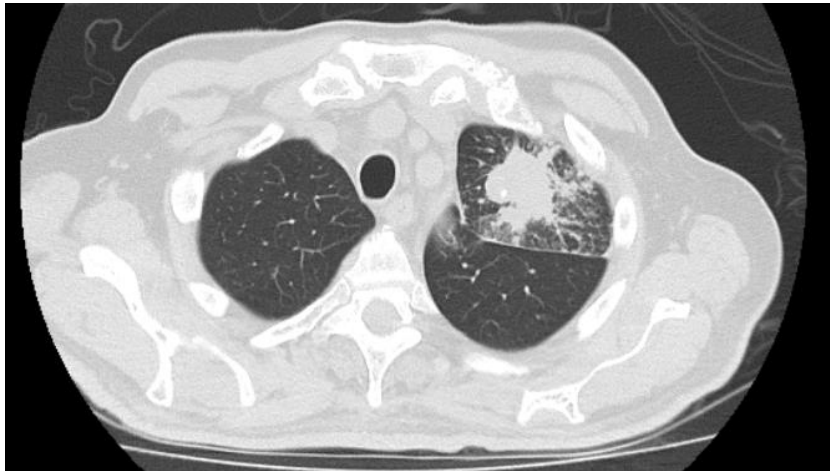BR-KEY-04478



Amplifications not graphed.

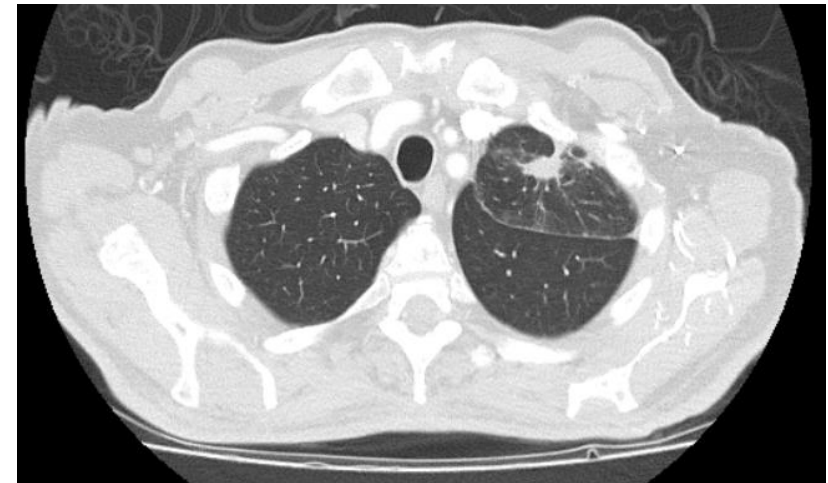Case Continued

- Patient starts on pembrolizumab 200mg
- Improved cough and shortness of breath in two weeks



July 2022

3/21/2024



October 2022

BR-KEY-04478

BR-LAM-00438

Case Continued

- Patient continues on pembrolizumab
- Most recent CT scan in Feb 2024 demonstrates stable disease

Esta apresentação é para uso exclusivo em aulas médicas e não deve ser distribuída como material promocional.
BR-KEY-04478 PRODUZIDO EM MARÇO/2024 VÁLIDO POR 2 ANOS