

European Course on
Pediatric Neuroradiology in
Latin America (ECPNR-LATAM)

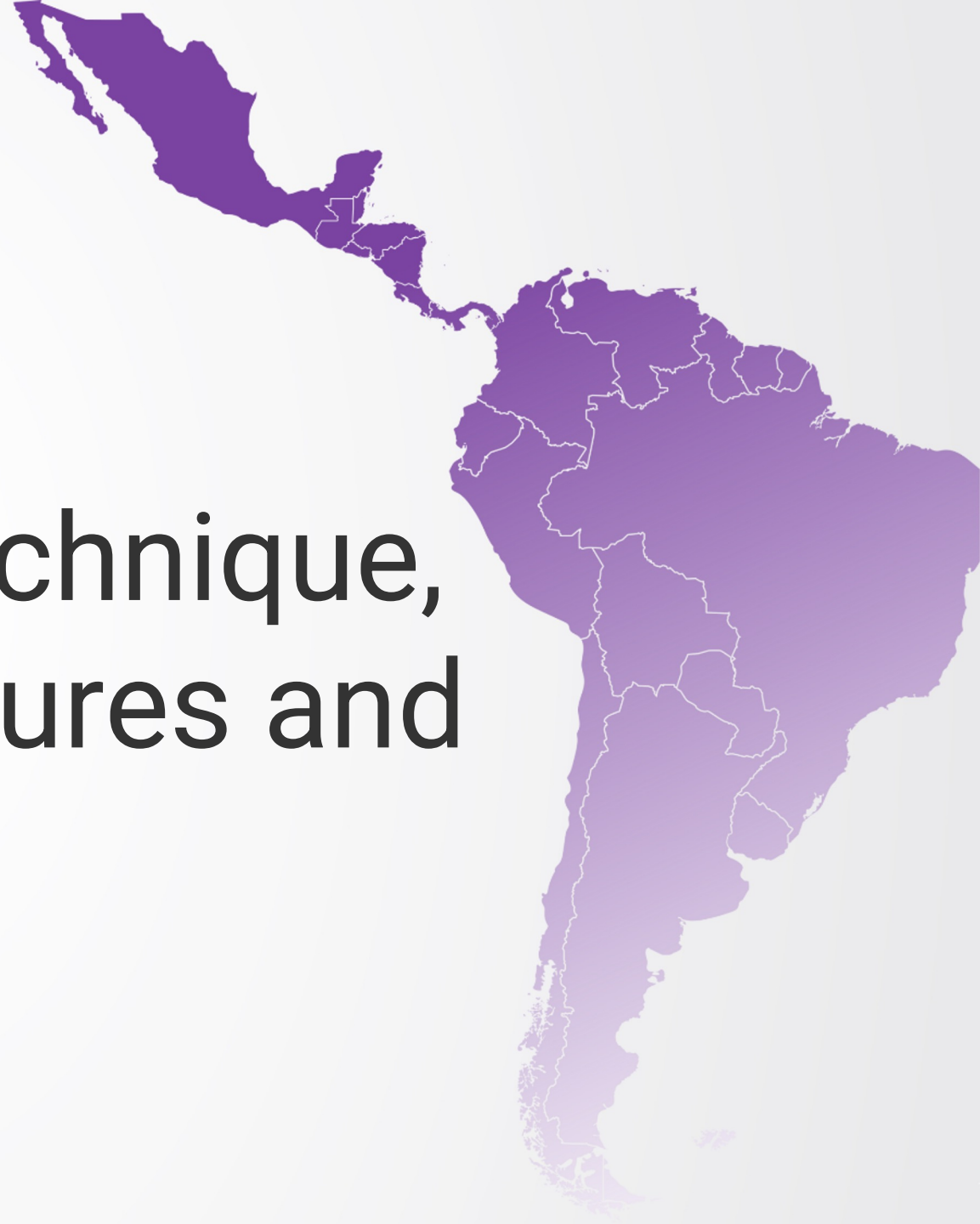3rd Cycle - Module 1

Fetal Neuro-MRI: Technique, Developmental Features and Pitfalls

Idealização:



Organização:



European Course on
Pediatric Neuroradiology in
Latin America (ECPNR-LATAM)
3rd Cycle - Module 1

Dr Kelly Pegoretti
Baruteau

Consultant Neuroradiologist

- National Hospital for Neurology and Neurosurgery
- University College London Hospital

Lead neuroradiologist for the
Fetal and Neonatal MRI service at
University College London
Hospital

Honorary Associate Professor at
the UCL Institute of Woman's
Health in London.

Idealização:



Organização:



Fetal Neuro-MRI: Technique, Developmental Features, and Pitfalls

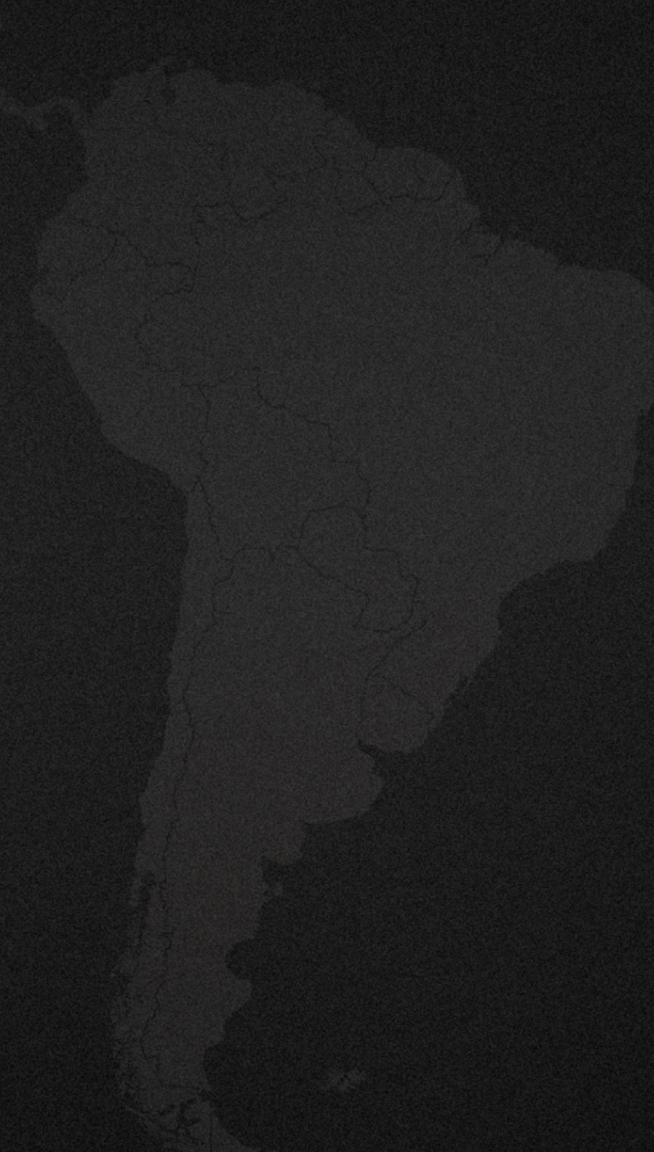European Course on
Pediatric Neuroradiology in
Latin America (ECPNR-LATAM)
3rd Cycle - Module 1

There is no conflict of interest in this presentation

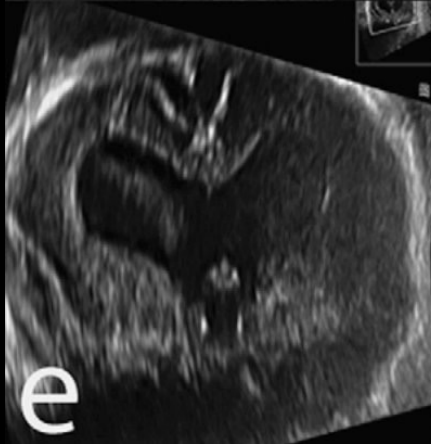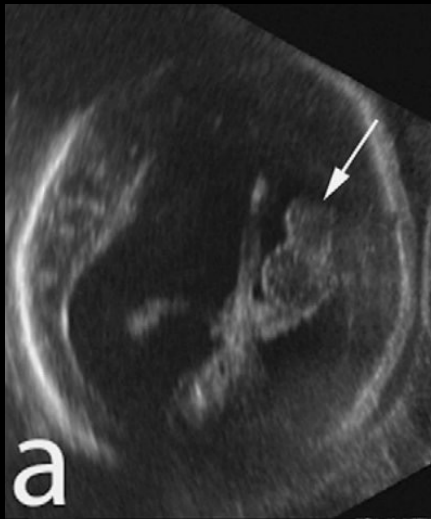
Fetal Neuro-MRI: Technique, Developmental Features, and Pitfalls

European Course on
Pediatric Neuroradiology in
Latin America (ECPNR-LATAM)
3rd Cycle - Module 1

- Safety
- Technique / Protocol
- Essentials for optimal interpretation
- Clinical Indications

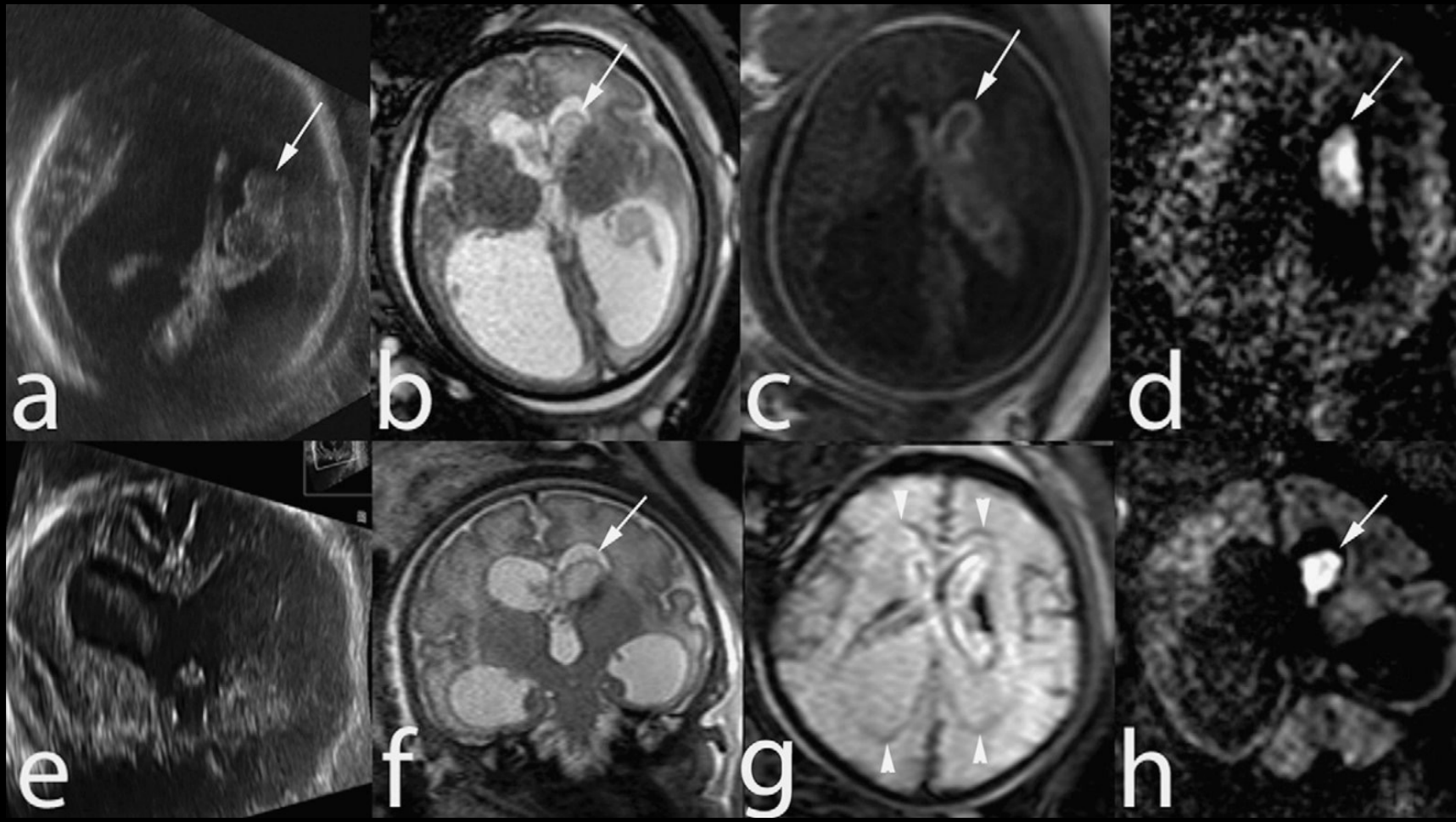


Antenatal Imaging - *Ultrasound*



- primary screening modality for obstetric and fetal imaging
- *Advantages: low cost, easy access, quicker*
- *Disadvantages: reduced FOV, lower spatial resolution, poor soft tissue contrast, operator dependent*

Antenatal Imaging - MRI



Safety

Operate

Within radiological safety guidelines:

- Screen for metal
- SAR to minimise heating effects
- Minimise noise

Avoid

First trimester:

- Technically challenging rather than safety

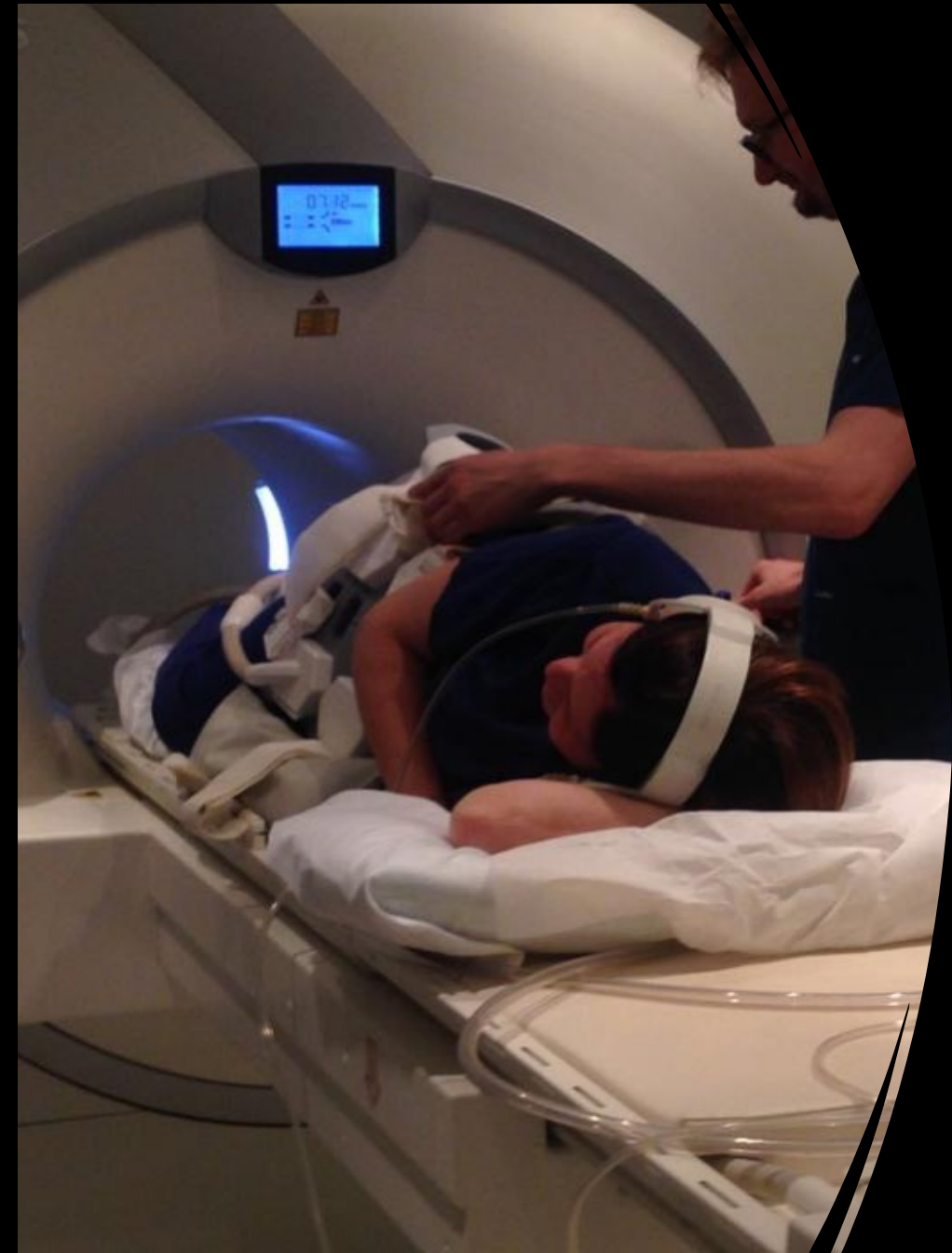Contrast

Contrast injection

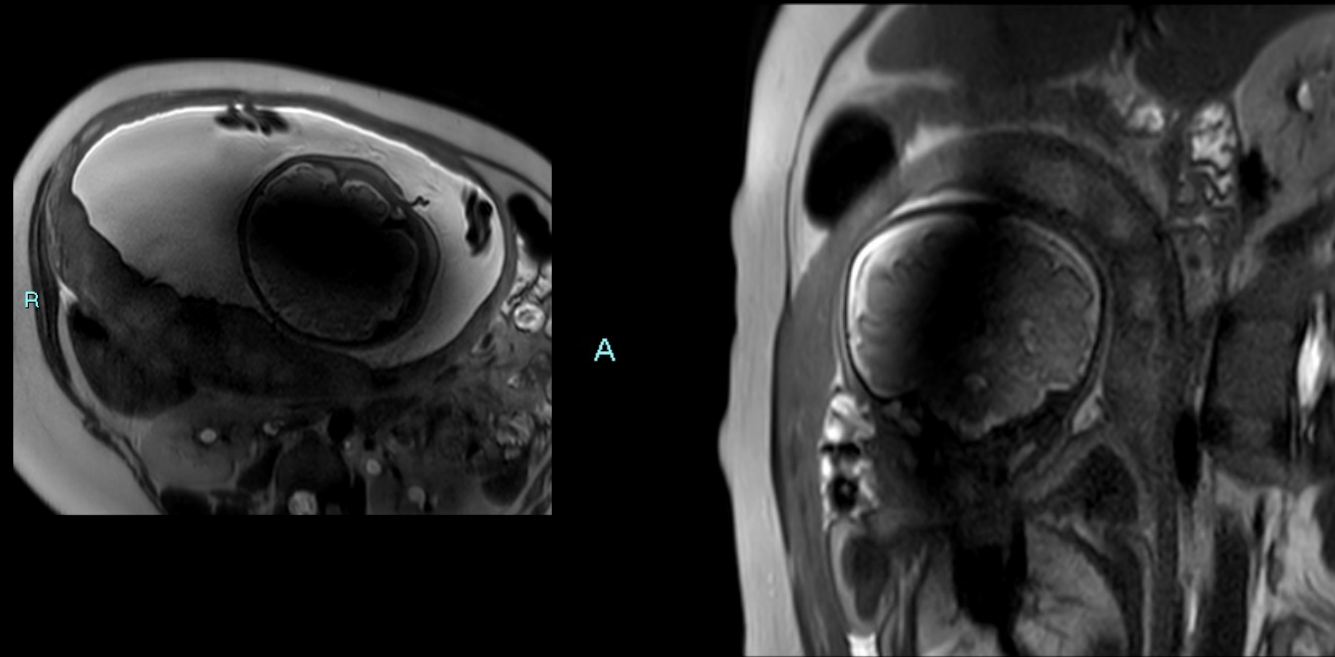
- Unnecessary
- No reported detrimental effects to the fetus

Technique:

- 1.5 or 3 T scanner
- Normal body or cardiac coils
- Multichannel coils
- Mother in left lateral or supine with pillows
- Usually 30 min - 1h
- No sedation – communication is the best sedation



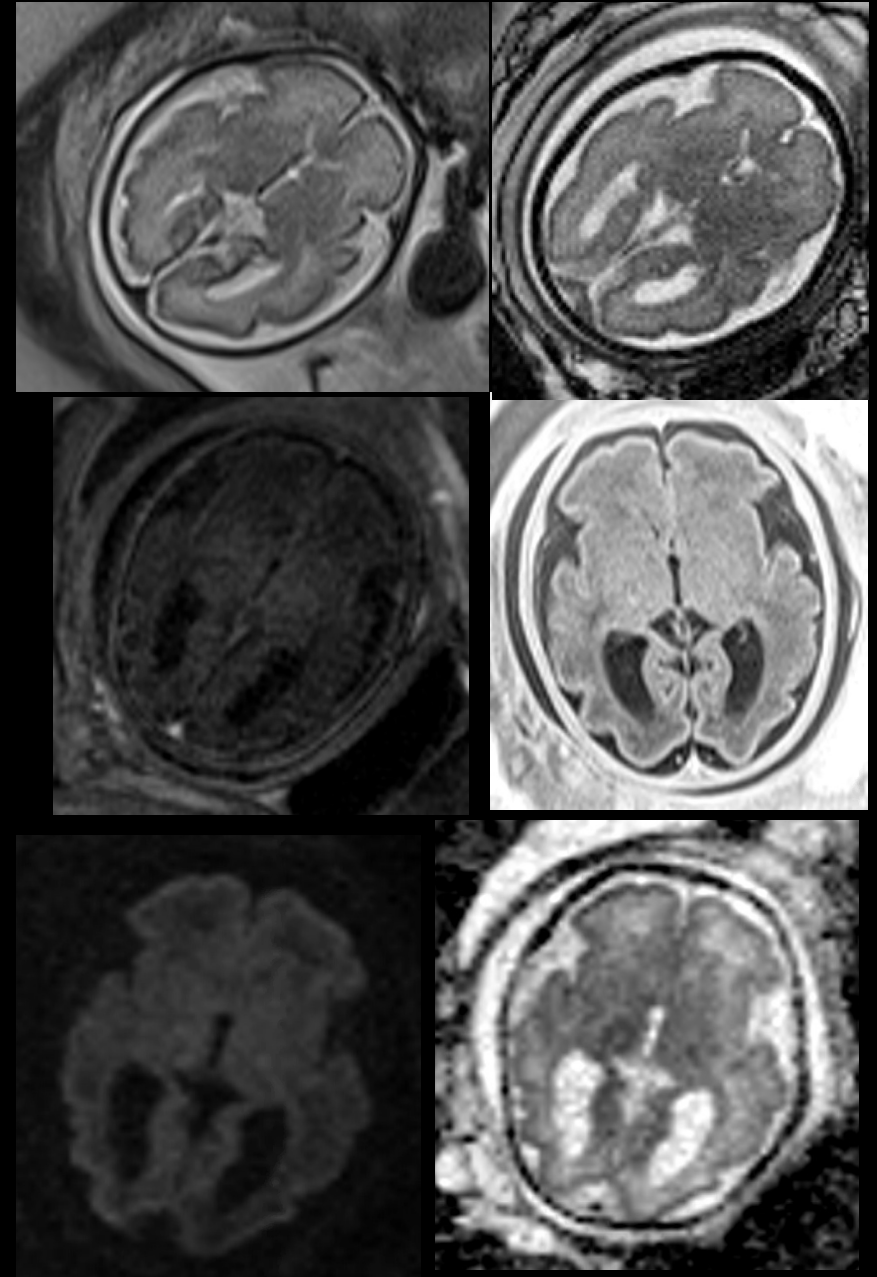
Polyhydramnios 3T less indicated



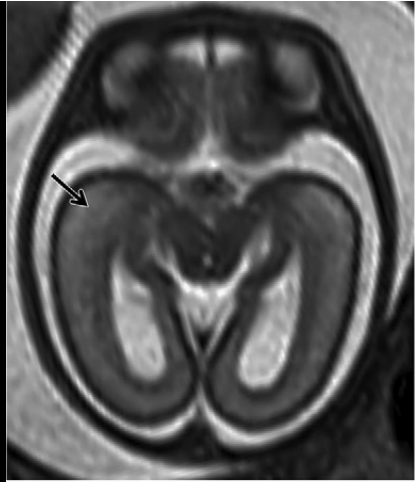Courtesy of Prof Chen Hoffman, Sheba Medical Center Tel-Hashomer, Israel

Sequences

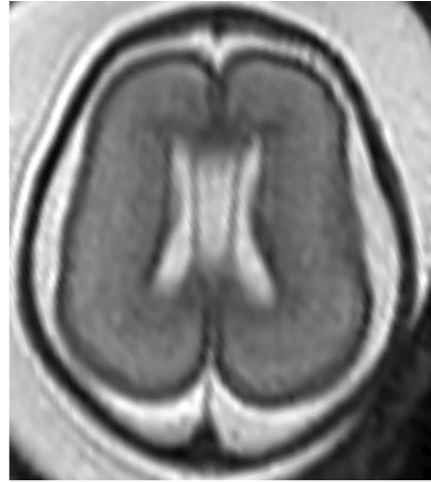
- T2 weighted HASTE
Half-fourier acquired single shot turbo spin echo
- T1 weighted (single shot or SNAPIR)
- T2 GRE
- T2 TRUFI
- DWI
- EPI FLAIR*



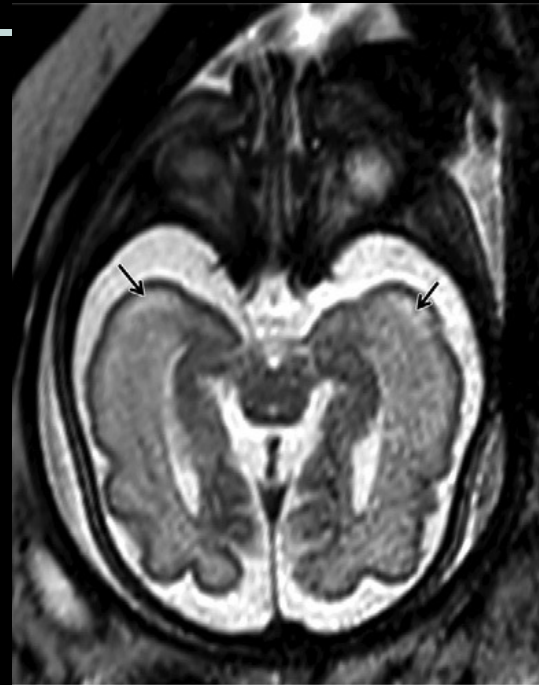
Echo-planar FLAIR Sequence Improves Subplate Visualization in Fetal MRI of the Brain



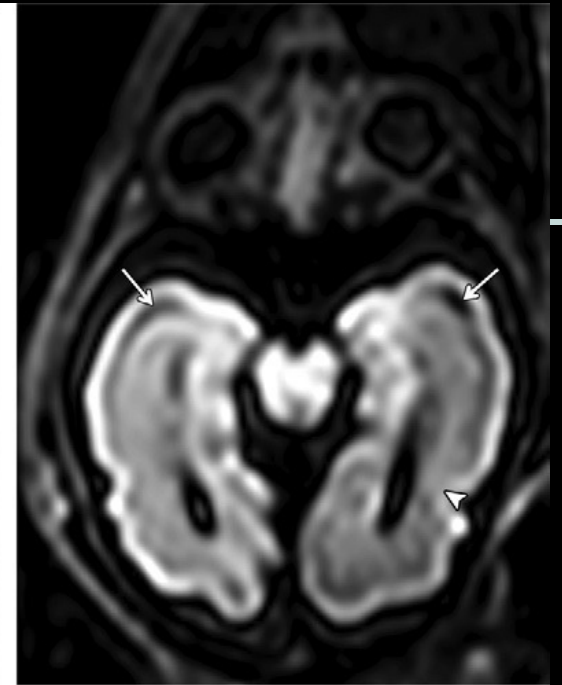
a.



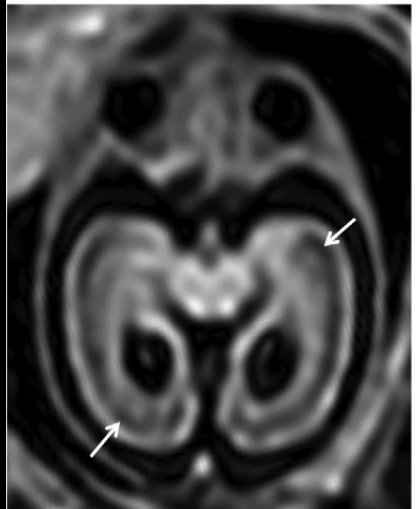
b.



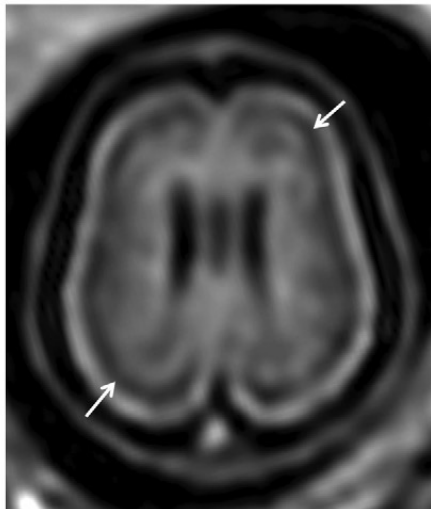
a.



b.

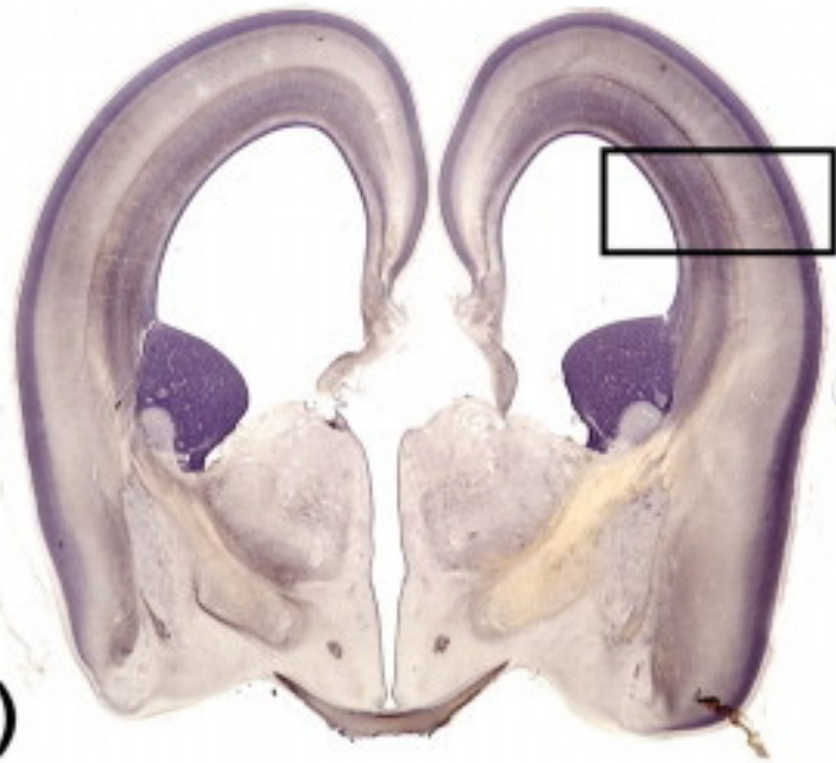


c.

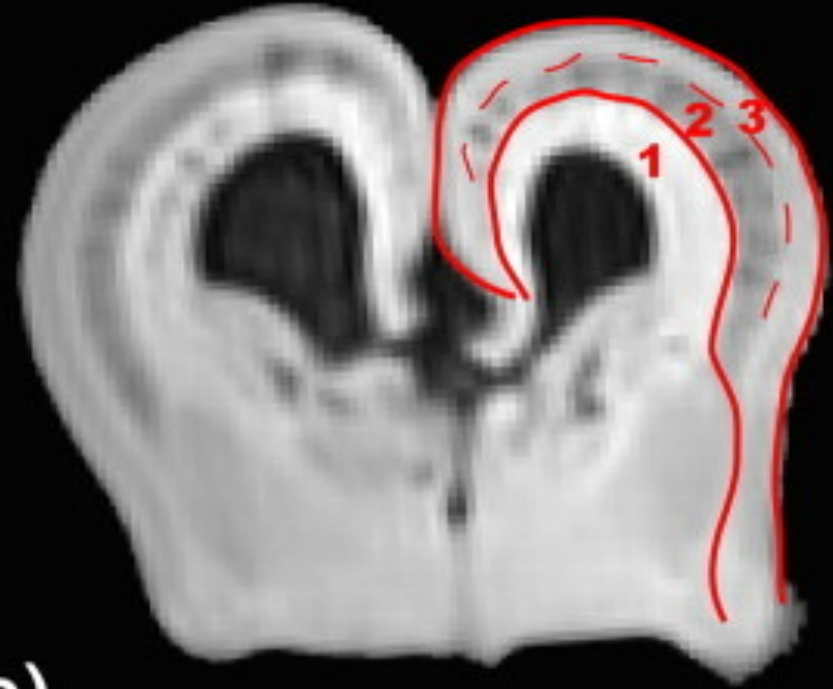


d.


(a)



(b)



(c)



1 = ventricular, periventricular, subventricular and intermediate zones

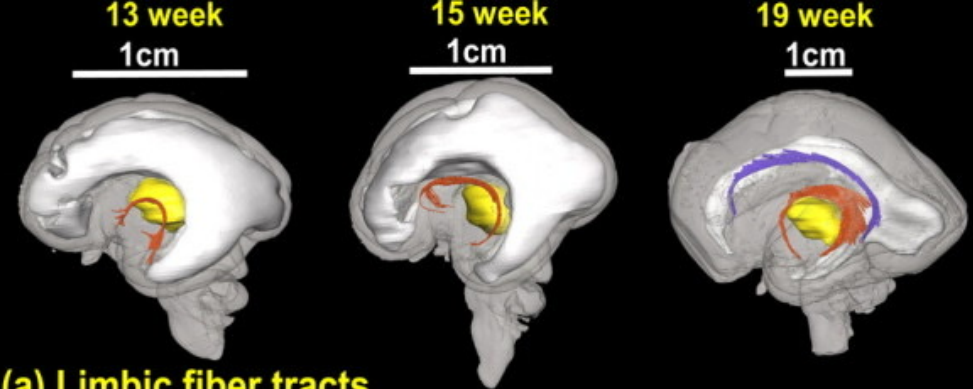
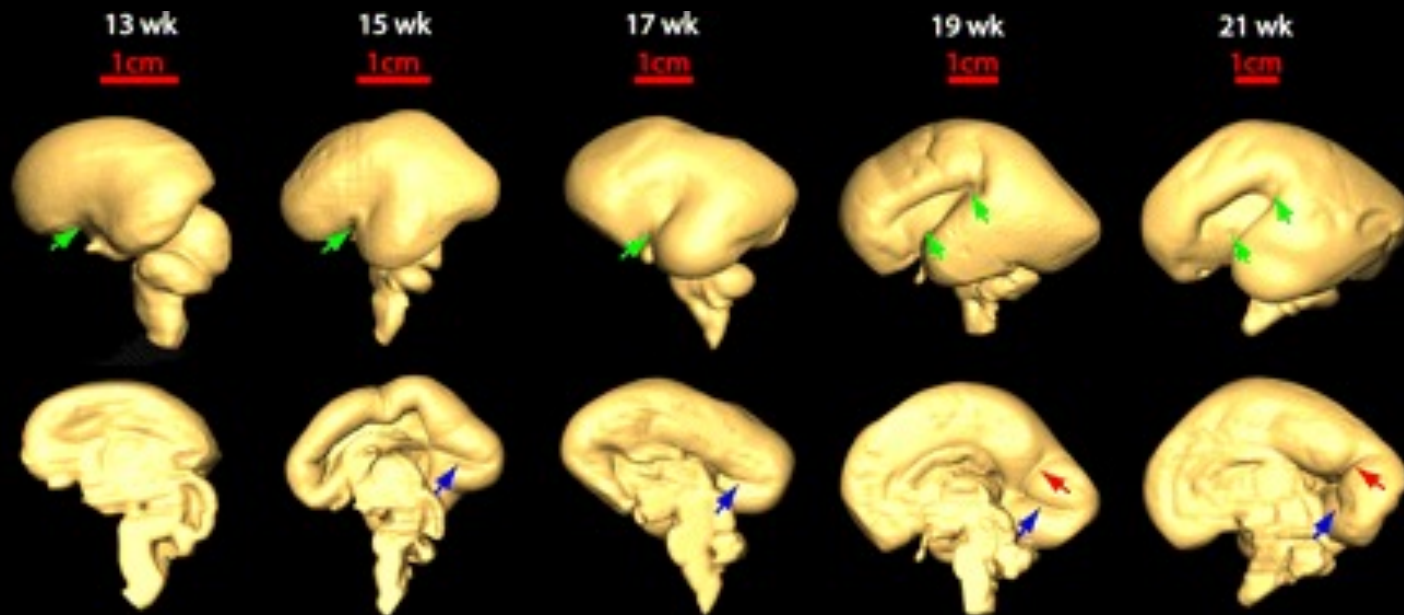
2 = subplate

3 = cortical plate

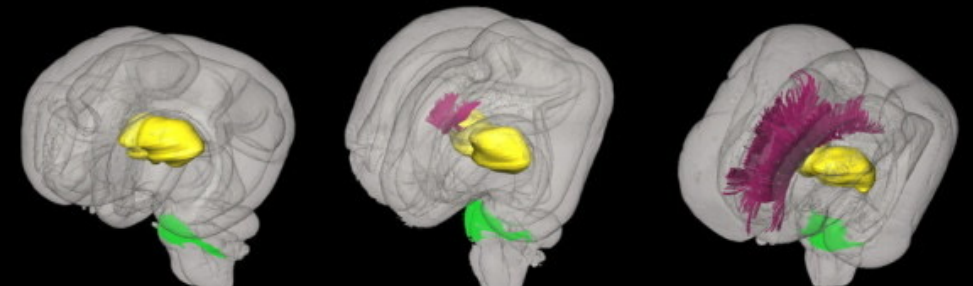
Sequences

Advanced techniques

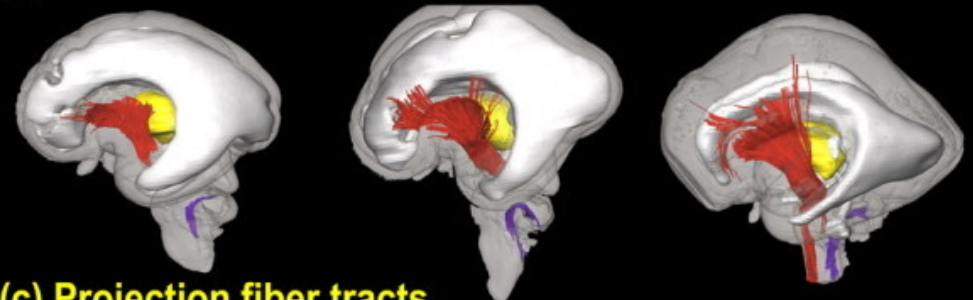
- Diffusion tensor imaging



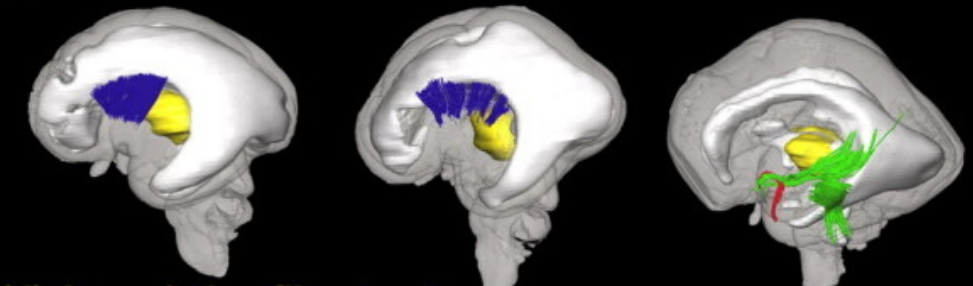
(a) Limbic fiber tracts



(b) Commissural fiber tracts



(c) Projection fiber tracts

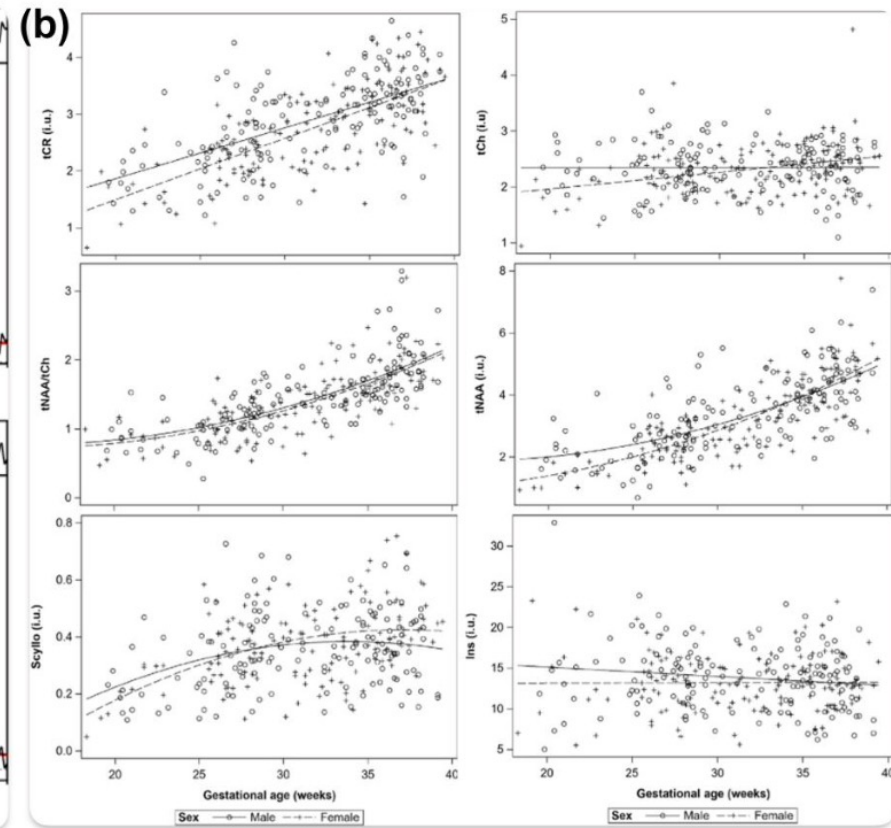
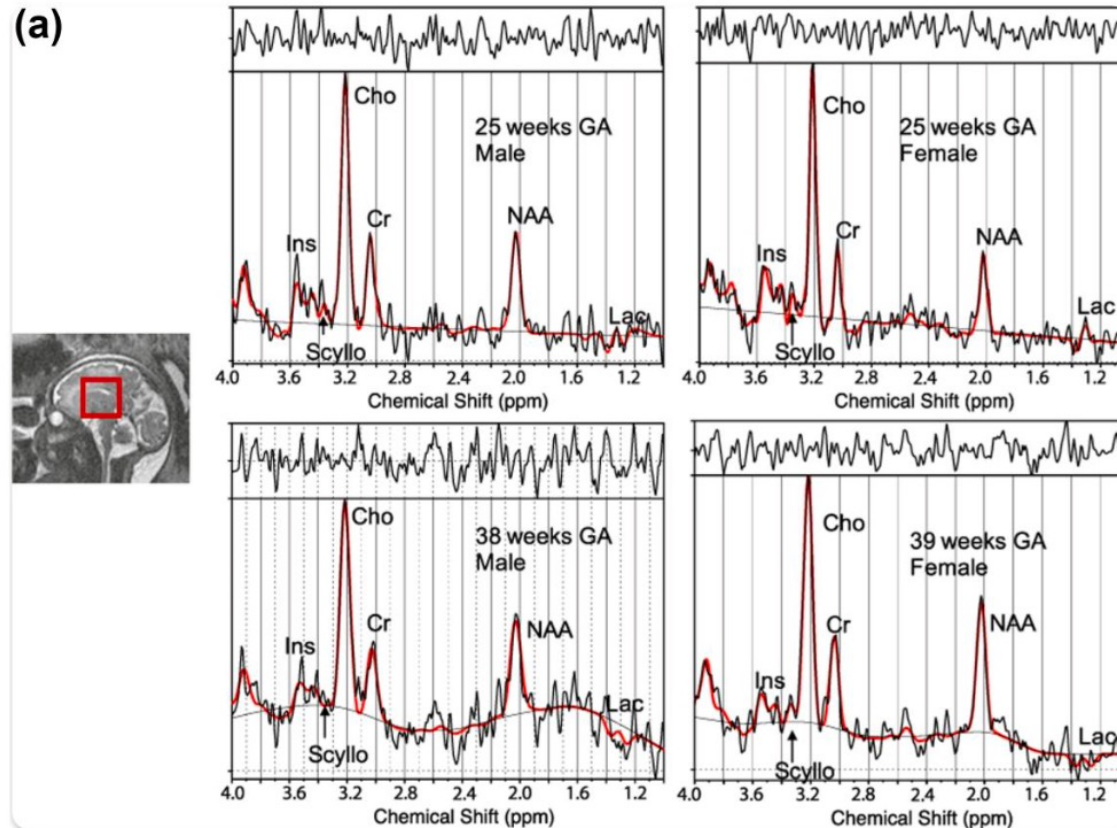


(d) Association fiber tracts

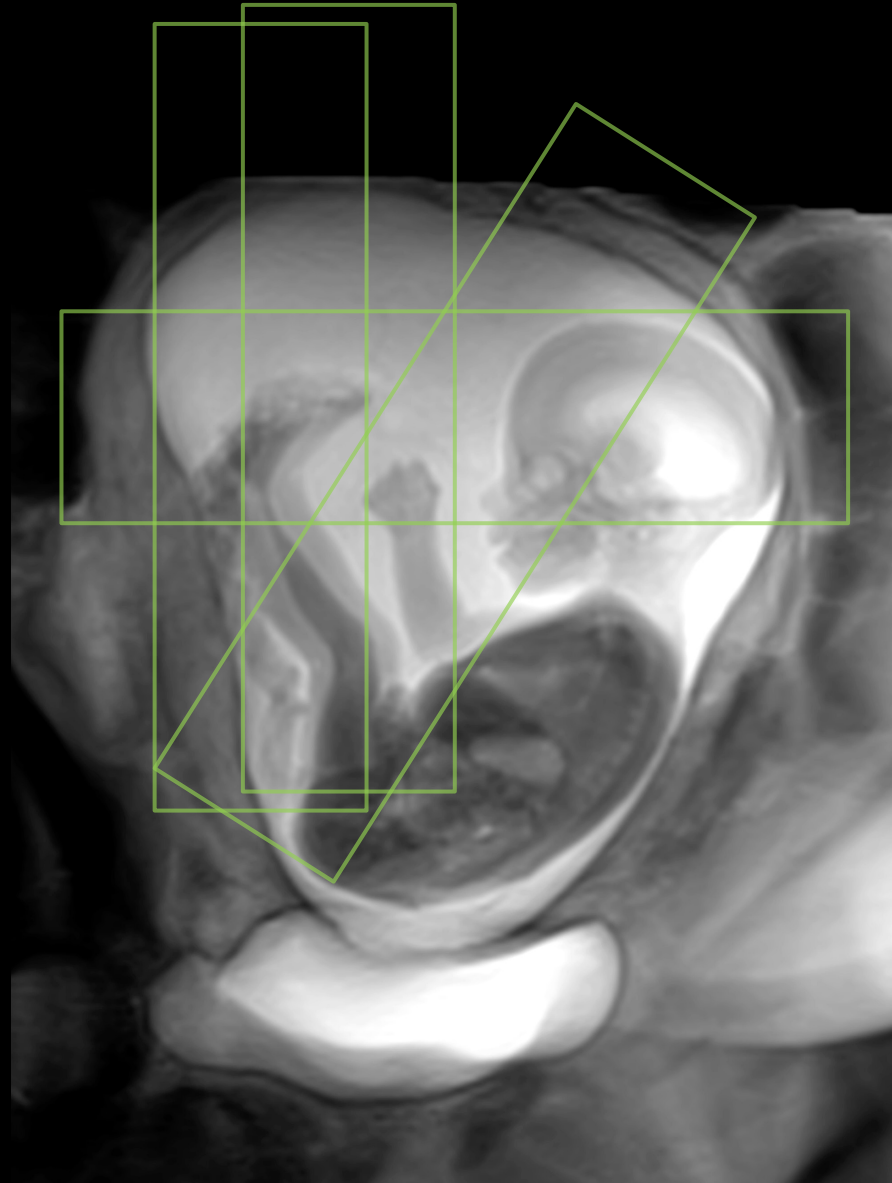
Sequences

Advanced techniques

- MR spectroscopy

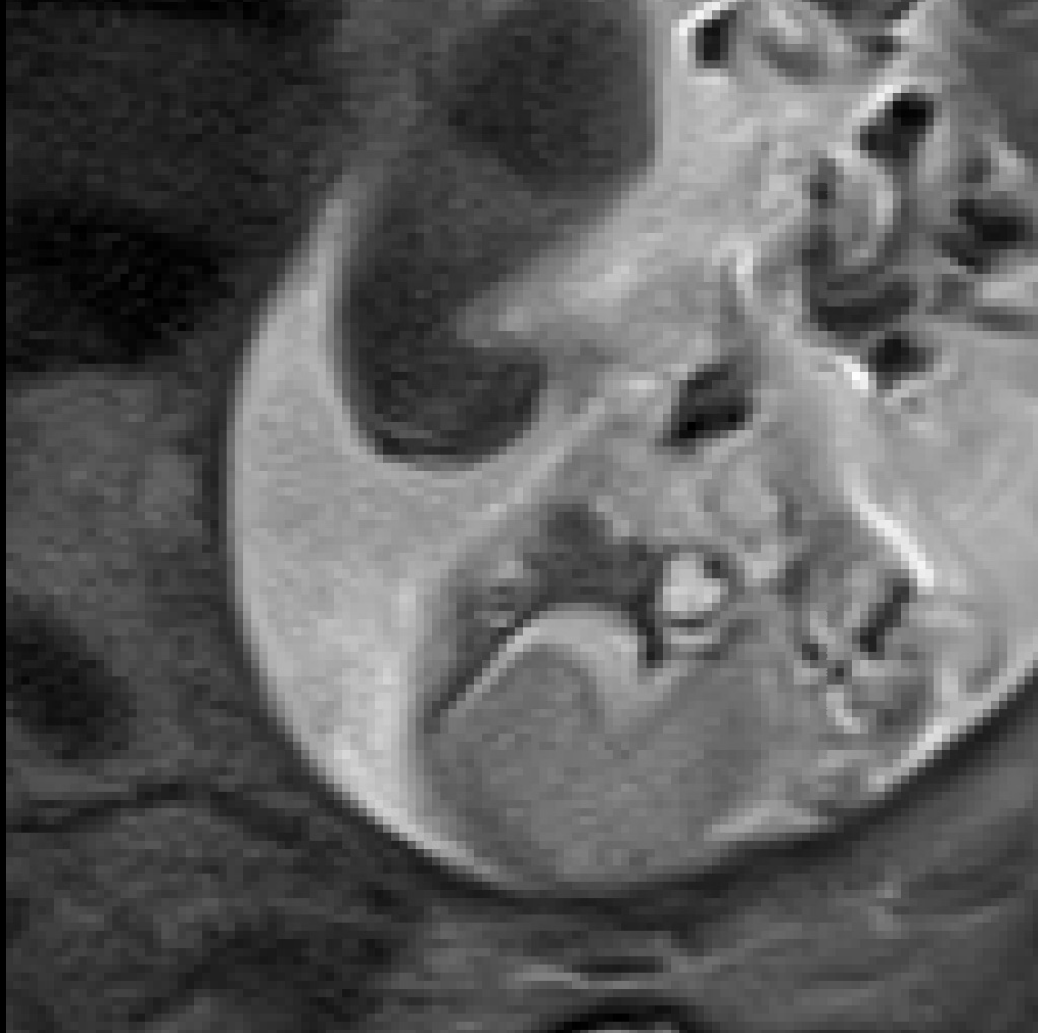


Motion




*Courtesy of Magda Sokolska,
Senior Clinical Scientist, UCLH*

Effects of motion




SAG

- Artefacts due to motion
- Inconsistent head orientation
- Can lead to missed anatomy/pathology



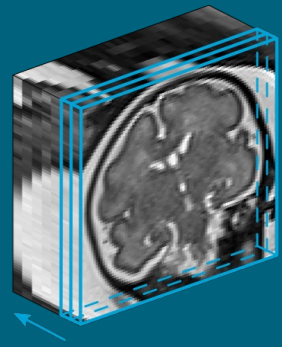
AX



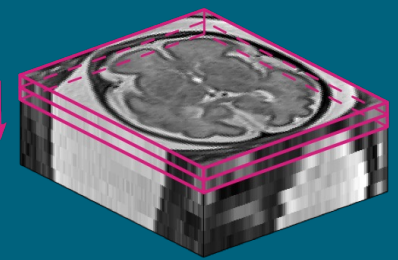
COR

Novel Automated Super Resolution Reconstruction (SRR)

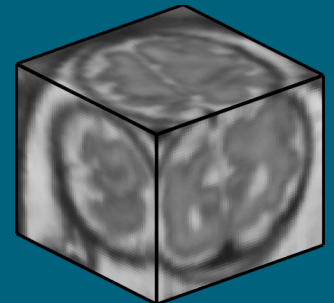
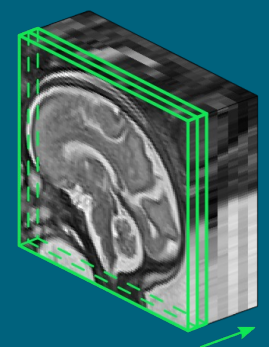
HASTE Coronal



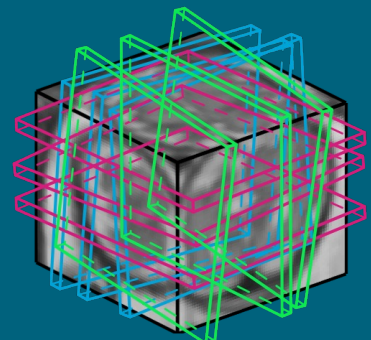
HASTE Axial



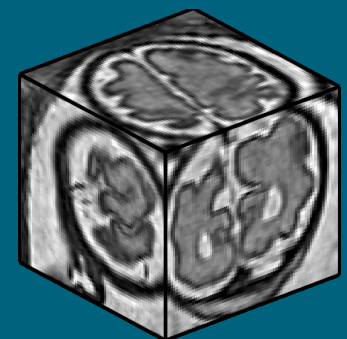
HASTE Sagittal




Initial Volume Estimate



Initial Volume Estimate



Super-Resolution Reconstruction



wellcome
EPSRC centre
interventional +
surgical sciences

An Automated Localization, Segmentation and Reconstruction Framework for Fetal Brain MRI. Ebner & Wang et al MICCAI (1) 2018: 313-320

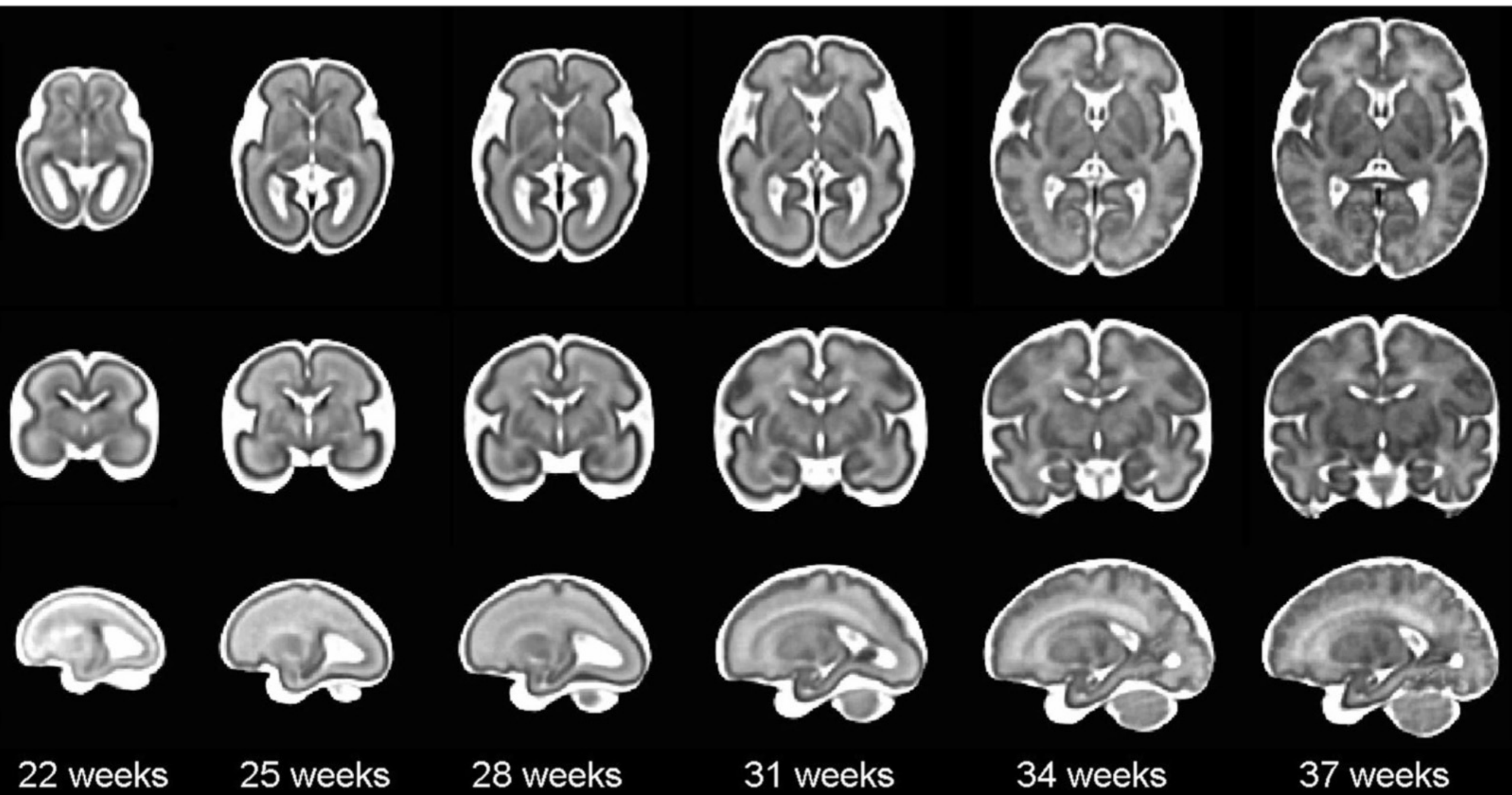
Essentials for optimal interpretation

Always have clinical and ultrasound data available

Experienced interpreter

Understanding of relevant local pregnancy termination laws

Compare 2D measurements with existing centile charts based on GA *



Brain Struct Funct (2017) 222:2295–2307


DOI 10.1007/s00429-016-1342-6



CrossMark

ORIGINAL ARTICLE

Normative biometry of the fetal brain using magnetic resonance imaging

Vanessa Kyriakopoulou¹  · Deniz Vatansever¹ · Alice Davidson¹ · Prachi Patkee¹ ·
Samia Elkommos¹ · Andrew Chew¹ · Miriam Martinez-Biarge¹ · Bibbi Hagberg^{1,2} ·
Mellisa Damodaram¹ · Joanna Allsop¹ · Matt Fox¹ · Joseph V. Hajnal¹ ·
Mary A. Rutherford¹

Ultrasound Obstet Gynecol 2009; 33: 173–181

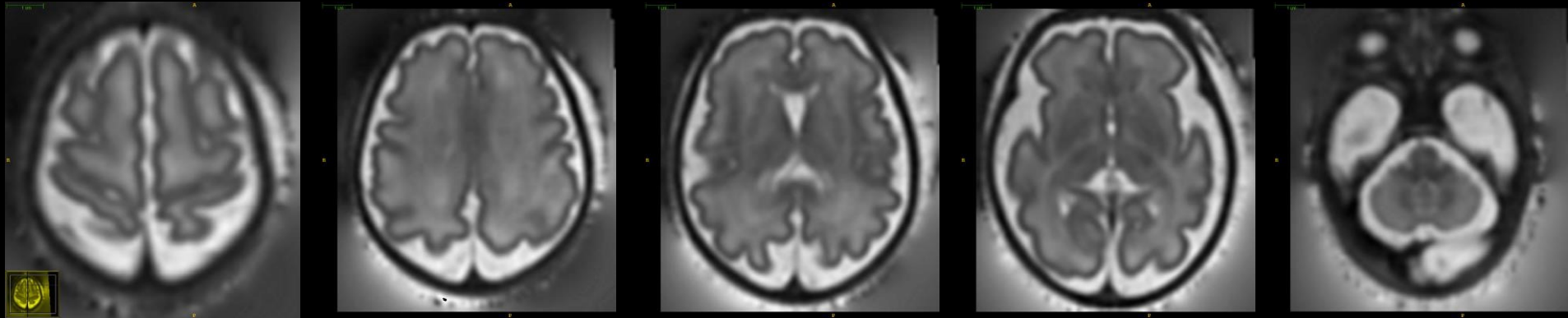
Published online in Wiley InterScience (www.interscience.wiley.com). DOI: 10.1002/uog.6276

Cerebral biometry in fetal magnetic resonance imaging: new reference data

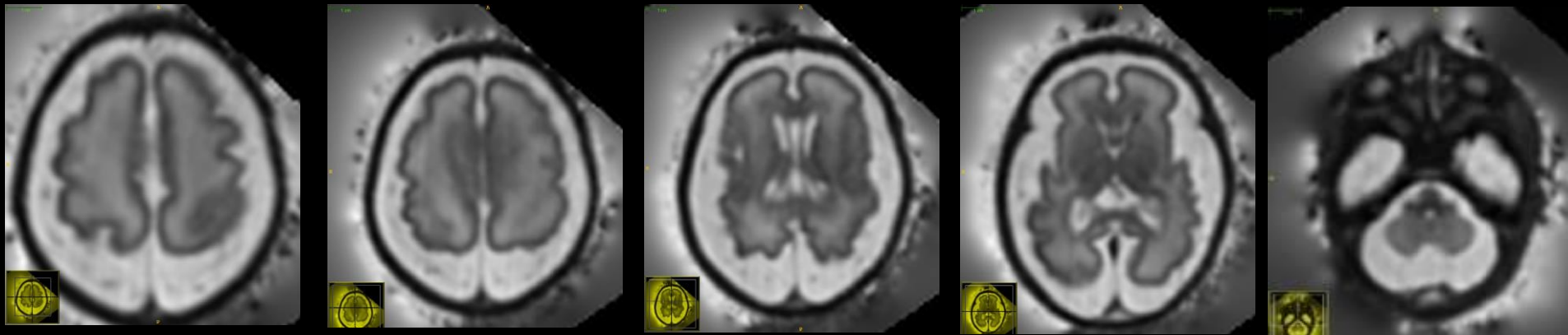
B. TILEA*†, C. ALBERTI‡§, C. ADAMSBAUM¶**, P. ARMOOGUM‡§, J. F. OURY†°,
D. CABROL**#, G. SEBAG*†, G. KALIFA¶** and C. GAREL^*

*AP-HP, Hôpital Robert Debré, Service d'Imagerie Pédiatrique, °AP-HP, Hôpital Robert Debré, Service de Gynécologie Obstétrique - Centre de Diagnostic Prénatal, ‡AP-HP, Hôpital Robert Debré, Unité d'Epidémiologie Clinique, ¶AP-HP, Hôpital Saint-Vincent-de-Paul, Service de Radiologie Pédiatrique, #AP-HP, Hôpital Saint-Vincent-de-Paul, Centre de Diagnostic Prénatal - Maternité de Port-Royal, ^AP-HP, Hôpital d'Enfants Armand-Trousseau, Service de Radiologie Pédiatrique, †Université Paris VII Denis Diderot, §Inserm, CIE5 and **Université Paris V René Descartes, Paris, France

30 weeks (normal)



30 weeks



Post-mortem: Abnormal thin cortex, neuronal migration delay in the WM, blurring of grey/white matter boundary, partial rhomboencephalosynapsis.

Clinical Indications: CNS

- Ventriculomegaly
- Agenesis/dysgenesis of the corpus callosum
- Absent Cavum septum pellucidum
- Micro or Macrocephaly – cortical malformations
- Intracranial haemorrhage
- Posterior fossa abnormalities
- Vein of Galen malformation
- Congenital infections
- Neural tube defects
- Orofacial abnormalities
- Complications of twin pregnancies (TTTS, TAPS)

Clinical Indications: *CNS*

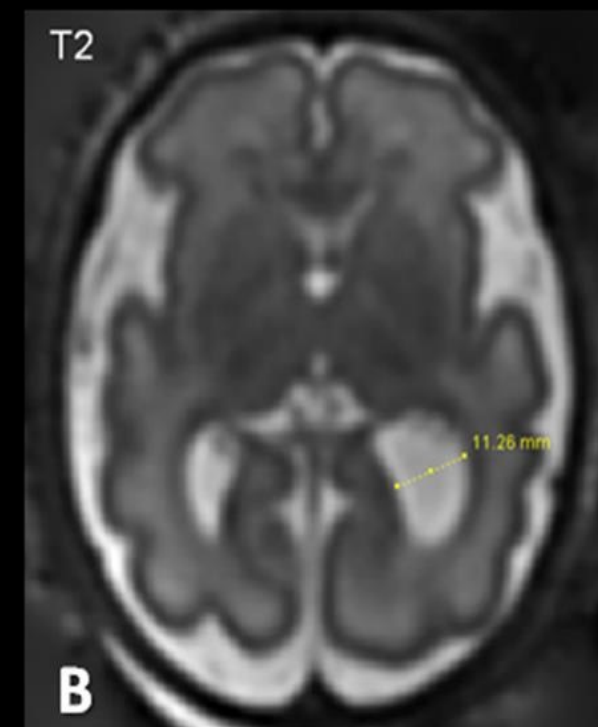
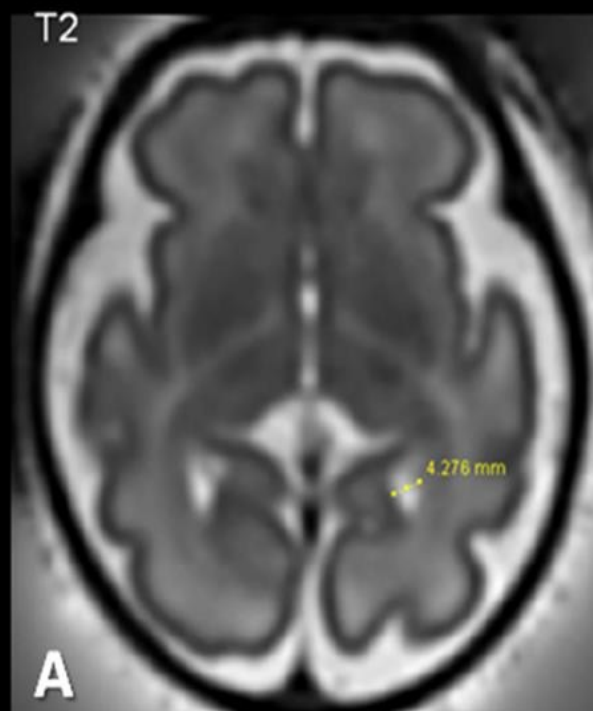
- Reassurance for patients with previous sibling abnormality
- Known genetic abnormality for phenotype if variable expression
- Fetal anaemia of unknown aetiology
- Acute maternal hypoxic event or illness

Clinical Indications: CNS

- Ventriculomegaly
- Agenesis/dysgenesis of the corpus callosum
- Absent Cavum septum pellucidum
- Micro or Macrocephaly – cortical malformations
- Intracranial haemorrhage
- Posterior fossa abnormalities
- Vein of Galen malformation
- Congenital infections
- Neural tube defects
- Orofacial abnormalities
- Complications of twin pregnancies (TTTS, TAPS)

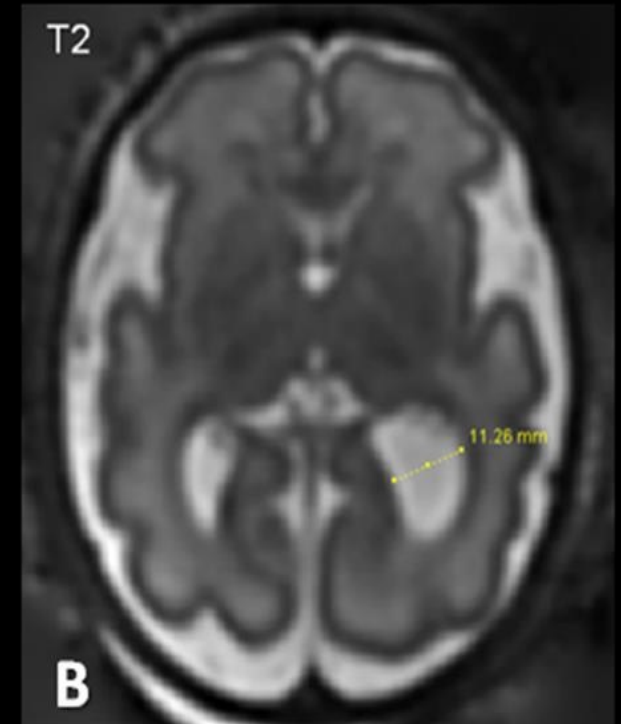
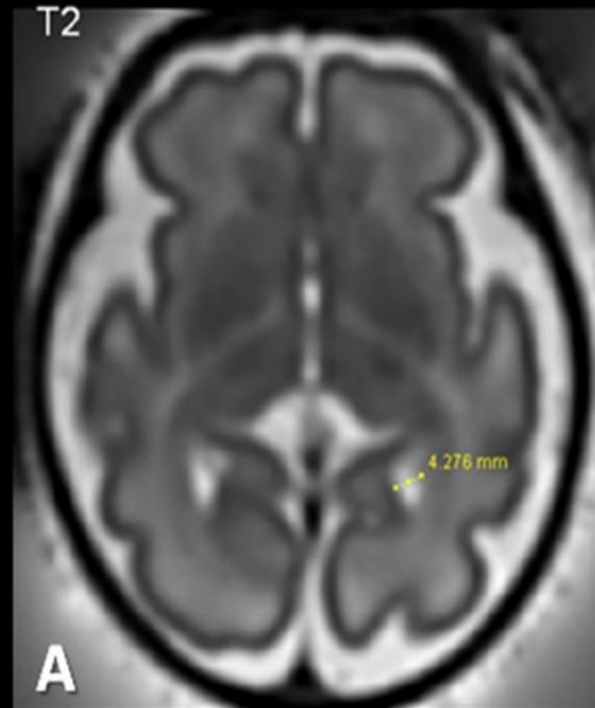
Ventriculomegaly

- 1% pregnancies atrial diameter > 10 mm
- More frequent in male - 61%
- Current practice: further investigations
 - Detailed fetal ultrasound
 - Maternal TORCH screen
 - Fetal MRI
 - Consider Amniocentesis



Isolated Ventriculomegaly - Outcome

- Normal NDV at 2y
- Mild 10-12mm = 93%
- Moderate 12.1-14.9mm = 75%
- Severe 15mm or more = 62.5%

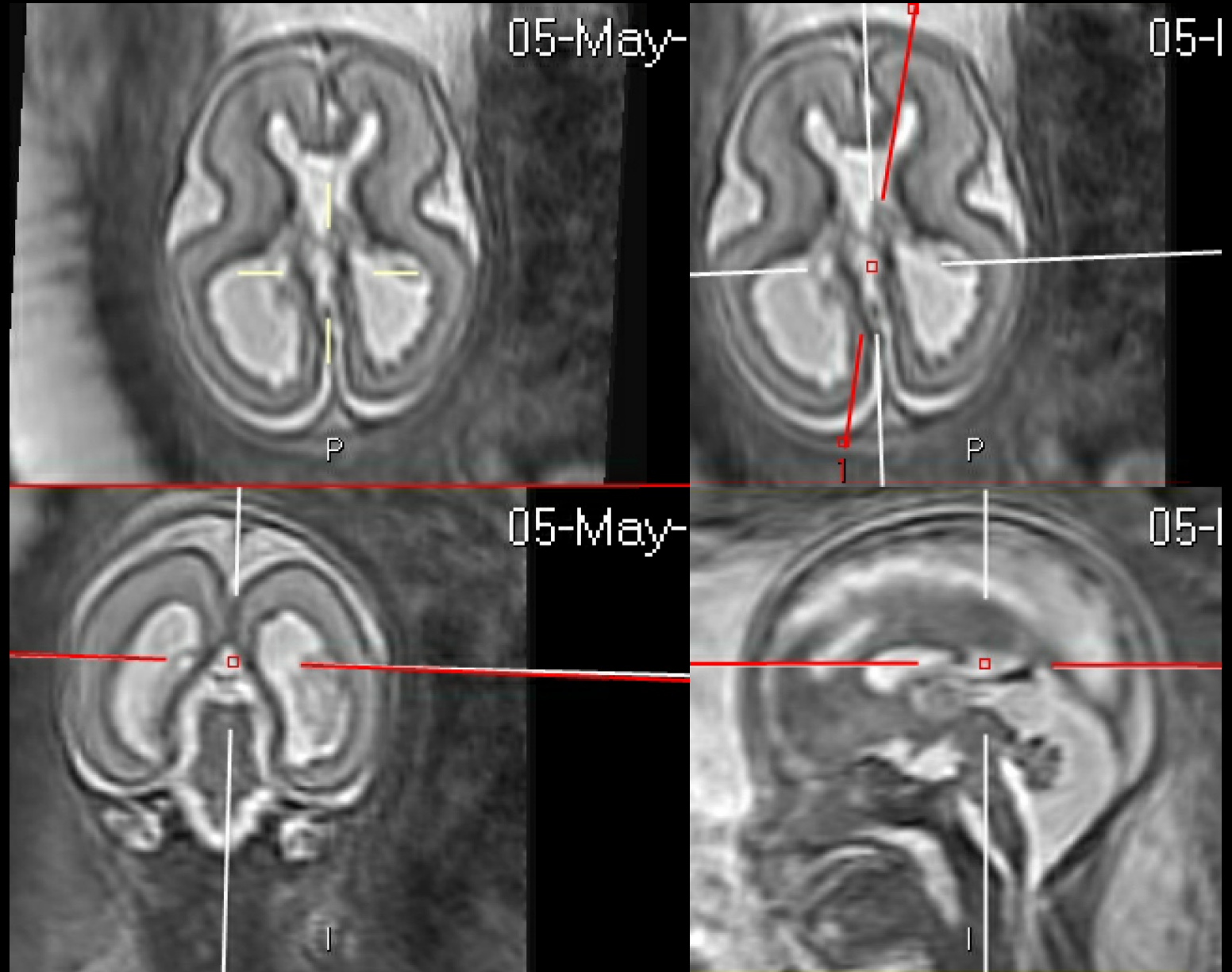


23w + 5d
Ventriculomegaly

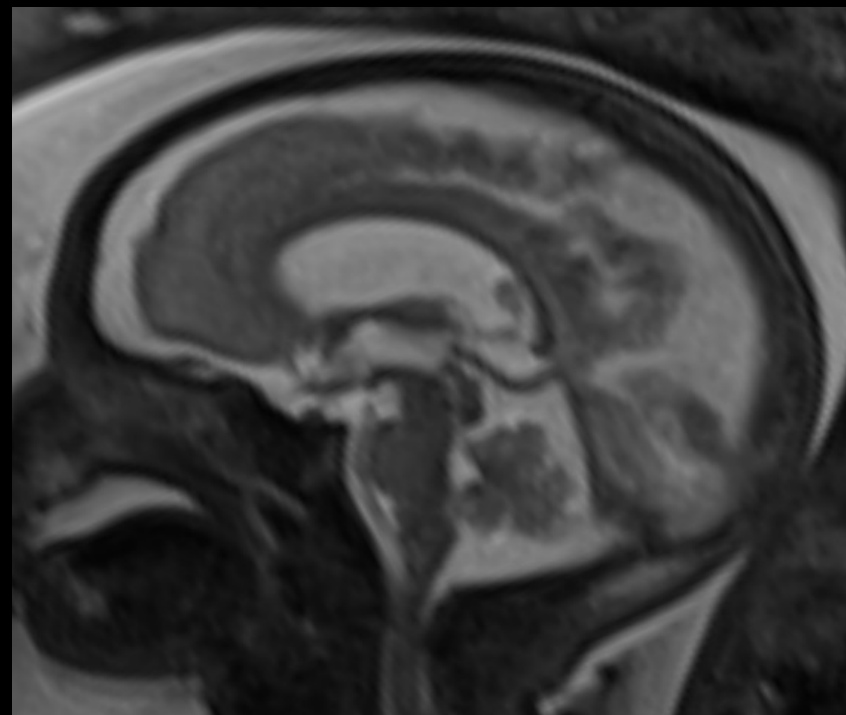
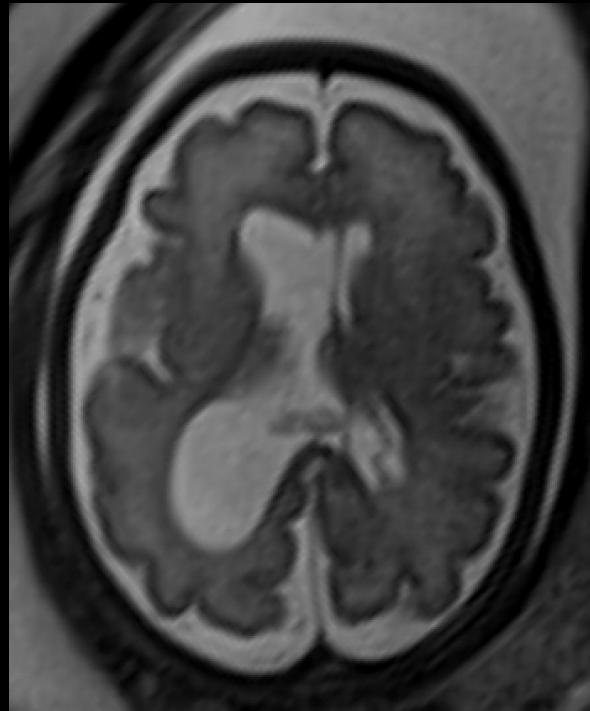
Nodular Heterotopia

Abnormal
 Opercularisation

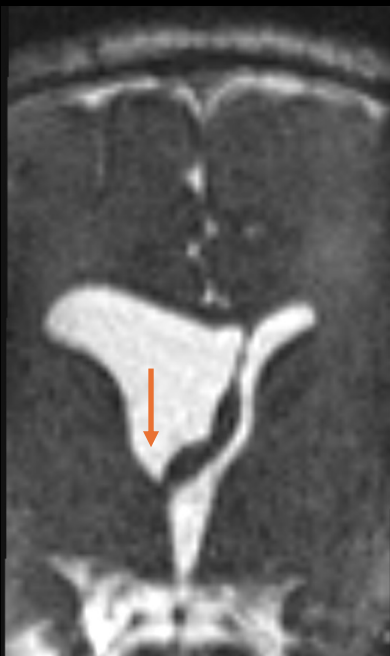Vermis Hypoplasia



Fetal MRI
23 w+ 4d



Neonatal
MRI

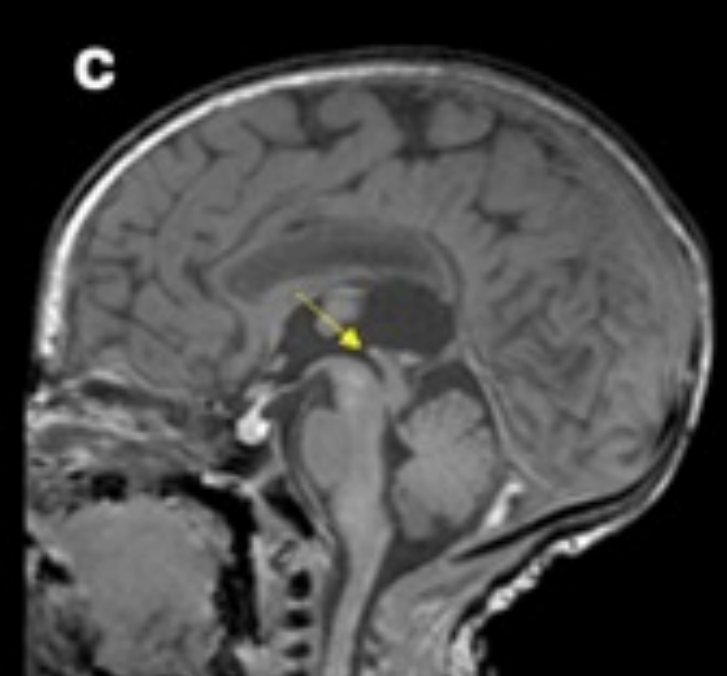
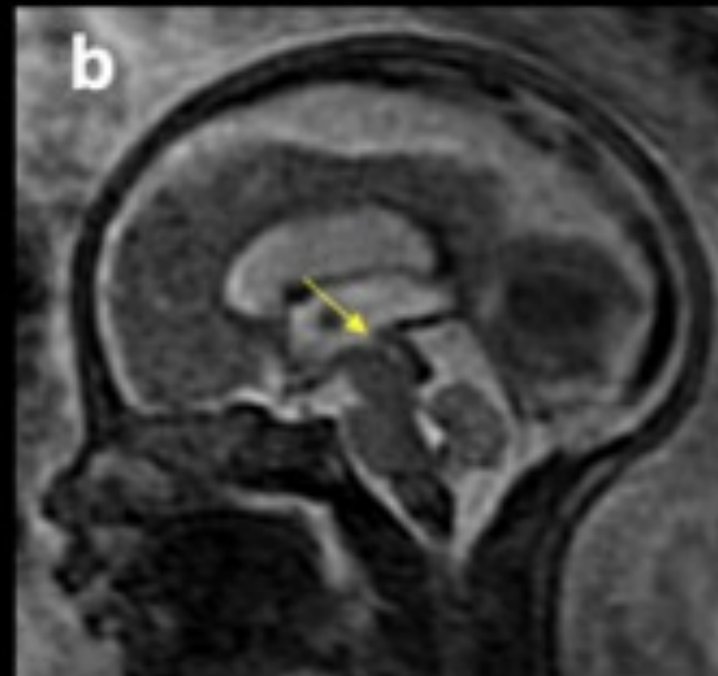
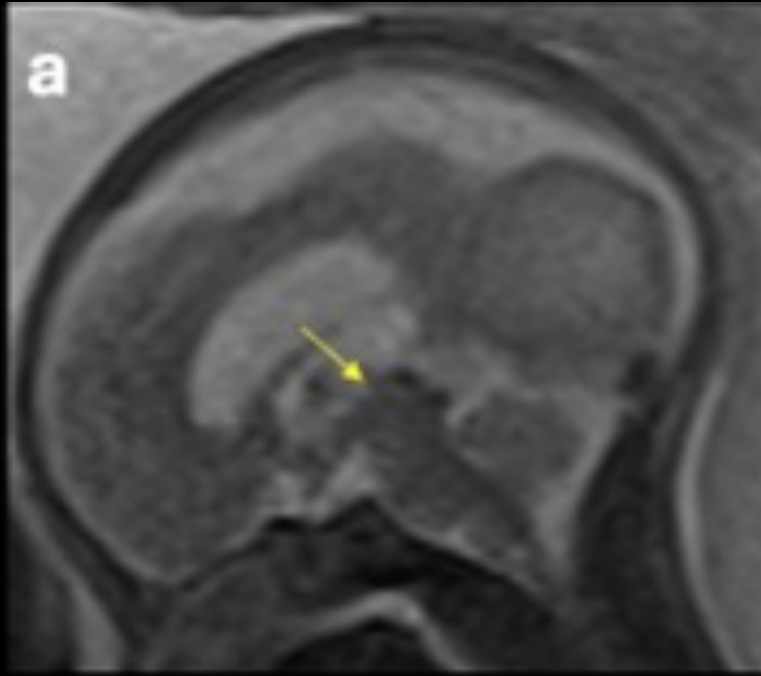


Unilateral F. Monro
occlusion

Aqueduct stenosis

Prenatal

Post-natal

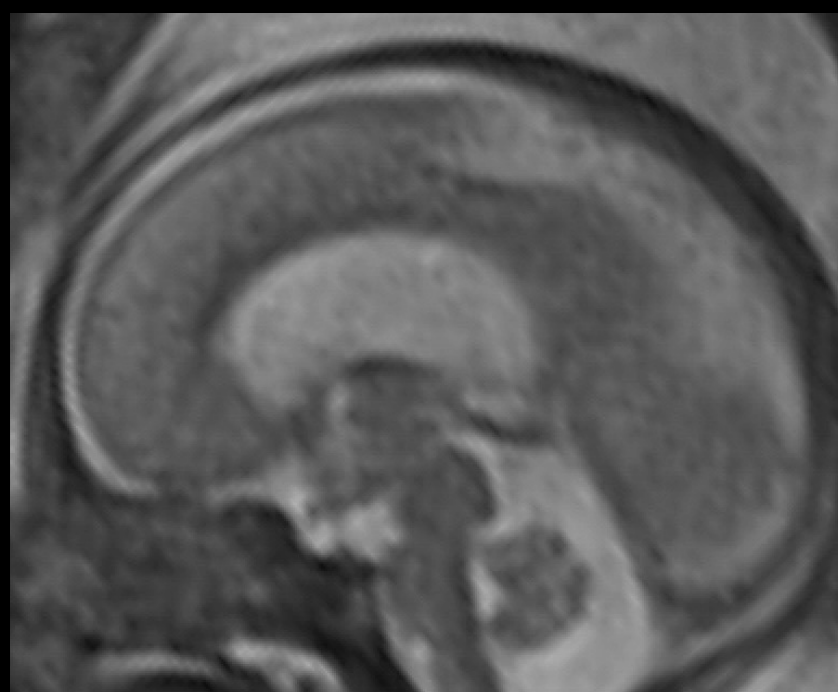
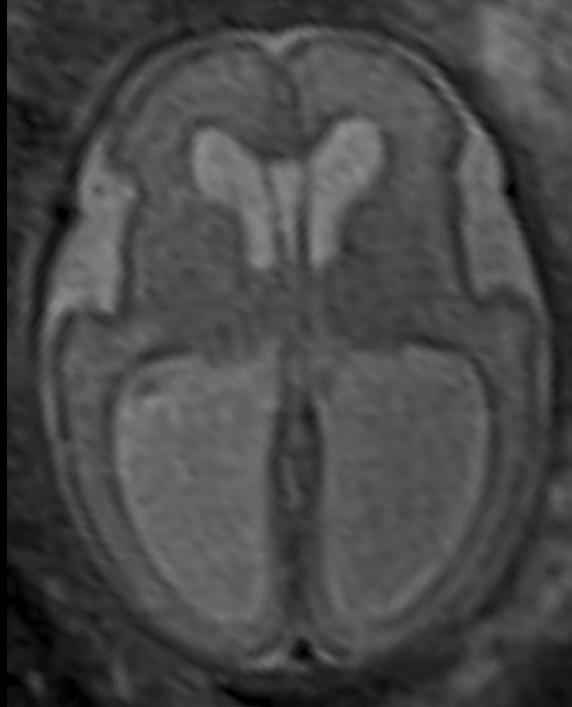


Source images

SVR

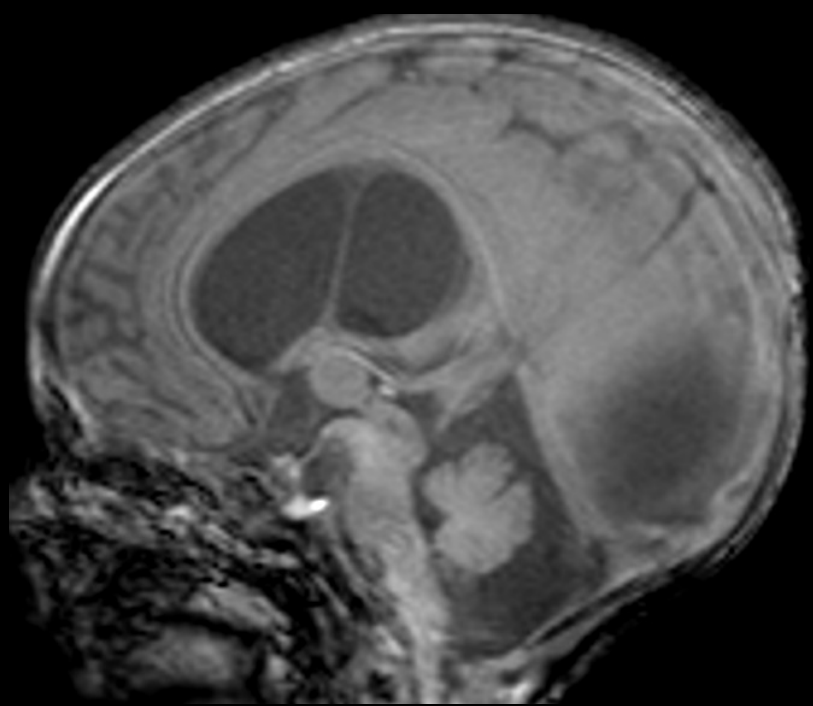
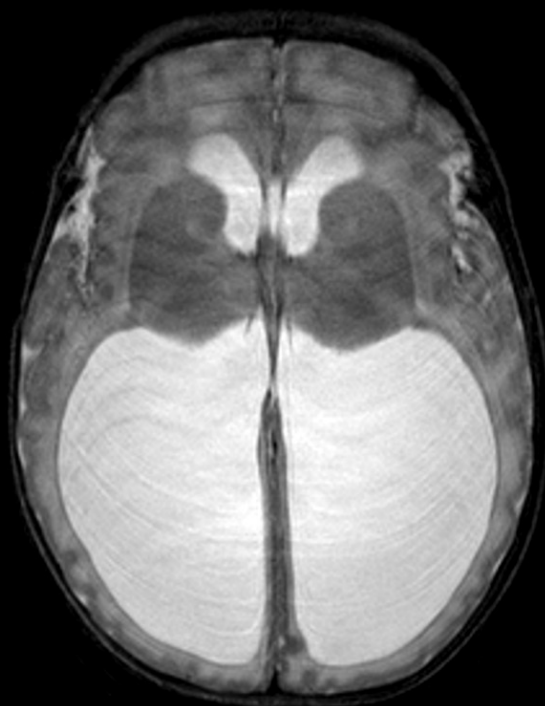MPRAGE

Fetal MRI
27 w



**Congenital
Aqueduct stenosis**

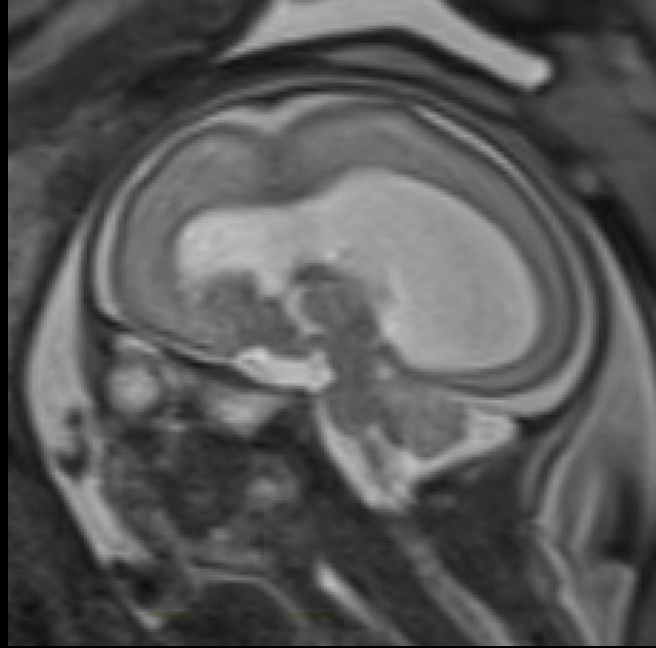
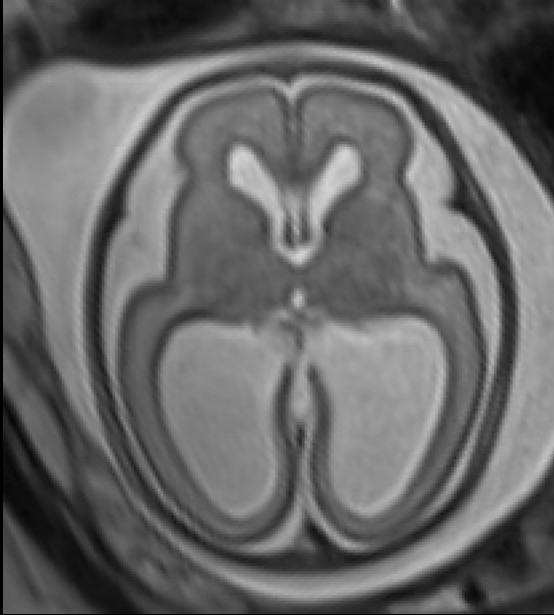
Neonatal
MRI



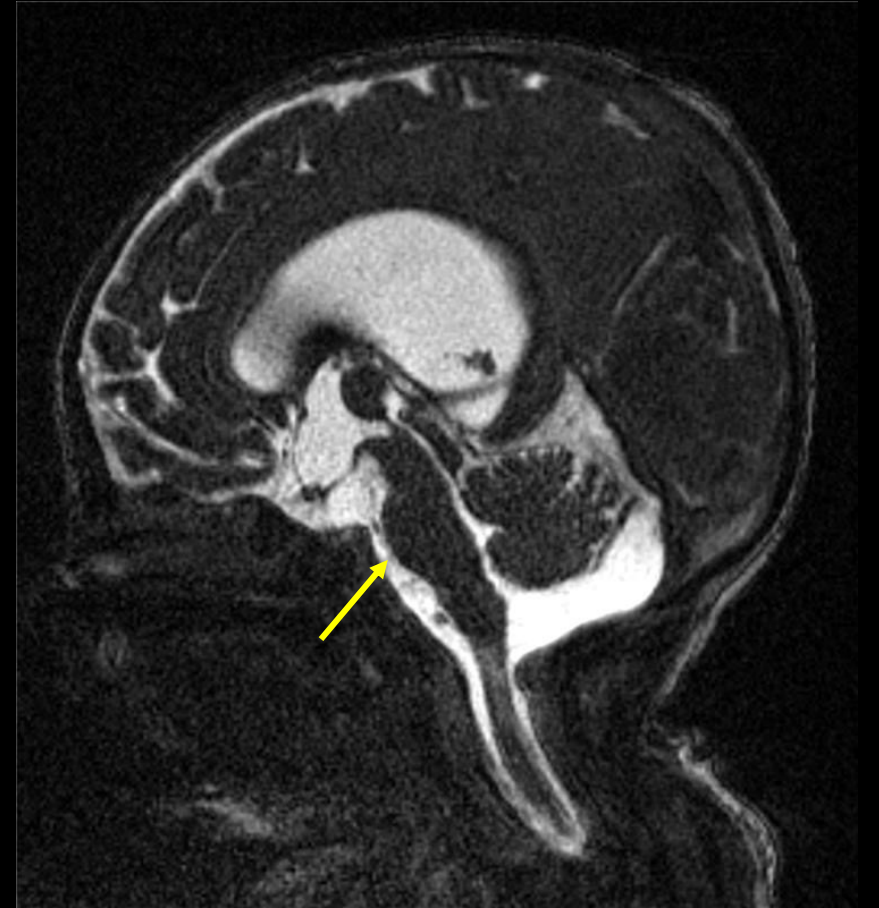
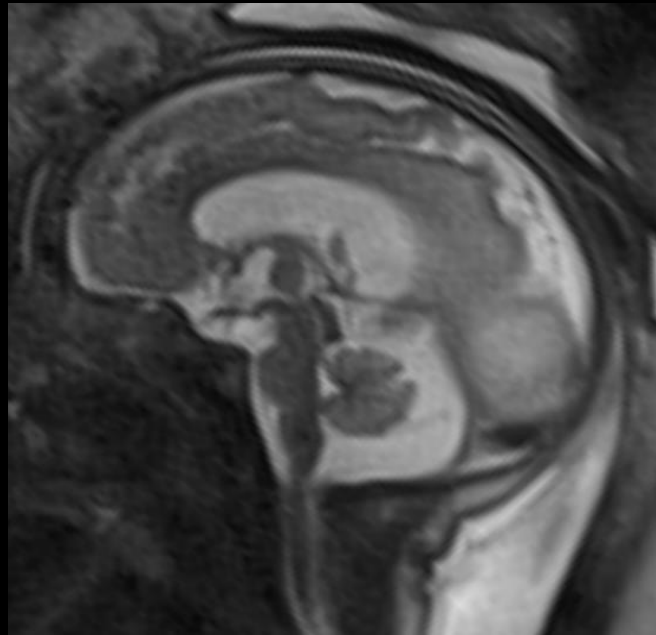
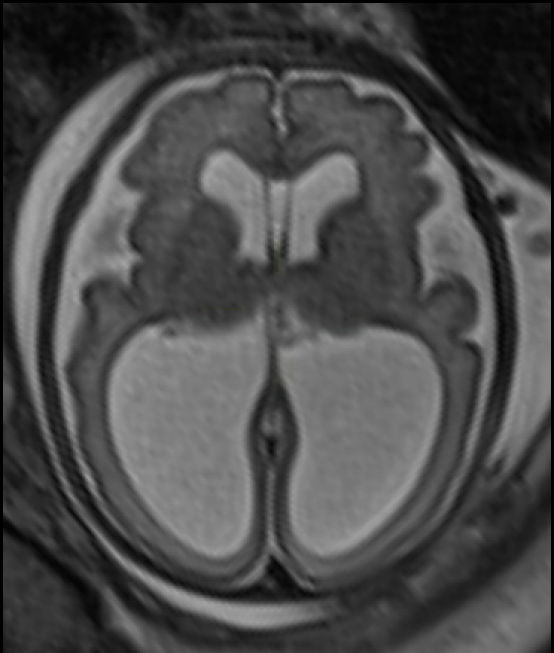
Fetal MRI

Neonatal MRI

26 w



31 w



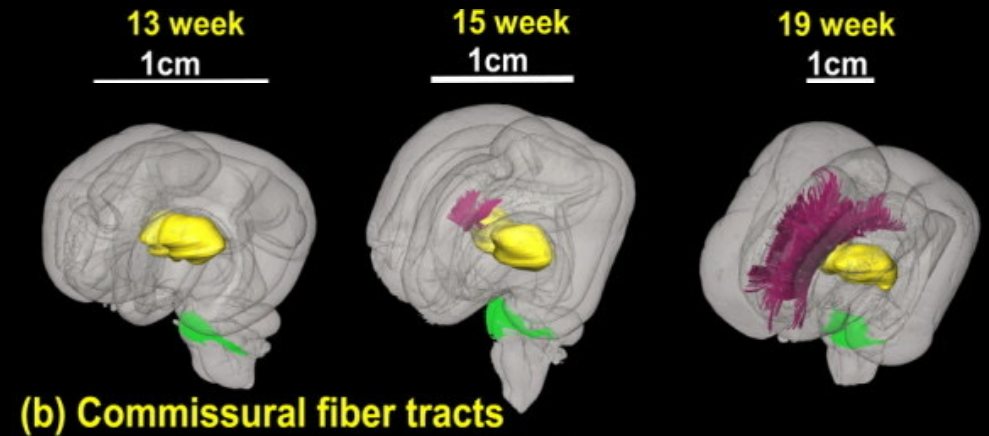
**Diencephalic-
mesencephalic junction
anomaly**

Clinical Indications: CNS

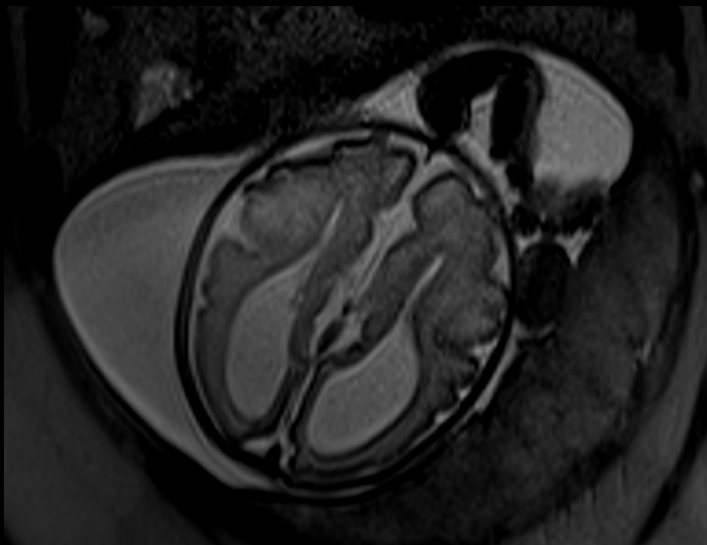
- Ventriculomegaly
- Agenesis/dysgenesis of the corpus callosum
- Absent Cavum septum pellucidum
- Micro or Macrocephaly – cortical malformations
- Intracranial haemorrhage
- Posterior fossa abnormalities
- Vein of Galen malformation
- Congenital infections
- Neural tube defects
- Orofacial abnormalities
- Complications of twin pregnancies (TTTS, TAPS)

Aggenesis / Dysgenesis of the corpus callosum

- Disruption brain cell migration (~ 8 – 18 weeks)
- ACC: 1:5000 to 1:4000 (0.020–0.025%)
- Exclude other abnormalities
 - increased detection with MRI 22.5%
- Chromosomal abnormalities in ~17%
 - worse outcome
- Gender
 - Aicardi syndrome – females, infantile spasms, chorioretinal lacunae

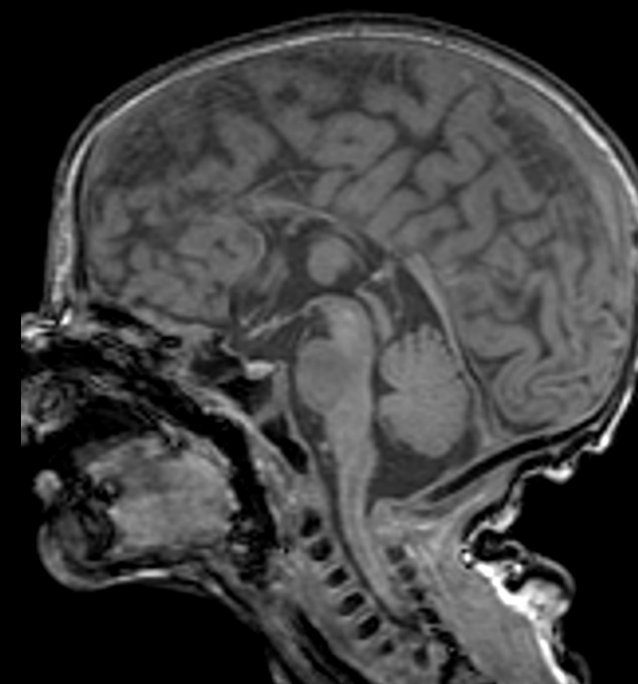
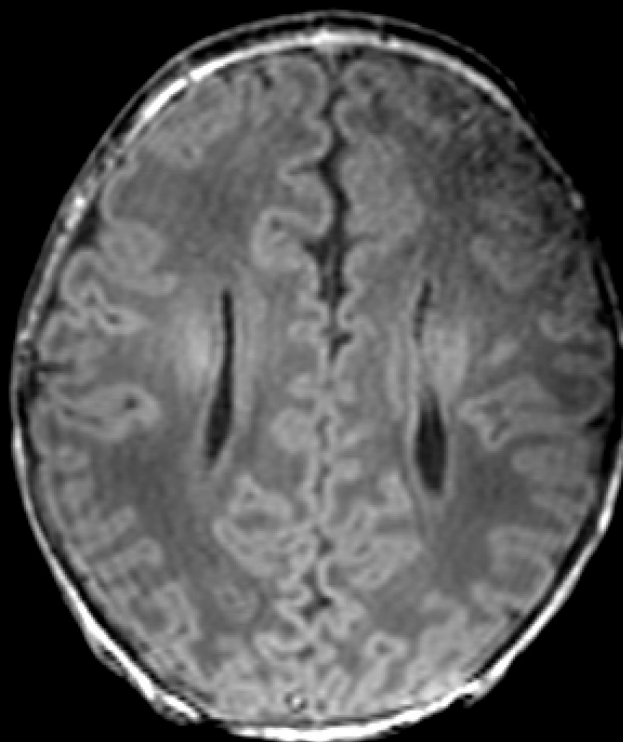
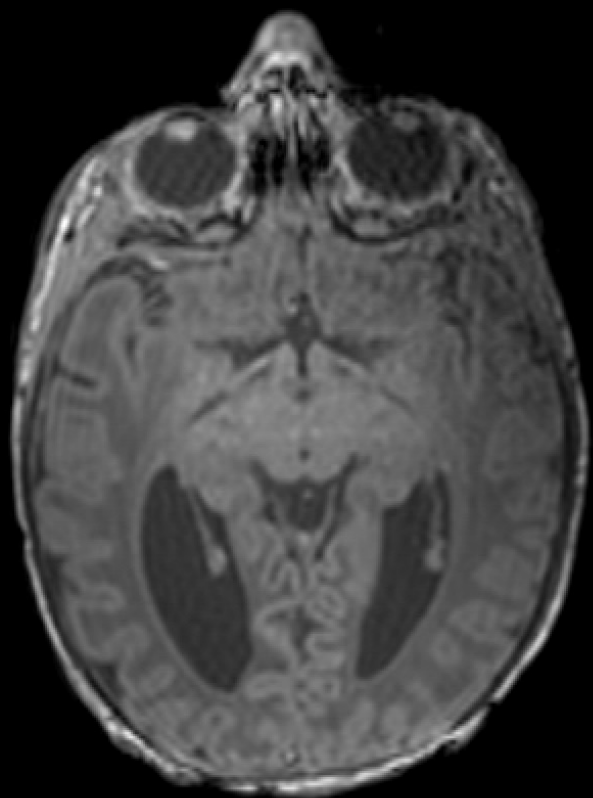


Fetal MRI
30w +4d

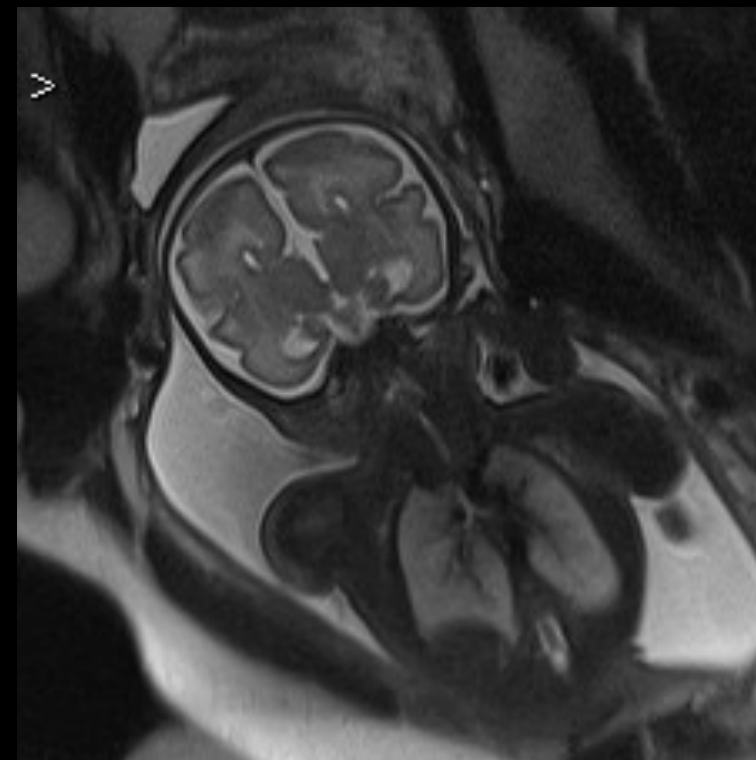
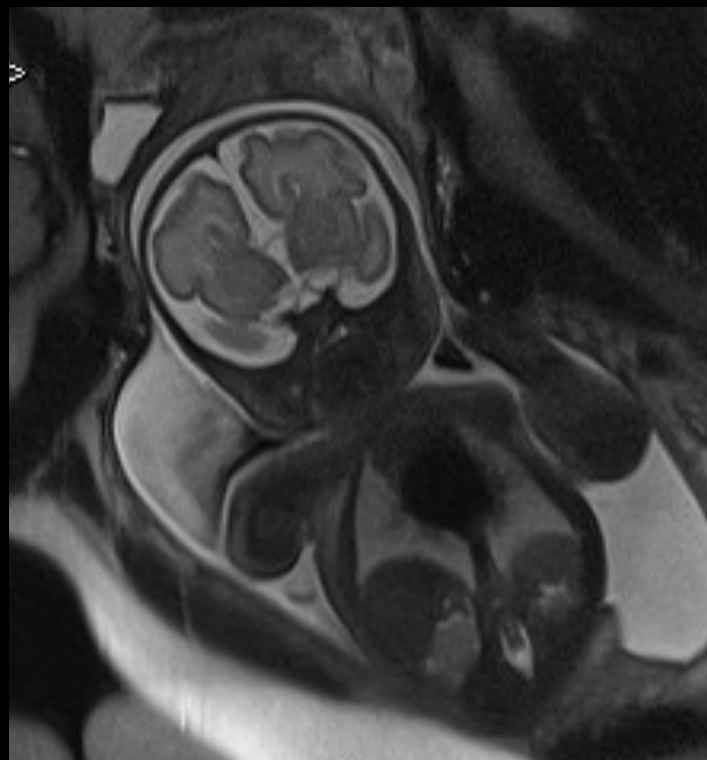
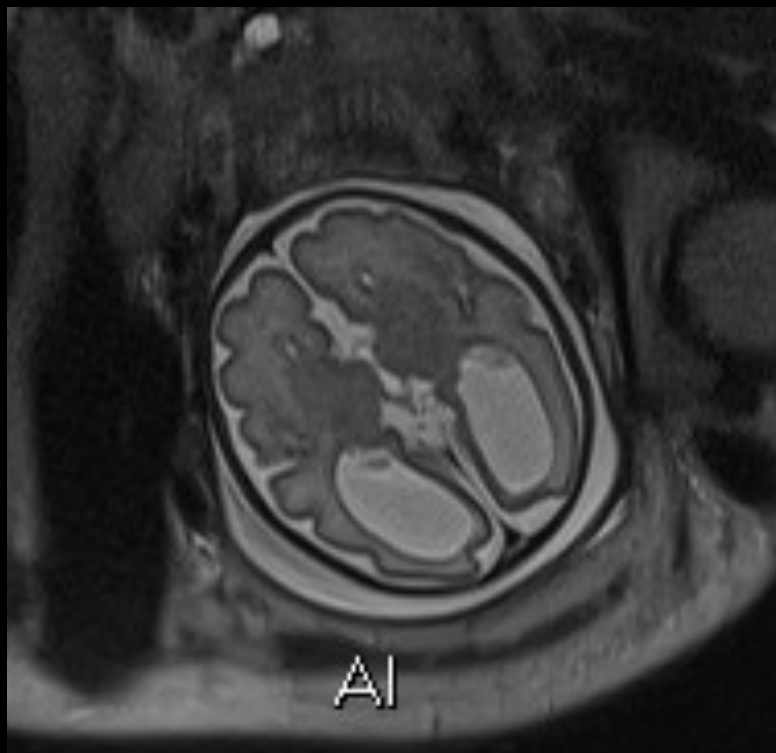


CC
Agenesis

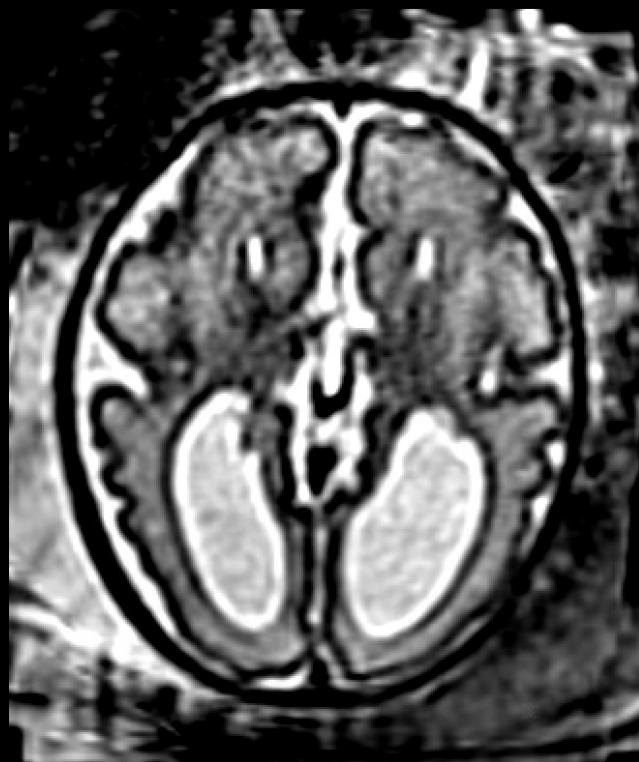Neonatal MRI



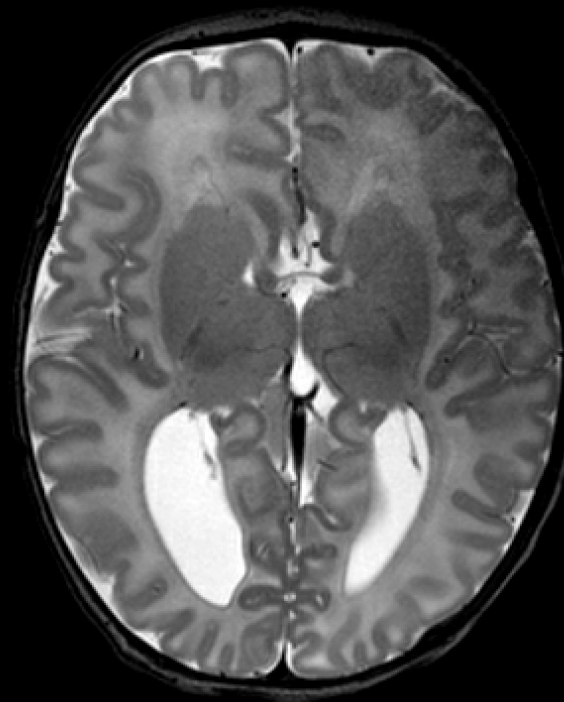
Agenesis CC 31w



Ageneis CC



30w 4d



40w 5d post natal

Isolated ACC – outcome 1y – 4y age

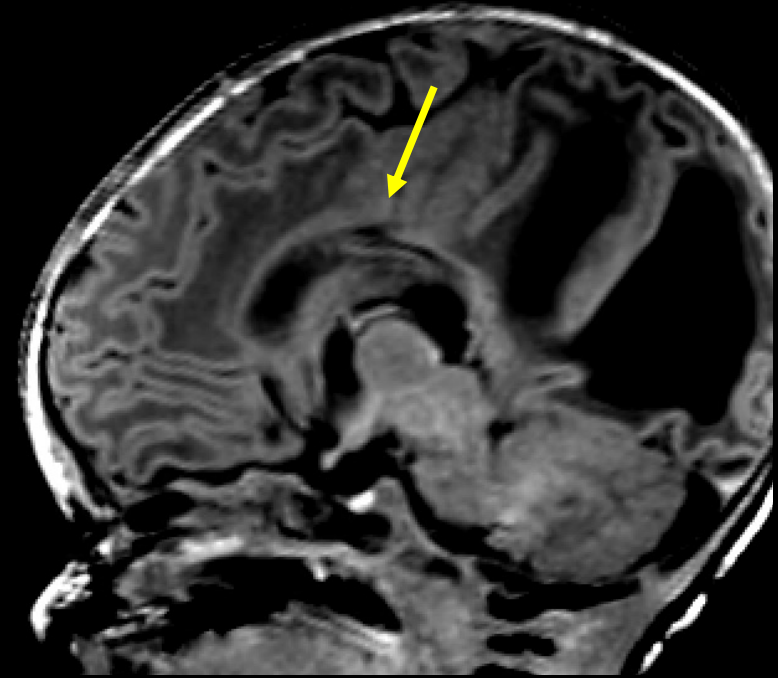
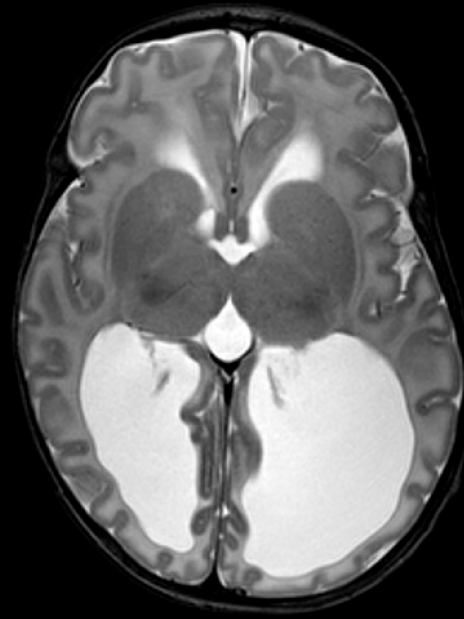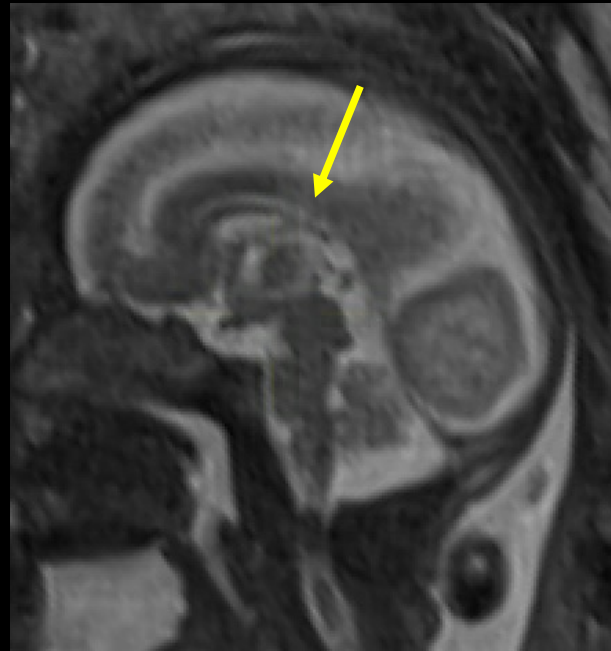
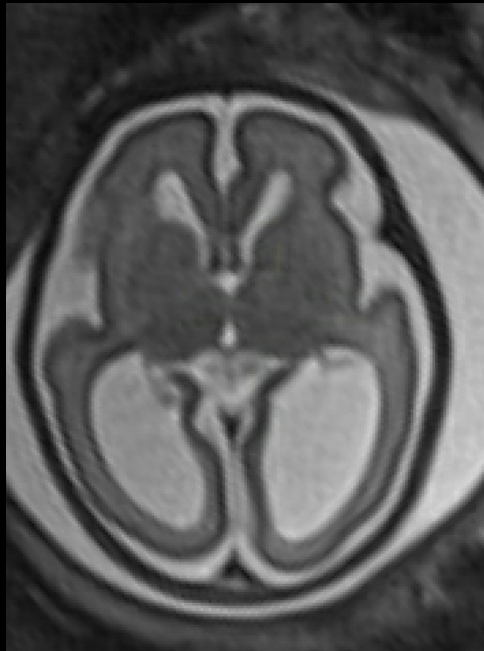
Table 1 Magnetic resonance imaging scoring system for fetuses with corpus callosal agenesis

Parameter	Score (points)		
	0	1	2
Gyration	Normal	Mildly delayed (≤ 2 weeks)	Delayed (> 2 weeks)
Opercularization	Normal	Delayed	—
Temporal lobe asymmetry*	Asymmetrical (R $>$ L)	Symmetrical (R = L) or inverted (L $>$ R)	—
Hippocampi	Normal	Malrotation (mild to moderate and/or unilateral)	Verticalization (bilateral), reduced volume
Lamination	Normal	—	Abnormal
Basal ganglia	Normal	Abnormal	—
Ventricular size†	Normal (< 10 mm)	10–14.9 mm	≥ 15 mm

*Temporal lobe asymmetry described according to Kasprian *et al.*²⁴; if not assessable (i.e. at later gestational ages (> 32 weeks)), a score of 0 should be given. †Measured at level of atrium; if ventricular size is asymmetrical, larger ventricle should be assessed. L, left; R, right.

Significant negative correlation between fetal MRI score and neurodevelopmental outcome in the three fields tested: cognitive ($\rho = -0.559$, $P < 0.0001$), motor ($\rho = -0.414$, $P = 0.012$) and language ($\rho = -0.565$, $P < 0.0001$).

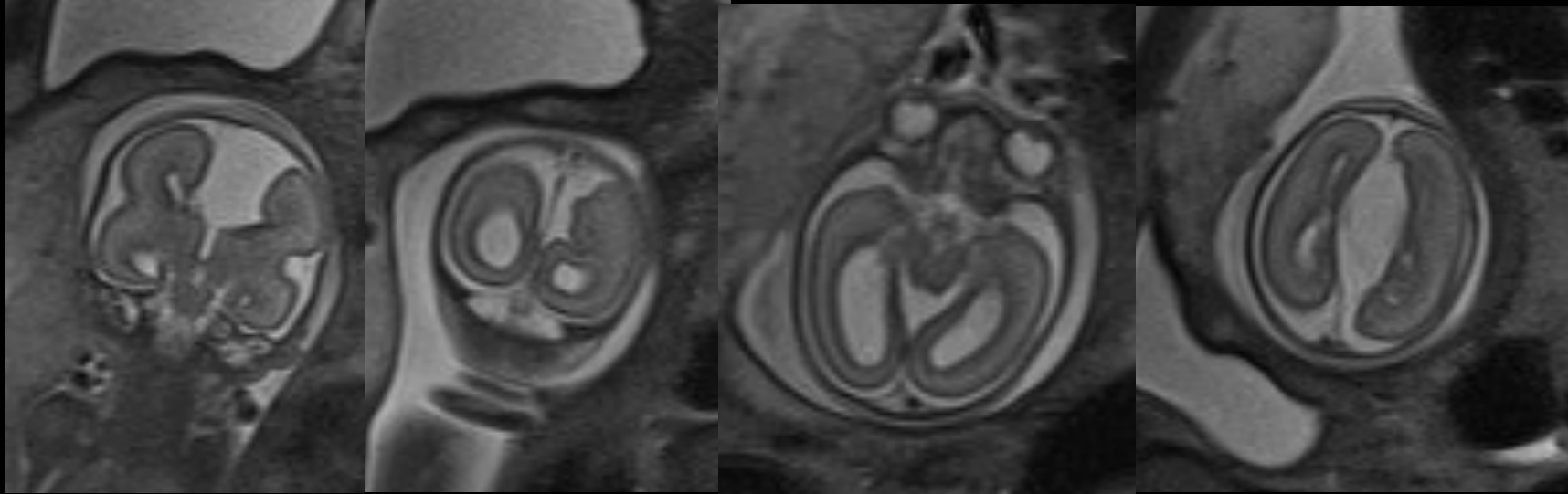
Splenium hypoplasia



Fetal MRI

Neonatal MRI

Aggenesis CC with interhemispheric cyst



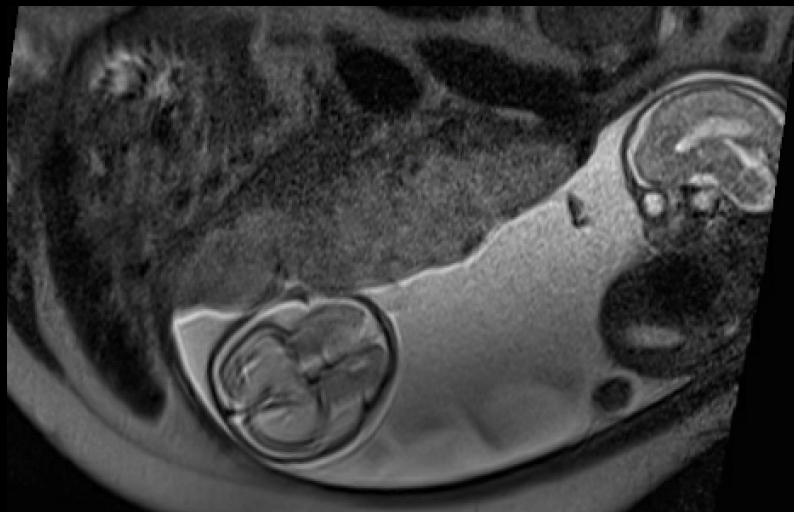22w + 4d

Aggenesis CC

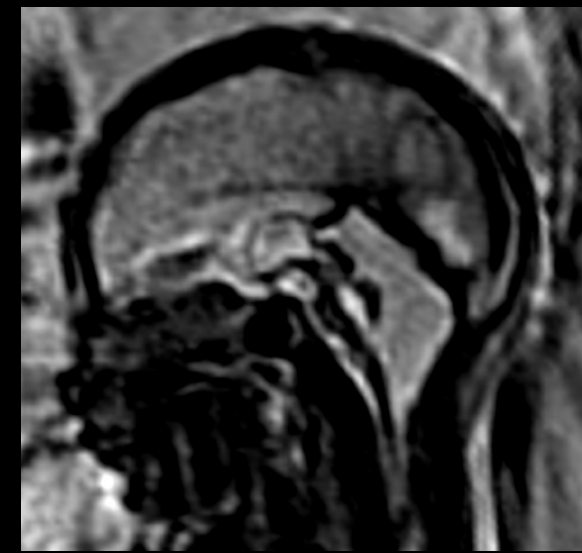
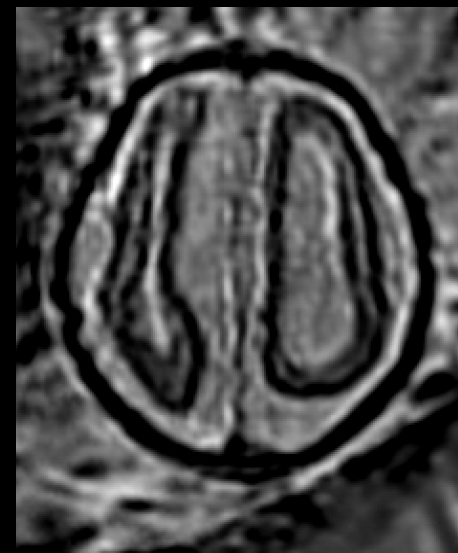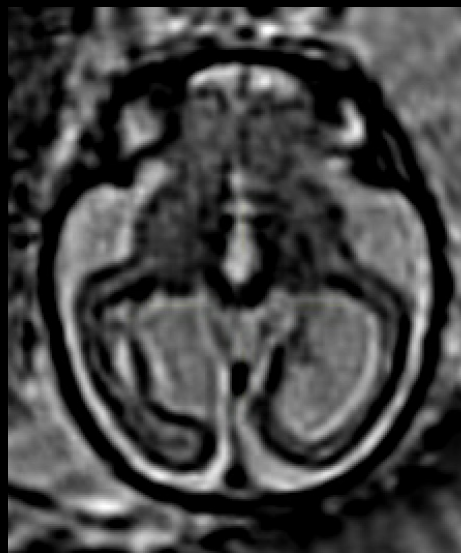Interhemispheric cyst

Early signs of polymicrogyria

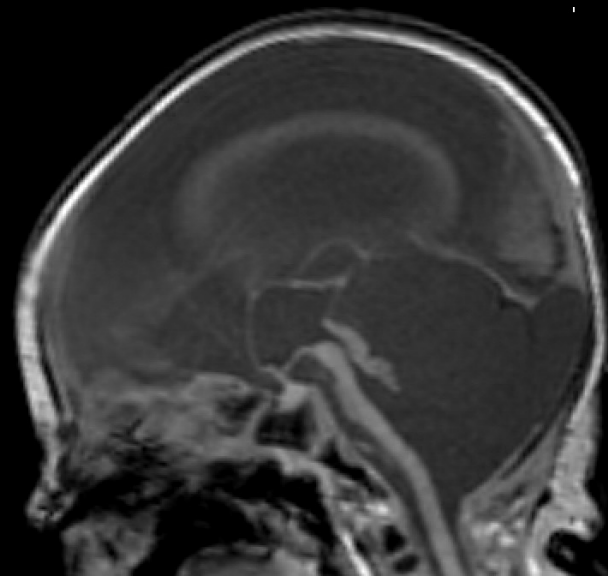
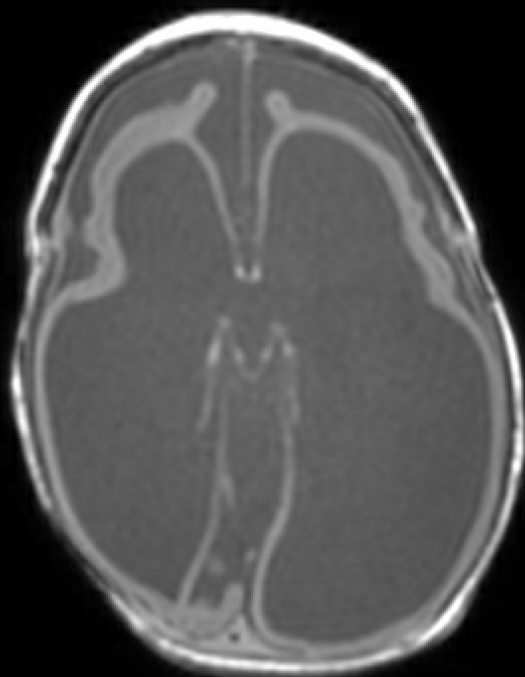
Fetal MRI(23w +6 d)



3D SRR



Neonatal MRI



- Lissencephaly
- Agensis CC
- Ventriculomegaly
- Pontocerebellar hypoplasia

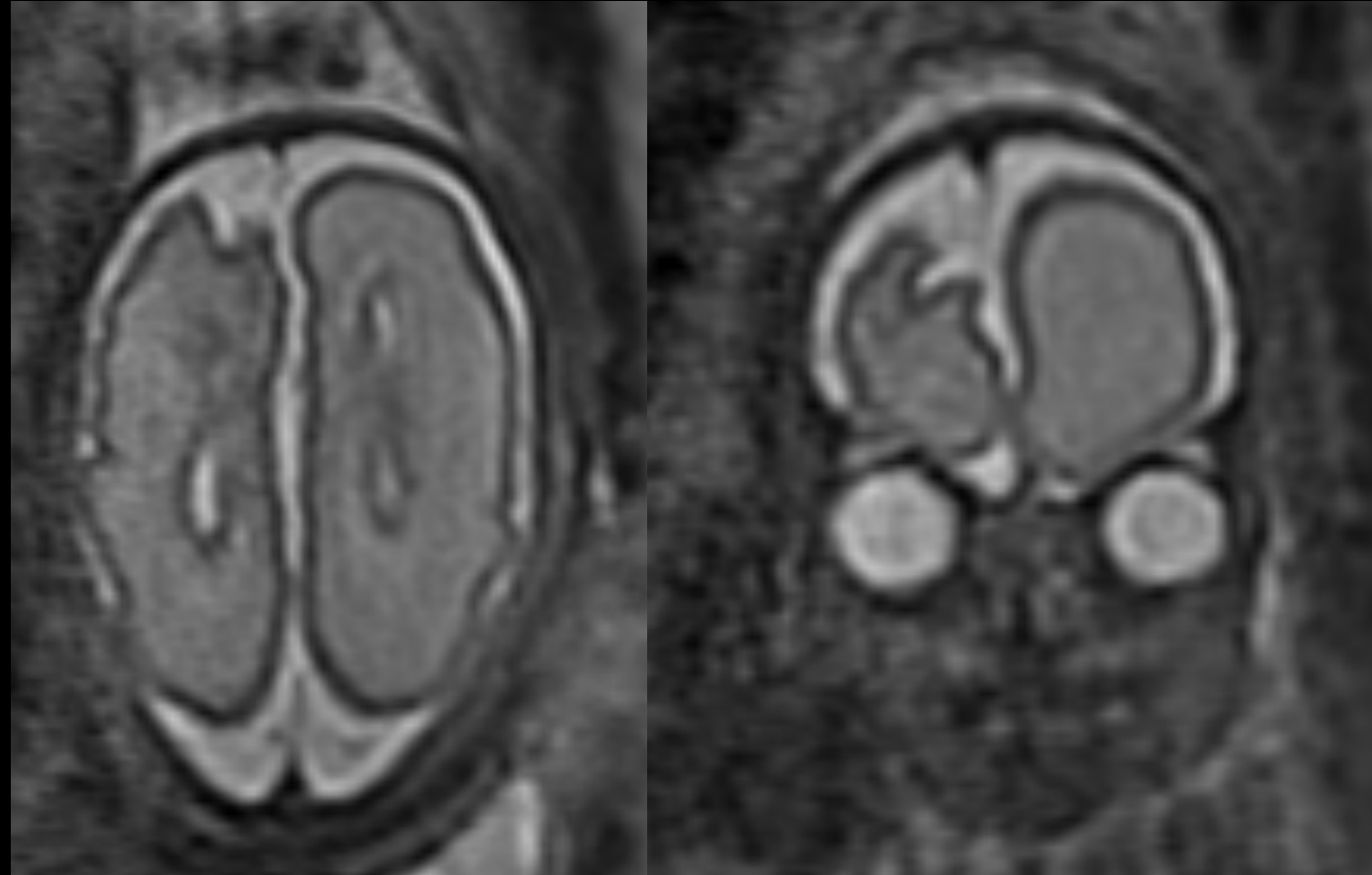
Clinical Indications: CNS

- Ventriculomegaly
- Agenesis/dysgenesis of the corpus callosum
- Absent Cavum septum pellucidum
- **Micro or Macrocephaly – cortical malformations**
- Intracranial haemorrhage
- Posterior fossa abnormalities
- Vein of Galen malformation
- Congenital infections
- Neural tube defects
- Orofacial abnormalities
- Complications of twin pregnancies (TTTS, TAPS)

Cortical anomalies

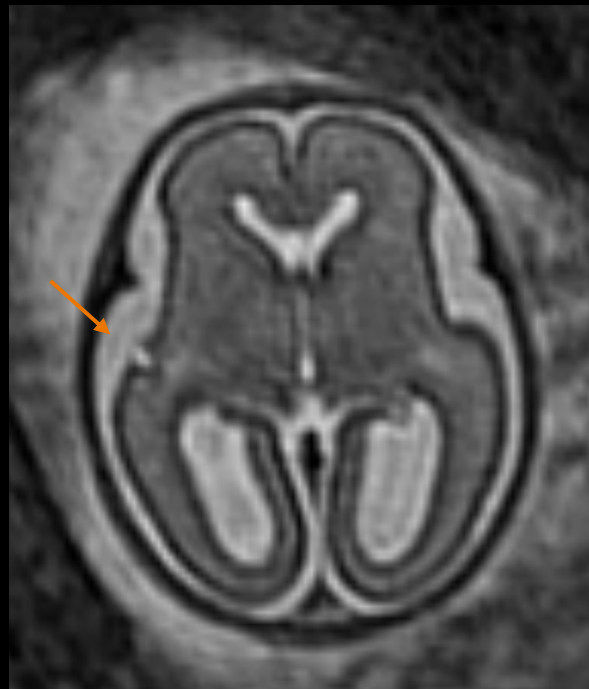
- Assess cortical maturation
- Early abnormal folding
- Delayed or absent folding

27w6d
Agenesis CC

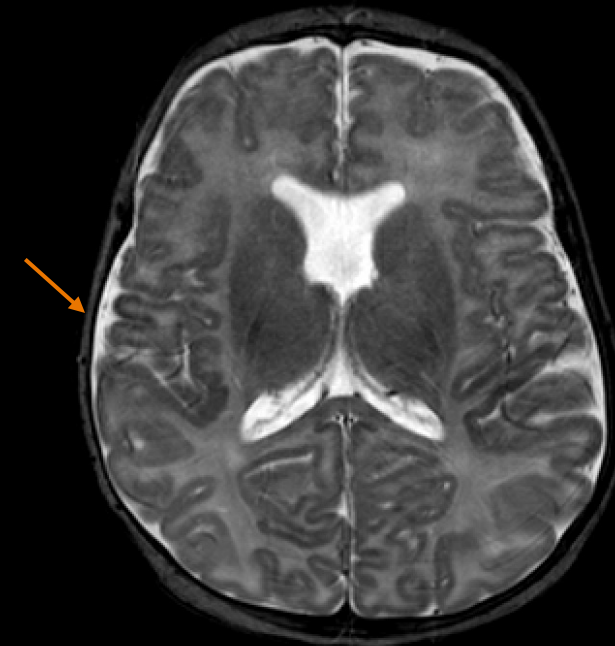
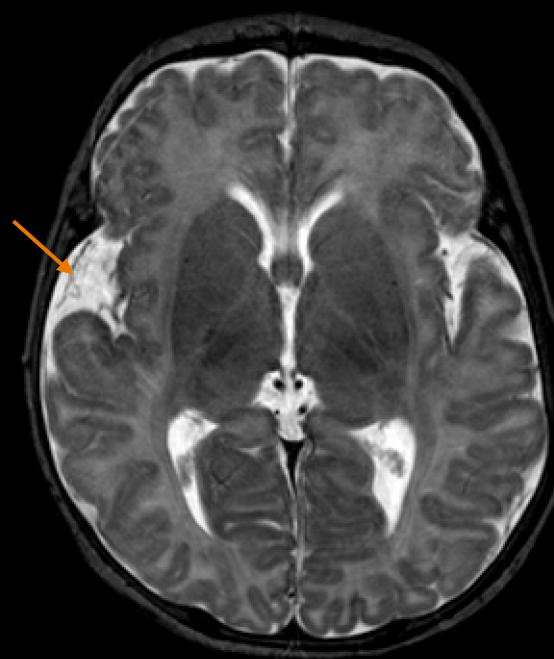
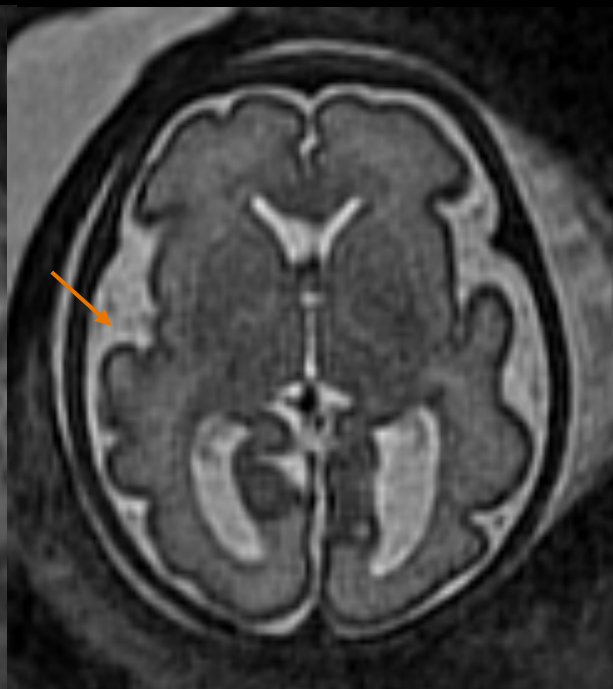


Absent CSP

23w2d



30w2d

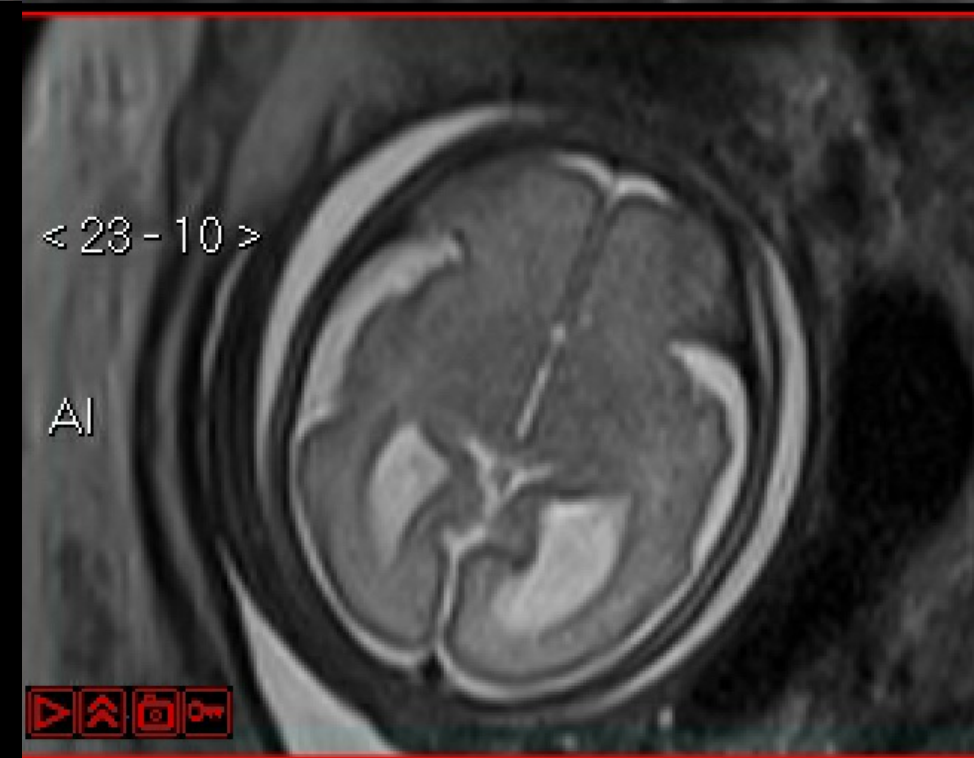
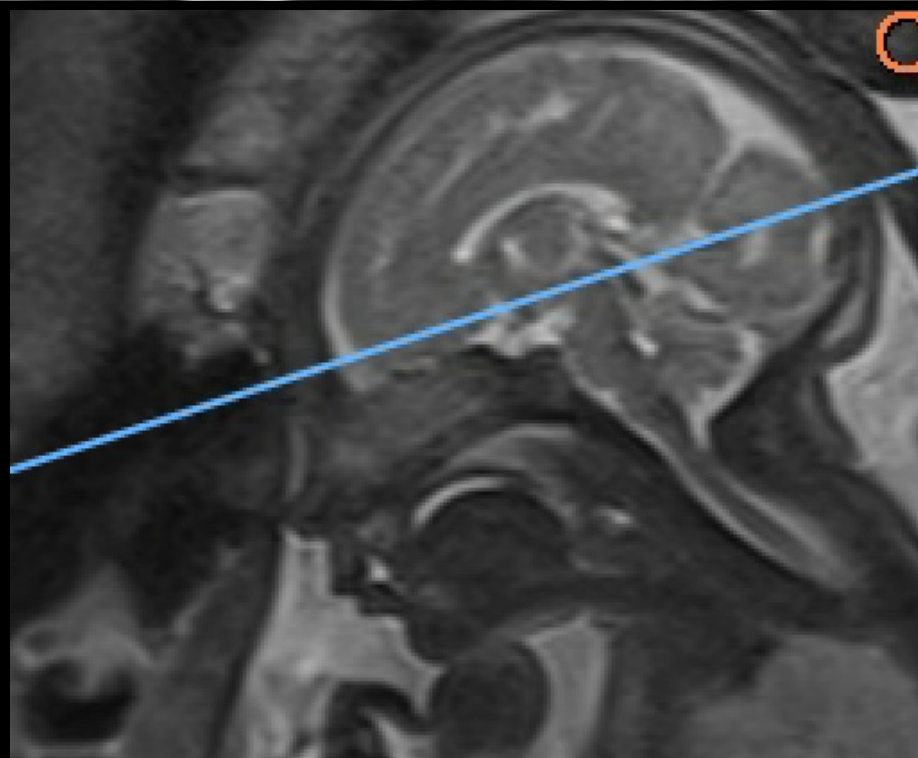
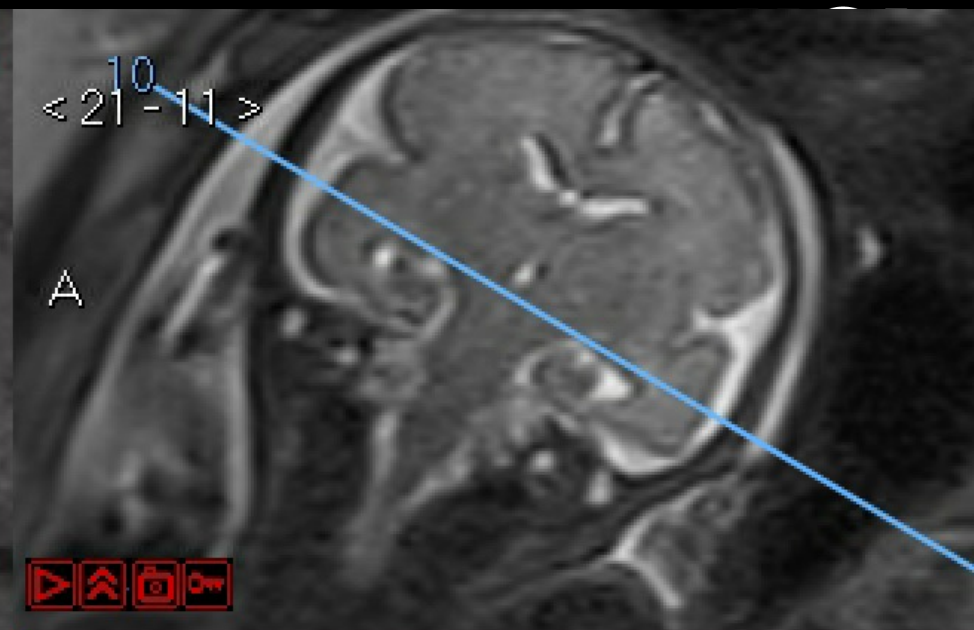
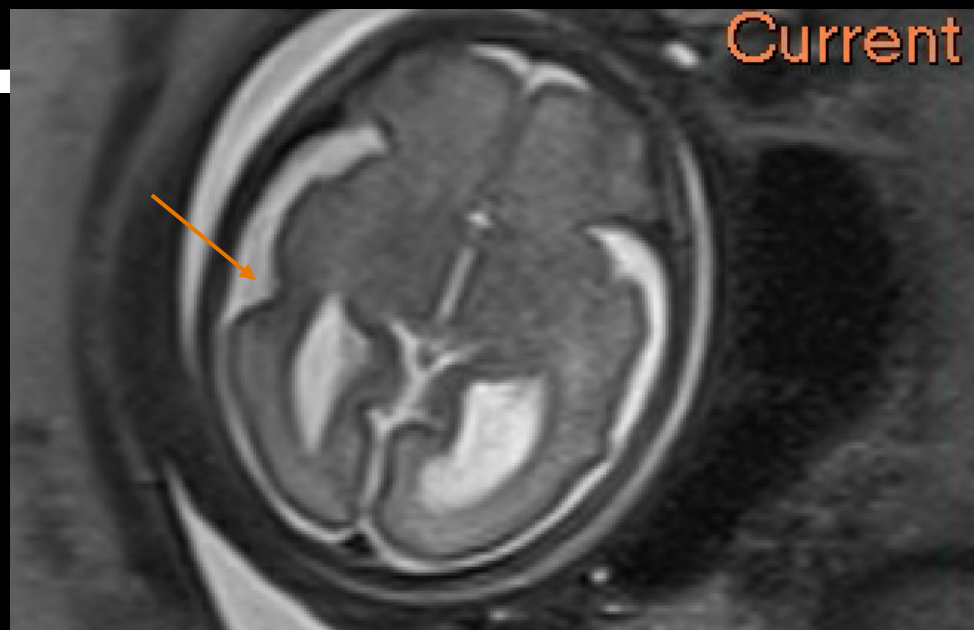


45w+3d

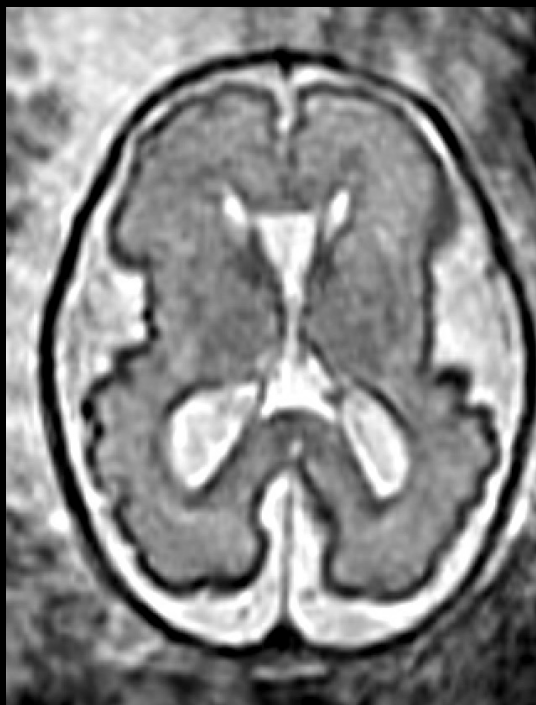Microcephaly and
ventriculomegaly

29w + 5d

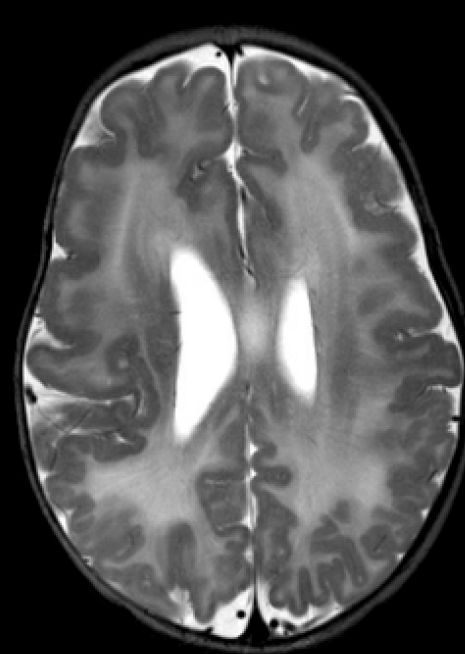
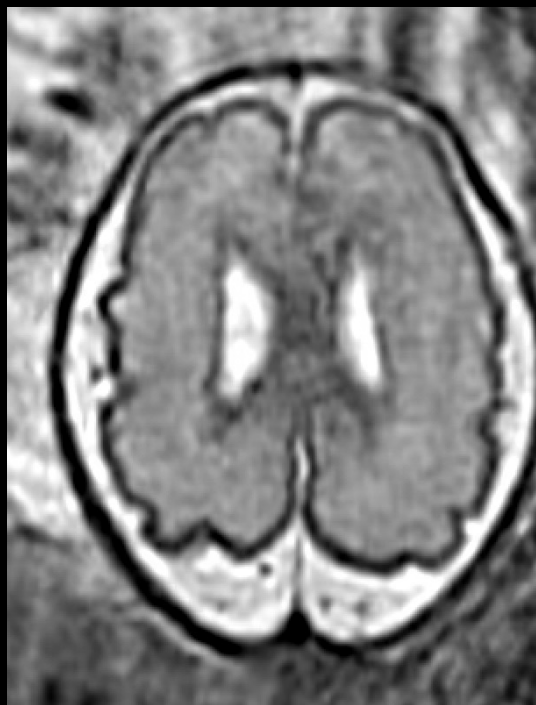
Early signs of
polymicrogyria



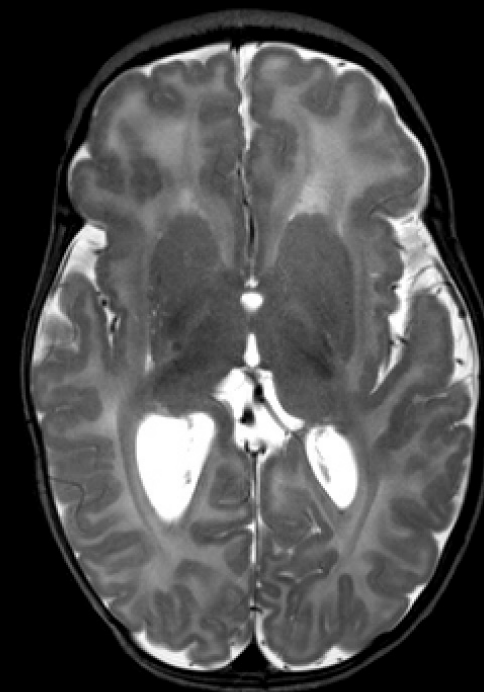
Macrocephaly + Cortical Malformation + Band Heterotopia



26w+2d GA



44w+2d CA



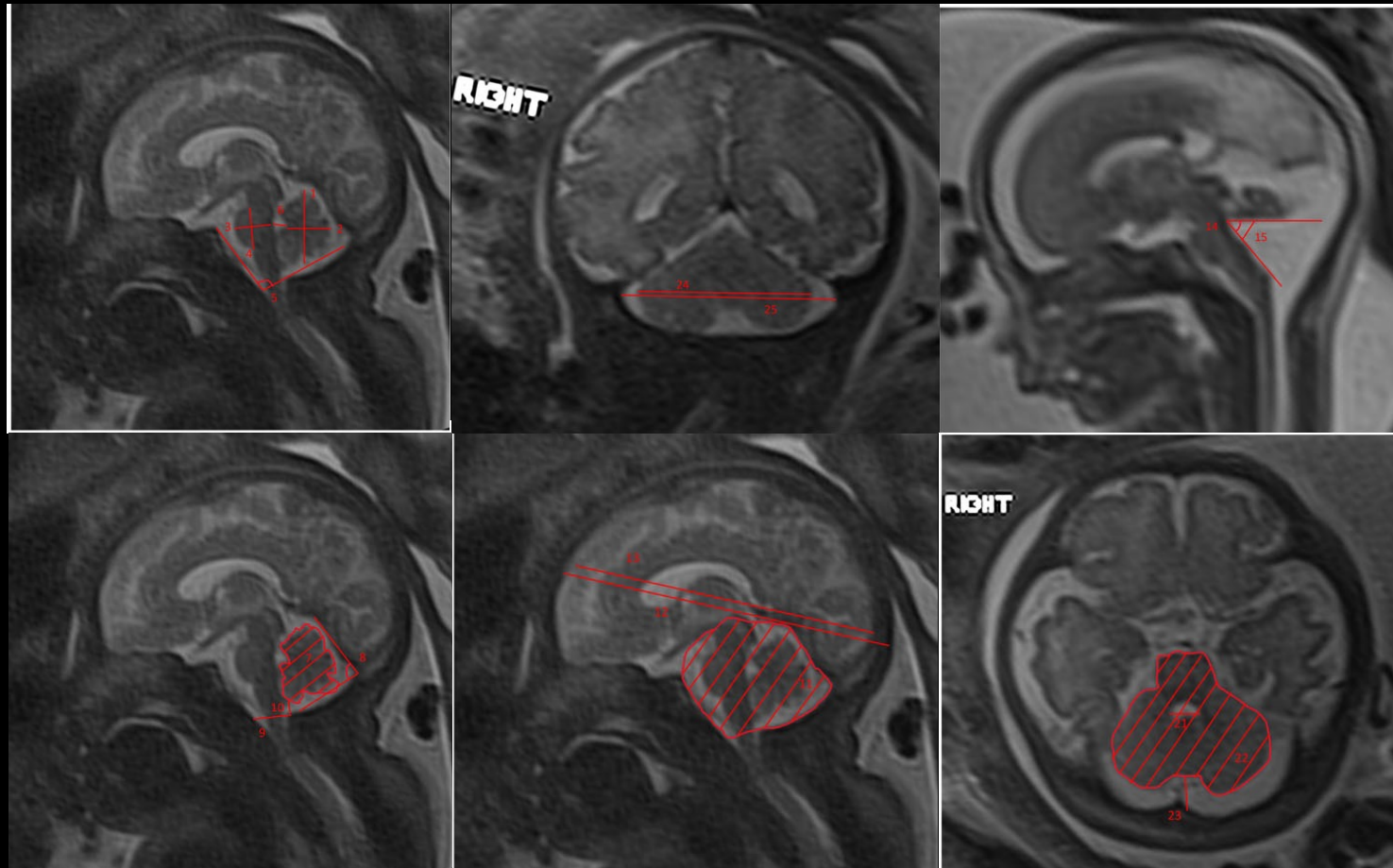
Clinical Indications: CNS

- Ventriculomegaly
- Agenesis/dysgenesis of the corpus callosum
- Absent Cavum septum pellucidum
- Micro or Macrocephaly – cortical malformations
- Intracranial haemorrhage
- **Posterior fossa abnormalities**
- Vein of Galen malformation
- Congenital infections
- Neural tube defects
- Orofacial abnormalities
- Complications of twin pregnancies (TTTS, TAPS)

Posterior fossa anomalies

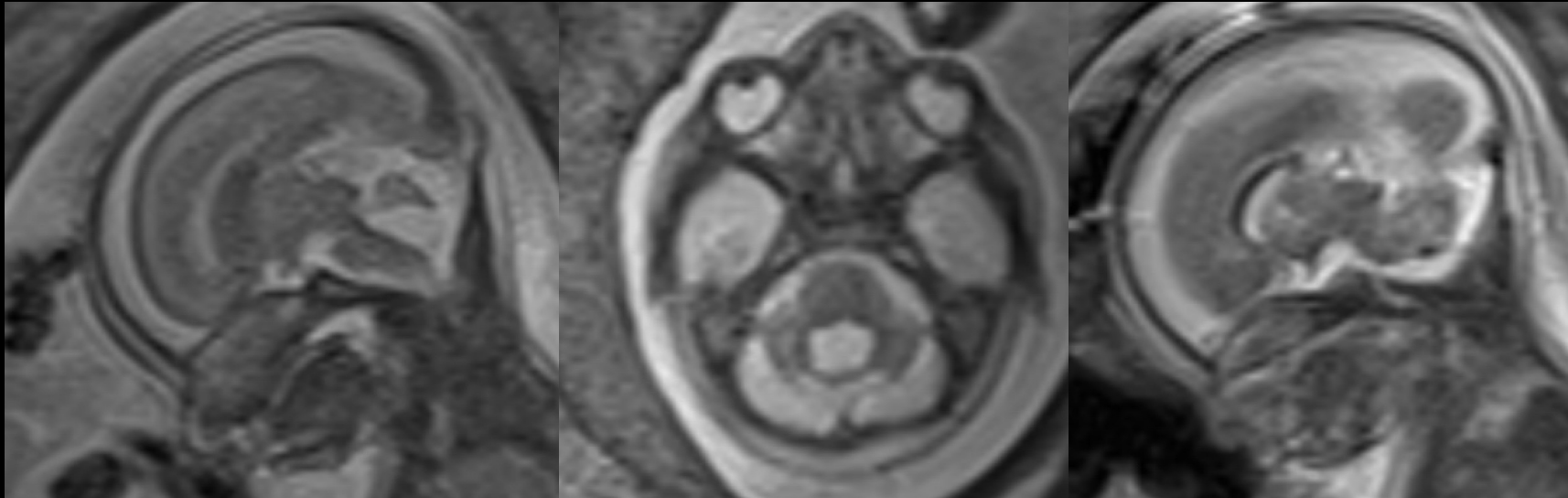
- Large cisterna magna
- Vermis hypoplasia +/- rotation
- Dandy-Walker malformation / Blake's pouch cyst
- Cerebellar hypoplasia
- Cerebellar haemorrhage
- Rhomboencephalosynapsis
- Brainstem abnormality
- SOL (arachnoid cyst, dural fistula)

Biometric assessment of the posterior fossa by fetal MRI



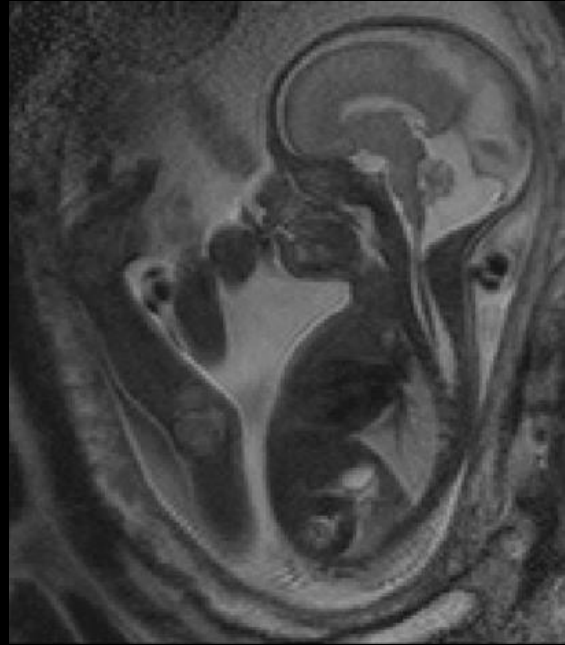
Vermis rotation 22w 1d

Inferior vermis hypoplasia and rotation, short CC, hypertelorism, prominent subcutaneous fat around the head



Micro-array: 8p inverted duplication/deletion syndrome.

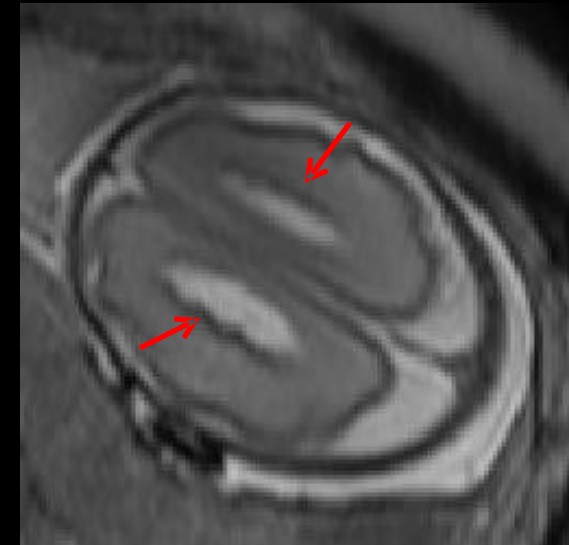
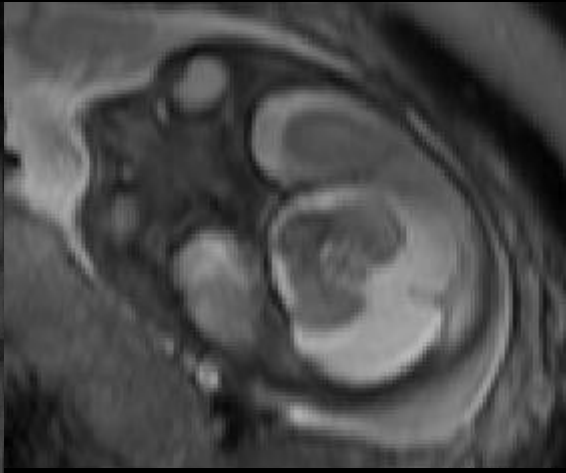
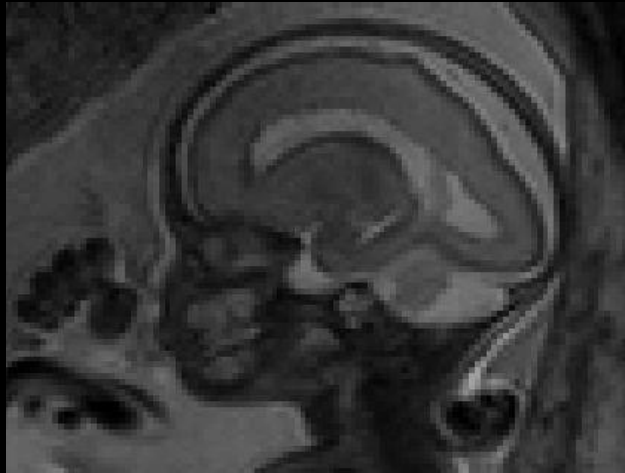
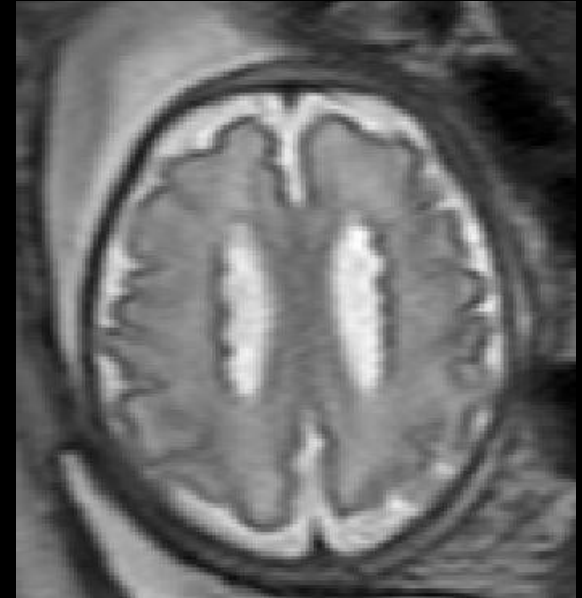
Expected to lead to an abnormal postnatal phenotype including learning disability, dysmorphism, and congenital malformations e.g. cardiac defect

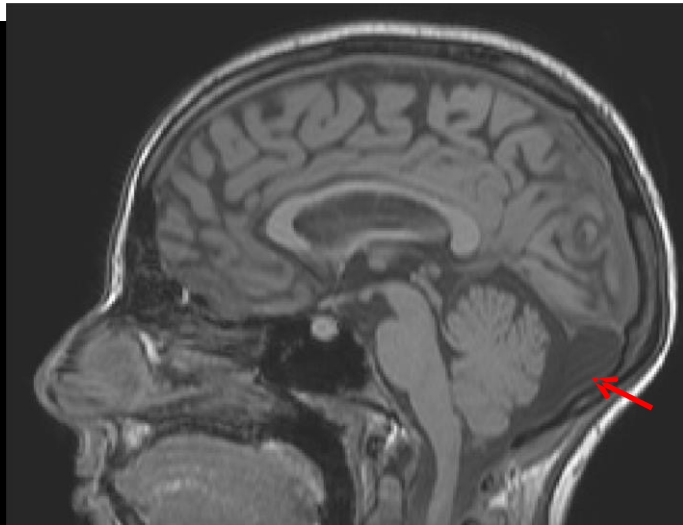


26w 3d

Large cisterna magna
Subependymal heterotopia

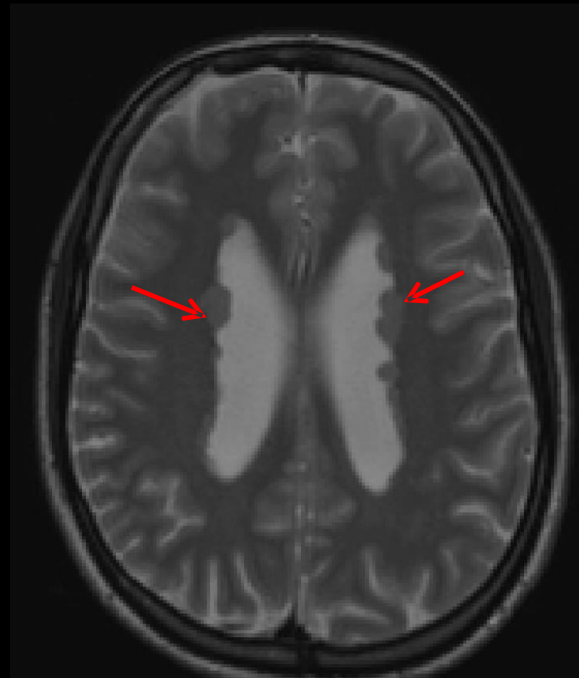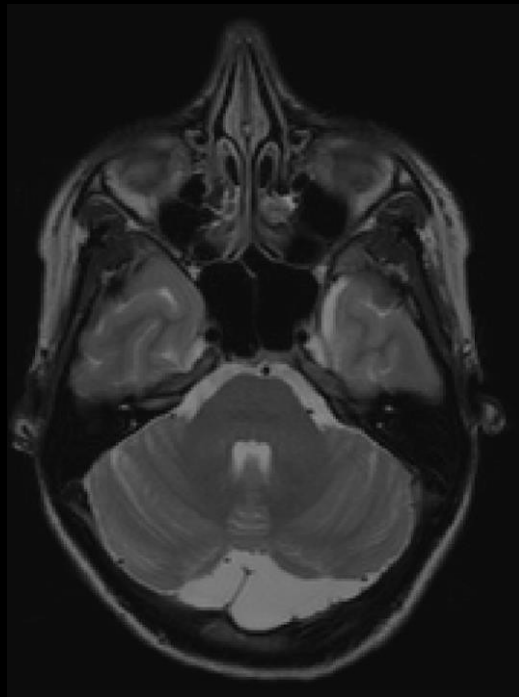
Female





Mother asymptomatic
Maternal grandmother
epileptic

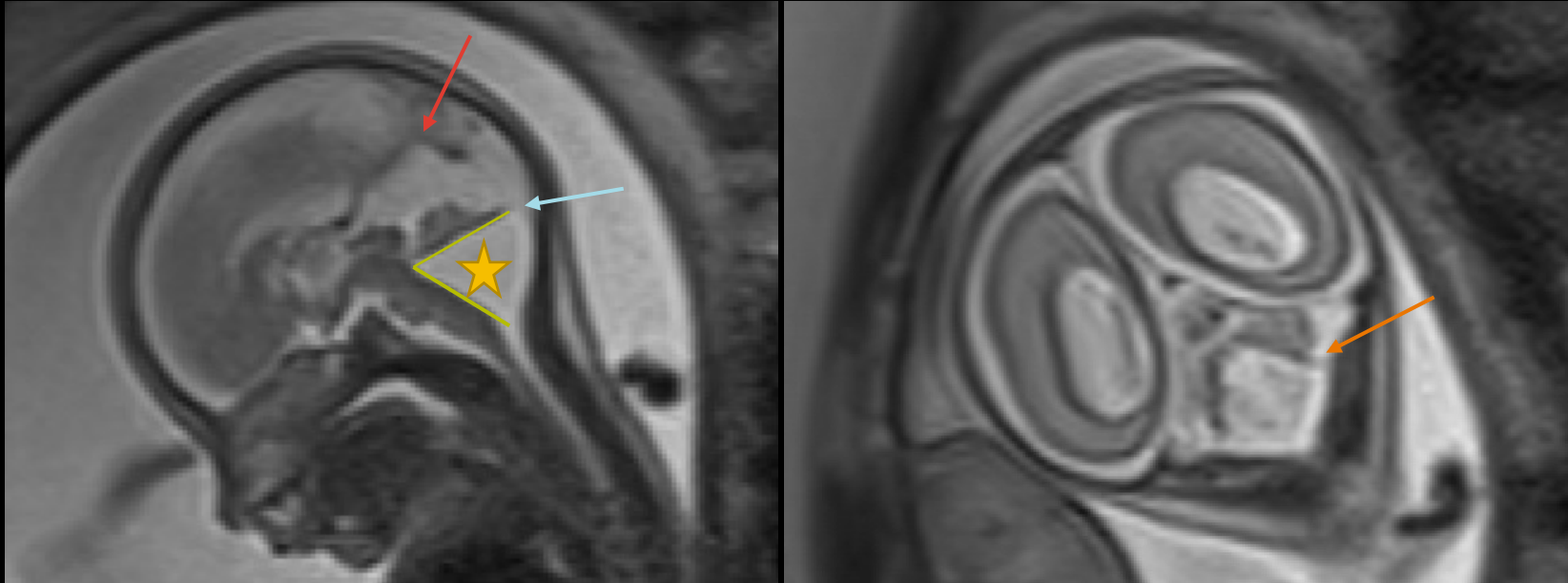
Mother's images



X linked
subependymal
heterotopia with
enlarged cisterna
magna

Filamin A mutation

23w



Dandy Walker Malformation

Large posterior fossa with elevation of the tentorium (**red arrow**)

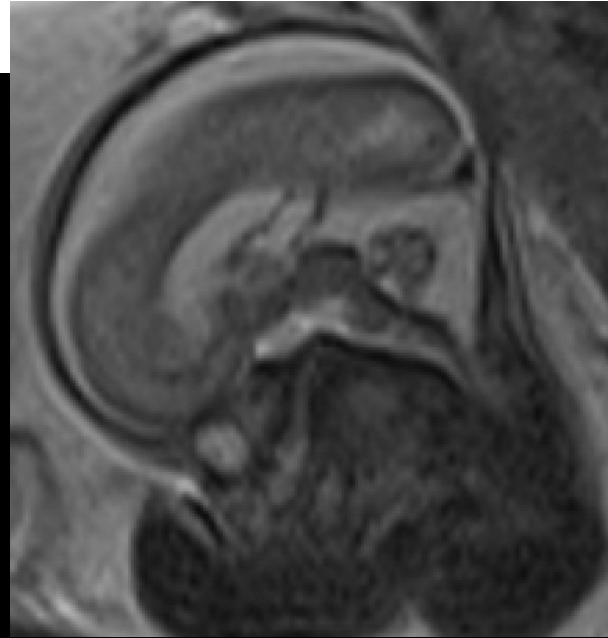
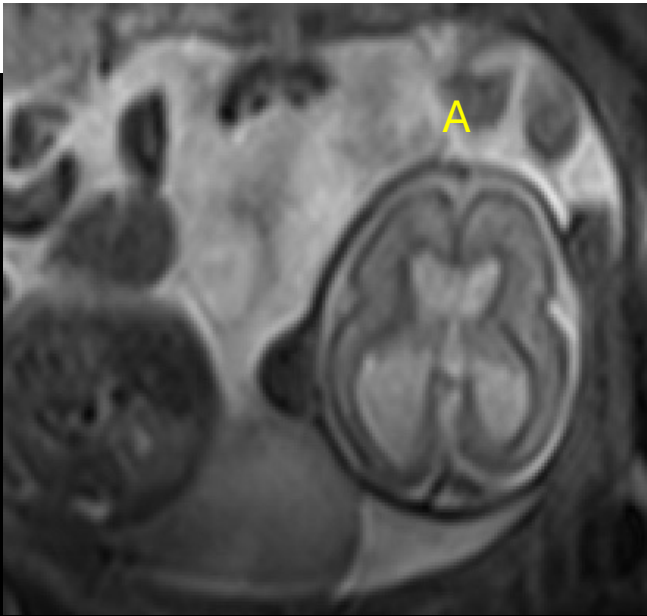
Cystic dilatation of 4th ventricle communicating with the cisterna magna ★

Vermis hypoplasia, rotation, obtuse fastigial angle, unpaired caudal lobe - "tail sign" (**blue arrow**)

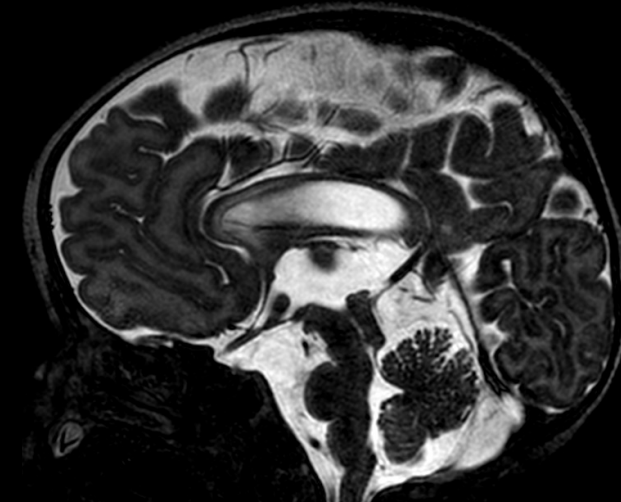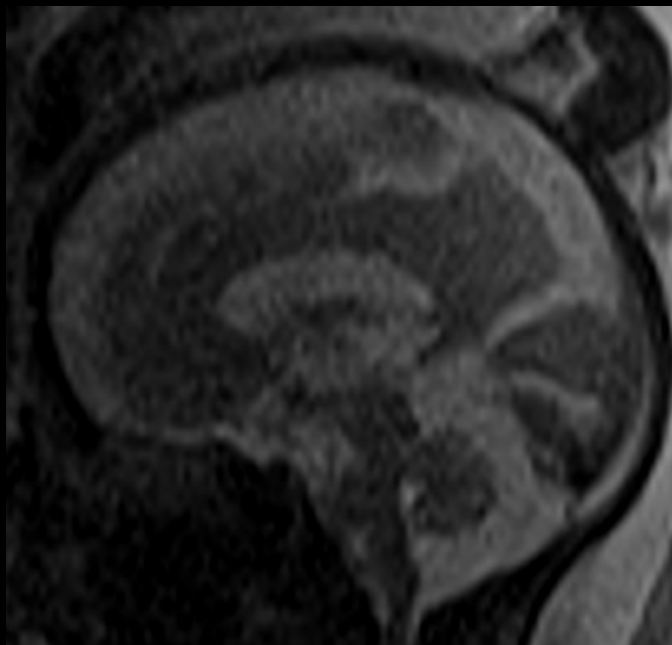
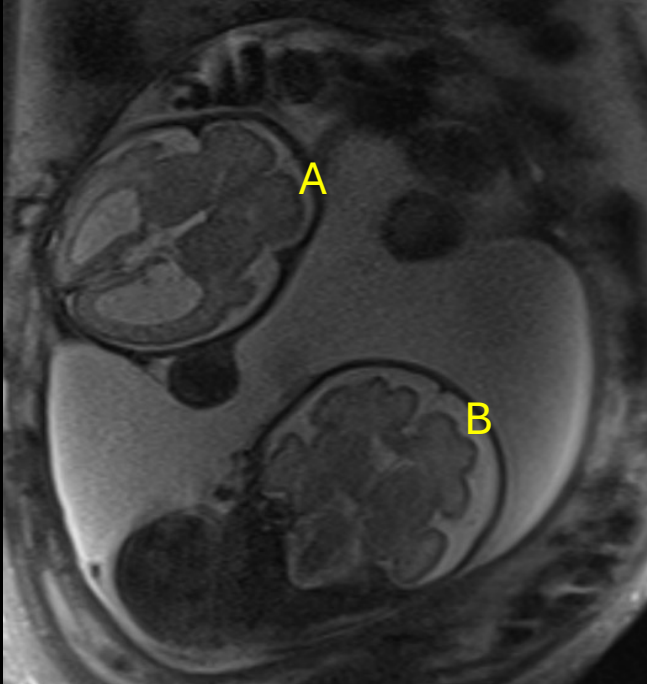
Increased tegmento-vermian angle (**green lines**)

Inferolateral displacement of the taenia–tela choroidea complex (**orange arrow**)

23 w

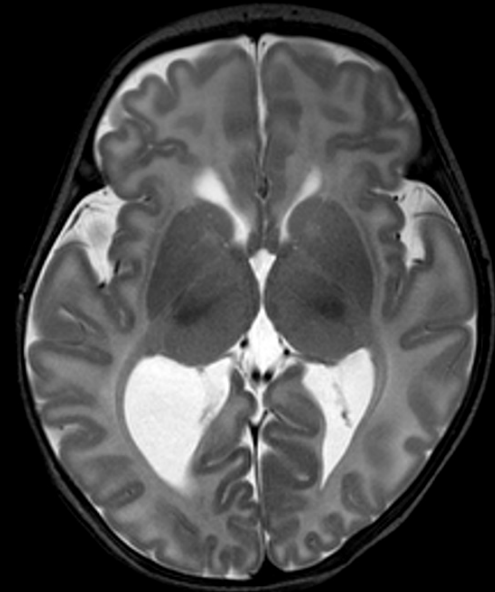


29 w



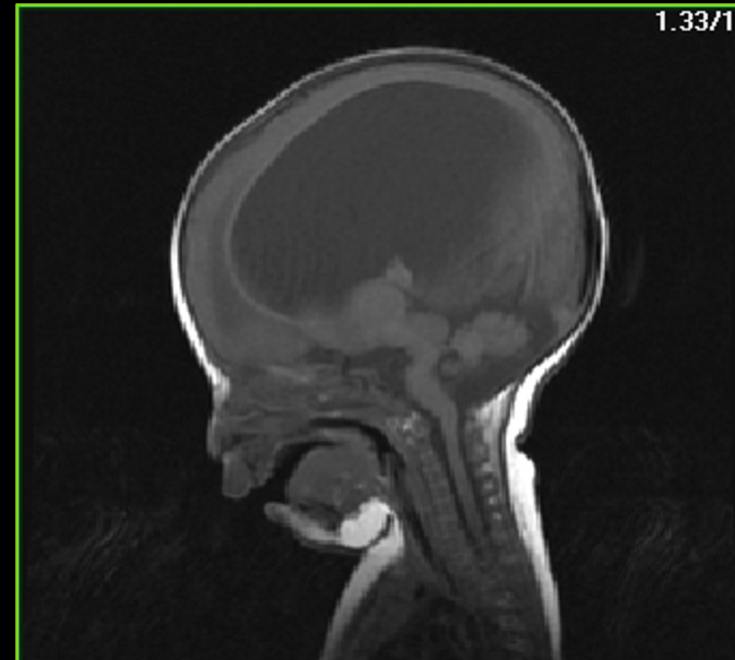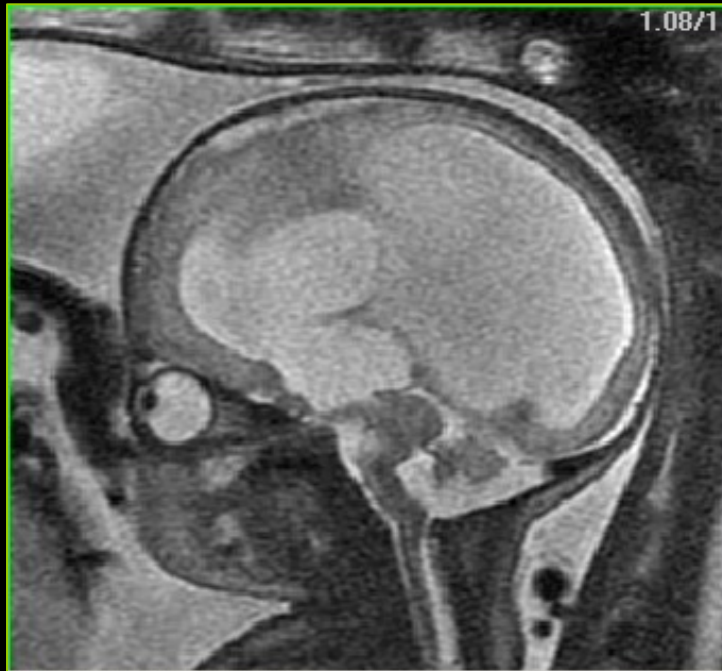Neonatal MRI

42w+5d



Walker-Warburg Syndrome

Age of 1 week



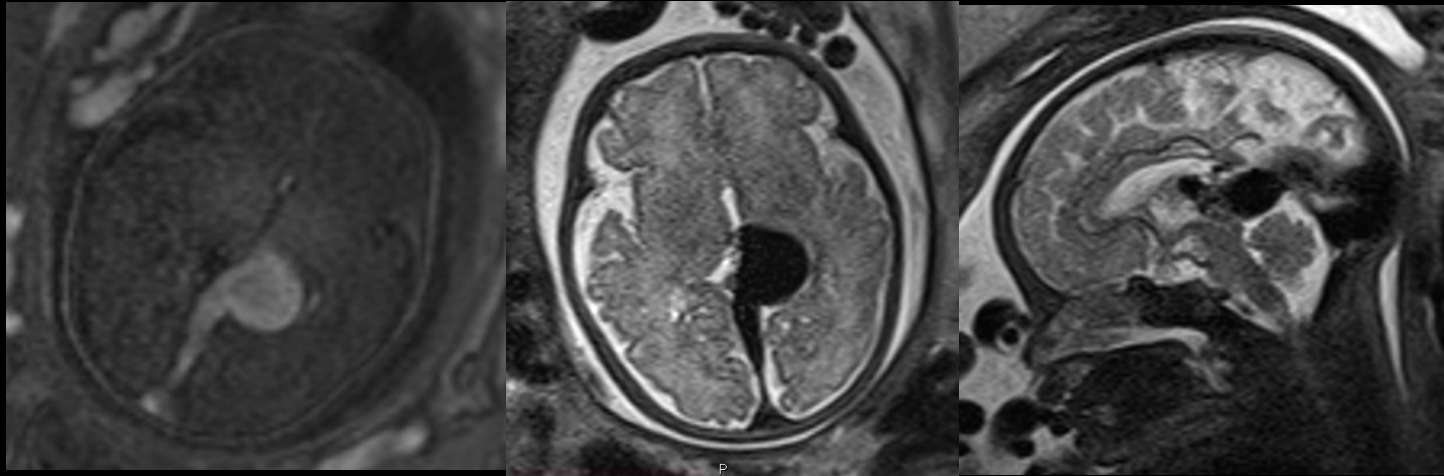
Cobblestone lissencephaly,
hydrocephalus
Z shaped brainstem

Clinical Indications: CNS

- Ventriculomegaly
- Agenesis/dysgenesis of the corpus callosum
- Absent Cavum septum pellucidum
- Micro or Macrocephaly – cortical malformations
- Intracranial haemorrhage
- Posterior fossa abnormalities
- **Vein of Galen malformation**
- Congenital infections
- Neural tube defects
- Orofacial abnormalities
- Complications of twin pregnancies (TTTS, TAPS)

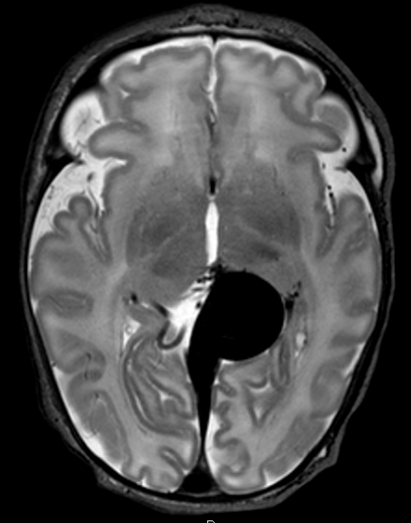
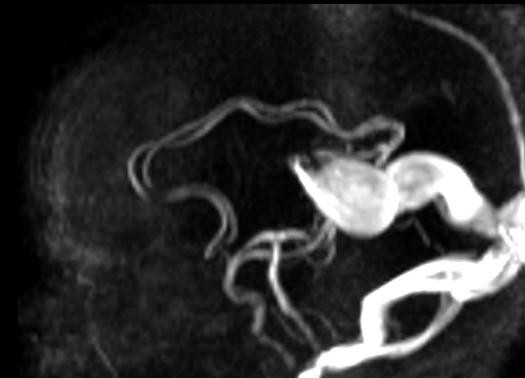
Vein of Galen Aneurysmal Malformation

Median Prosencephalic A/V fistula



36w + 6d

Post natal MRI 37w +4d

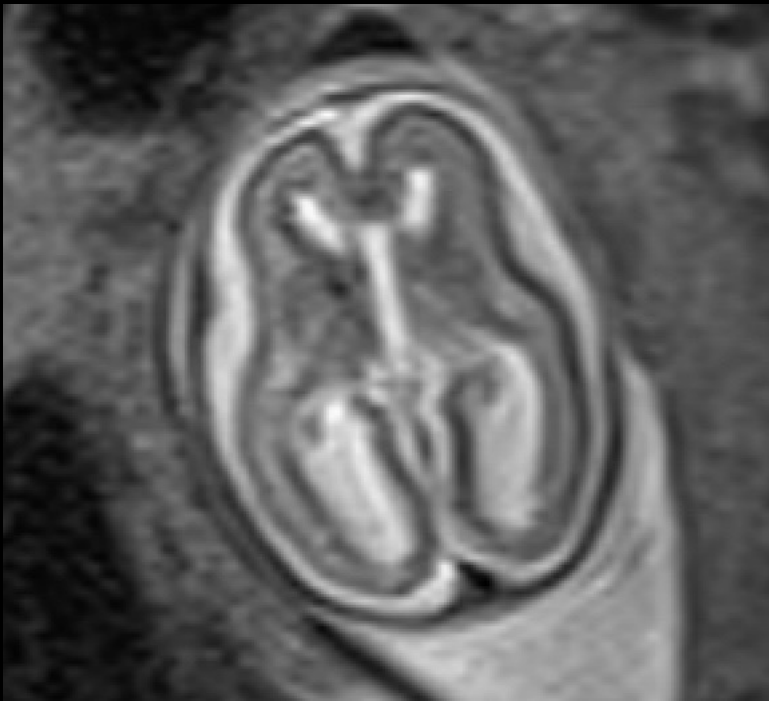

Clinical Indications: CNS

- Ventriculomegaly
- Agenesis/dysgenesis of the corpus callosum
- Absent Cavum septum pellucidum
- Micro or Macrocephaly – cortical malformations
- Intracranial haemorrhage
- Posterior fossa abnormalities
- Vein of Galen malformation
- Congenital infections
- Neural tube defects
- Orofacial abnormalities
- Complications of twin pregnancies (TTTS, TAPS)

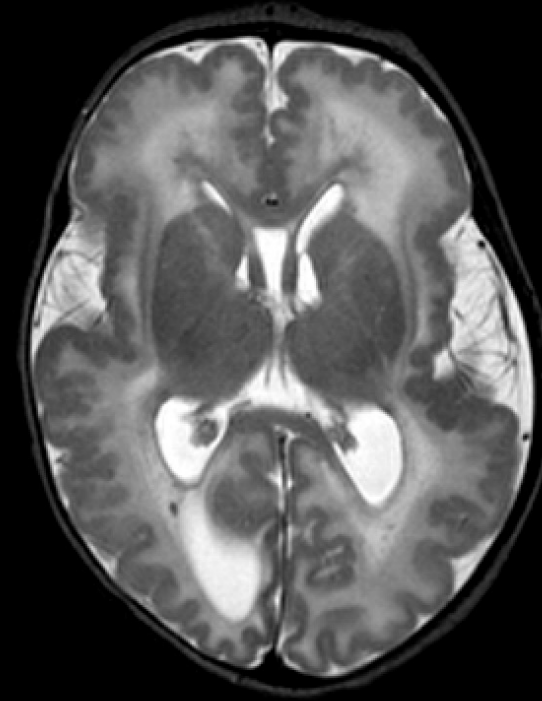
CMV+ amniocentesis
Valganciclovir during pregnancy
Fetal cardiomegaly, ascites, growth restriction

23w+4d



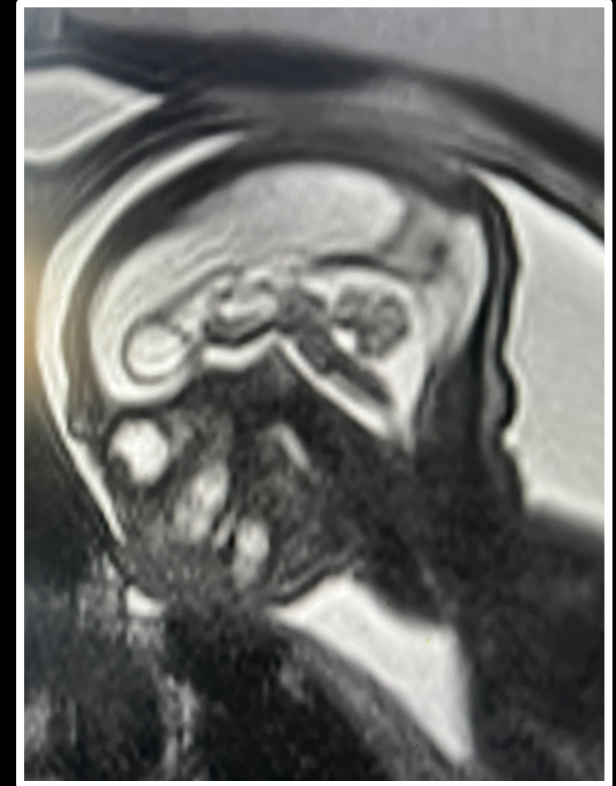
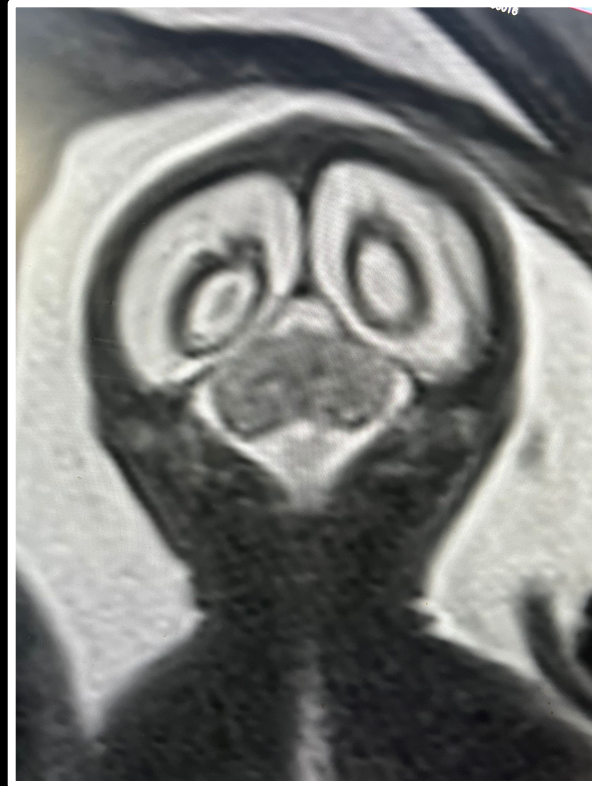
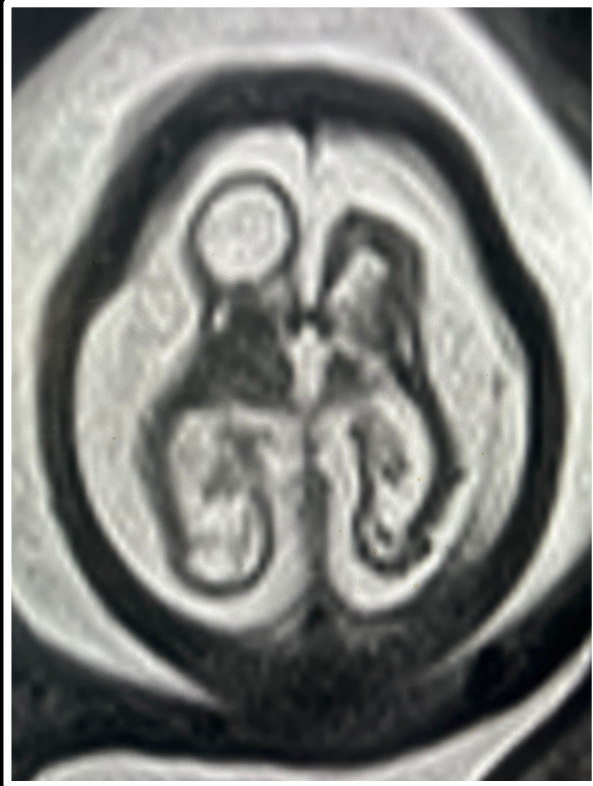
Microcephaly

42w+3d



Polymicrogyria, band heterotopia, subependymal cysts

Dengue at 5 weeks of pregnancy



Congenital Dengue Infection

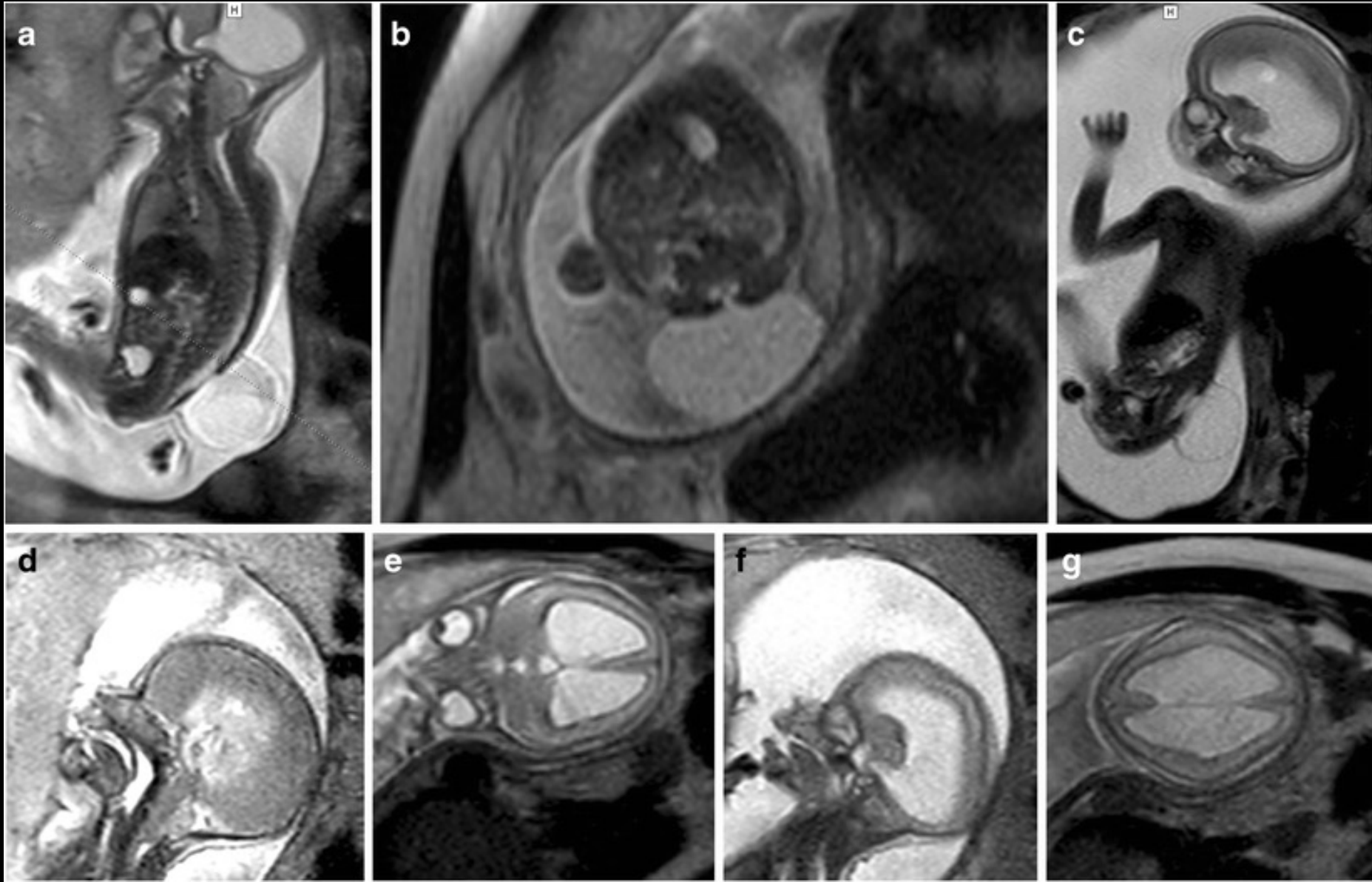
Clinical Indications: CNS

- Ventriculomegaly
- Agenesis/dysgenesis of the corpus callosum
- Absent Cavum septum pellucidum
- Micro or Macrocephaly – cortical malformations
- Intracranial haemorrhage
- Posterior fossa abnormalities
- Vein of Galen malformation
- Congenital infections
- Neural tube defects
- Orofacial abnormalities
- Complications of twin pregnancies (TTTS, TAPS)

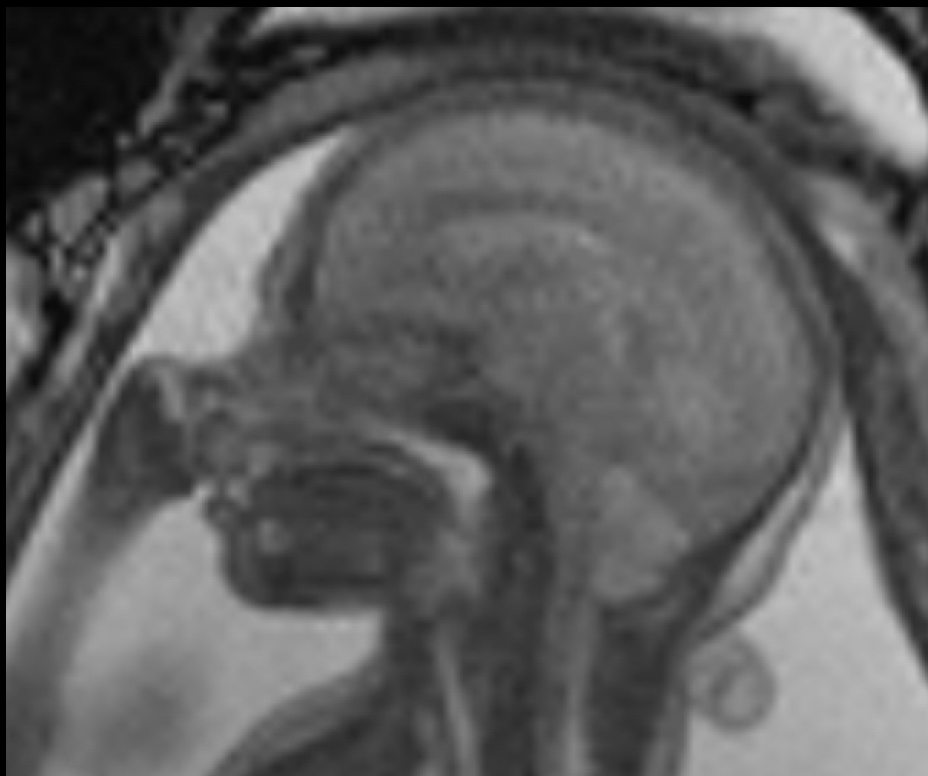
Neural tube defects

- Myelomeningocele / Myeloschisis
- Significant morbidity
- Neonatal surgical repair - 80% VP shunt - lifelong supportive care
- **Fetal surgery:**
 - Reduce hindbrain herniation and improve outcome
 - Higher risk of preterm birth and premature rupture of membranes

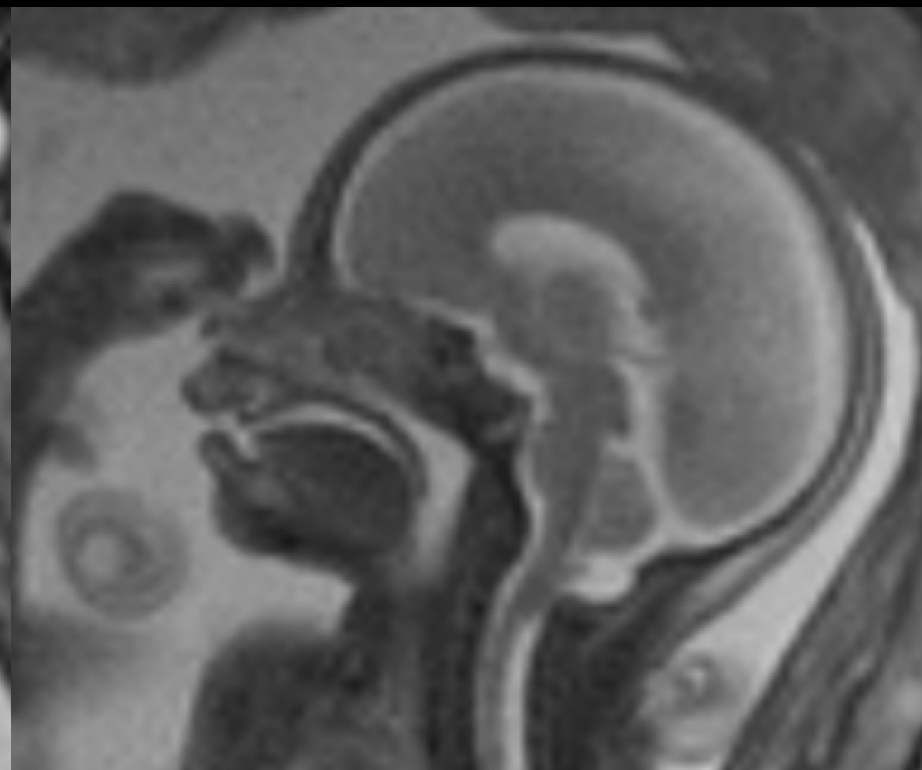
Arnold-Chiari II



Spina Bifida pre / post op

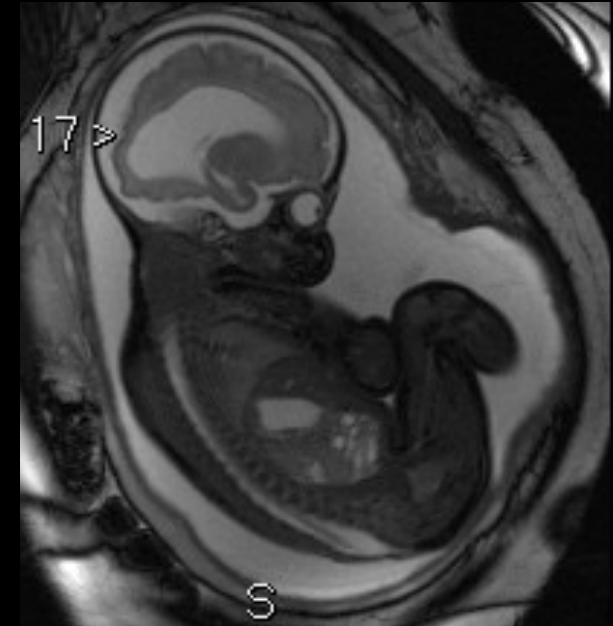
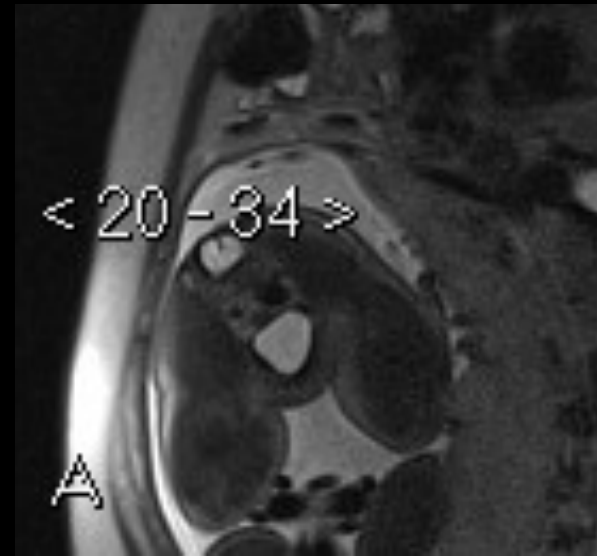
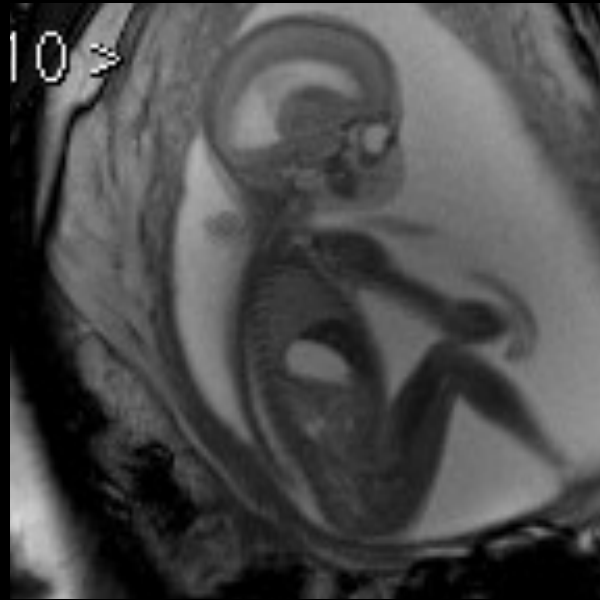
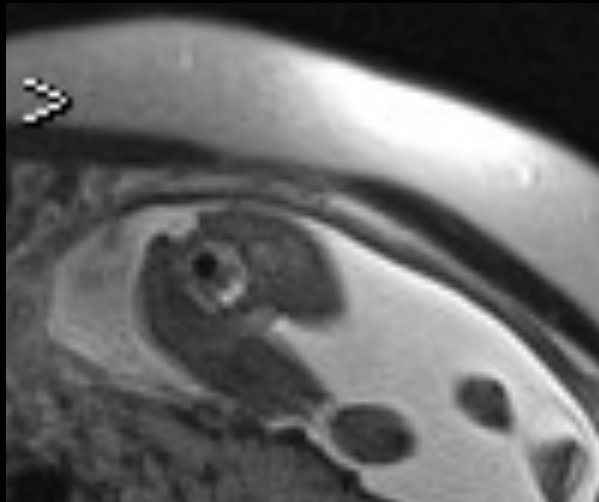


23w + 2d pre-op

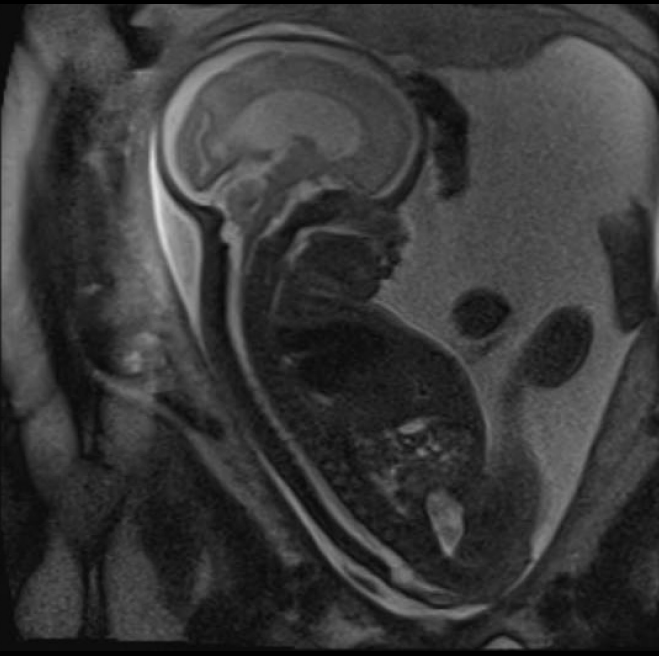
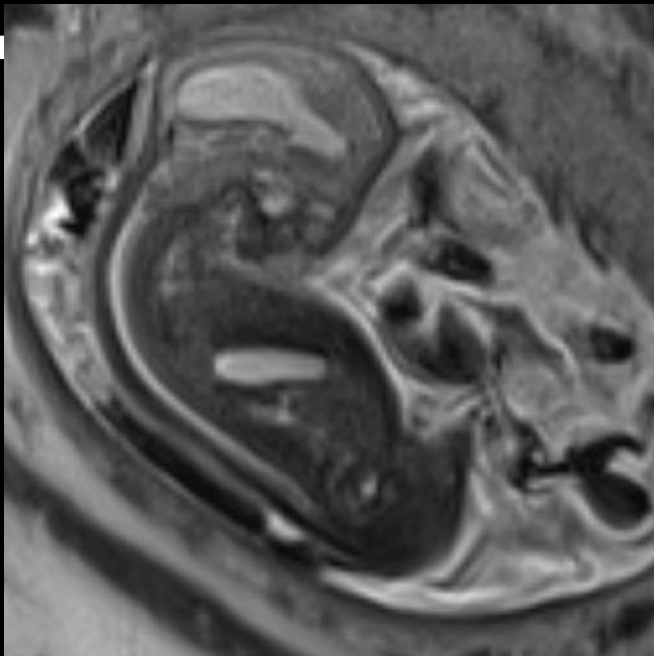


25w + 2d post fetal surgery
Reversal of the hindbrain herniation

Spina Bifida pre / post op

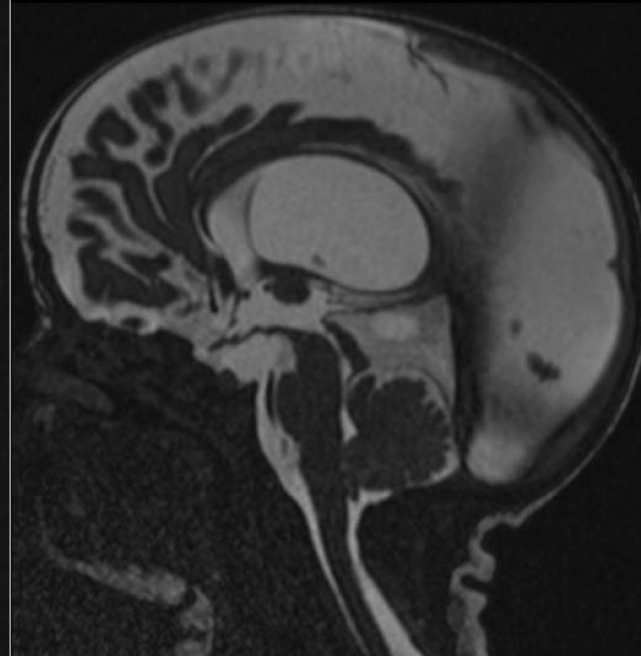
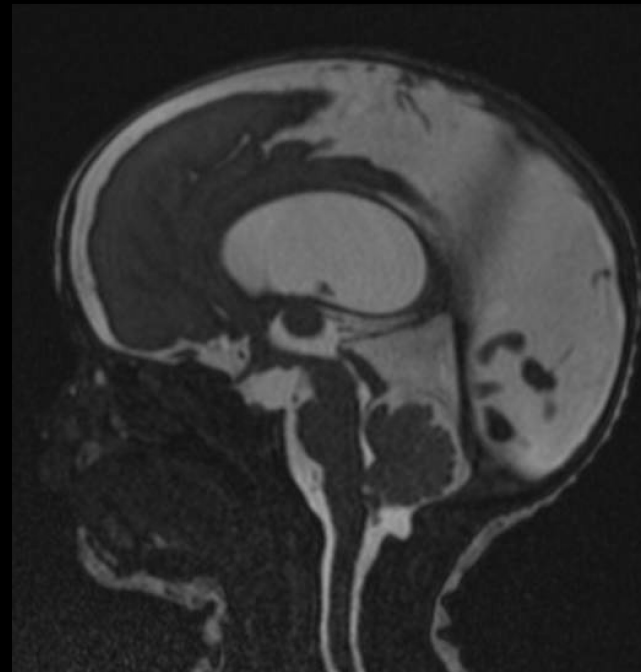


T2 HASTE



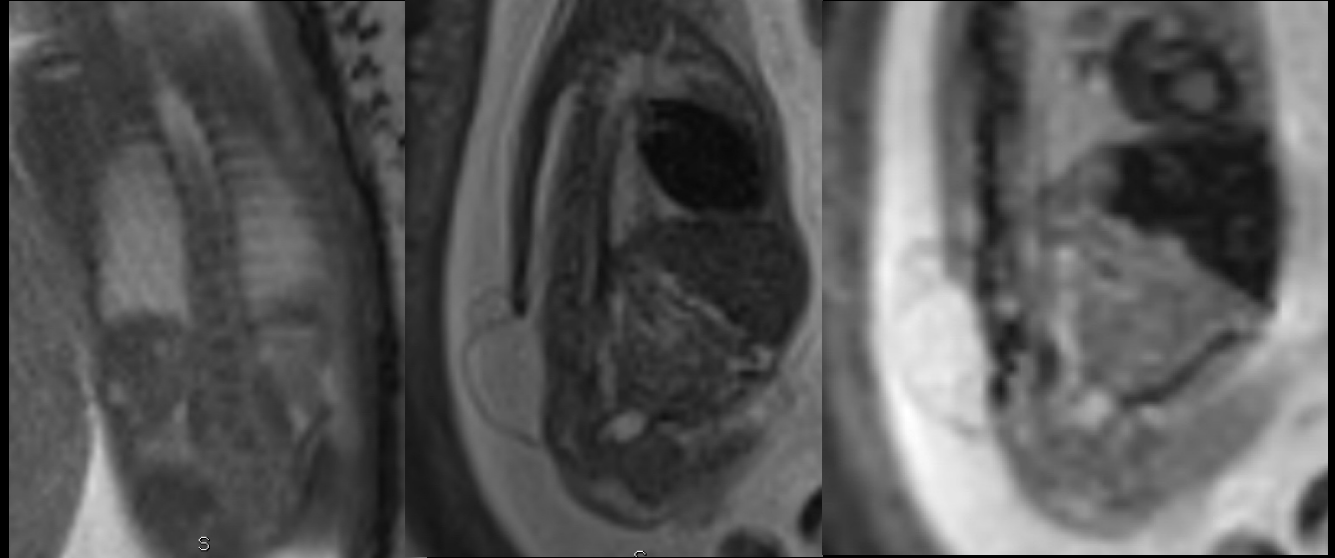
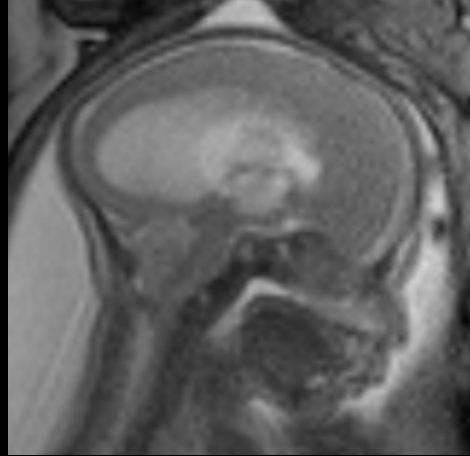
Pre- and Post-
Fetoscopic
Spina Bifida
Surgery

Neonatal
MRI

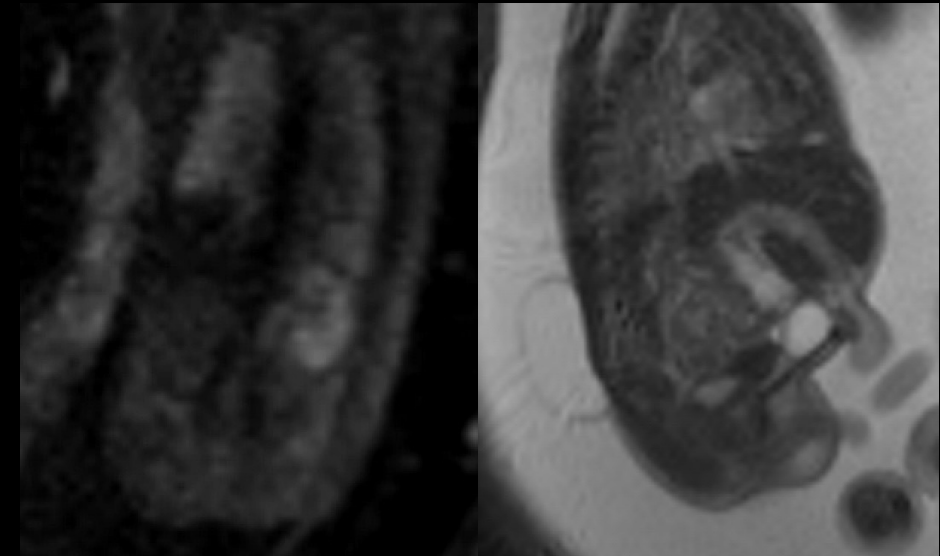


Courtesy of Dr Ata Siddiqui
Guy's & St Thomas' Hospital, London

Chiari II + scoliosis



Segmentation abnormality thoracic and lumbar spine
Short sacrum
Solitary left kidney
Urachal remnant
Possible VACTERL
Not suitable for fetal surgery



VACTERL Association

Vertebral anomalies

Anorectal anomalies

Cardiac anomalies / **C**left lip

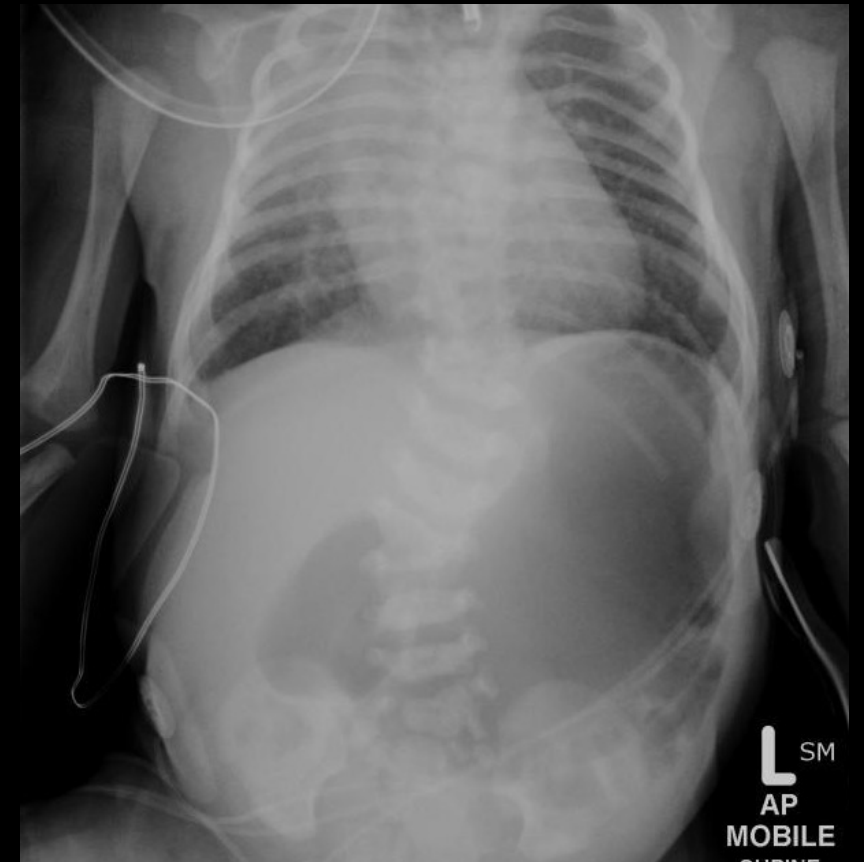
Tracheo **E**sophageal fistula +/-

Esophageal atresia

Renal anomalies / **R**adial ray anomalies

Limb anomalies – poly / oligodactyly

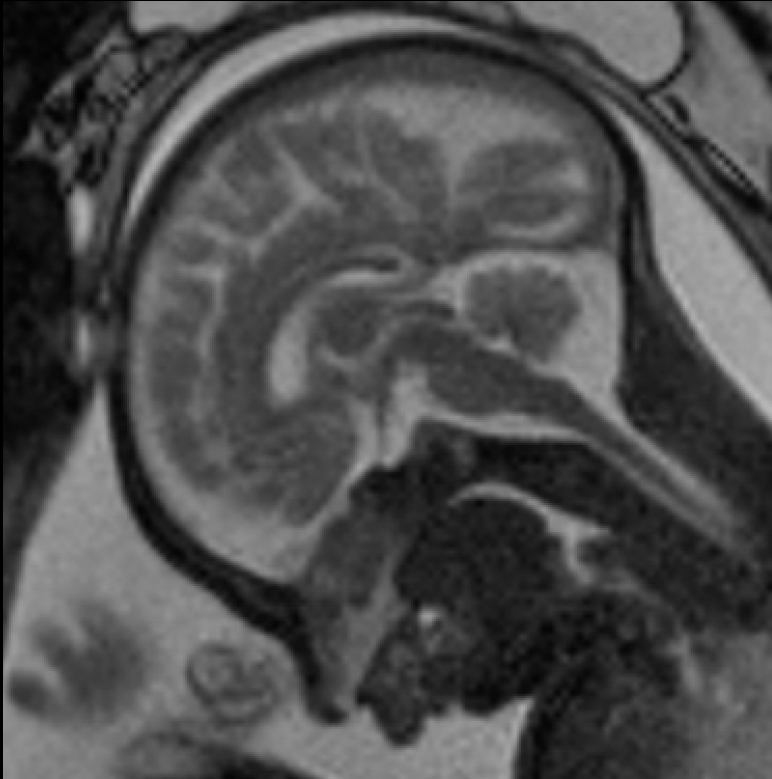
- At least 3



Clinical Indications: CNS

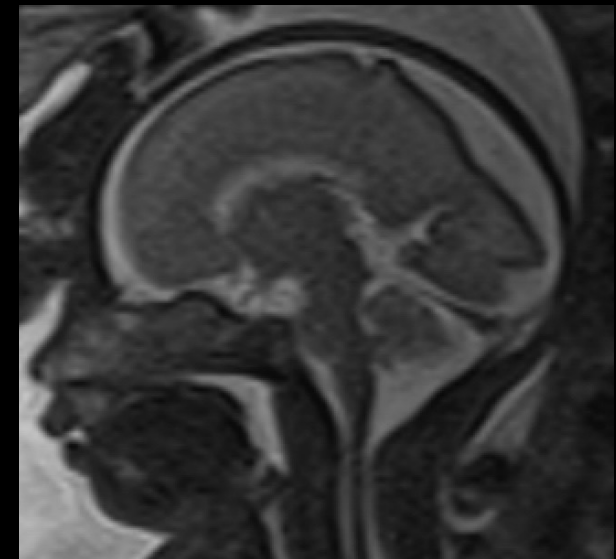
- Ventriculomegaly
- Agenesis/dysgenesis of the corpus callosum
- Absent Cavum septum pellucidum
- Micro or Macrocephaly – cortical malformations
- Intracranial haemorrhage
- Posterior fossa abnormalities
- Vein of Galen malformation
- Congenital infections
- Neural tube defects
- **Orofacial abnormalities**
- Complications of twin pregnancies (TTTS, TAPS)

Pierre Robin Sequence

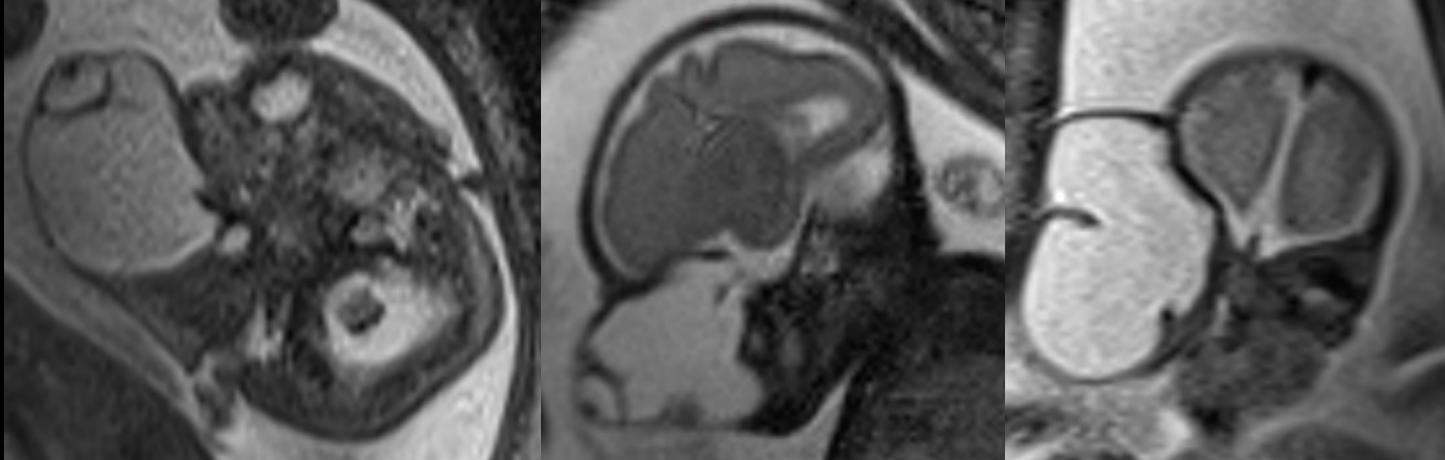


Micrognathia and
complete cleft palate

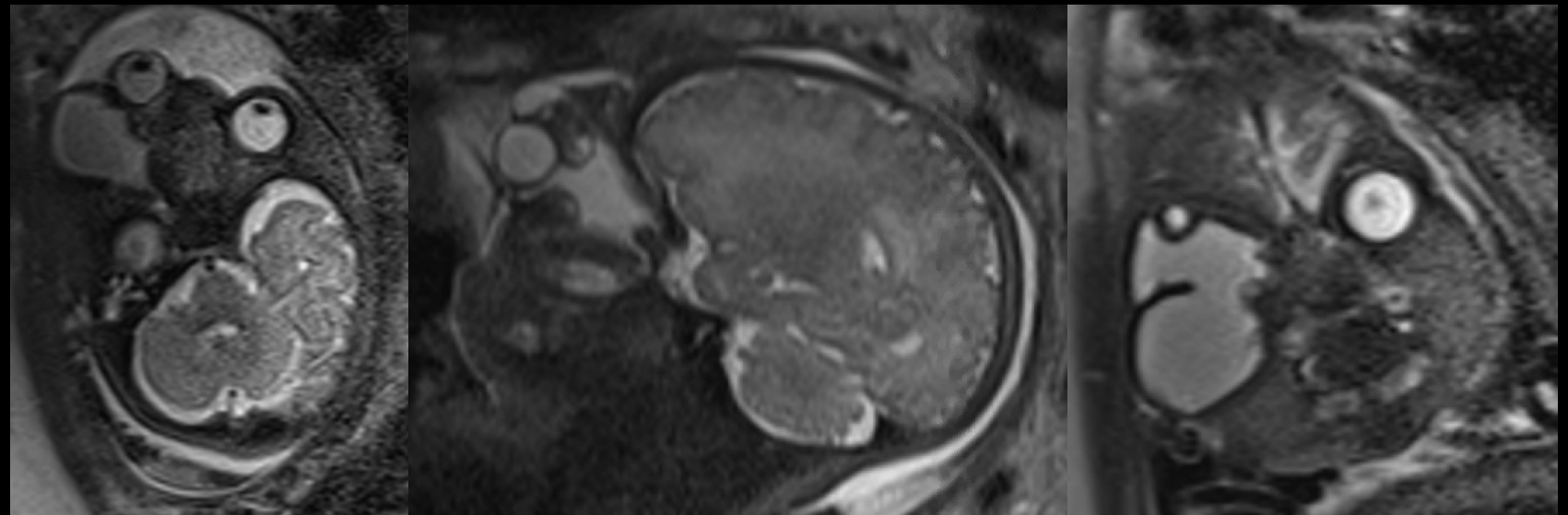
Normal



Congenital Orbital Teratoma



27w + 3d

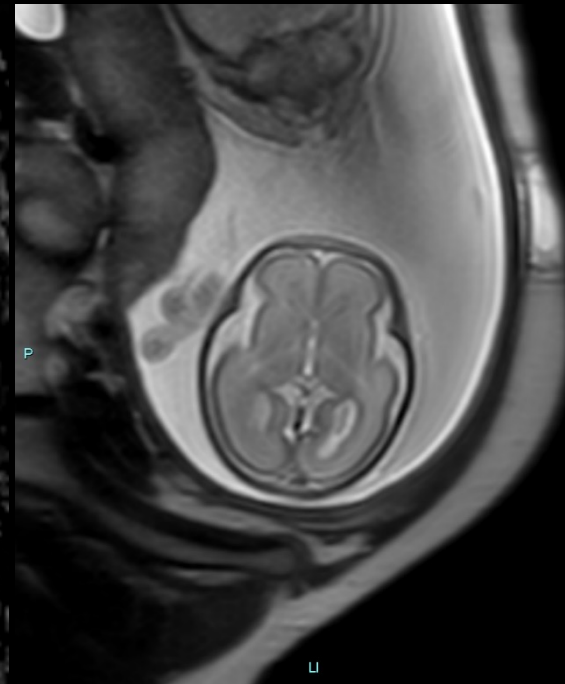
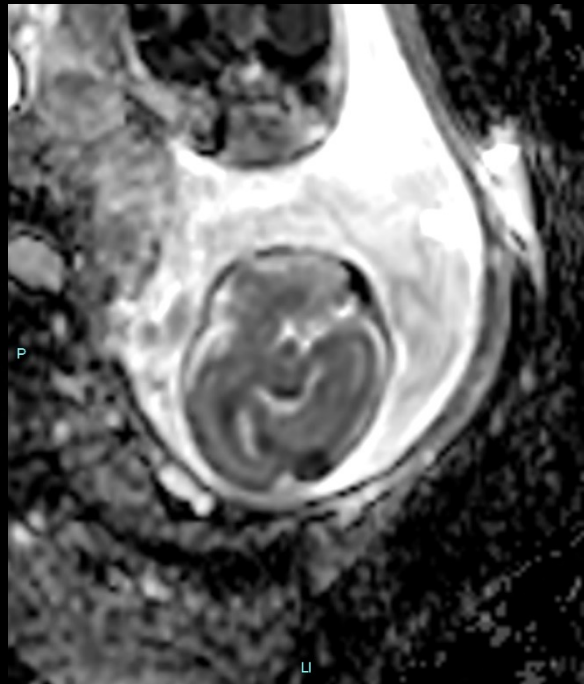
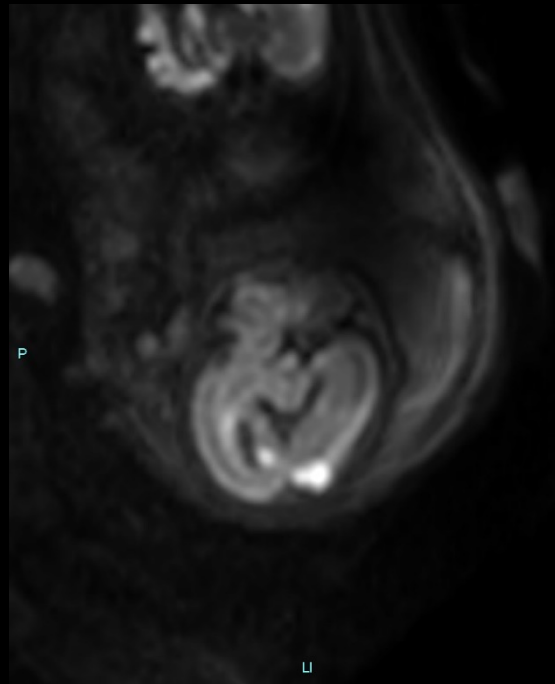


36w + 4d

Clinical Indications: CNS

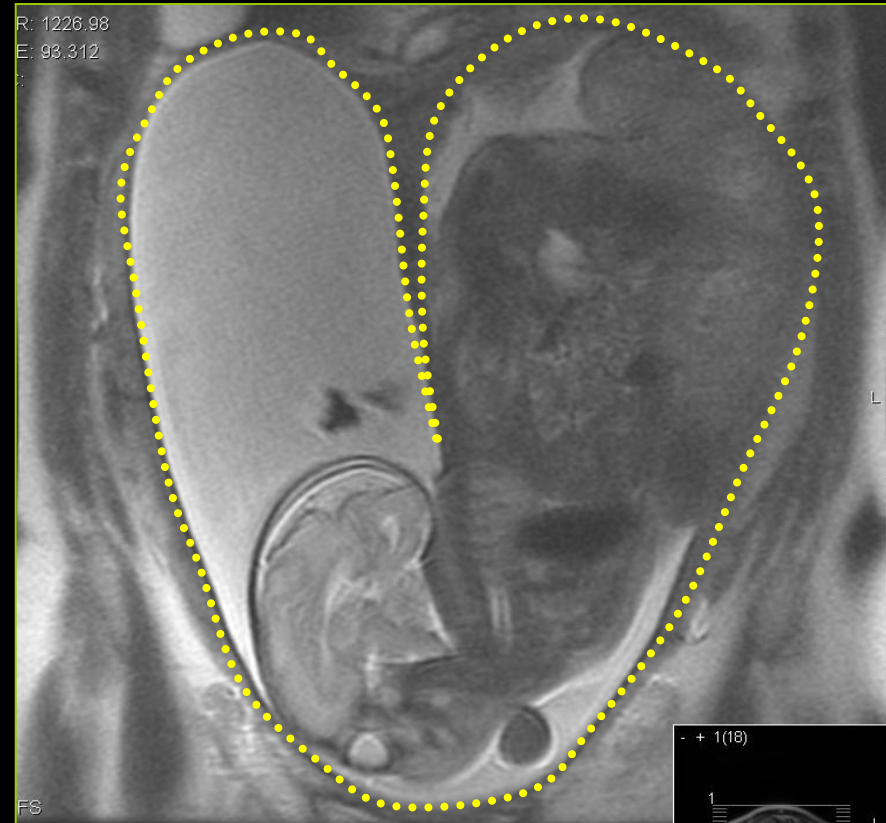
- Ventriculomegaly
- Agenesis/dysgenesis of the corpus callosum
- Absent Cavum septum pellucidum
- Micro or Macrocephaly – cortical malformations
- Intracranial haemorrhage
- Posterior fossa abnormalities
- Vein of Galen malformation
- Congenital infections
- Neural tube defects
- Orofacial abnormalities
- Complications of twin pregnancies (TTTS, TAPS)

26 weeks GA, TTTS, 3 days post laser ablation, IUFD



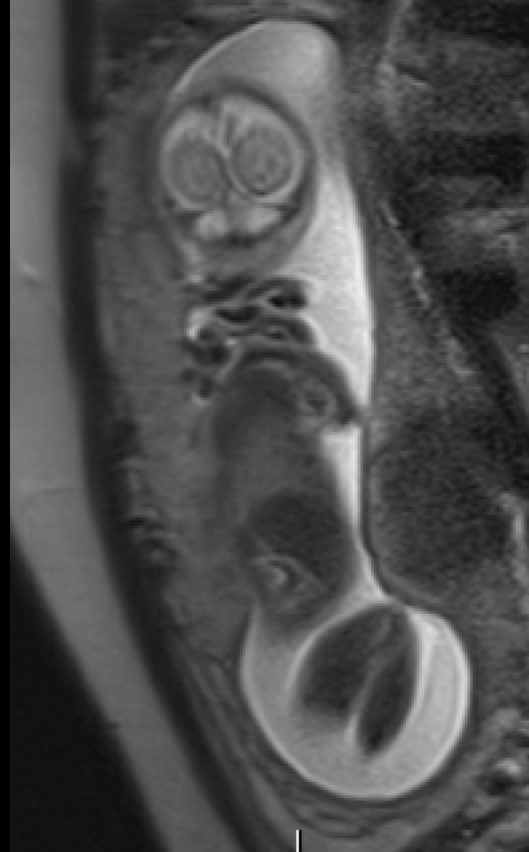
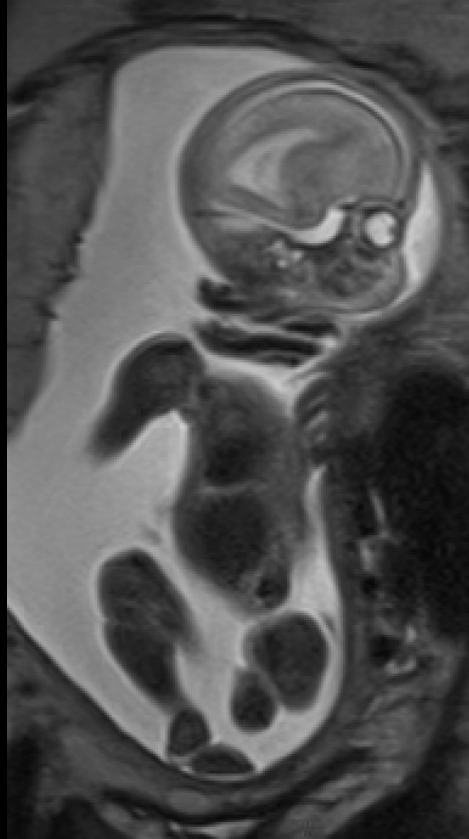
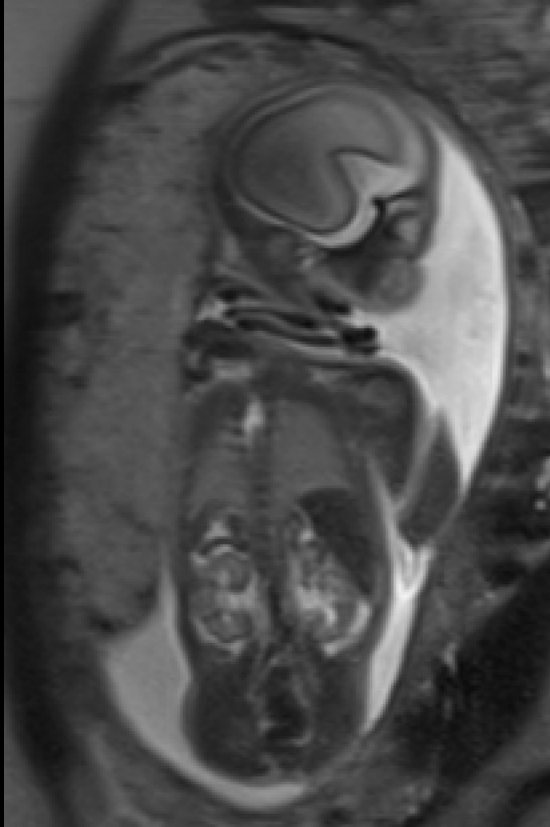
Look outside the head!

- ▶ When scanning the brain, we must look around
- ▶ Other malformations
- ▶ Abnormalities of the uterus
- ▶ Abdomen of the mother
- ▶ Bicornuate uterus

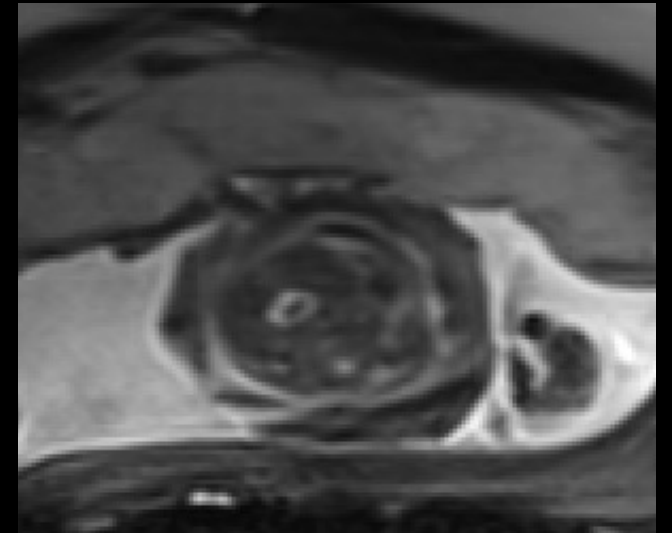


Look outside the head!

Nuchal Cord



Umbilical cord wrapped around the neck $\geq 360^\circ$



Fetal MR Imaging

- Diagnostic, therapeutic and prognostic assistance
- Increases our understanding of developmental anomalies counselling
- Understand clinical significance combined with post-natal follow-up or PM imaging



Ultrasound



MRI

Thank you

UCLH Fetal and Neonatal MRI services

Magda Sokolska (clinical scientist)

Dr Maureen Dumba

Dr Trevor Gaunt

Dr Emma Allan

Dr Giles Kendall

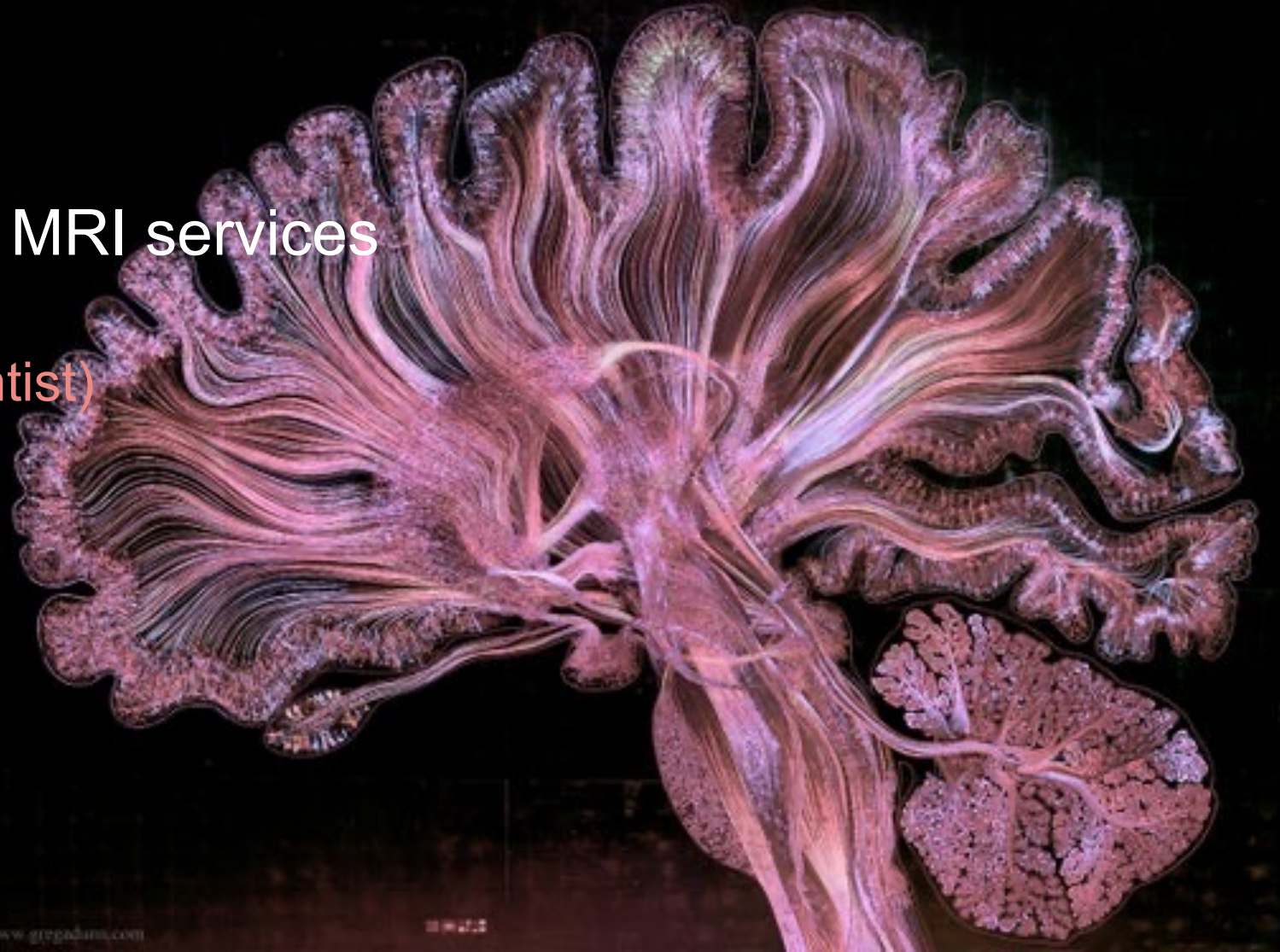Dr Leigh Dyet

Prof Anna David

Prof Donald Peebles

Prof Chen Hoffman (Tel-Aviv)

Families and Babies

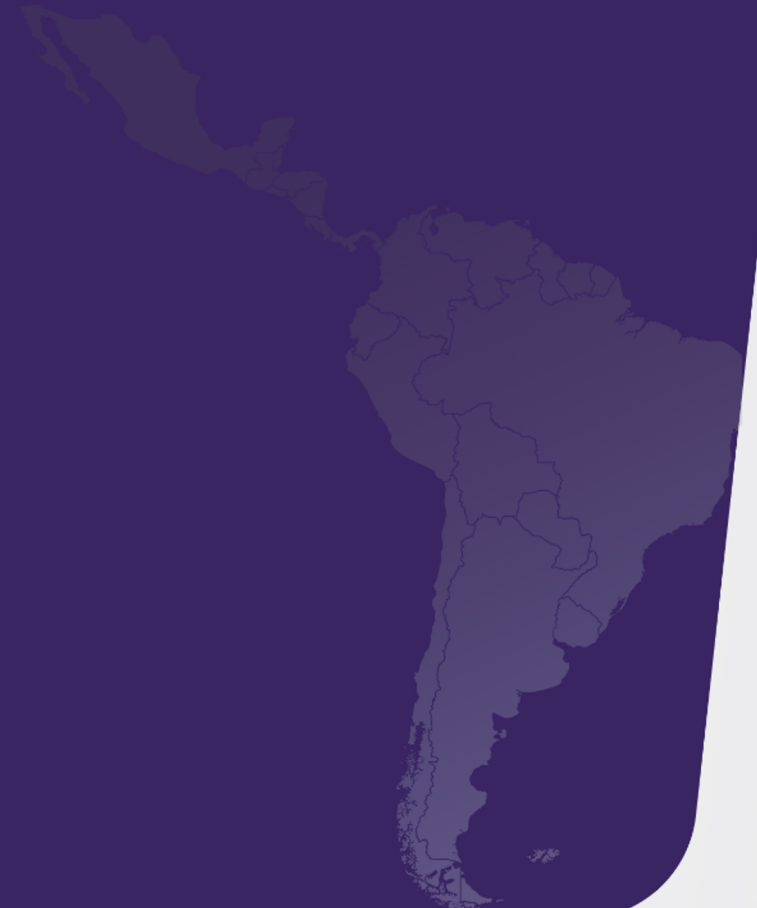

European Course on
Pediatric Neuroradiology in
Latin America (ECPNR-LATAM)
3rd Cycle - Module 1

Questions?

Contact

kelly.pegoretti@ucl.ac.uk



Idealização:



Organização:

