





European Course on Pediatric Neuroradiology in Latin America (ECPNR-LATAM)  
3<sup>rd</sup> Cycle - Module 1

# Neonatal Stroke



Ideiação:   Organização: 

1




European Course on Pediatric Neuroradiology in Latin America (ECPNR-LATAM)  
3<sup>rd</sup> Cycle - Module 1





Neuroradiologist at Curitiba, Paraná, Brazil, working at:

Pequeno Príncipe Childrens Hospital  
Neurological Institute of Curitiba  
Quanta Diagnostic Imaging

Adjunt Professor of Radiology at Federal University of Paraná

**Bernardo Corrêa de Almeida Teixeira**  
MD PhD

Ideiação:   Organização: 

2

## Neonatal Stroke

European Course on Pediatric Neuroradiology in Latin America (ECPNR-LATAM)  
3<sup>rd</sup> Cycle - Module 1

There is no conflict of interest in this presentation

3

## Neonatal Stroke Epidemiology

European Course on Pediatric Neuroradiology in Latin America (ECPNR-LATAM)  
3<sup>rd</sup> Cycle - Module 1

- Incidence → 1 / 2.500-5.000 neonates (3x higher than a male adult with hypertension and diabetes)
- 50% morbidity → Cerebral palsy, epilepsy, cognitive deficits
- More hemorrhagic and venous stroke than adults
- Risk factors → Male are more severely affected and in the peripartum period → activation coagulation cascades (tromboembolism risk factor in 42-78%)
- Treatment → Usually no occlusions and no known time of onset (endovenous>10kg / endovascular>2yo)

Fonte: Victor, et al. "A Comprehensive Review of the Pathophysiology of Neonatal Stroke and a Critique of Current and Future Therapeutic Strategies." Cells 14, 12 (2023): 818.

4

## Childhood X Perinatal Stroke

European Course on Pediatric Neuroradiology in Latin America (ECPNR-LATAM)  
3<sup>rd</sup> Cycle - Module 1

- Childhood stroke (28 days to 18 yo) → 50% cerebral arteriopathy, Cardiac disease (30%), Dissection (20%)
- Perinatal stroke (20gw to 28 days) → Arterial (80%), Venous (20%) - 43% of venous thrombosis occurs in the neonatal period
- Seizure is the most common symptom (80-92%), letargia, apnea → 40% neonates nonspecific / no signs of stroke
- Less than 25% of Strokes presentes with motor déficits in neonates
- Most diagnosis after 6 mo (coordinates motor activity) → hemiplegia, focal hand weakness (presumed perinatal stroke)

Fonte: Victor, et al. "A Comprehensive Review of the Pathophysiology of Neonatal Stroke and a Critique of Current and Future Therapeutic Strategies." Cells 14, 12 (2023): 818.

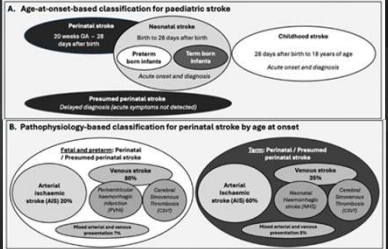
5

## Pediatric Stroke Classifications

European Course on Pediatric Neuroradiology in Latin America (ECPNR-LATAM)  
3<sup>rd</sup> Cycle - Module 1

**AGE-ONSET BASED CLASSIFICATION**

**PATHOPHYSIOLOGY BASED CLASSIFICATION**



Fonte: Victor, et al. "A Comprehensive Review of the Pathophysiology of Neonatal Stroke and a Critique of Current and Future Therapeutic Strategies." Cells 14, 12 (2023): 818.

6

### Pediatric Stroke Classifications

European Course on Pediatric Neurology in Latin America (ECPNH-LA/IAIM) 3<sup>rd</sup> Cycle - Module 1

| TABLE 1: Main Causes of Pediatric Stroke by Age Category |                          |            |  |
|--|--------------------------|------------|--|
| Age Category   | Type                     | CVSIT      |  |
| Term (>36 weeks gestation) to 28 d of life               | Arterial Ischemic Stroke | Thrombotic | Direct injury to vessel from trauma or infection |
|  | Hemorrhagic Stroke       | Thrombotic | Direct injury to vessel from trauma or infection |
| CHD 15-28 d to 18 d                                      | Arterial Ischemic Stroke | Thrombotic | Direct injury to vessel from trauma or infection |
|  | Hemorrhagic Stroke       | Thrombotic | Direct injury to vessel from trauma or infection |

**VENOUS**

Periventricular Infarction  
Sinovenous Thrombosis

**ARTERIAL**

Arterial Ischaemic Stroke  
Hemorrhagic Stroke

Reisner, Garcia, Lash, O., et al. "Imaging of suspected stroke in children, from the AJR Special Series on Emergency Radiology." American Journal of Roentgenology 200,3 (2012): 330-342.  
Dunbar, Mary, and Adam Kirton. "Perinatal stroke: mechanisms, management, and outcomes of early cerebrovascular brain injury." The Lancet Child & Adolescent Health 3,9 (2019): 658-670.

7

### Perinatal Stroke - The 6 Subtypes

European Course on Pediatric Neurology in Latin America (ECPNH-LA/IAIM) 3<sup>rd</sup> Cycle - Module 1

**ACUTE NEONATAL PRESUMED PERINATAL**

- ARTERIAL ISCHEMIC STROKE (80%)**
  - Most near Term (12-72h after delivery)
  - Rf: Multiparity, emergency birth, resuscitation, meconium, Aggar <7
  - Paradoxical placental embolism
- PRESUMED ARTERIAL ISCHEMIC STROKE**
  - 50% of strokes
  - Rf: Eucardiography and thrombophilia labs usually normal
- PERIVENTRICULAR VENOUS INFARCTION**
  - Term neonates with in-utero germinal matrix hemorrhage

- NEONATAL SINOVENOUS THROMBOSIS**
  - Sepsis, infection, dehydration, cardiac surgery, gestational diabetes, preeclampsia, chorioamnionitis,
  - 50% with strokes 175% hemorrhagic
  - Clinically similar to arterial stroke
  - Thalamic hemorrhage in term neonate
  - In Childhood 75% from AVM
  - Complete recanalization 50% after 3 months
- NEONATAL HEMORRHAGIC STROKE**
  - Ischemic hemorrhagic transformation
  - Deep sinovenous thrombosis (thalamus)
  - Vessel Weakness -> Temporal Lobes
  - No evident relation to birth trauma
- PRESUMED HAEMORRHAGIC STROKE**
  - Hereditary telangiectasia, immune thrombocytopenia, haemophilia, diatheses

Dunbar, Mary, and Adam Kirton. "Perinatal stroke: mechanisms, management, and outcomes of early cerebrovascular brain injury." The Lancet Child & Adolescent Health 3,9 (2019): 658-670.  
Reisner, M. H., et al. "Magnetic resonance imaging in neonatal stroke." Seminars in Fetal and Neonatal Medicine 10, 14, No. 6, VII, Elsevier, 2005.

8

### Perinatal Stroke Outcomes

European Course on Pediatric Neurology in Latin America (ECPNH-LA/IAIM) 3<sup>rd</sup> Cycle - Module 1

**Figure 3: Perinatal stroke outcomes, by stroke type**  
See appendix for more details.

Reisner, M. H., et al. "Magnetic resonance imaging in neonatal stroke." Seminars in Fetal and Neonatal Medicine 10, 14, No. 6, VII, Elsevier, 2005.  
Dunbar, Mary, and Adam Kirton. "Perinatal stroke: mechanisms, management, and outcomes of early cerebrovascular brain injury." The Lancet Child & Adolescent Health 3,9 (2019): 658-670.

9

### Perinatal Stroke Imaging

European Course on Pediatric Neurology in Latin America (ECPNH-LA/IAIM) 3<sup>rd</sup> Cycle - Module 1

- Most common arteries affected -> MCA (80-90%, Left -> Fetal Dominant), PCA (5-10%), ACA (1-5%) and Vertebrobasilar (<1%)
- US is abnormal in majority of cases 1 day after the insult -> but operator dependent
- CT not sensitive enough for ischemic stroke -> may miss 80% of ischemic strokes -> Always MRI if possible!
- MRI + DWI is the Gold Standard! T2 + 24-48 hours to positive / ADC + Lowest day 3/4 (pseudonormalisation in 4-21 days) and encephalomalacia + 1-2 months
- Advanced Techniques can be helpful, but increase scan times -> SWI for hemorrhage, AngioMR for vessel occlusion, Vessel Wall for vasculitis and Perfusion for penumbra

Reisner, M. H., et al. "Magnetic resonance imaging in neonatal stroke." Seminars in Fetal and Neonatal Medicine 10, 14, No. 6, VII, Elsevier, 2005.

10

### Perinatal Stroke - The 6 Subtypes

European Course on Pediatric Neurology in Latin America (ECPNH-LA/IAIM) 3<sup>rd</sup> Cycle - Module 1

- Neonatal Arterial Ischaemic Stroke
- Presumed Perinatal Arterial Ischaemic Stroke
- Neonatal Haemorrhagic Stroke
- Presumed Perinatal Haemorrhagic Stroke
- Neonatal Cerebral Sinovenous Thrombosis
- Periventricular Venous Infarction

Dunbar, Mary, and Adam Kirton. "Perinatal stroke: mechanisms, management, and outcomes of early cerebrovascular brain injury." The Lancet Child & Adolescent Health 3,9 (2019): 658-670.

11

### Neonatal Arterial Ischaemic Stroke

European Course on Pediatric Neurology in Latin America (ECPNH-LA/IAIM) 3<sup>rd</sup> Cycle - Module 1

F, 9d, seizure, birth 24 hours after ruptured membranes (without antibiotic use), intrauterus ischemia?

F, 8d, new rhythmic limb movements, ABO blood incompatibility with need for intensive phototherapy

F, 11d, Group B Streptococcal meningitis

Dunbar, Mary, and Adam Kirton. "Perinatal stroke: mechanisms, management, and outcomes of early cerebrovascular brain injury." The Lancet Child & Adolescent Health 3,9 (2019): 658-670.

12

### Childhood Arterial Ischaemic Stroke

European Course on Pediatric Neurology in Latin America (ECPNR-LATAM) 3<sup>rd</sup> Cycle - Module 1

M, 9mo, right side hemiparesis following flu-like symptoms

Normal AngioMRI    Varicella Vasculitis

**FOCAL ARTERIOPATHY (ADENOVIRUS)**  
Infection → hypercoagulable state/endothelial injury  
Herpesvirus (Varicella), Bacterial meningitis (Streptococcus) and Influenza

Arribas-García, Liso D., et al. "Imaging of suspected Stroke in children: from the AJR Special Series on Emergency Radiology." American Journal of Roentgenology 200 3 (2023): 330-342

13

### Childhood Arterial Ischaemic Stroke

European Course on Pediatric Neurology in Latin America (ECPNR-LATAM) 3<sup>rd</sup> Cycle - Module 1

F, 2yo, pneumonia and loss of consciousness    F, 4do, fever and seizures    M, 8yo, dilated cardiomyopathy with cardiac surgery

**HYPERCOAGULABLE STATE/ENDOTHELIAL INJURY → VESSEL OCCLUSIONS**

14

### Childhood Arterial Ischaemic Stroke

European Course on Pediatric Neurology in Latin America (ECPNR-LATAM) 3<sup>rd</sup> Cycle - Module 1

**MOYAMOYA SYNDROME**  
Progressive Vasculopathy → Up to 50% in Children  
Vascular smooth muscle overgrowth with collaterals (puff of smoke)  
In children → Ischemia > hemorrhage  
RF → Down Syndrome, Sick Cell Disease, Cranial Radiotherapy, NF1, T21

Demartini Jr, Zeferno, et al. "Moyamoya disease and syndrome: a review." Radiologia brasileira 55(01) (2022): 31-37

15

### Presumed Arterial Ischaemic Stroke

European Course on Pediatric Neurology in Latin America (ECPNR-LATAM) 3<sup>rd</sup> Cycle - Module 1

F, 1mo, cough with respiratory distress, osteogenesis imperfecta and neonatal pulmonary sepsis    F, 2mo, vesicoureteral reflux, Grade 5, oligodromia, peritoneal dialysis

**NETWORK INJURY**

Smith, M. H., et al. "Moyamoya syndrome imaging in neonatal stroke." European Paediatric Neurology 14: No. 6 (Wiley-Blackwell) 2009

16

### Presumed Perinatal Ischaemic Stroke

European Course on Pediatric Neurology in Latin America (ECPNR-LATAM) 3<sup>rd</sup> Cycle - Module 1

F, 6mo, at 18do started with respiratory distress, hx of patent ductus arteriosus and aortic dilatation

**MULTISYSTEMIC SMOOTH MUSCLE DYSFUNCTION SYNDROME**

- Mutation in the ACTA2 gene
- Cerebrovascular, aortic, intestinal hypoperistalsis, hypotonic bladder and pulmonary hypertension
- Congenital midline and aortic aneurysm
- Hereditary Vasculopathies → DDX COL4A1 (aneurysm, microbleeds, porencephaly)

Arribas-García, Liso D., et al. "Imaging of suspected Stroke in children: from the AJR Special Series on Emergency Radiology." American Journal of Roentgenology 200 3 (2023): 330-342

17

### Pathogenesis of Perinatal AIS

European Course on Pediatric Neurology in Latin America (ECPNR-LATAM) 3<sup>rd</sup> Cycle - Module 1

**PERINATAL ARTERIAL ISCHEMIC STROKE (Maternal, Placental and Fetal Conditions)**

1. Embolism (33%)
2. Meningitis/sepsis (9%)
3. Trauma (7%)
4. Primary thrombosis (4%)
5. Arteriopathy (4%)
6. Other causes (7%)
7. Unclassifiable (26%)

**Maternal Risk Factors:** Antithrombotic abnormalities, Chronic renal dysfunction, Diabetes, Gestational hypertension, Labor and delivery complications, Maternal thrombotic disorders, Preeclampsia/eclampsia, Premature rupture of membranes, Prothrombotic abnormalities

**Fetal/neonatal Risk Factors:** Congenital heart disease, Dehydration, Infection, Intrauterine growth restriction, Neonatal microangiopathy, Perinatal asphyxia, Perinatal hypoxemia, Post-term asphyxia

**Pathogenesis:** Cervical/cerebral arteries → ARTERIOPATHY (Mendelian: PROCR1, HNF1B; Traumatic compression; Cervical artery dissection, herniation or direct compression from subdural or intracranial hemorrhage); Infection; Arteritis due to meningitis; Arterial tortuosity, Myoelastosis, Endothelial thickening; Genetic thrombophilias (Factor V Leiden, prothrombin mutation); Systemic illness (Infectious: C. or arboviruses/EBV, Infectious: Sickle cell disease, malaria, factor V Leiden, prothrombin mutation); Other (Lupus, hypoxemia, hypotension, DIC, Sepsis); Intrauterine constriction (IUGR), polyhydramnios; Babes/candida; Congenital heart disease, heart failure, endocarditis, myocarditis; Transcatheter (via PFO): Thrombotic thrombocytopenic syndrome, umbilical cord, fetal/neonatal venous system, an aneurysm, cerebral venous thrombosis

**PERINATAL STROKE**

18

### Menkes Disease – Stroke Mimics

European Course on Pediatric Neuroradiology in Latin America (ECPNR-LA/IRAM) 3<sup>rd</sup> Cycle - Module 1

M, 3mo, status epilepticus, cutis laxa with low cooper and ceruloplasmin

**MENKES DISEASE**

- X-linked recessive disorder (ATP7A)
- Impaired Copper absorption/metabolism
- Increased arterial tortuosity (75%)
- WM Tumorlike Lesions (33%)
- Atrophy and delayed myelination
- Cerebellar Atrophy (80%)
- Subdural Collections

Follow-up MRI

White Kinky Hair

19

### Neonatal Hemorrhagic Stroke

European Course on Pediatric Neuroradiology in Latin America (ECPNR-LA/IRAM) 3<sup>rd</sup> Cycle - Module 1

M, 23do, blood dyscrasia and hyperkalemia, preterm 33wk

F, 5do, seizures and lethargy

M, 7mo, mycotic aneurysms Strep. Pneumoniae Meningitis (child not vaccinated)

20

### Presumed Hemorrhagic Stroke

European Course on Pediatric Neuroradiology in Latin America (ECPNR-LA/IRAM) 3<sup>rd</sup> Cycle - Module 1

M, 1yo 4mo, left hemiparesis and seizures

M, 7mo

F, 5mo, left motor deficit and hyperreflexia

Accidental Trauma

Abusive Trauma

Prior CT after car accident

**ETIOLOGY**

- Primary (60%) - Hemorrhagic Transformation (35%) - Presumed (5%)
- Thrombocytopenia (20%)
- Cavernomas (5%)
- Idiopathic (75%)

21

### Neonatal Sinovenous Thrombosis

European Course on Pediatric Neuroradiology in Latin America (ECPNR-LA/IRAM) 3<sup>rd</sup> Cycle - Module 1

F, 20do, sepsis and dehydration

Pre-GAD

Pos-GAD

F, 4yo, cough with fever

22

### Neonatal Sinovenous Thrombosis

European Course on Pediatric Neuroradiology in Latin America (ECPNR-LA/IRAM) 3<sup>rd</sup> Cycle - Module 1

**RISK FACTORS**

- Hypoxia, maternal infections, membrane ruptures (5%)
- Dehydration (30%)
- Head/Neck Disorders (16%)

**3 PATTERNS**

- Thalamocaudate (internal cerebral vein)
- Striato-hippocampal (basal vein)
- Iris/brush pattern (deep medullary veins)

**FIGURE 18** Serial medullary vein angiogram in a term infant with hemorrhagic infarct in 23-week-old neonate born at 33 weeks gestation who was diagnosed with SIV and toxic shock. (A, B) Axial CT imaging (A) and coronal MRI (B) show the thalamocaudate deep medullary vein congestion or thrombosis and right thalamic and left parieto-occipital hemorrhagic infarctions. (C) Coronal MRI shows the striato-hippocampal vein thrombosis secondary to the thalamic, causing the brush sign. (D) Axial MRI scan of the sigmoid sinus thrombosis secondary to the thalamic. (E) Axial MRI scan of the sigmoid sinus thrombosis secondary to the thalamic.

Liabin M, et al. "Neuroimaging of neonatal stroke: venous focus." Radiographics 2024; 44(2): 4230-4237

23

### Periventricular Venous Infarction

European Course on Pediatric Neuroradiology in Latin America (ECPNR-LA/IRAM) 3<sup>rd</sup> Cycle - Module 1

M, 5mo, preterm 32, duodenal atresia surgery, germinal matrix hemorrhage GI

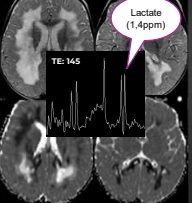
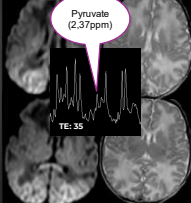
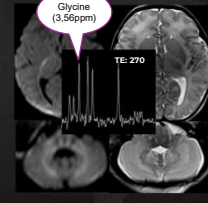
F, 5mo, left distal hemiplegia and epilepsy (West Syndrome)

Curran, Mary, and Adam Kilian. "Perinatal stroke: mechanisms, management, and outcomes of early cerebrovascular brain injury." The Lancet Child & Adolescent Health 2 (9) (2018): 656-671

24

**Stroke Mimics – Metabolic Diseases**

European Course on Pediatric Neuroradiology in Latin America (ECPNR-LATAM)  
3<sup>rd</sup> Cycle - Module 1

|   |   |   |
|---|---|---|
| F, 10mo, since 8 mo motor skills regression, hypotonia, hyperreflexia             | F, 2do, hypotonia, seizure and metabolic acidosis                                 | M, 3do, excessive sleepiness, lethargy, apnea and hypotonia                       |
|  |  |  |
| <b>LEIGH SYNDROME (NDUFV1)</b>  | <b>LEIGH SYNDROME (PDCD)</b>  | <b>NONKETOTIC HYPERGLYCIEMIA</b>  |

25

**Take Home Points**

European Course on Pediatric Neuroradiology in Latin America (ECPNR-LATAM)  
3<sup>rd</sup> Cycle - Module 1

- Classifications - Perinatal/Childhood, Acute/Presumed, Arterial/Venous
- Etiology - Hypercoagulable States (Maternofetal), Heart Disease, Trauma
- Always double check the veins in preterms and neonates
- Remember Network Injury/Wallerian Degeneration in Children!
- If history and imaging findings don't match think of abusive trauma
- Don't forget neonatal inborn errors of metabolism (there aren't many)

26

European Course on Pediatric Neuroradiology in Latin America (ECPNR-LATAM)  
3<sup>rd</sup> Cycle - Module 1

**Contact**  
[bernardo.teixeira@ufpr.br](mailto:bernardo.teixeira@ufpr.br)

**Thank you for your attention!**

Idealização:    Organização: 

27