

European Course on
Pediatric Neuroradiology in
Latin America (ECPNR-LATAM)

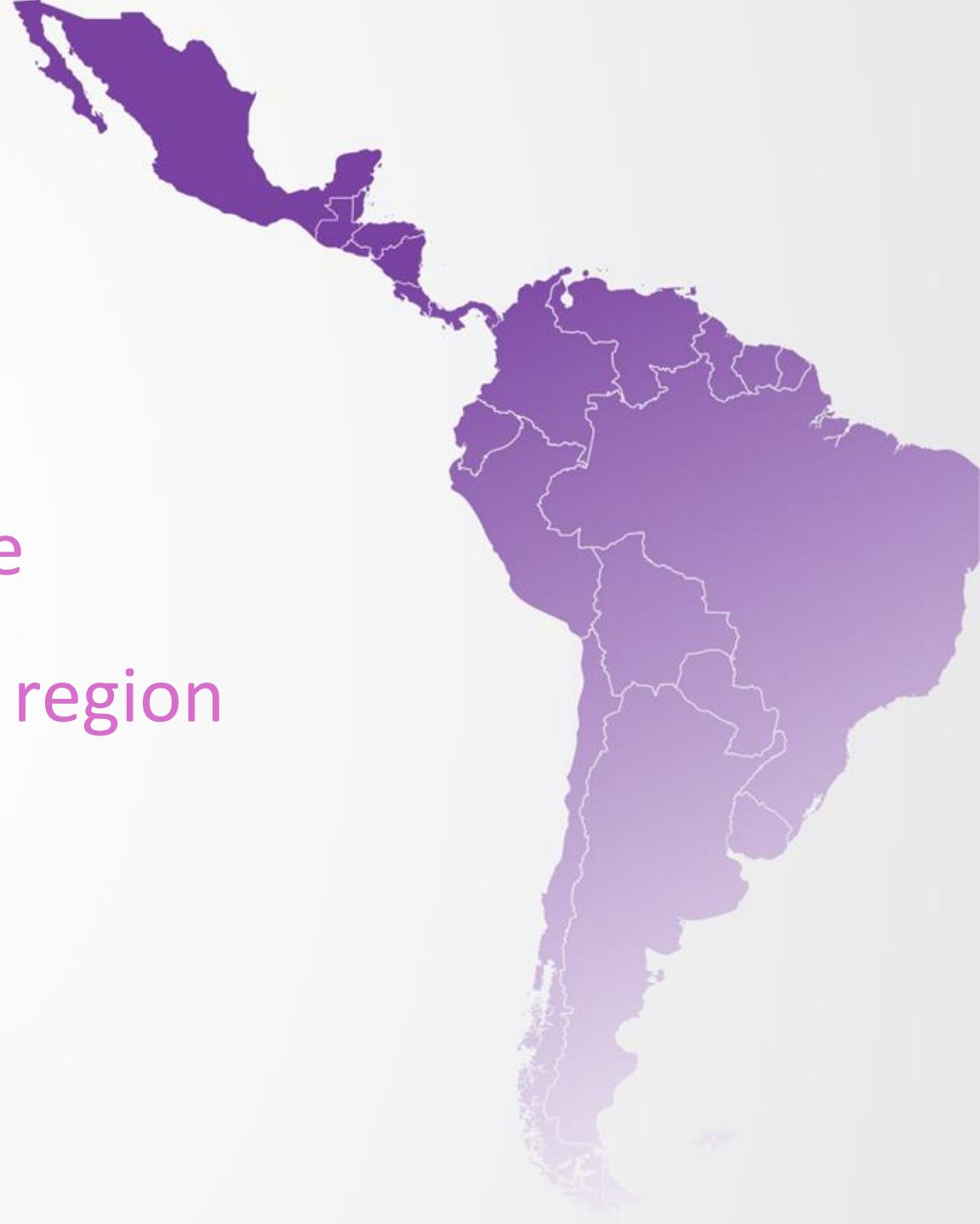3rd Cycle - Module 1

MR imaging of the
hypothalamus-pituitary region
in children

Idealização:



Organização:



European Course on
Pediatric Neuroradiology in
Latin America (ECPNR-LATAM)

3rd Cycle - Module 1



MR imaging of the hypothalamus-pituitary
region in children

Antônio Rocha, MD PhD

Radiologista e Neurorradiologista

CBR / SBNR / EDiNR

CRM SP 74453

RQE 34187

Idealização:



Organização:



Conflicts of Interest

de acordo com a RDC nº 96, de 17 de dezembro de 2008 e da resolução 1.595/2000 do CFM, declaro:

Dr. Antônio José da Rocha, MD PhD
Radiologista e Neurorradiologista
CBR / SBNR / EDiNR
CRM SP 74453
RQE 34187

Honorários como palestrante para as empresas: Sanofi, Roche, Biogen, Bayer e Novo Nordisk Farmacêutica

Vínculo com Hospital Central da Santa Casa de SP e Grupo DASA

Professor adjunto da FCMSCSP

Sócio do Grupo Educacional RadExperts



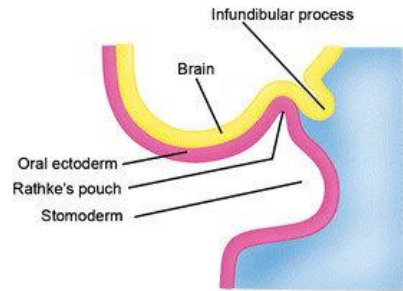
Purposes

- To present a comprehensive review of imaging features of the sellar and parasellar imaging in pediatric endocrinology including mostly:
 - Appearances of congenital diseases arising in the sellar and suprasellar regions
 - To demonstrate how the embryological correlations of the pituitary gland with the adjacent structures facilitate the correct interpretation of sellar and parasellar abnormalities
 - How to use MRI FAST 1.2 in the evaluation of hypothalamic-pituitary disorders
 - faster acquisition images without Gd administration (is it safe for clinical practice or only as a research protocol?)
 - How, When and Why
 - How to use multiplanar MRI with intravenous Gd administration
 - How, When and Why
 - Reviewing differential diagnoses useful for clinical practice
-

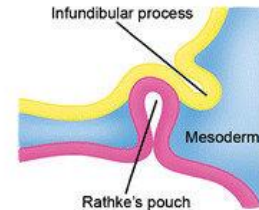


Introduction – Embriology

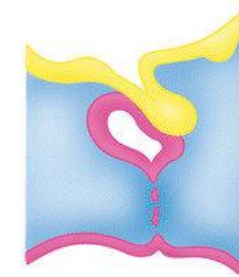
4-6W



1. Start of development of Rathke's pouch and infundibular process



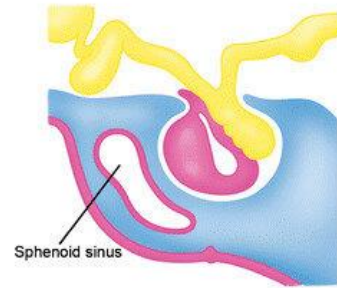
2. Growth of the mesoderm is limited by the neck of Rathke's pouch



3. Rathke's pouch "compressed"

8W

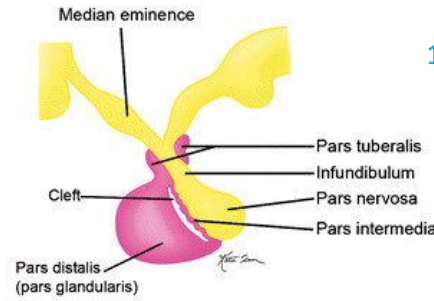
11W



4. "Compressed" segment integrates the neural process, forming pars distalis, pars intermedia, and pars tuberalis



5. Pars tuberalis wraps around the infundibular stalk



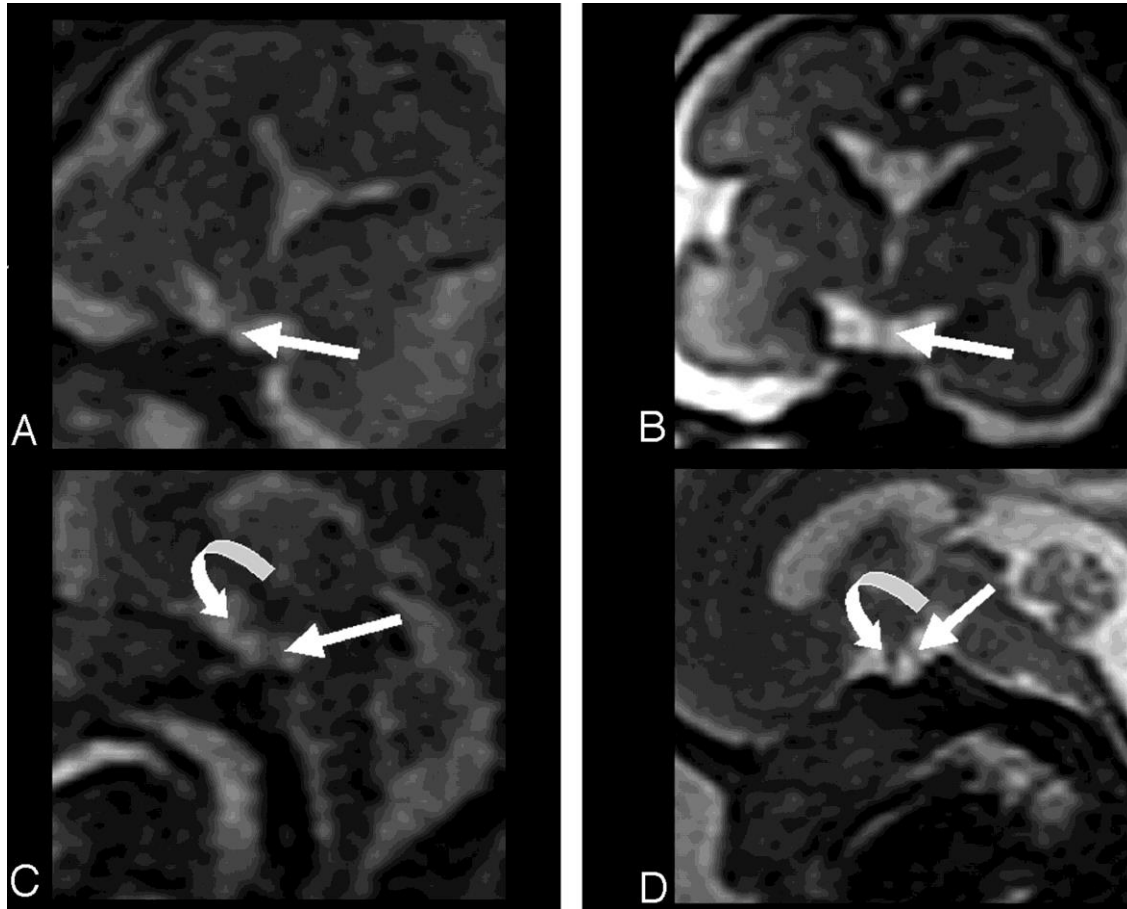
6. Mature form

16W

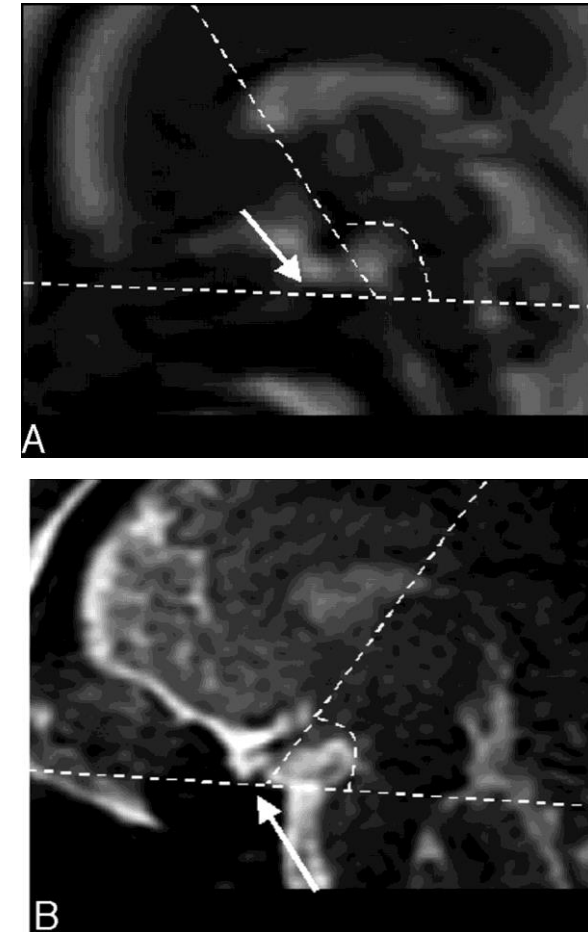
The pituitary gland consists of two embryological and functionally distinct divisions:

Adenohypophysis (pars anterior or distalis, pars intermedia (rudimentary in humans) and pars tuberalis (along the stalk))
Neurohypophysis (median eminence, infundibular stem and pars posterior)

coronal and sagittal SS-FSE T2-weighted sections from 21 weeks' GA (A and C) and 27 weeks' GA (B and D) show the PS (arrows); curved arrows indicate the optic chiasm and optic nerve, which are more horizontally oriented than the PS.



Sagittal SS-FSE T2-weighted sections from 22 (A) and 37 (B) weeks' GA fetuses show the PS-SP angle measurement method.

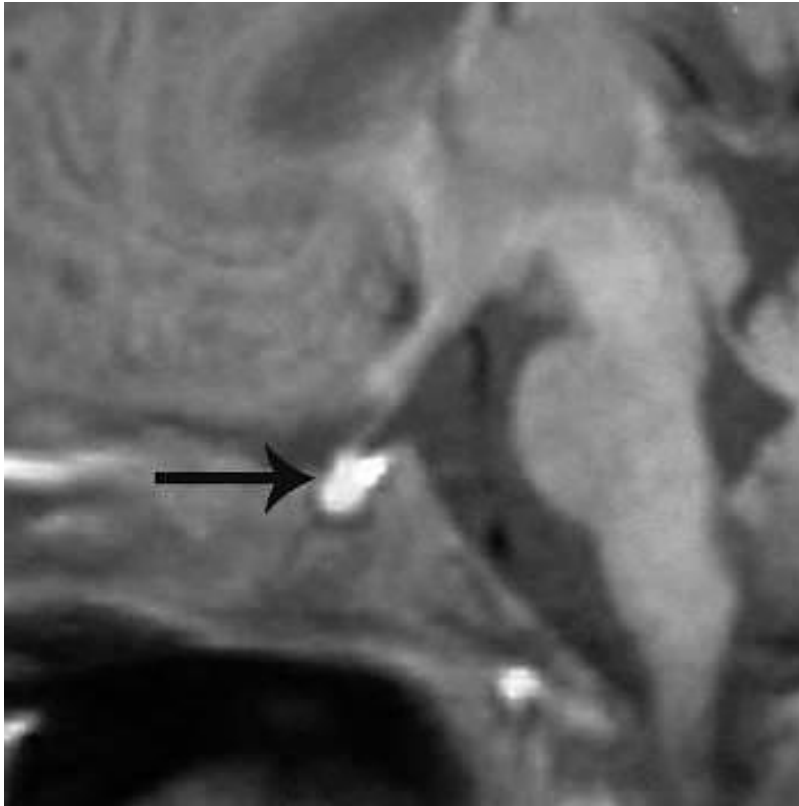




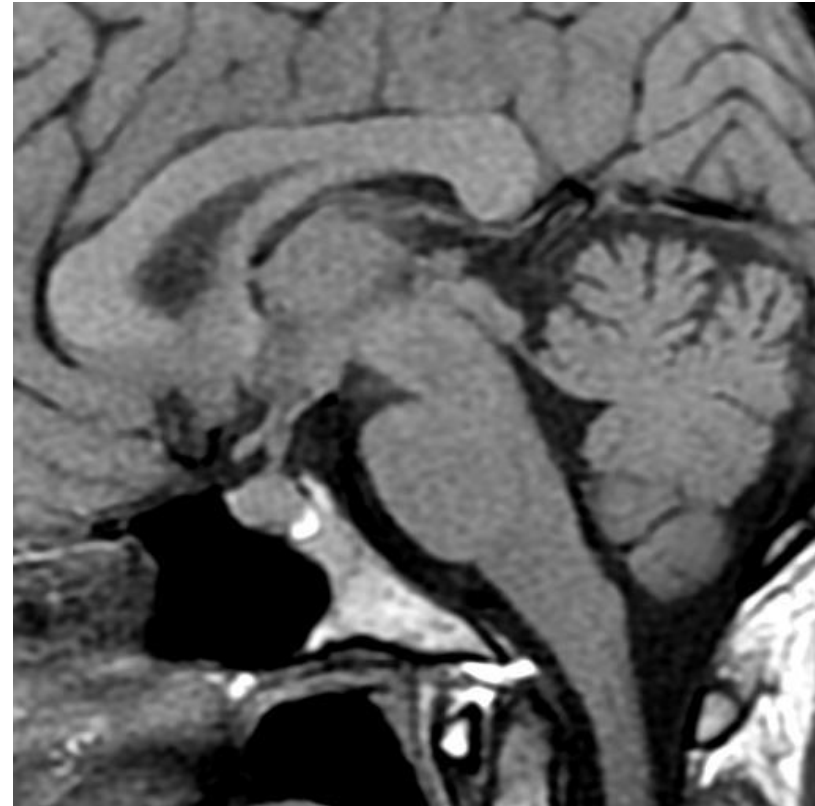
Neonatal appearance

SAGITAL T1

Neonatal normal appearance



Adult pattern





Endocrine-related diseases in pediatric population

- Main endocrine related disorders in children include:
 - hypopituitarism,
 - growth failure, including dwarfism
 - diencephalic syndrome,
 - delayed puberty and precocious puberty,
 - diabetes insipidus and syndrome of inappropriate antidiuretic hormone (SIADH) secretion,
 - and rarely hyperpituitarism
 - among hormonally active tumors:
 - adrenocorticotrophic hormone-releasing adenomas are most common in the first 11 years of life
 - prolactinomas become more common into the teenage years

Imaging of pediatric pituitary endocrinopathies.

Chaudhary V and Bano S.

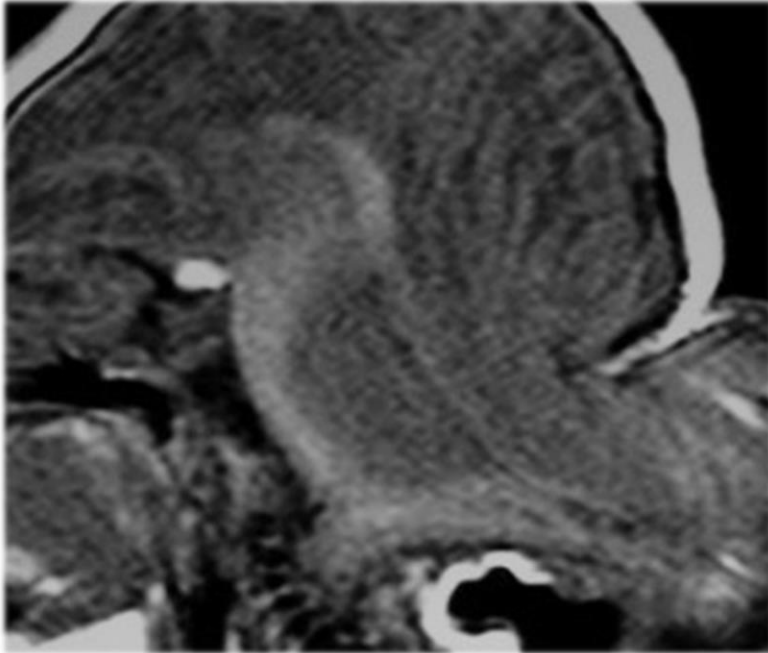
[Indian J Endocrinol Metab. 2012 Sep-Oct;16\(5\):682–691. doi: 10.4103/2230-8210.100635.](#)



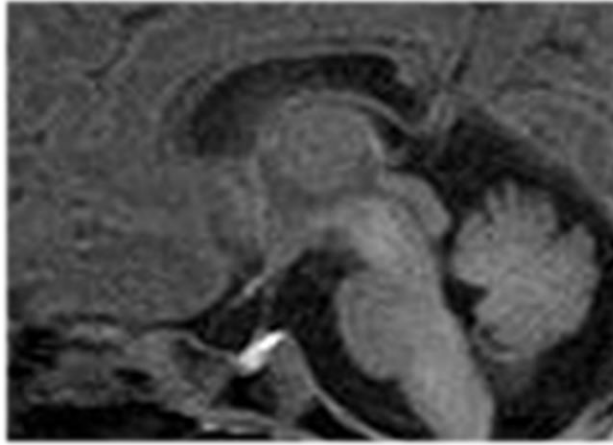
Normal appearance

Convex appearance of pituitary gland: 63% of neonates below 1 month

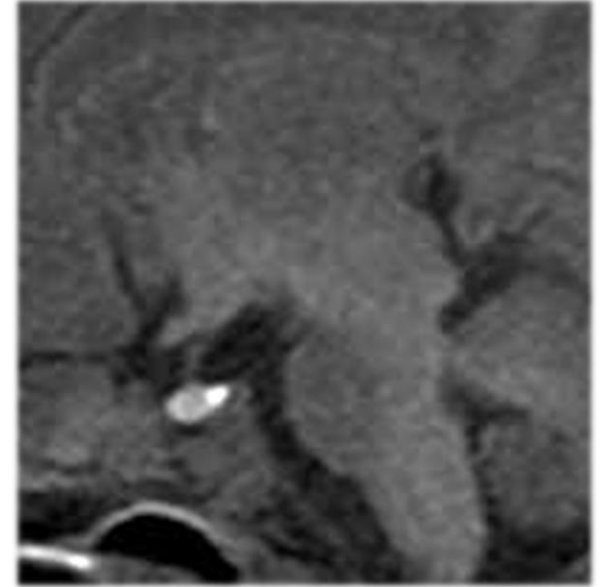
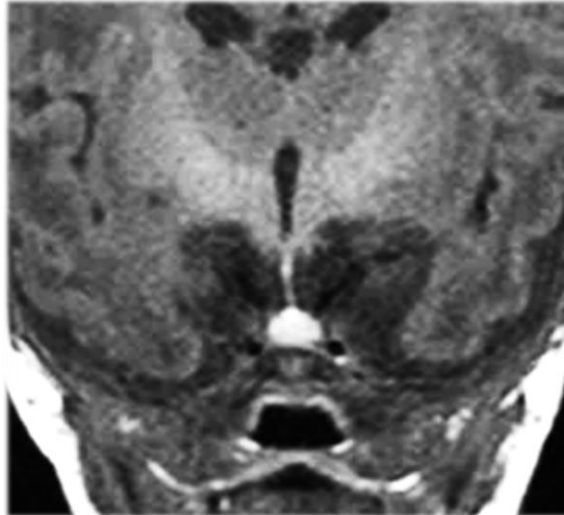
Anterior pituitary T1 hyperintense (0-2 months): Intense hormonal secretion activity & intense protein secretion



♂
WWS
2d



♀ 1w



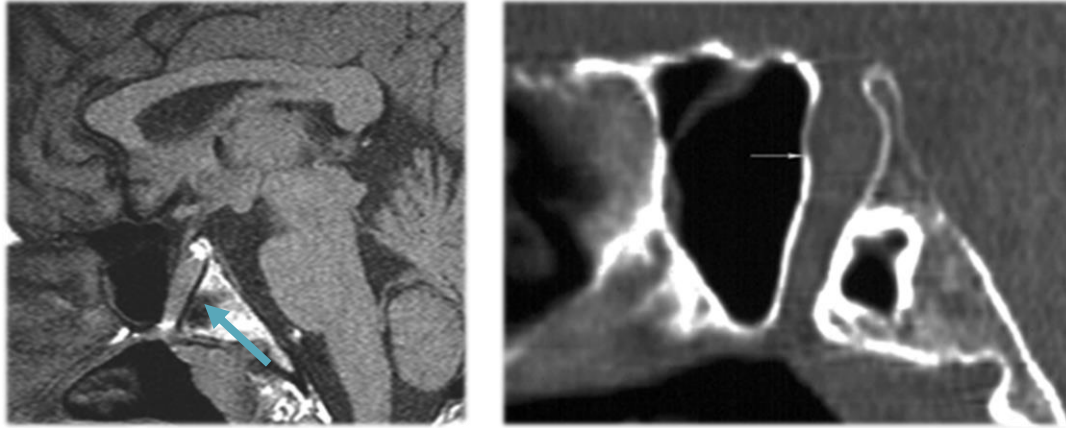
♂, 4w



Congenital anomalies

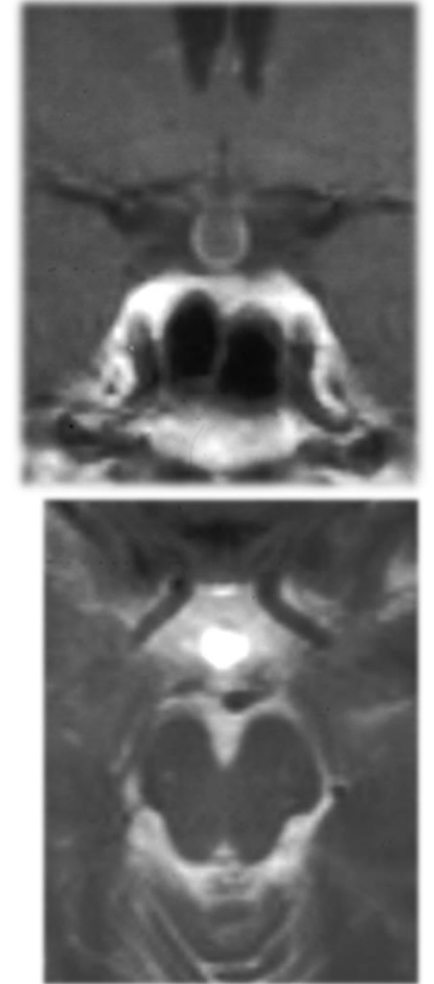
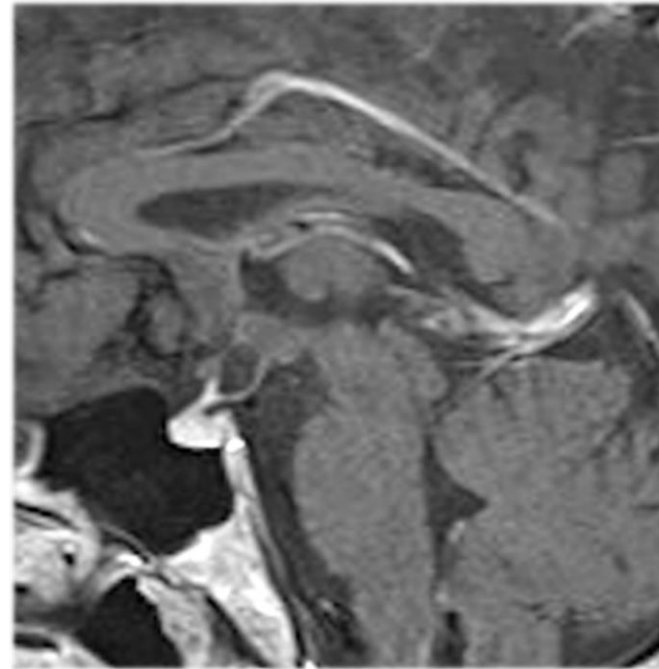
Persistent craniopharyngeal canal

♂, 18yo



Stalk fenestration

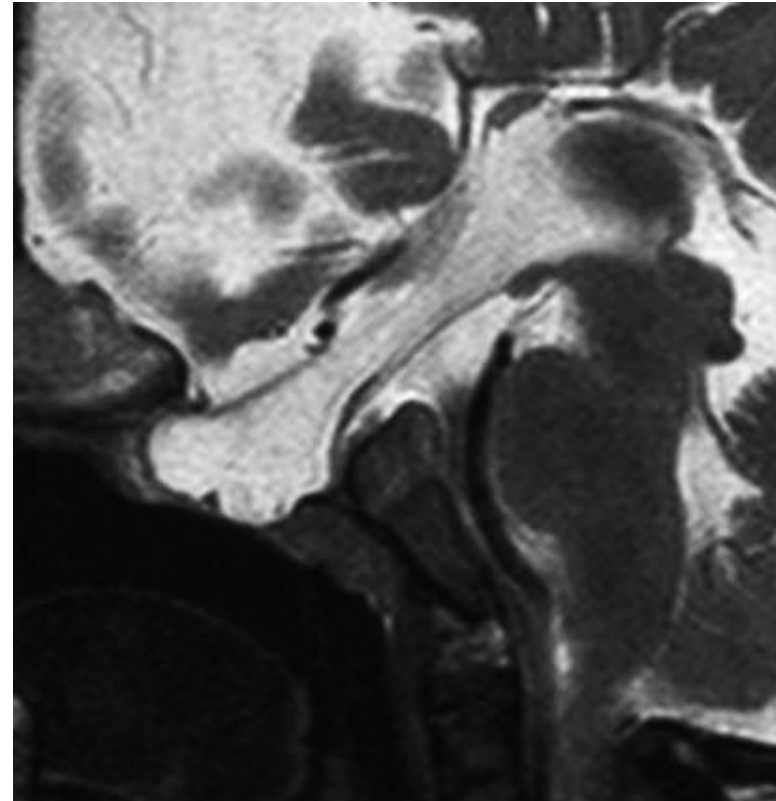
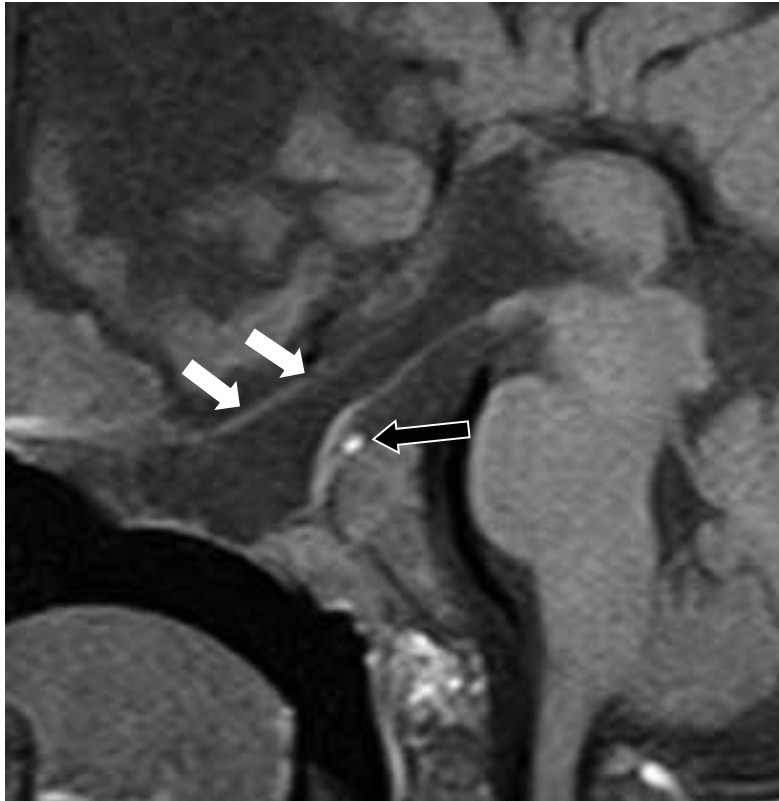♂, 14yo





Congenital anomalies

Transsphenoidal Encephalocele

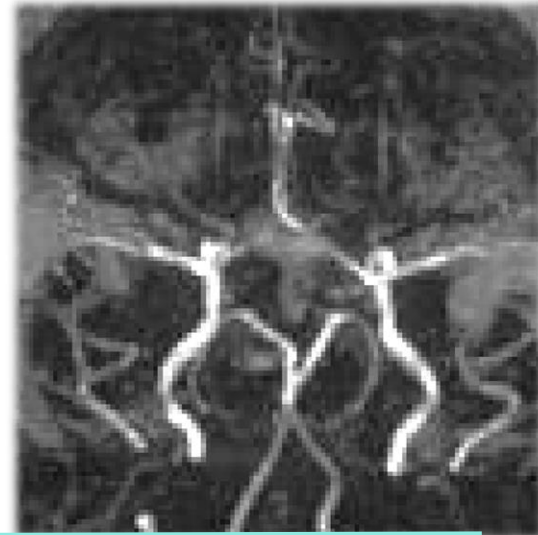
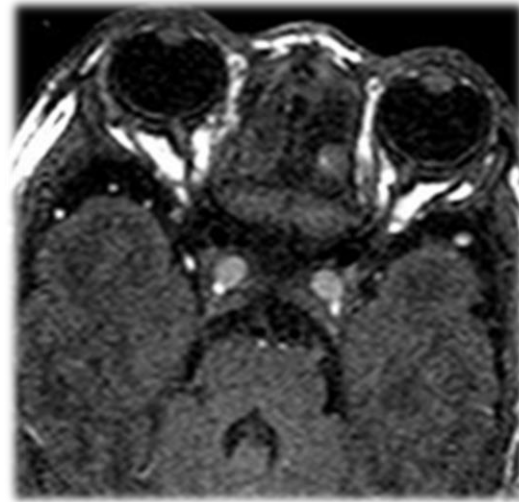
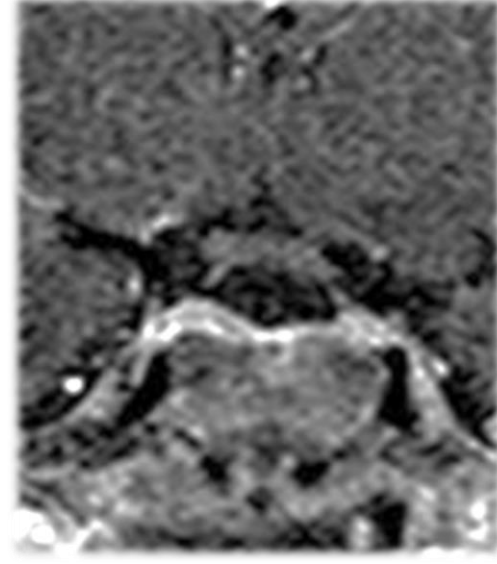
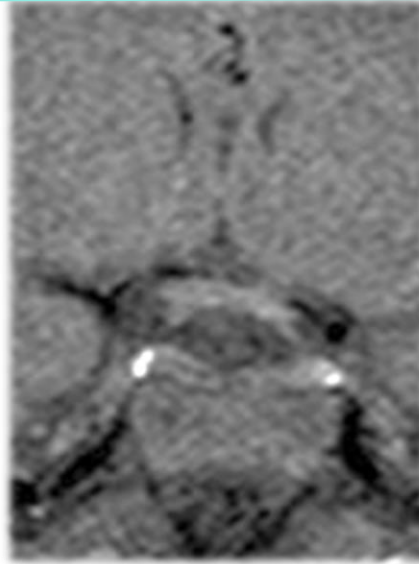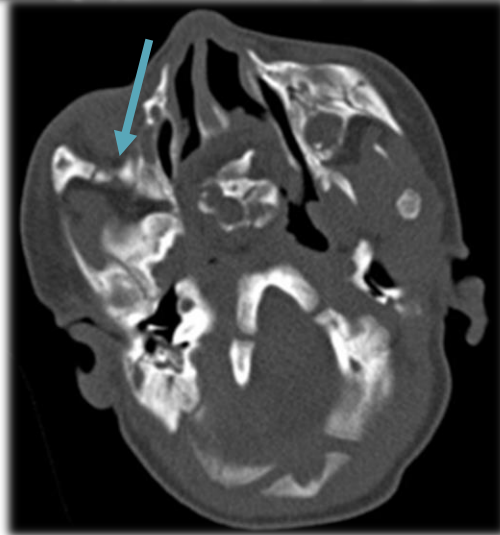
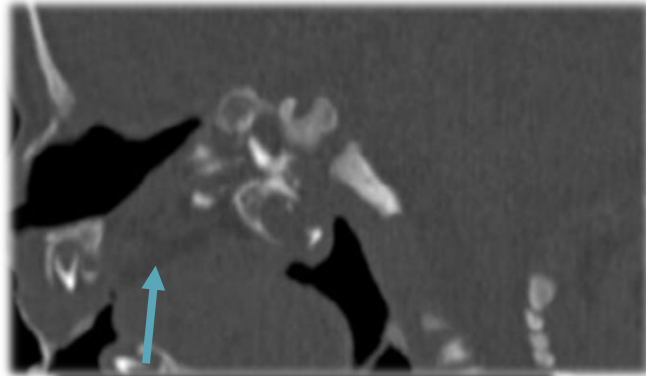




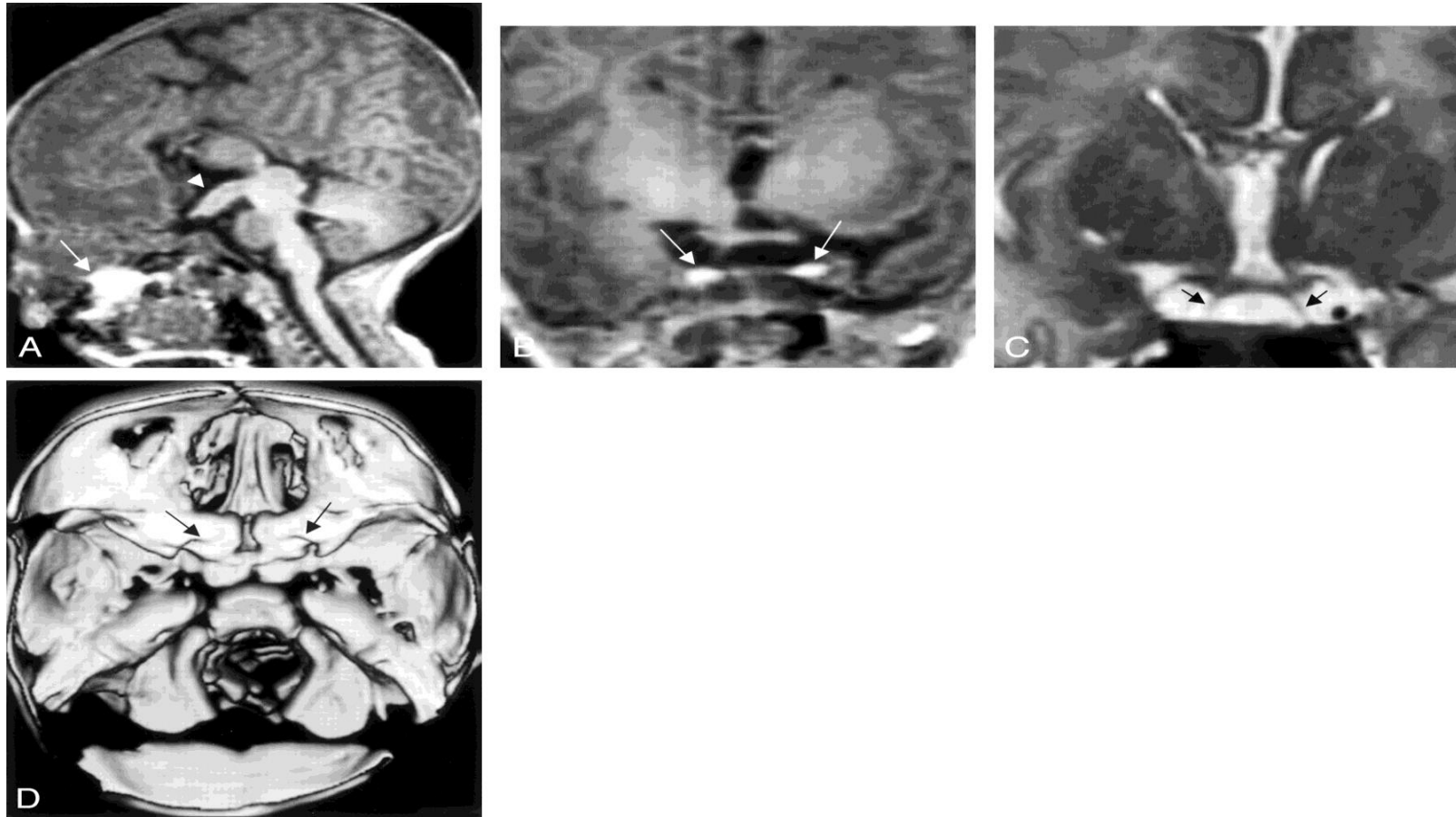
Congenital anomalies

Pituitary duplication

♂ 20d



Images from the case of a 2-day-old female patient who presented with a protruding whitish mass from the oral cavity (case 2).A, Sagittal view T1-weighted MR image shows tubomammillary fusion (short arrow) and the oral dermoid (long arrow).B, Coronal view T...

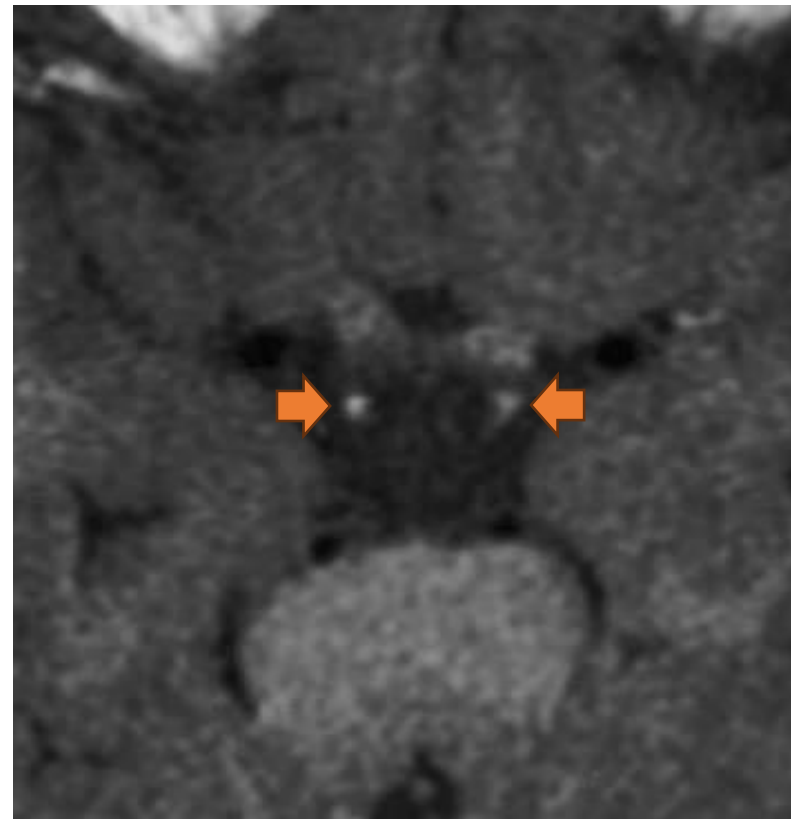
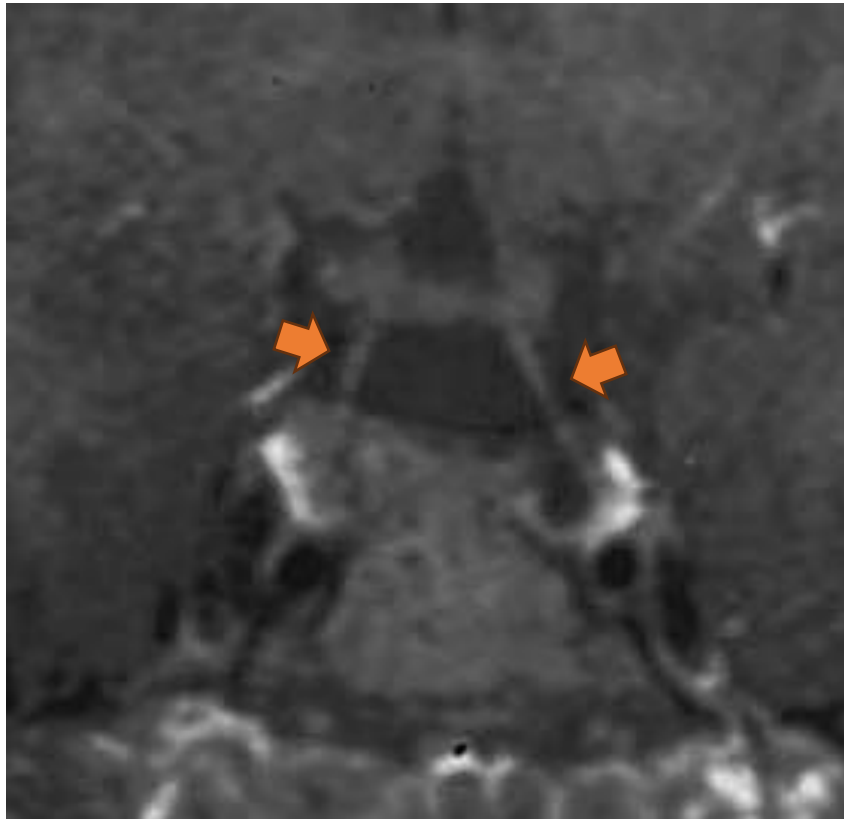


Manohar Shroff et al. AJNR Am J Neuroradiol 2003;24:956-961



Congenital anomalies

Duplicated Pituitary Gland





Hypothyroidism

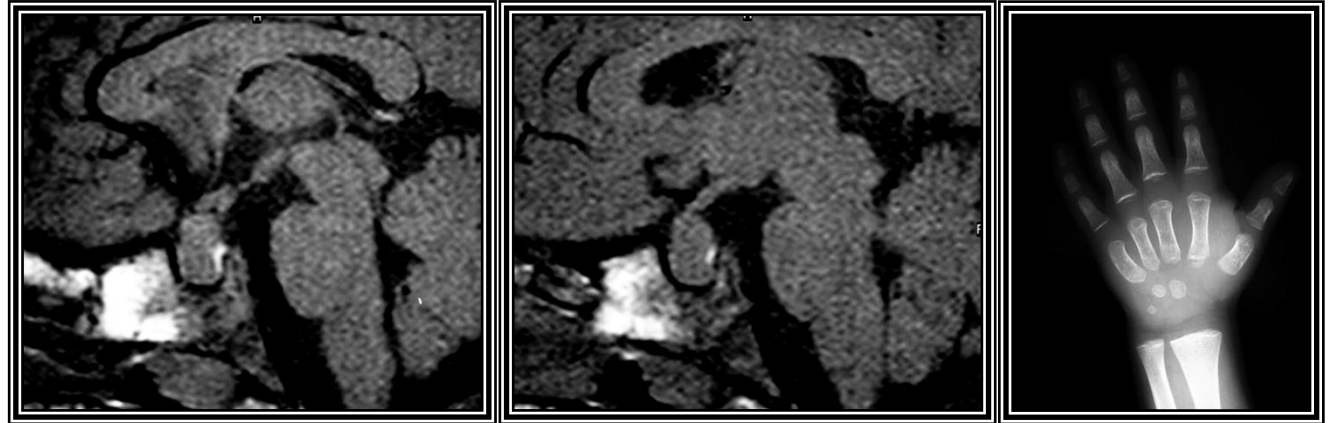
Congenital dysfunction with pituitary hyperplasia

High TSH

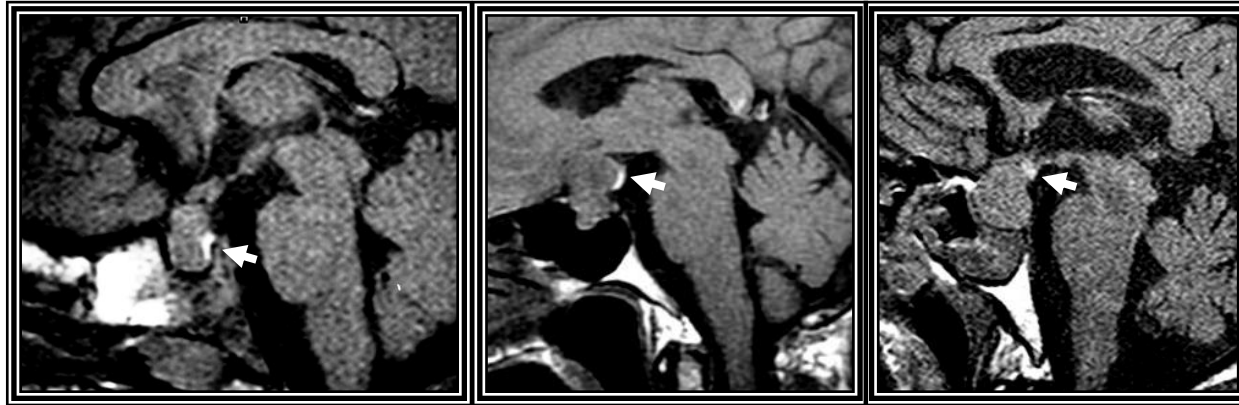
Reversible

Normal posterior lobe

♀, 5yo



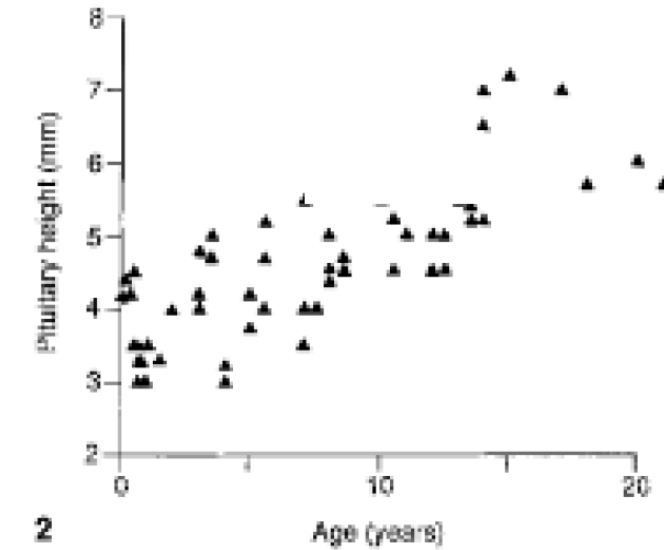
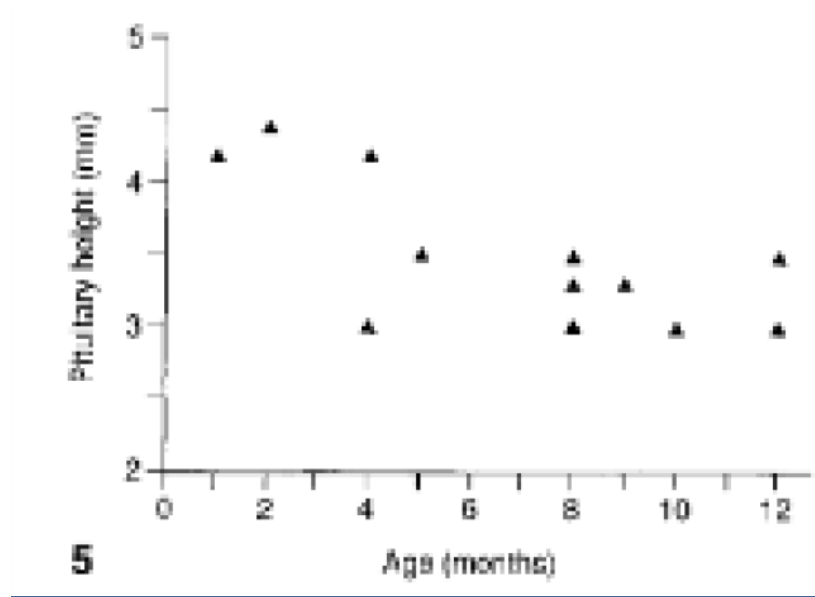
Ddx





Normal appearance

Height of the anterior lobe



Height

- < 6 mm
- Upper surface: flat or slightly concave

Thickness of the stalk

- 1 to 2 mm
- < 1 mm: hypoplasia
- > 2 mm: thick

Argyropoulou, M. et al. *Pediatr. Radiol.*, 1991.

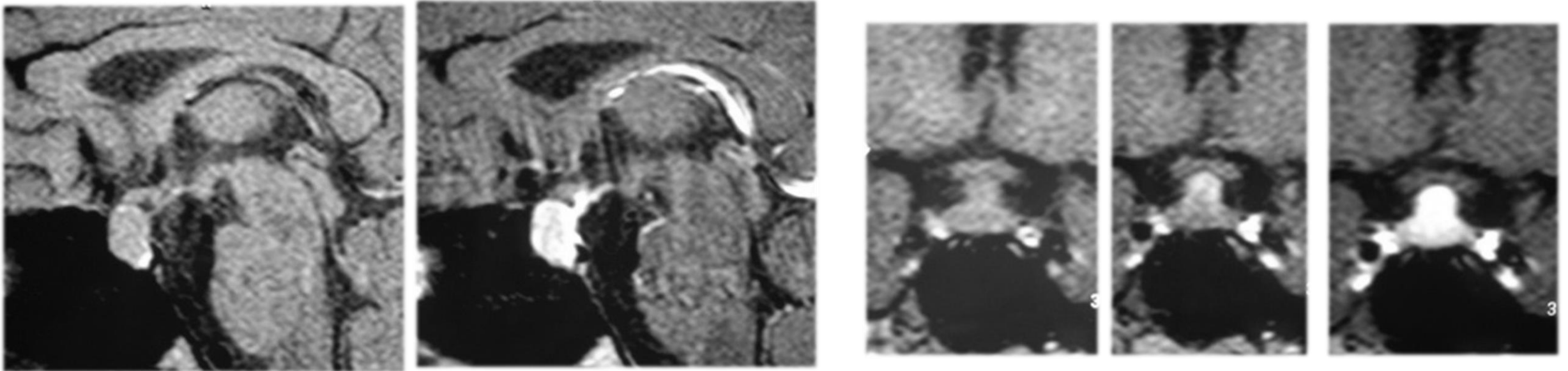
Okazaki, T. et al. *Brain Dev*, 2018.



Normal appearance

Transient Physiological Hyperplasia

- Puberty;
- Convex appearance, Girls++



♀, 14yo, headache



Introduction – Main Indications

- **Hormone hyposecretion**

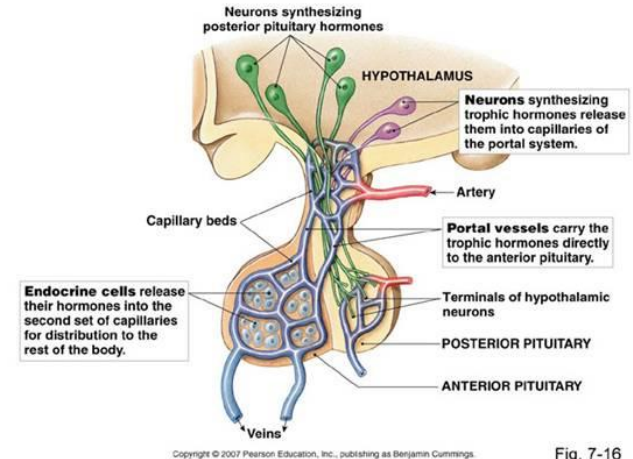
- Short stature +/- delayed puberty
- Central diabetes insipidus

- **Hormone hypersecretion**

- Central precocious puberty
- Acromegaly
- Hyperprolactinemia

- **Mass effect**

- Visual deficit: bipolar hemianopsia (chiasm)
- Hydrocephalus
- Hypothalamic dysfunction
 - epilepsy (gelastic seizures)
 - Abnormal behaviour
 - Eating disorders
 - Diencephalic syndrome: emaciation, pallor, alertness & hyperactivity = hypothalamic astrocytoma





Hyposecretion

Growth Hormone deficiency is the most frequent hormone deficiency in children

Causes of short stature

Normal growth velocity

- Familial short stature (short parents)
- Low birth weight
- Loss of growth in infancy related to illness
- Idiopathic short stature

Reduced growth velocity

Normal endocrinology with abnormal skeletal response

- Turner's syndrome
- Noonan's syndrome
- Down's syndrome
- Prader-Willi syndrome

Endocrine abnormalities

- Thyroid disease
- Abnormalities of the growth hormone–insulin-like growth factor 1 axis

Growth hormone deficiency

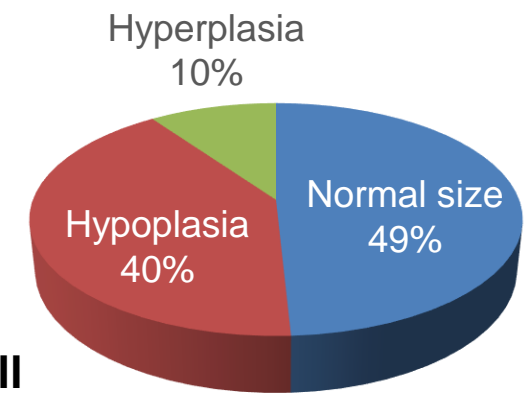
Growth hormone insensitivity (Laron's syndrome)

Abnormalities of insulin-like growth factor 1 secretion or action

Non-endocrine illness (e.g. gastrointestinal problems, chronic infection)

Psychosocial short stature

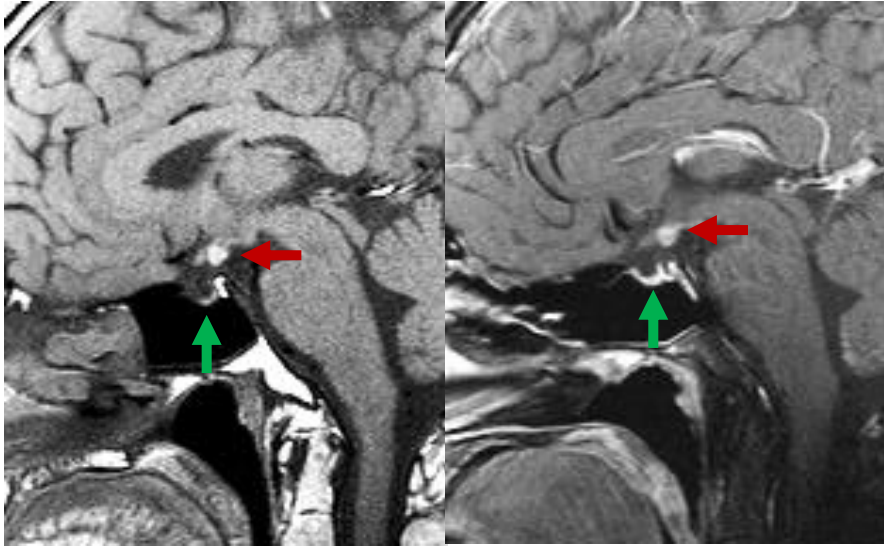
- **Reduced growth speed**
 - Neonate, infant: hypoglycemia (GH involved in osseous growth after 4 years)
- **Isolated Growth Hormone Deficiency (IGHD)**
 - Sporadic
 - Familial: GH1, GHRH mutation
- **Multiple Hormone deficits (MPHD)**
 - Combined Pituitary Hormone deficits (CPHD)
 - Familial: numerous mutations
- **Congenital hypopituitarism**
 - Look for malformations
 - Posterior pituitary, stalk
 - Whole brain study
- **Pituitary gland may be normal or small**



Adapted from: Nicola Bridges, *Medicine*, 2005.



Pituitary Stalk Interruption Syndrome



MRI is required for the diagnosis and demonstrates

Triad (Fujisawa *et al* Radiology 1987):

- ✓ thin or interrupted pituitary stalk,
- ✓ an ectopic or absent posterior pituitary lobe, and
- ✓ hypoplasia of the anterior pituitary gland

Clinico-radiological correlation of pituitary stalk interruption syndrome in children with growth hormone deficiency.

Sridhar S, Raja BR, Priyanka R *et al*.

[Pituitary. 2023 Oct;26\(5\):622-628. doi:10.1007/s11102-023-01351-2.](#)

- **PSIS:**

- It is a rare syndrome, with an estimated incidence of 0.5 in 100,000 births.
- Patients present early in life, either in the first decade of life with a deficiency of GH resulting in short stature or during puberty due to a lack of developing secondary sexual characteristics.
- Multiple pituitary hormone deficiencies might develop in the absence of ADH secretion preserved.
- There is an increased incidence of breech presentation and difficult delivery, and possible learning difficulties or seizures.

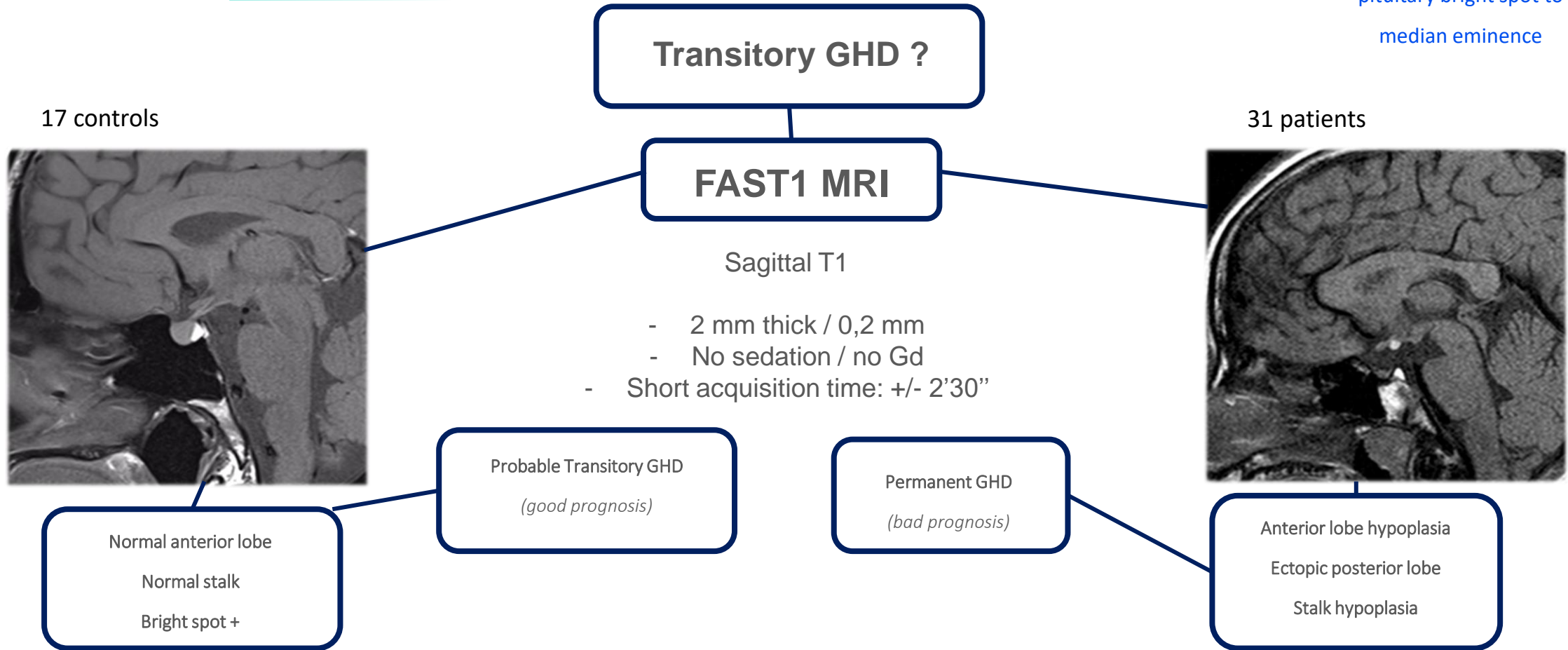
- **Pathology:**

- Various hypotheses have been proposed to explain the syndrome such as defective migration of the pituitary gland during intrauterine life or ischemia with subsequent reorganization of the infundibular axons and development of an ectopic posterior pituitary



Hypopituitarism

translocation of
pituitary bright spot to
median eminence



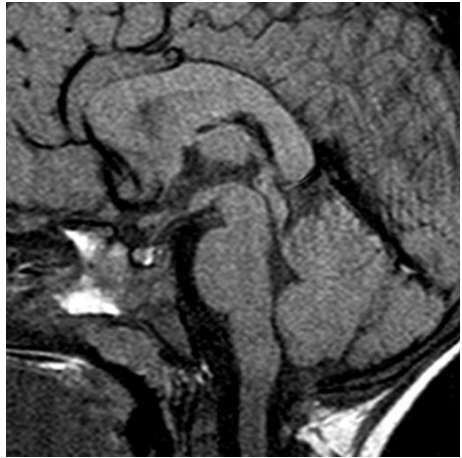
Fast acquisition sagittal T1 magnetic resonance imaging (FAST1-MRI): a new imaging approach for the diagnosis of growth hormone deficiency.

Longui CA, Rocha AJ, Menezes DM *et al.*

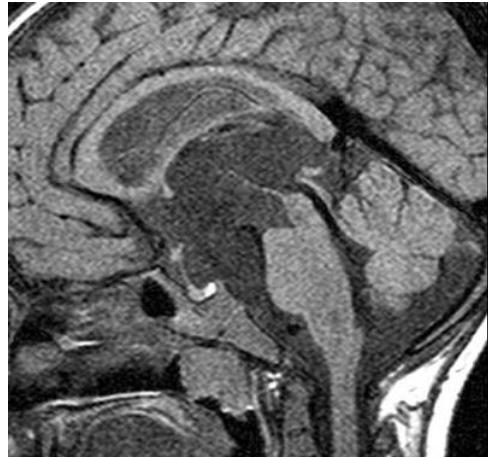
[J Pediatr Endocrinol Metab. 2004;17\(8\):1111–4. https://doi.org/10.1515/jpem.2004.17.8.1111.](https://doi.org/10.1515/jpem.2004.17.8.1111)



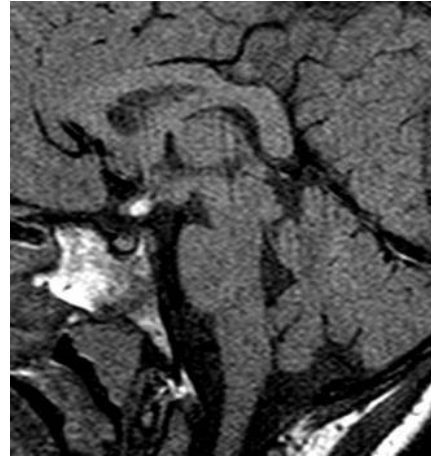
Hypopituitarism in FAST 1



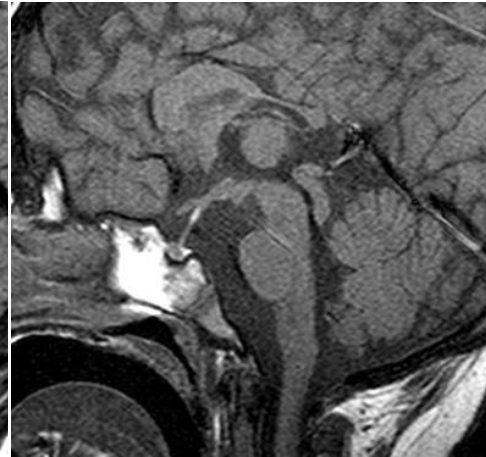
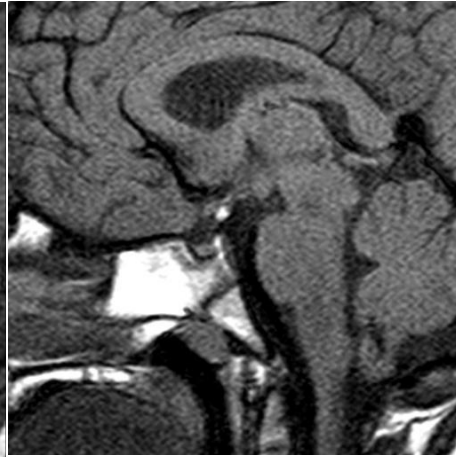
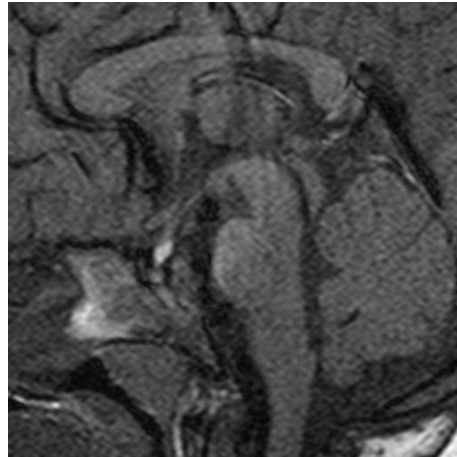
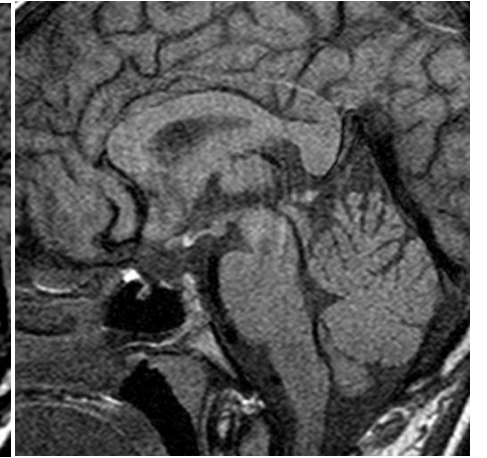
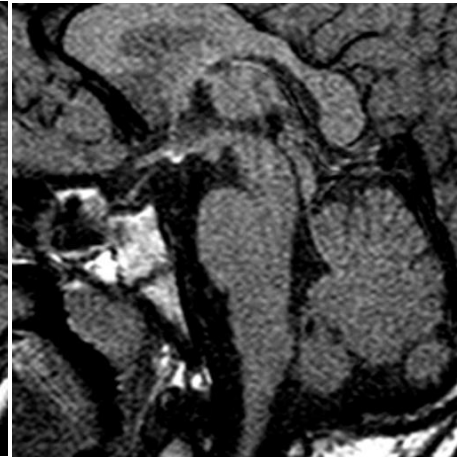
Normal MRI



Arachnoid cyst



Ectopic posterior pituitary lobe

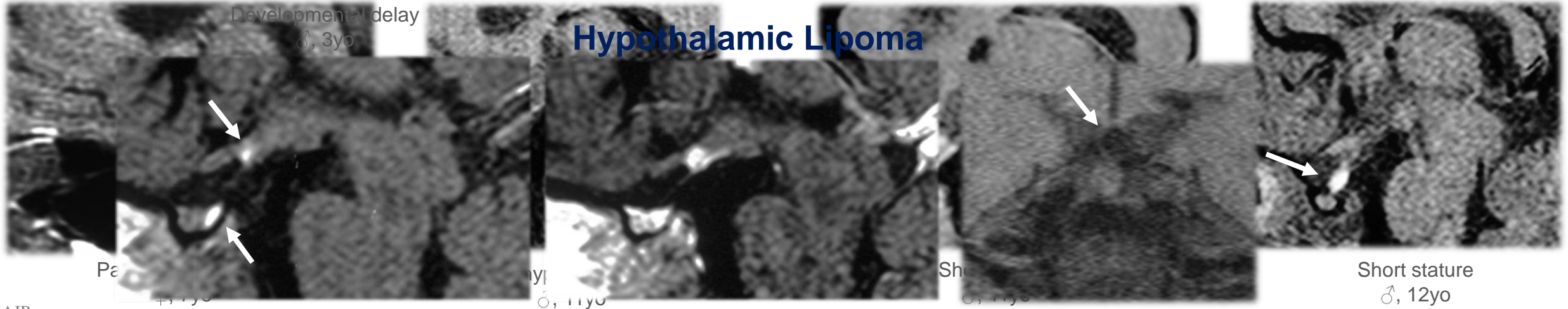
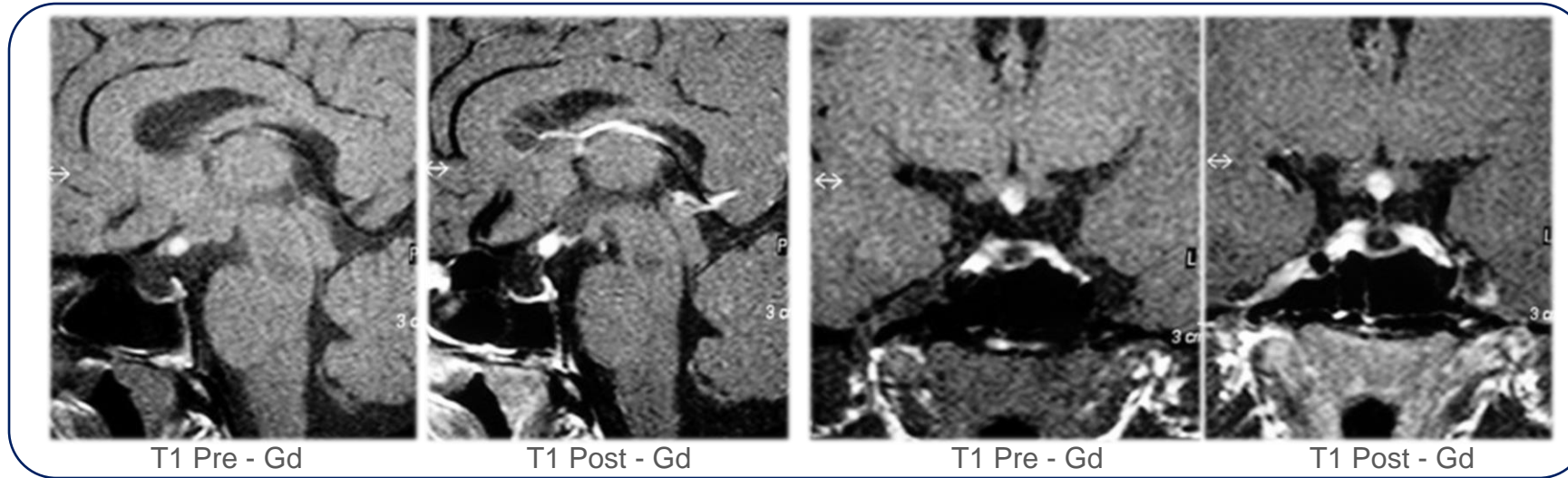




Pituitary Stalk Interruption Syndrome

Ectopic posterior lobe

Panhypopituitarism
♂, 9yo





Hypopituitarism

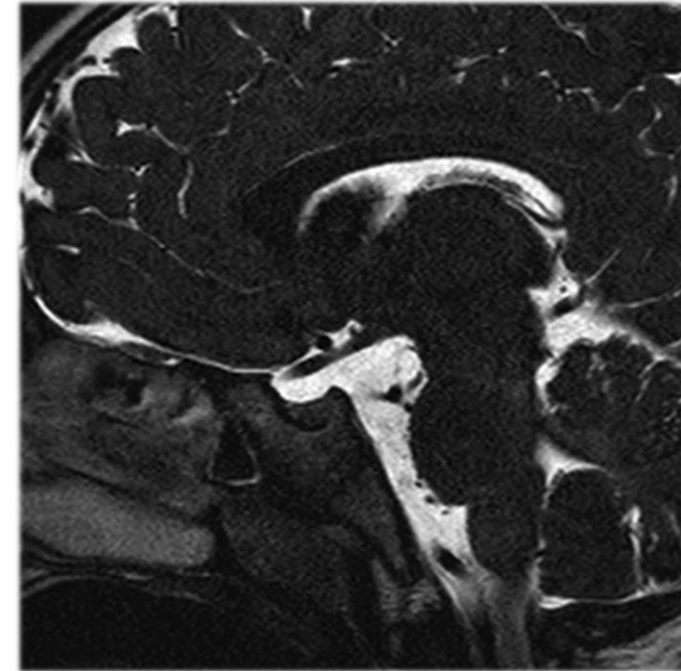
Screening – FAST1.2MRI

Sagittal T1

- 2mm thick / 0,2 mm
- No sedation / no Gd
- Short acquisition time: +/- 2:30 min.

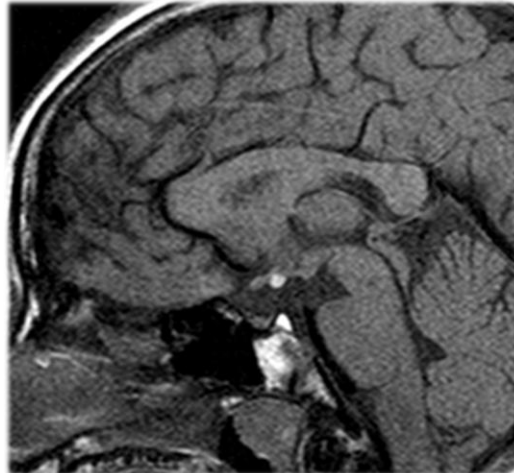
3D FIESTA / CISS / DRIVE – sella

PITUITARY STALK



**Permanent
GHD**

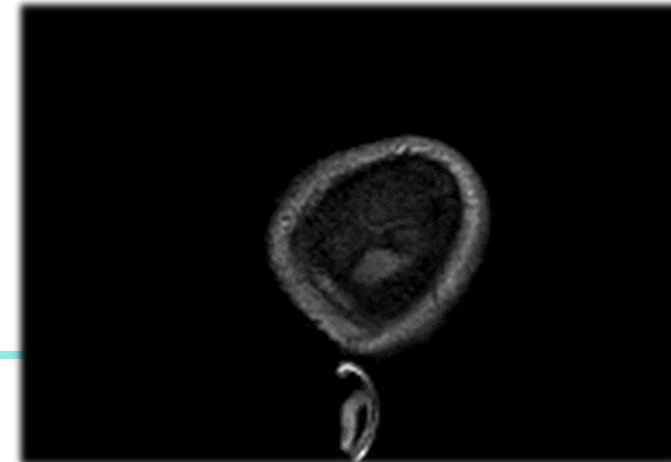
(bad prognosis)



Short stature
♂, 13yo

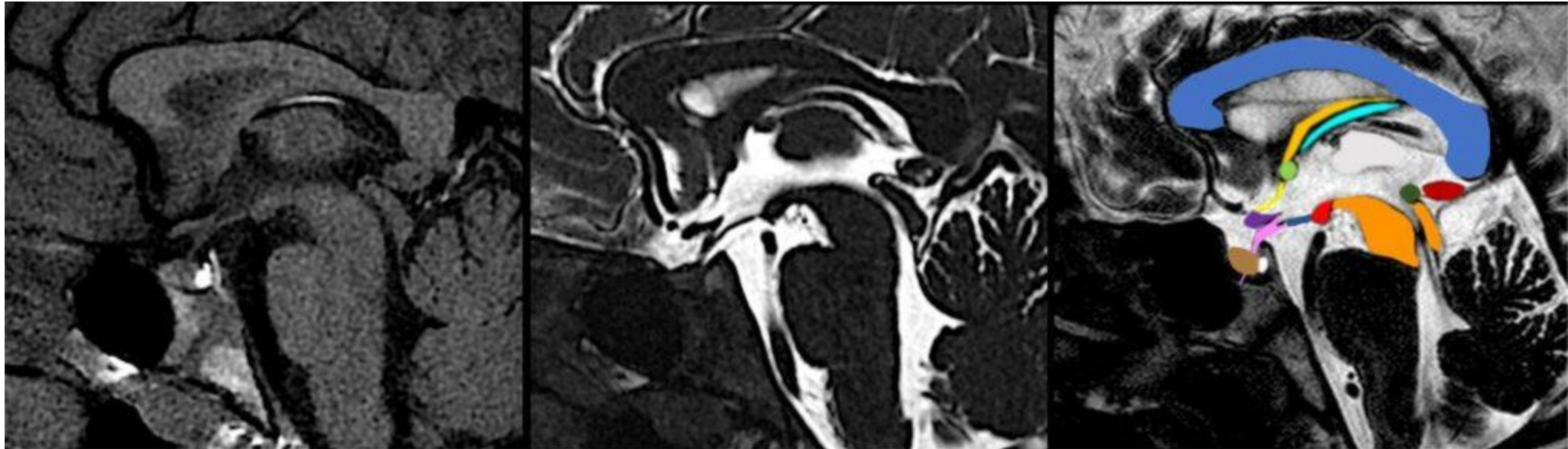
3D Sagittal T1 – whole brain

BRAIN MALFORMATIONS





IMAGING ANATOMY OF PITUITARY-HYPOTHALAMIC AXIS



Adding T2-Weighted Images to FAST1 Protocol to Evaluate the Anatomy of the Hypothalamic-Pituitary Region.

Meira AS, Lyra A, Kochi C *et al.*

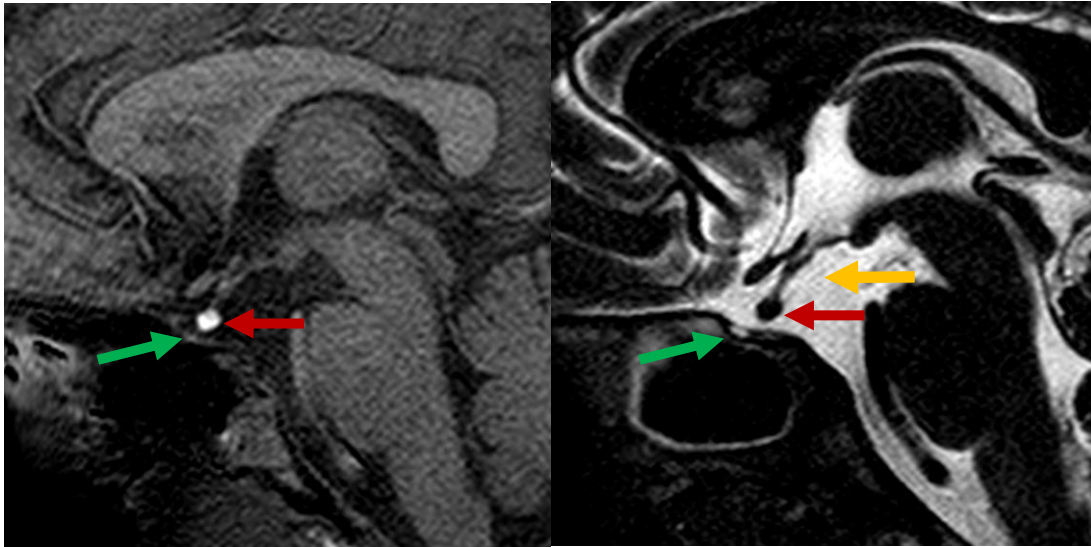
[Horm Res Paediatr \(2022\) 95 \(3\): 244–254. https://doi.org/10.1159/000524032.](https://doi.org/10.1159/000524032)



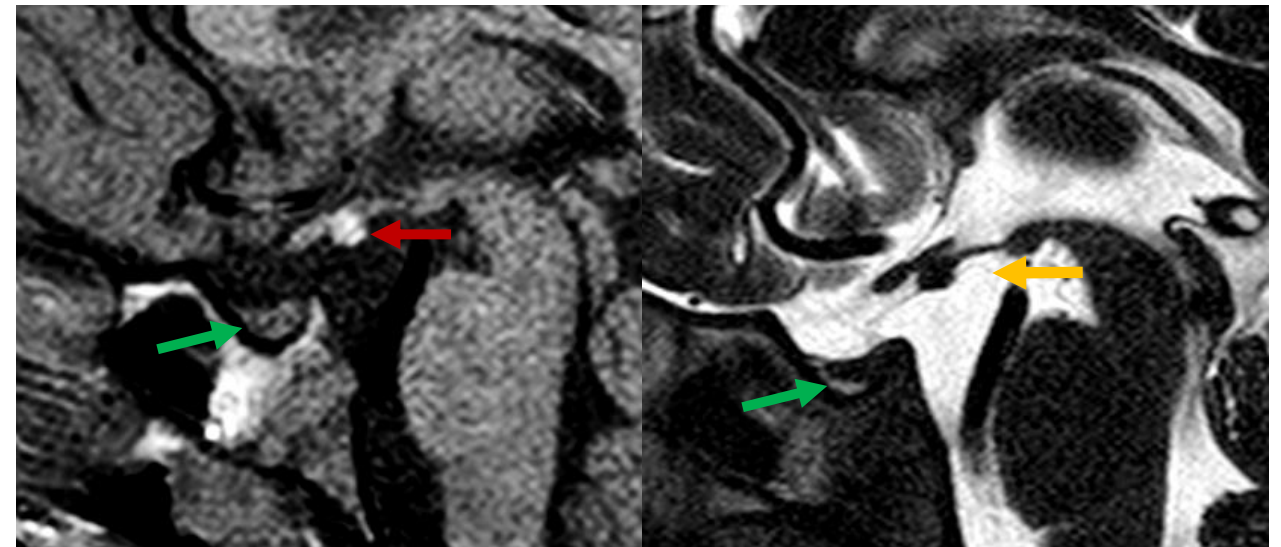
Hypopituitarism in FAST 1.2

Pituitary Stalk Interruption Syndrome

♀ 11 y-o



♂ 7 y-o



partially empty sella + ectopic posterior pituitary (median eminence) and interrupted pituitary stalk

Adding T2-Weighted Images to FAST1 Protocol to Evaluate the Anatomy of the Hypothalamic-Pituitary Region.

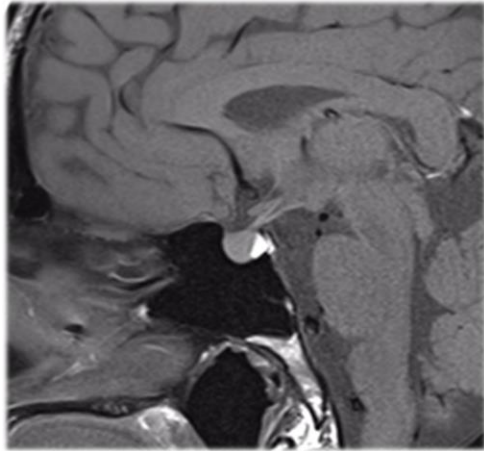
Meira AS, Lyra A, Kochi C *et al.*

[Horm Res Paediatr \(2022\) 95 \(3\): 244–254. https://doi.org/10.1159/000524032.](https://doi.org/10.1159/000524032)



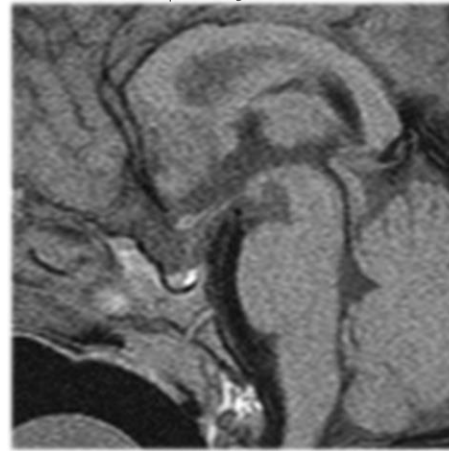
Hypopituitarism – MRI presentation

♂, 9yo



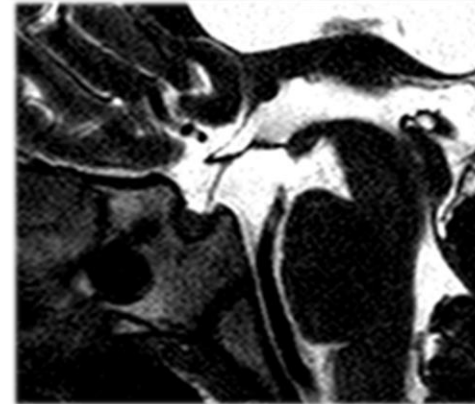
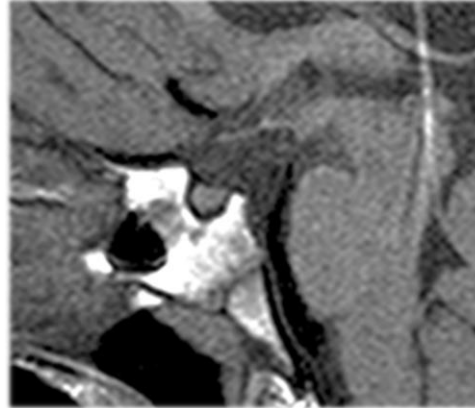Anterior lobe normal
Bright spot +
Stalk normal

♀, 5yo



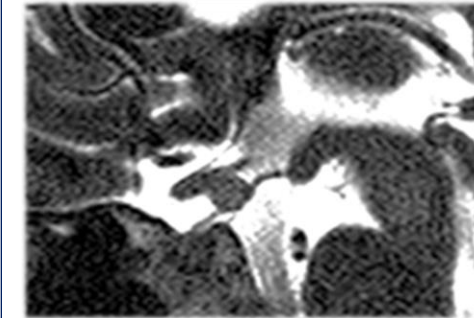
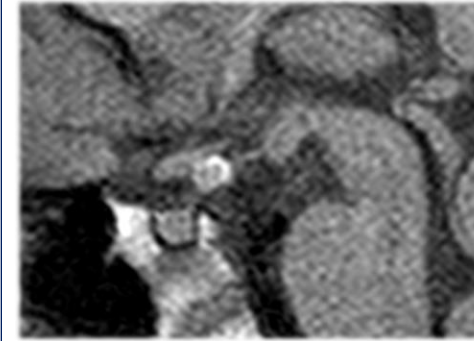
Anterior lobe - small
Bright spot +
Stalk - thin

♀, 14yo



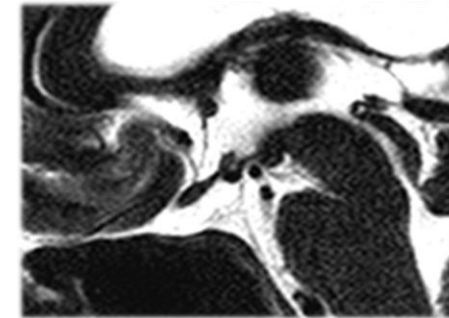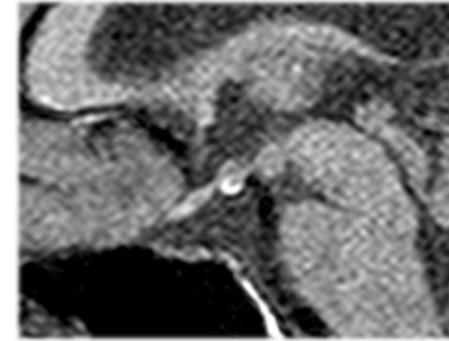
Anterior lobe normal
Bright spot -
Stalk - thin

♂, 15yo



Anterior lobe normal
Ectopic post. lobe
Stalk - thin

♂, 8yo



Ant. lobe - small
Ectopic post. lobe
Stalk - absent

Good prognosis

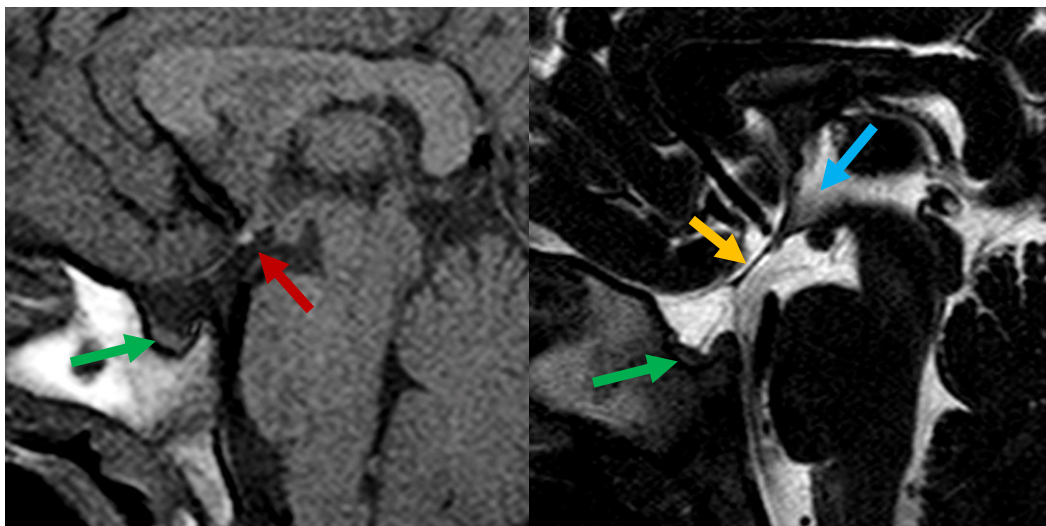
Bad prognosis
PSIS (pituitary stalk interruption syndrome)



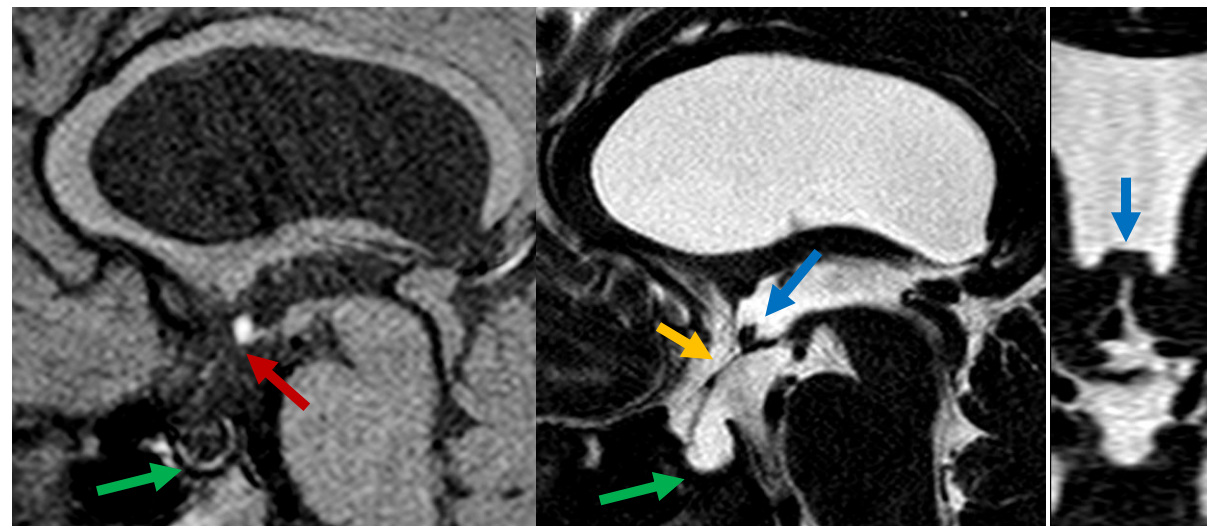
Hypopituitarism in FAST 1.2

imaging spectrum of Septo-optic dysplasia

♂ 4 y-o



♂ 9 y-o



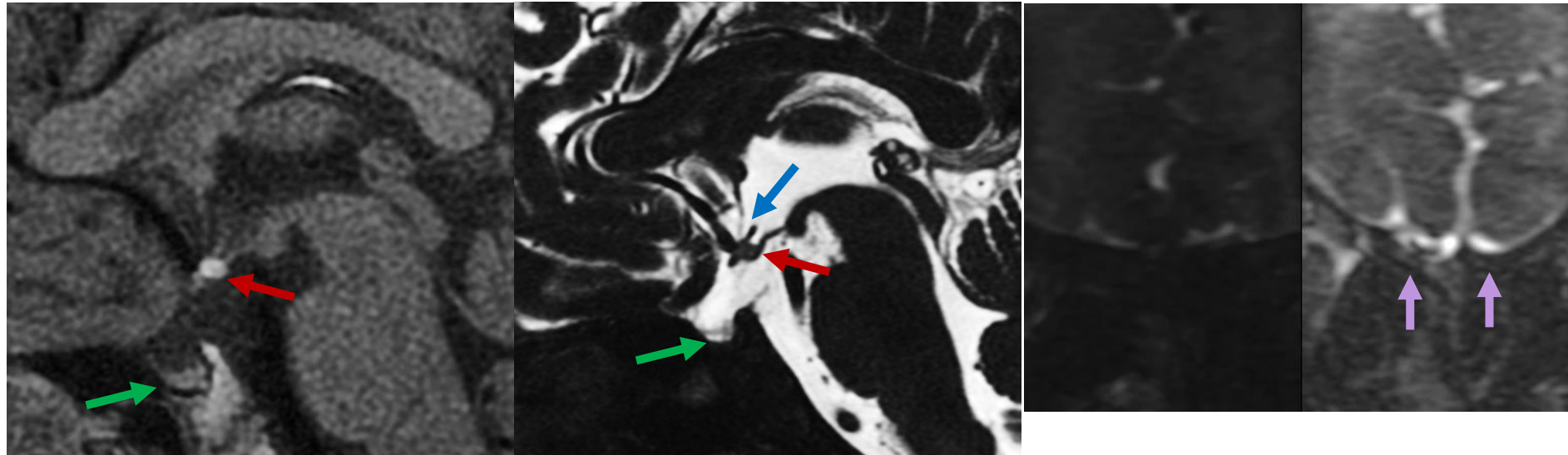
Adding T2-Weighted Images to FAST1 Protocol to Evaluate the Anatomy of the Hypothalamic-Pituitary Region.

Meira AS, Lyra A, Kochi C *et al.*

[Horm Res Paediatr \(2022\) 95 \(3\): 244–254. https://doi.org/10.1159/000524032.](https://doi.org/10.1159/000524032)



Pituitary Stalk Interruption Syndrome



- **Kallmann syndrome:**

- a rare genetic neuronal migration disorder of olfactory axons and gonadotropin-releasing hormone-producing neurons.
- The estimated incidence is 1 in 10,000 men and 1 in 50,000 women. Most cases are sporadic.
- KS is characterized by congenital hypogonadotropic hypogonadism and hyposmia/anosmia + MRI absent or hypoplastic olfactory bulbs and olfactory sulci, with or without hypoplastic anterior pituitary.

Kallmann syndrome: MRI findings.

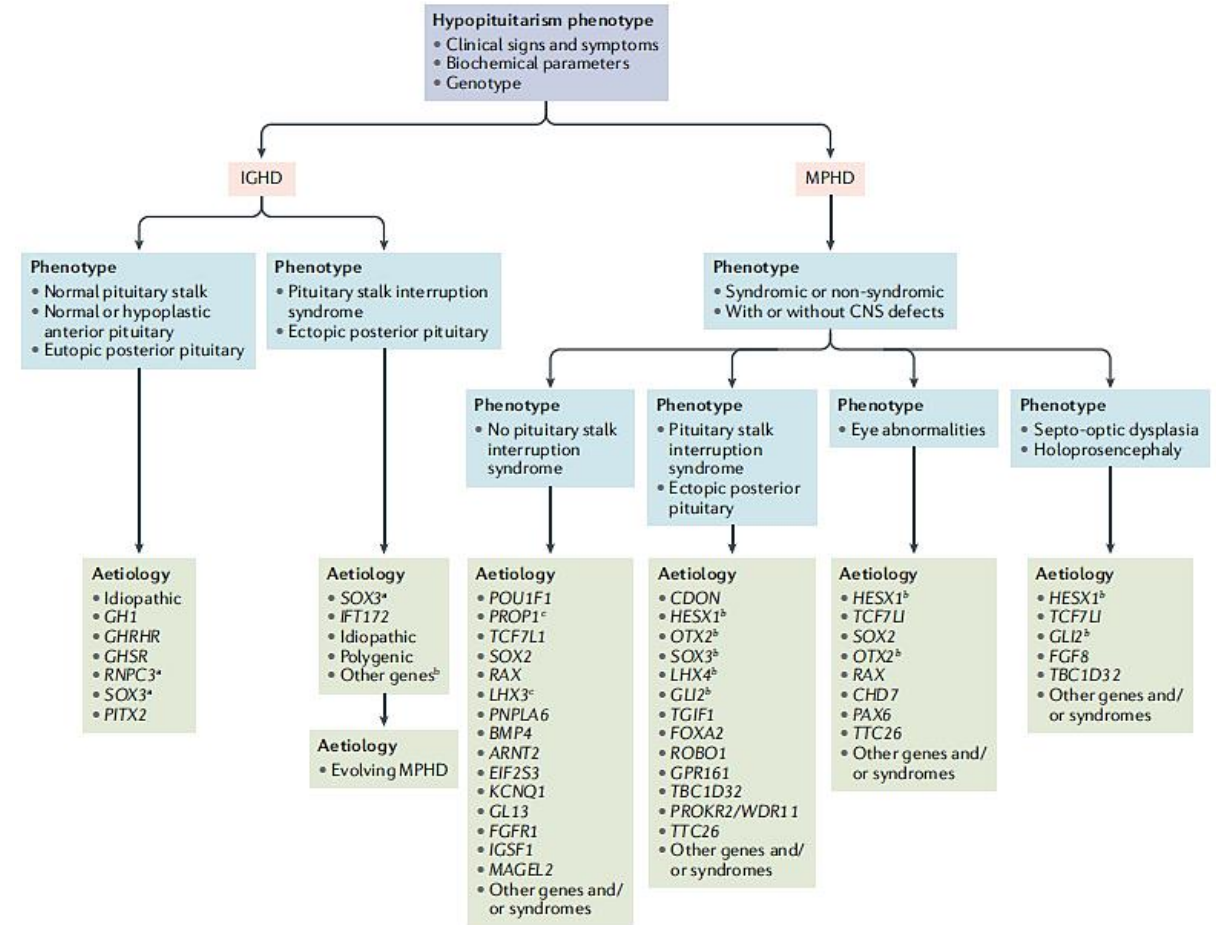
Zaghouani H, Slim I, Zina NB *et al.*

[Indian J Endocrinol Metab. 2013 Oct;17\(Suppl1\):S142–S14. doi: 10.4103/2230-8210.119536.](#)



Phenotype-genotype correlation

- Growth hormone (GH) affects growth, body composition, metabolic profile, bone mineral density and quality of life; a secretory defect leads to impaired growth and function, known as GH deficiency (GHD).
- GHD can occur in isolation (isolated GHD, IGHD) or in conjunction with other pituitary hormone deficits (multiple pituitary hormone deficiency, MPHD); GHD might be congenital or acquired.
- GHD is familial in 3–30% of affected patients: in IGHD, the most commonly mutated genes are *GH1* or *GHRHR*, whereas MPHD can be caused by mutations in several pituitary-specific transcription factors.
- Congenital hypothalamic–pituitary abnormalities confirmed via imaging, such as anterior pituitary hypoplasia, pituitary stalk anomalies and ectopic posterior pituitary, are common in both children with moderate to severe IGHD and those with MPHD.



Advances in differential diagnosis and management of growth hormone deficiency in children.

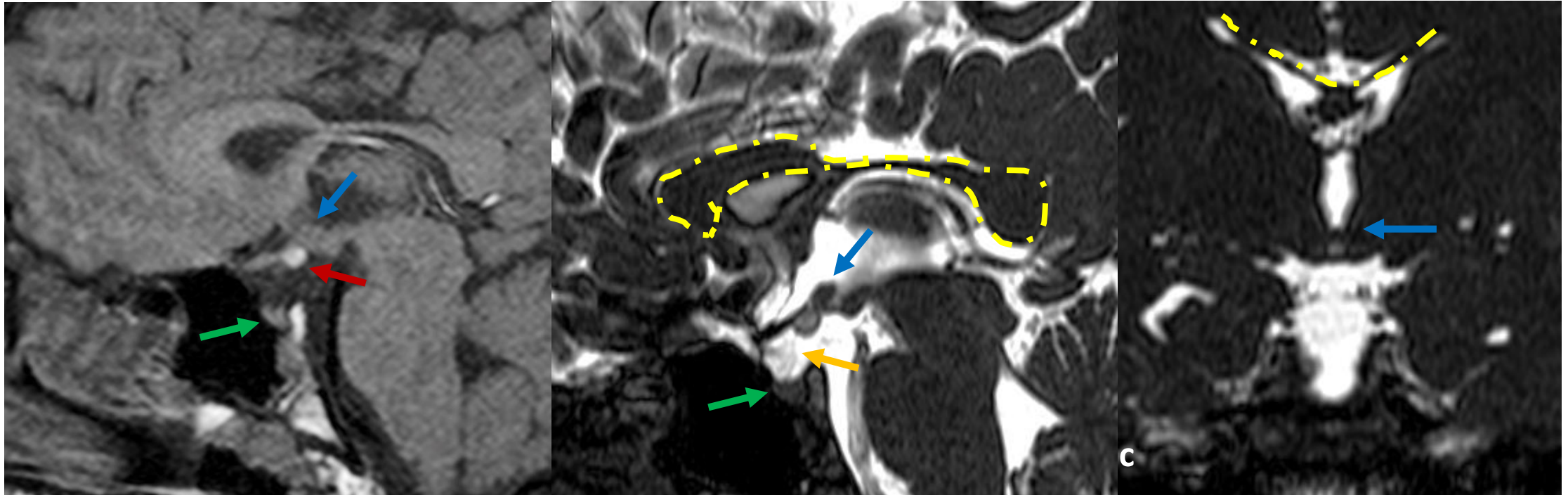
Hage C, Gan H-W, Ibba A *et al.*

[Nat Rev Endocrinol. 2021 Oct;17\(10\):608-624. doi: 10.1038/s41574-021-00539-5.](https://doi.org/10.1038/s41574-021-00539-5)



Pituitary Stalk Interruption Syndrome

♂ 12 y-o



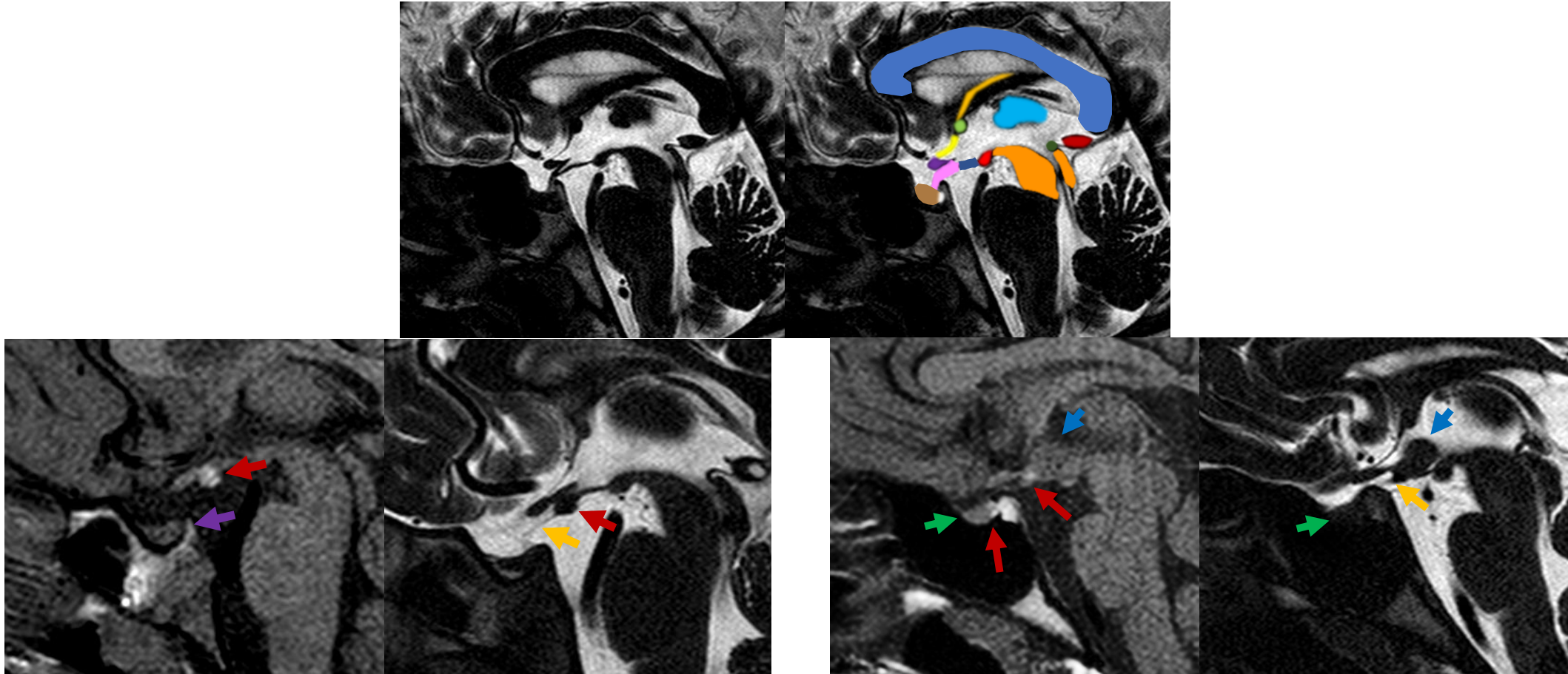
Extra-pituitary midline structural abnormalities associated with ectopic posterior pituitary detected on a new rapid MRI protocol (FAST1.2).

Lyra A, Guimarães DF, Meira *et al.*

[Arch Endocrinol Metab. 2022 Aug 4;66\(6\):831–836. doi: 10.20945/2359-3997000000505.](#)



Extra-pituitary midline structural abnormalities associated with ectopic posterior pituitary

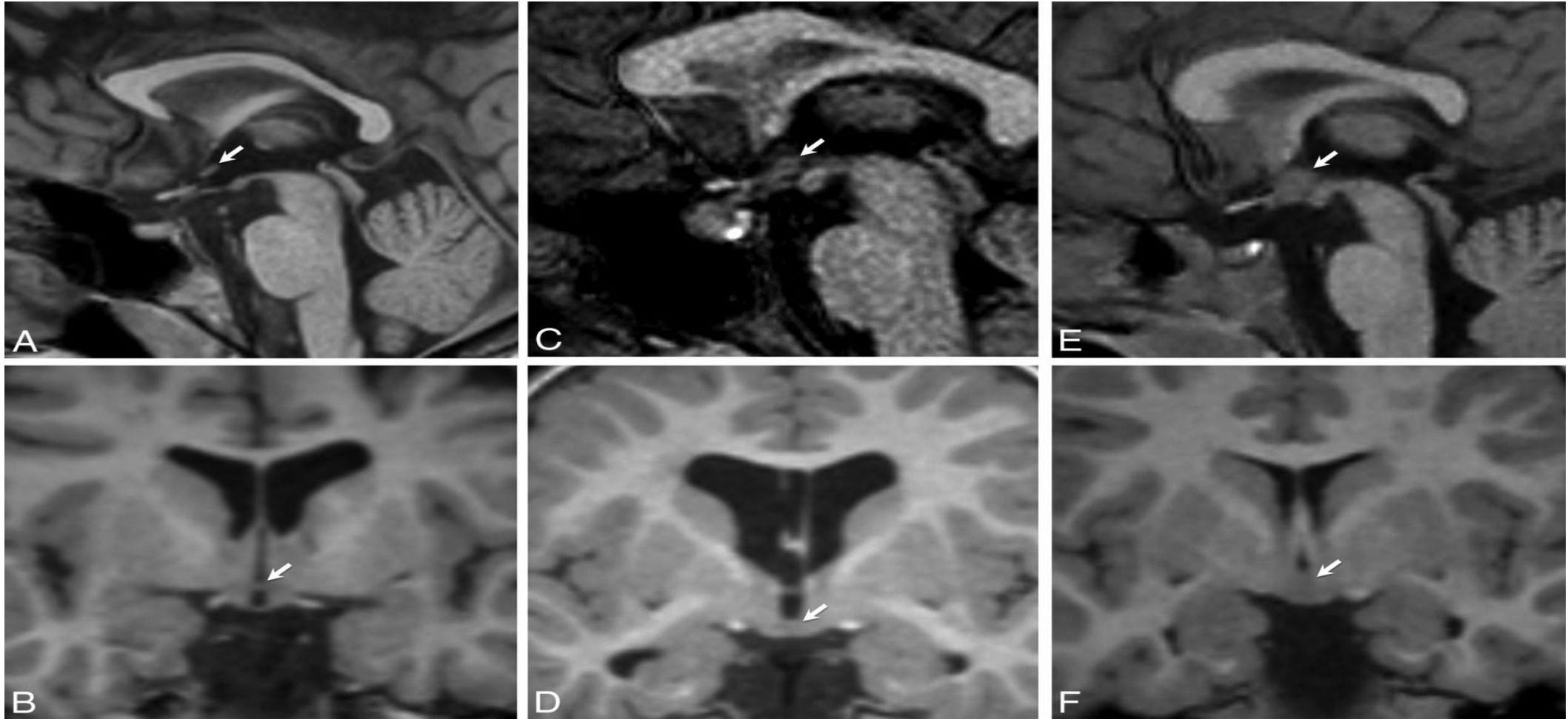


Extra-pituitary midline structural abnormalities associated with ectopic posterior pituitary detected on a new rapid MRI protocol (FAST1.2).

Lyra A, Guimarães DF, Meira *et al.*

[Arch Endocrinol Metab. 2022 Aug 4;66\(6\):831–836. doi: 10.20945/2359-3997000000505.](#)

A band of tissue spanning the anterior recess of the third ventricle that appeared linear in the axial and coronal planes and nodular in the sagittal plane as seen on 3T T1WI.



F.N. Ahmed et al. AJNR Am J Neuroradiol 2016;37:726-729





Interhypothalamic adhesions

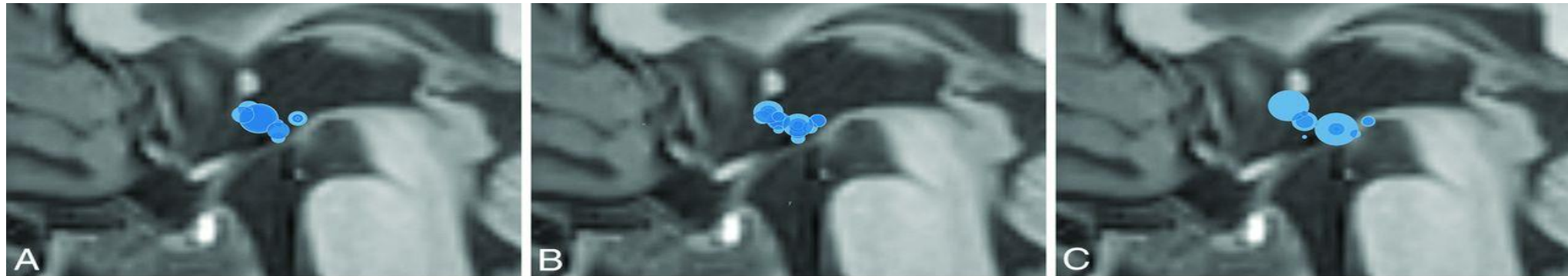- IHAs are tissue bands that connect the hypothalamus horizontally across the third ventricle.
- Characteristic appearance on a sagittal brain MRI as an additional small, ovoid structure between the fornices and lamina terminalis
- IHAs have been predominantly reported in the pediatric population and have not been documented in adults. As a potential explanation for this, we initially hypothesized that IHAs might involute as the brain grew, explaining the lack of reports in adults.
- IHAs are observed incidentally through the routine acquisition, mostly in the absence of other structural abnormalities, specifically midline defects.
- Although the underlying etiology is unclear, it may be the result of incomplete hypothalamic cleavage, failed apoptosis, or abnormal neuronal migration, the latter being potentially more likely, given the association we found with GMH.
- An isolated IHA could represent form fruste holoprosencephaly, and as such, its presence should prompt a search for additional midline anomalies.
- Additional manifestations of holoprosencephaly may include ocular anomalies, cleft lip, cleft palate, absent septum pellucidum, falx cerebri hypoplasia, under-rotation of the hippocampi, and/or corpus callosum dysgenesis

Asymptomatic Interhypothalamic Adhesions in Children.

Ahmed FN, Stence NV, Mirsky DM.

[AJNR Am J Neuroradiol. 2016 Apr;37\(4\):726–729. doi: 10.3174/ajnr.A4602.](#)

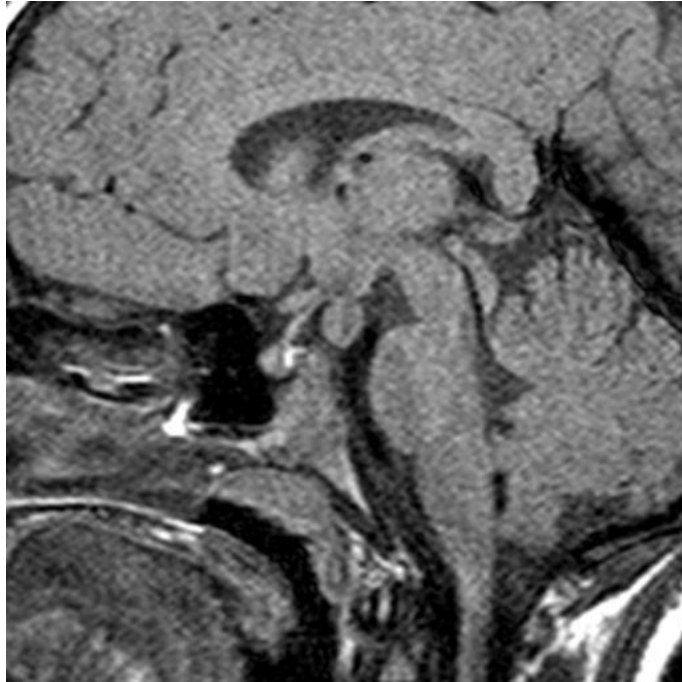
Position maps of the interhypothalamic adhesions.



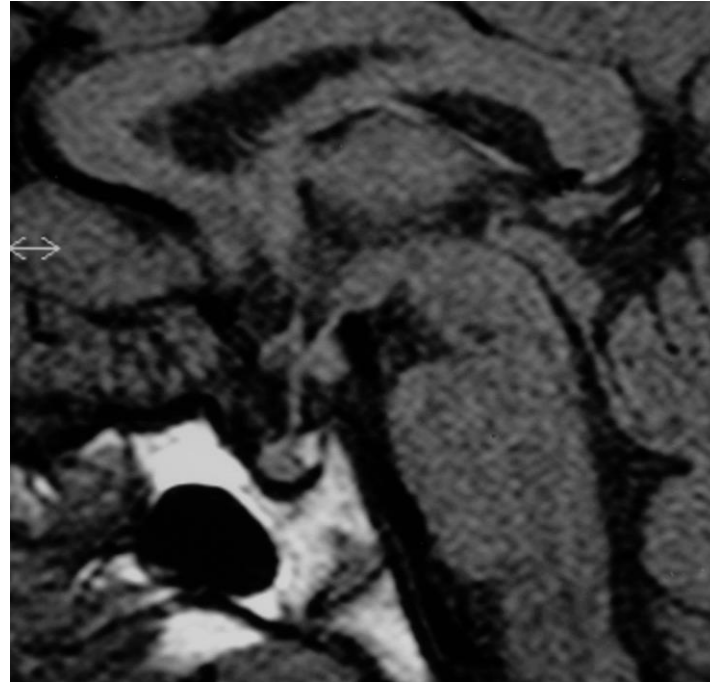
F.N. Ahmed et al. AJNR Am J Neuroradiol 2016;37:726-729



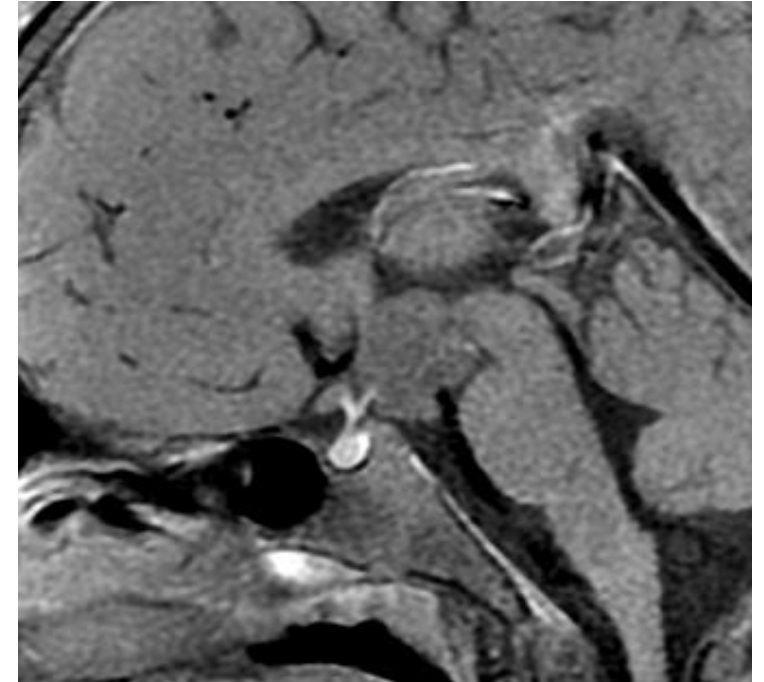
Hypothalamic hamartoma



♀, 7yo



♀, 9yo

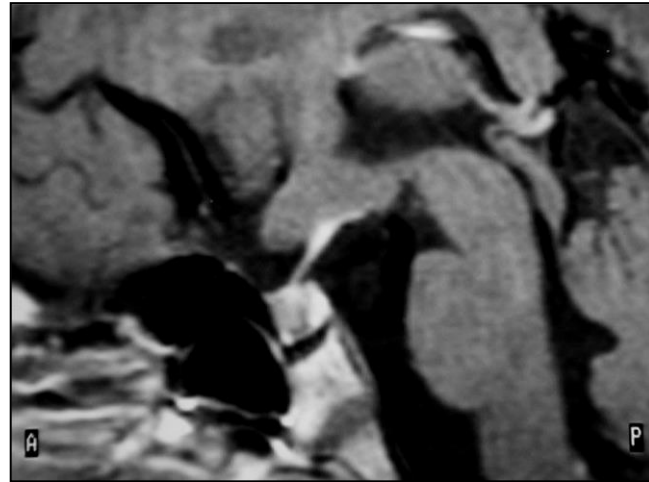
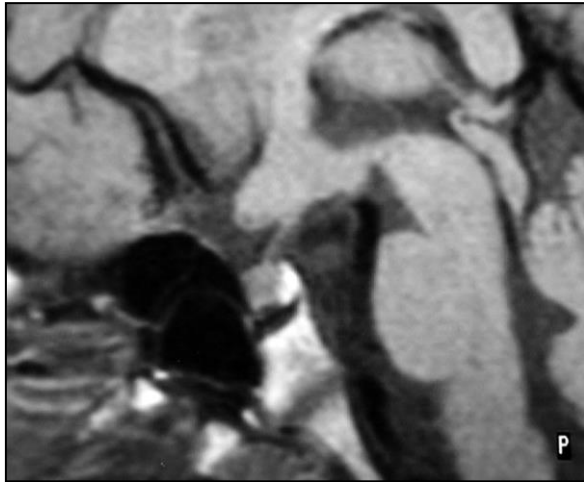


♀, 8yo



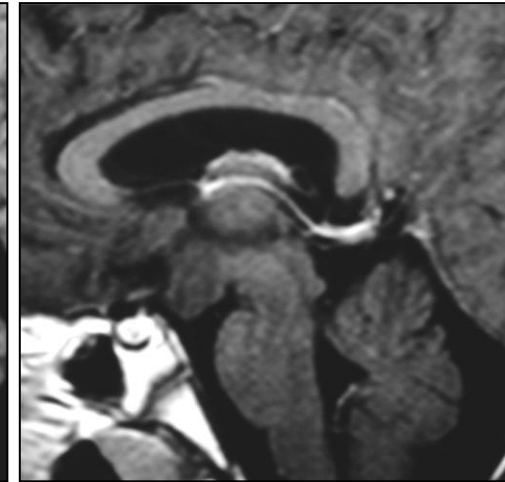
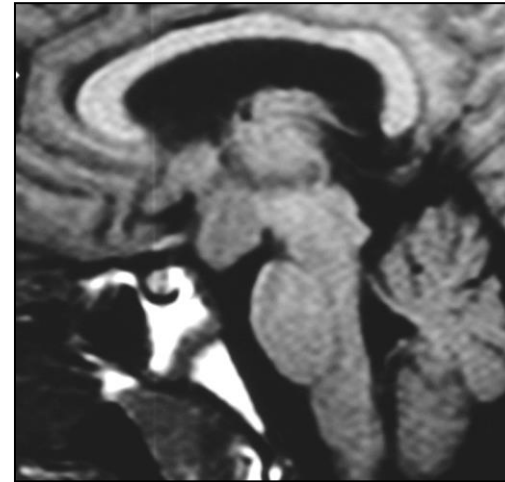
Hypothalamic hamartoma

Optic Pathway Gliomas in NF 1

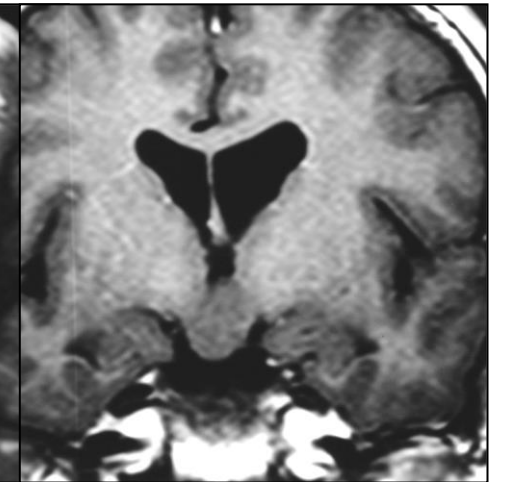
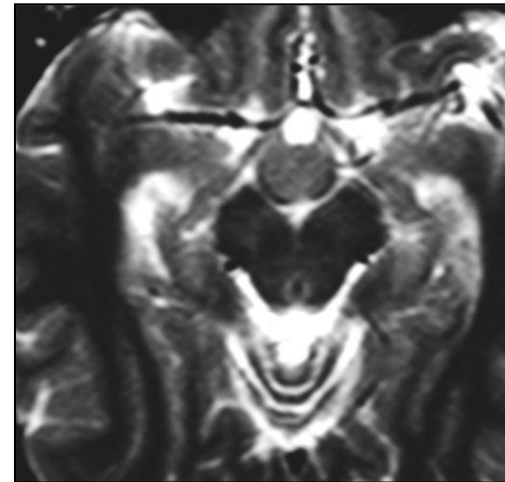


♀, 7yo,
Short stature,
café-au-lait spots,
visual imparment

Hypothalamic hamartoma

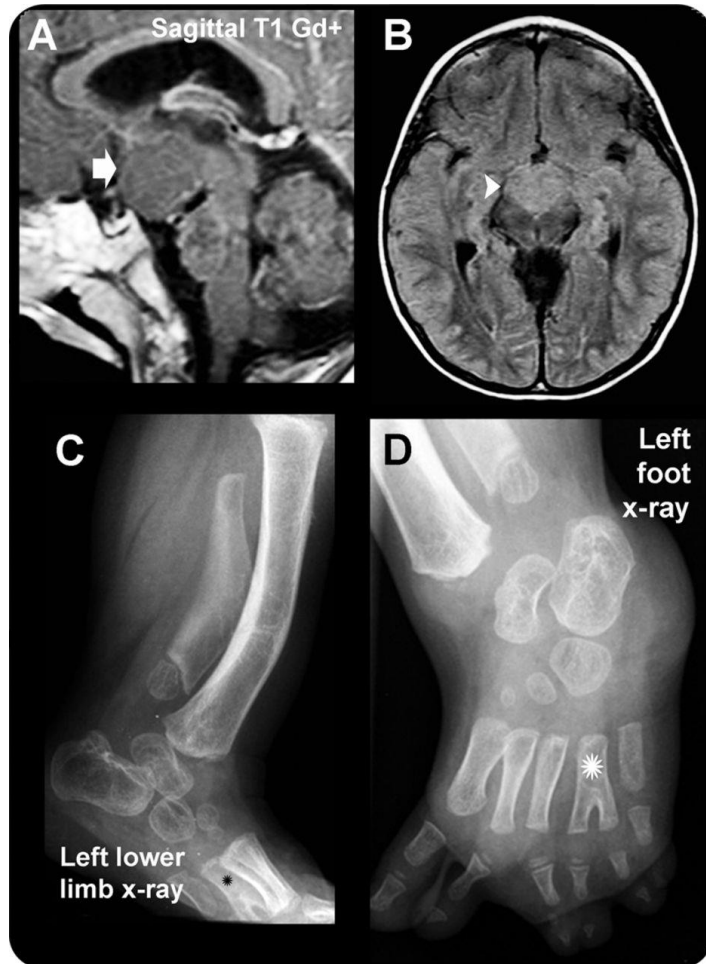


♀, 5yo
Precocious puberty and
gelastic epileptic
seizures

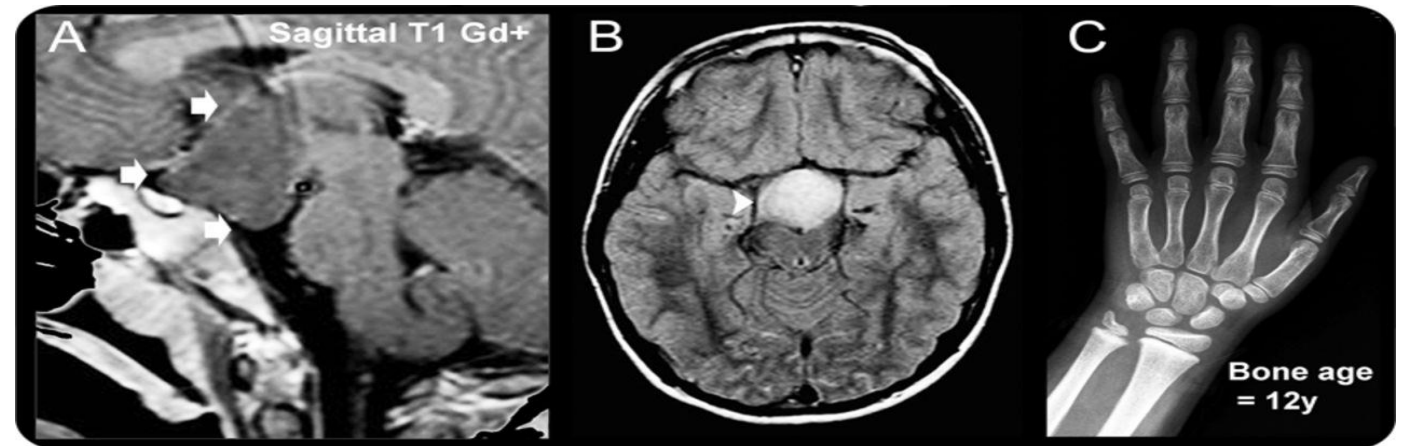


Hypothalamic hamartoma

Pallister-Hall syndrome (2-year-old boy)(A, B) MRI confirmed nonenhancing hypothalamic hamartoma (arrow) that was isointense to gray matter on fluid-attenuated inversion recovery (arrowhead).



Isolated hypothalamic hamartoma (HH) (3-year-old boy) with gelastic epilepsy and precocious puberty(A, B) MRI confirmed nonenhancing HH (arrows).



Antonio J. da Rocha et al. Neurology 2012;79:950-951

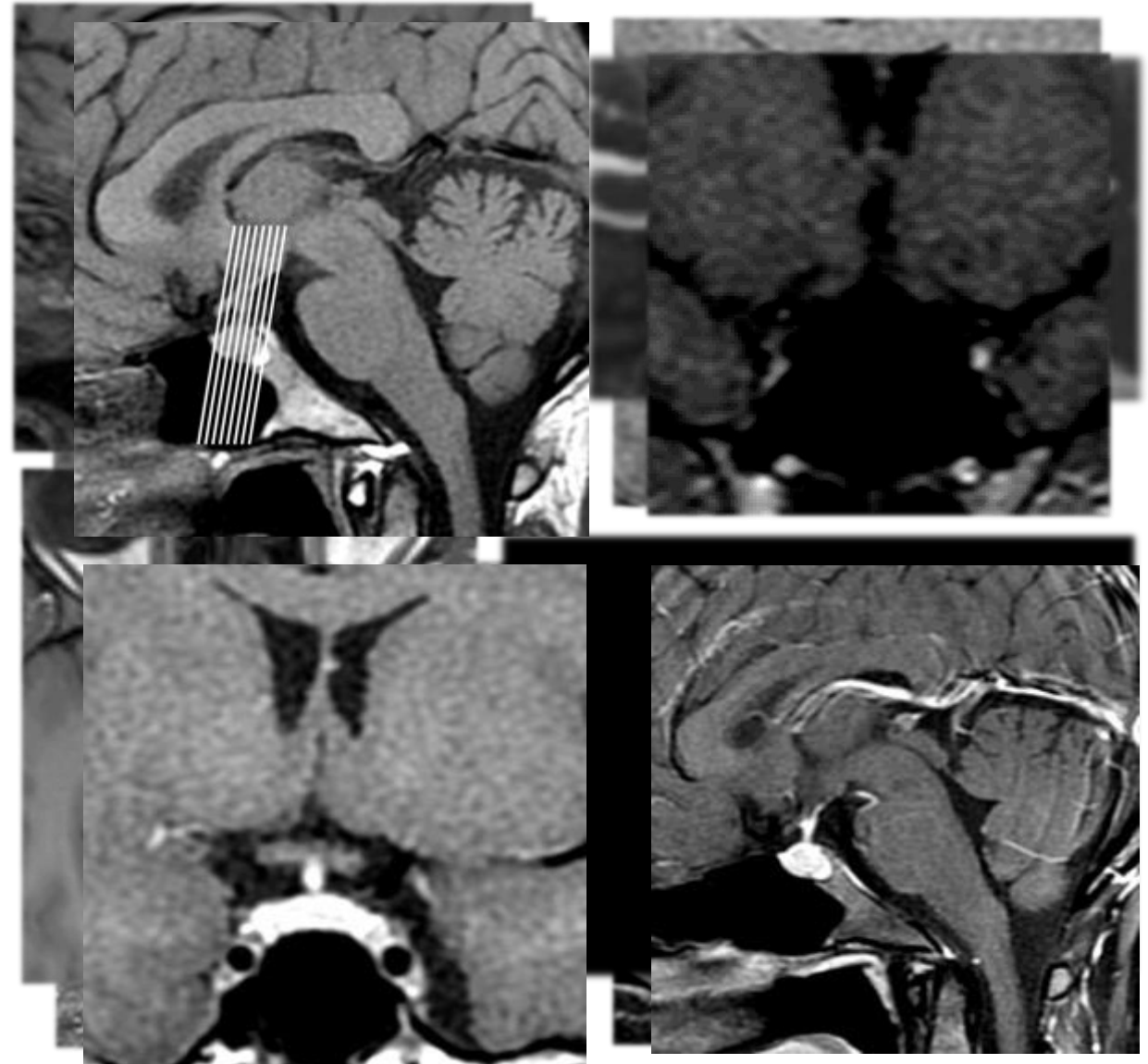

Imaging protocol

MRI

Plane	Sequence Name
Sagittal	T1 3D sagittal
Axial	T2 fluid-attenuated inversion recovery (FLAIR) axial
Axial	T2 axial (no fat saturation)
Axial	Diffusion tensor imaging
Coronal	T1 coronal thin (pituitary)
Sagittal	T1 sagittal thin (pituitary)
Contrast bolus 1 × dose (0.1 mmol/kg): 1 cc/sec, dynamic pituitary if ordered	
Coronal	T1 postcoronal thin (pituitary)
Sagittal	T1 postsagittal thin (pituitary)
Axial	T1 axial post

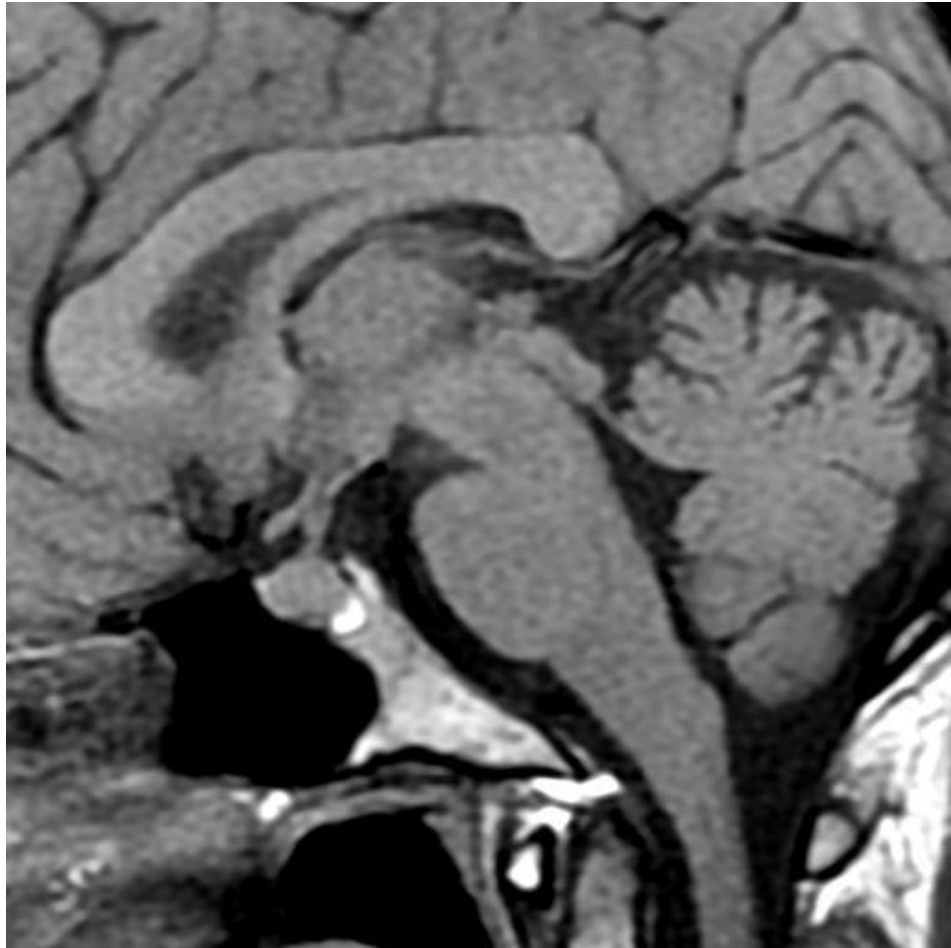
Adapted from: Seeburg, P. D. et al. *Neuroimag Clin N Am*, 2017.



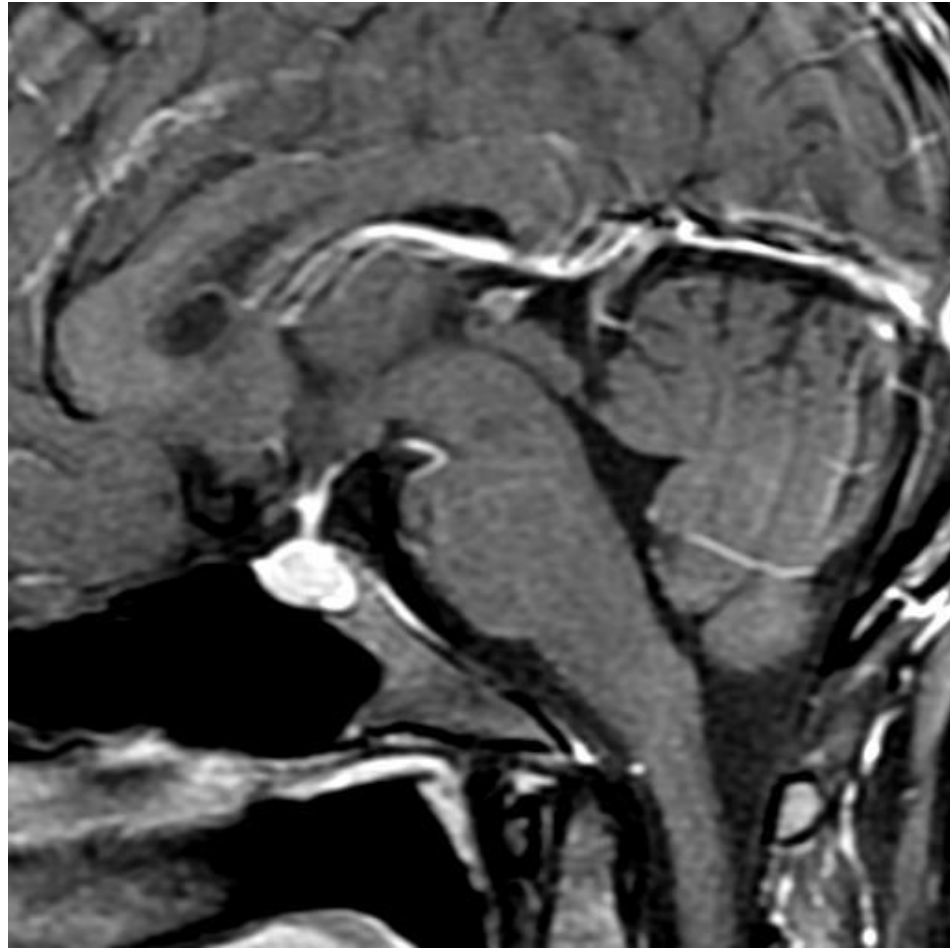


Normal appearance

SAGITAL T1



SAGITAL T1 Gd





Hyposecretion

Pubertal Delay

- Hypogonadotropic hypogonadism
- Congenital
 - Anosmic (Kallman syndrome):
 - Mutations within KAL1, FGFR1, FGF8 & PROKR2
 - normosmic isolated
- Acquired

Table 1 - Etiologies of Hypogonadotropic Hypogonadism (3).

Hyperprolactinemia
Pituitary lesions (tumor, granuloma, abscess)
Cushing syndrome
Drug use (opiates, alcohol abuse)
Anabolic steroids use
Severe or chronic illness
Pituitary irradiation, trauma or surgery
Iron overload
Kallmann syndrome
Idiopathic hypogonadotropic hypogonadism
Other genetic mutations
Prader Willi syndrome

Modified from Darby E, Anawalt BD. Male hypogonadism: an update on diagnosis and treatment. *Treat Endocrinol.* 2005;4(5):293-309.

From: Fraietta, R. et al, *Clinics*, 2013.

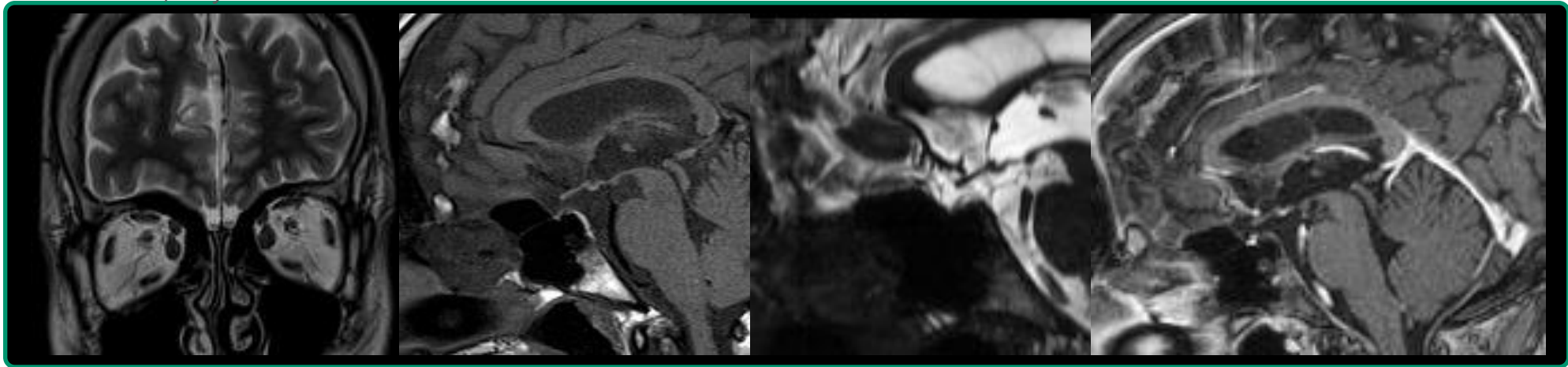


Hyposecretion

- Kallman**

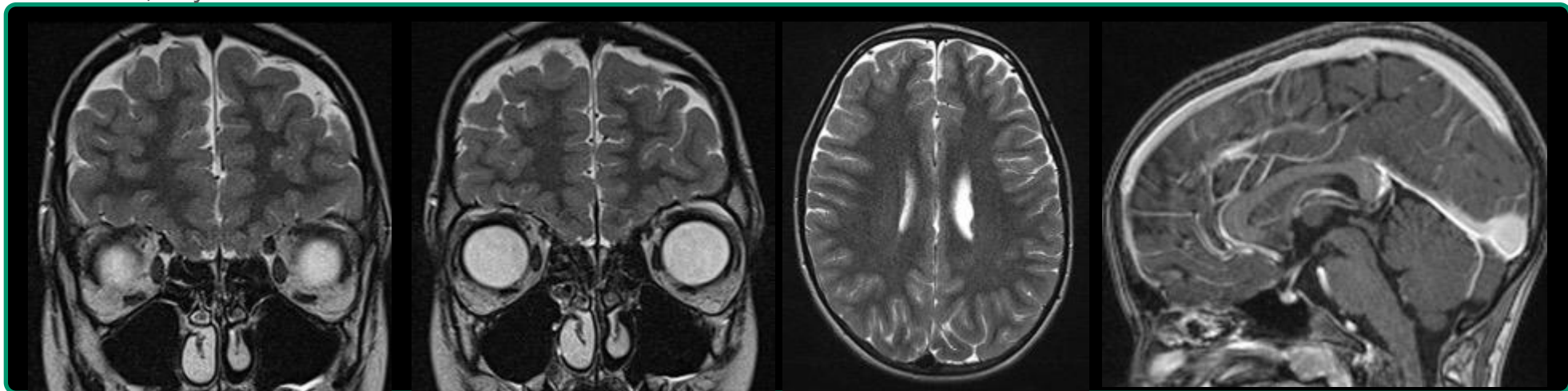
♀, 15yo

Olfactive bulbs present



♀, 11yo

Olfactive bulbs absent

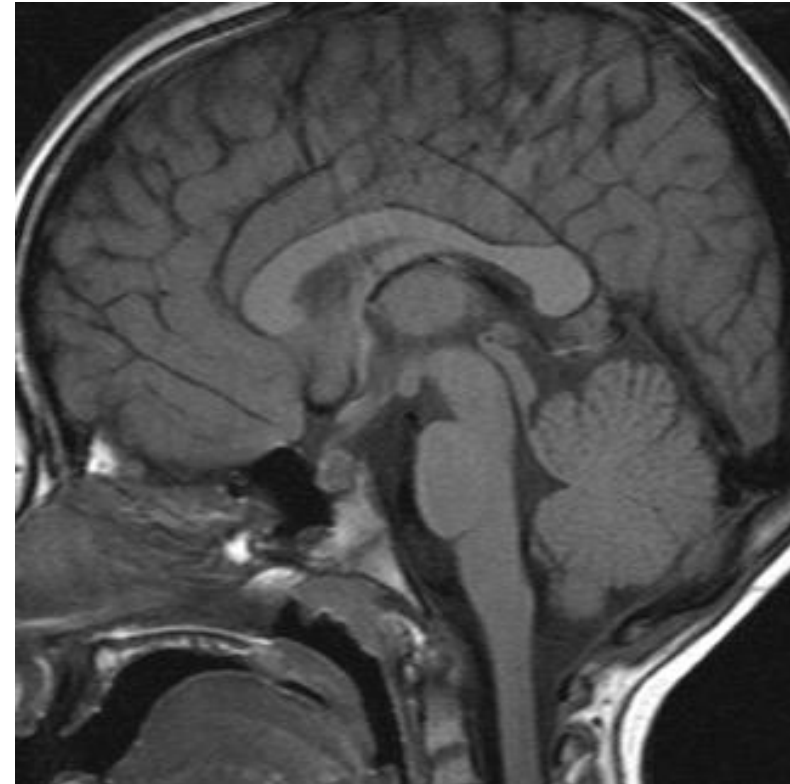




Central diabetes insipidus

- Look for tumors
 - **Germinoma +++++**
 - **Langerhans cell histiocytosis**
 - Craniopharyngioma
- Congenital: rare,
 - Malformation of hypothalamus
 - Mutation AVP-NP11
- Sarcoid
- Trauma; Postsurgery
- Meningitis
- Hydrocephalus
- Autoimmune process

Unidentified bright spot

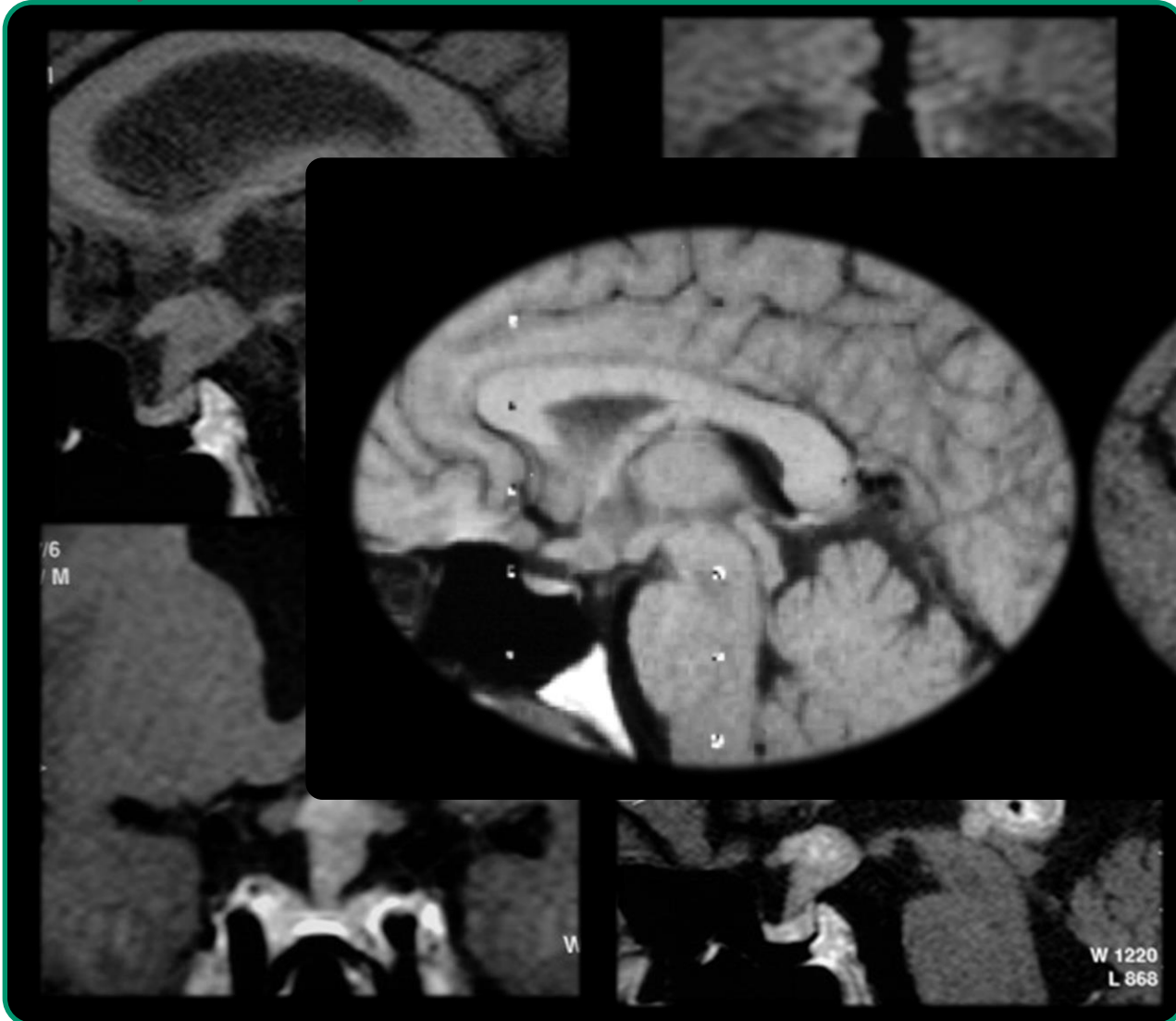




Central diabetes insipidus

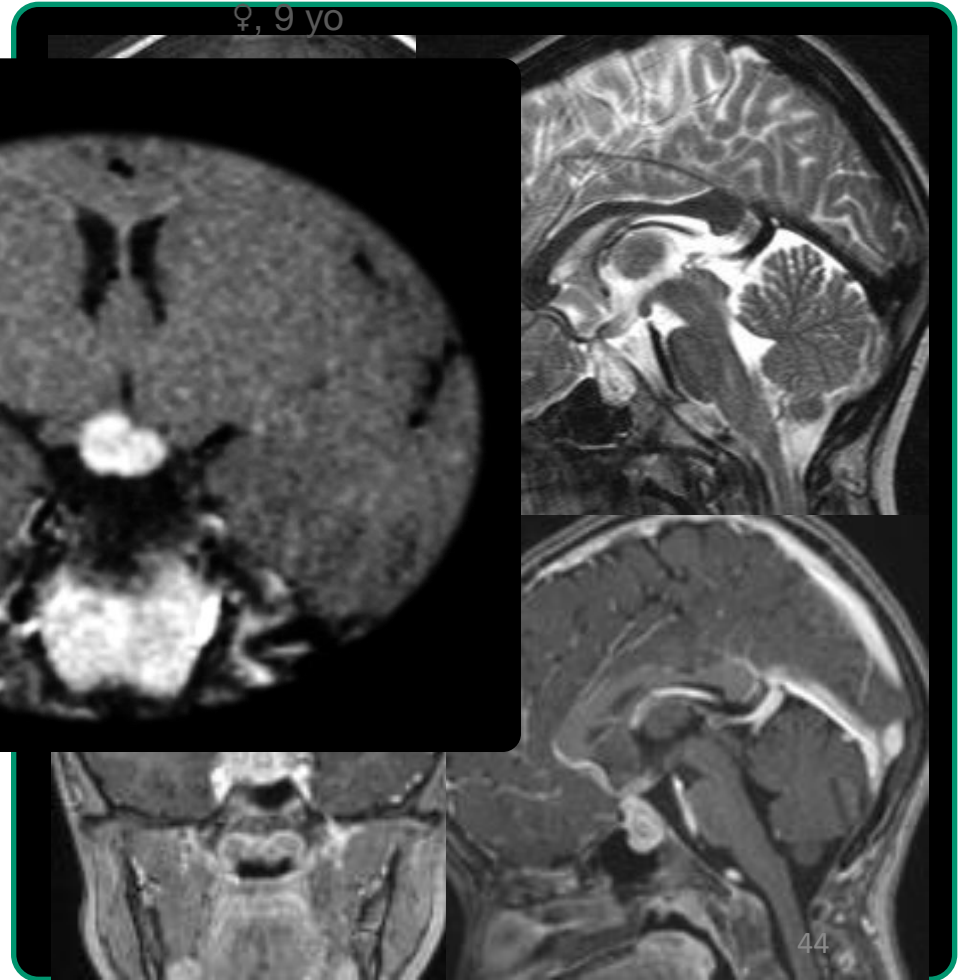
Germinoma

♀, 11 yo, Parinaud syndrome



♀, 7 yo

♀, 9 yo

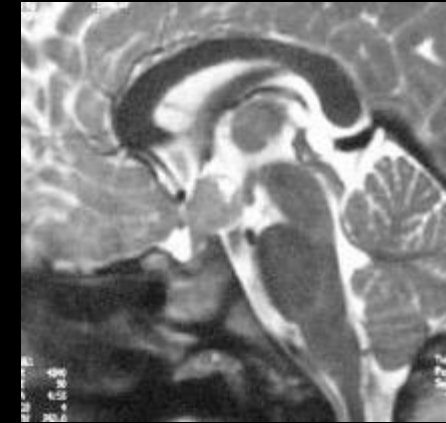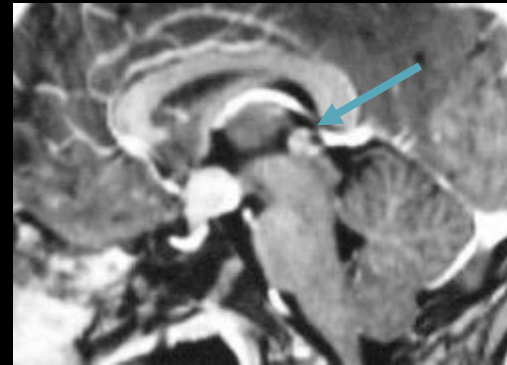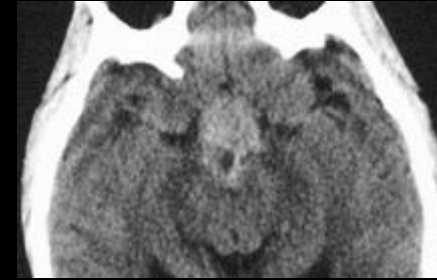




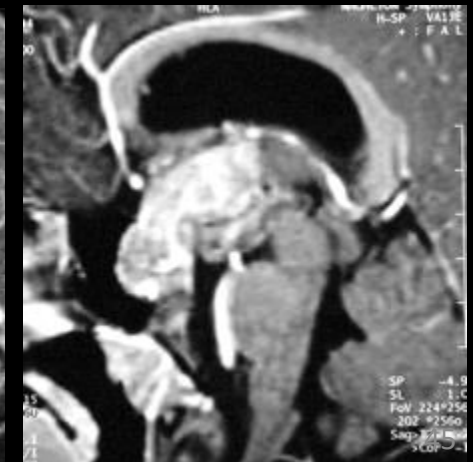
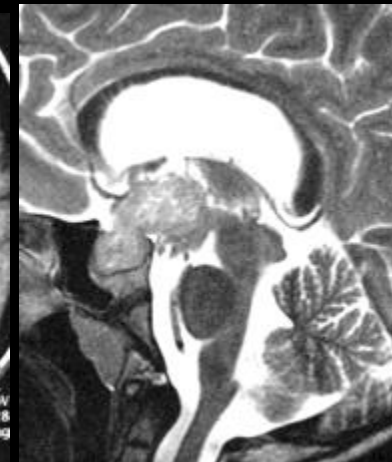
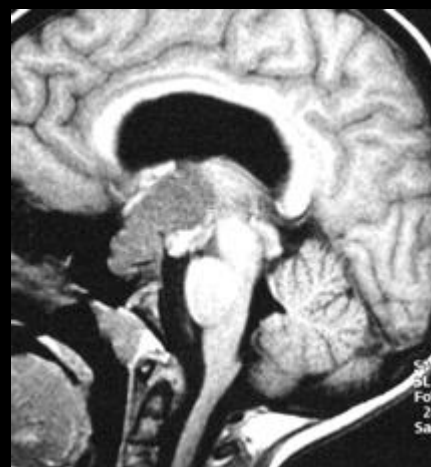Central diabetes insipidus

Germinoma

- CT high attenuation
- MRI: mass
- hypo to isointense T1
- iso-hypointense T2 (highly cellular), hyper T2
- Strong Gd enhancement



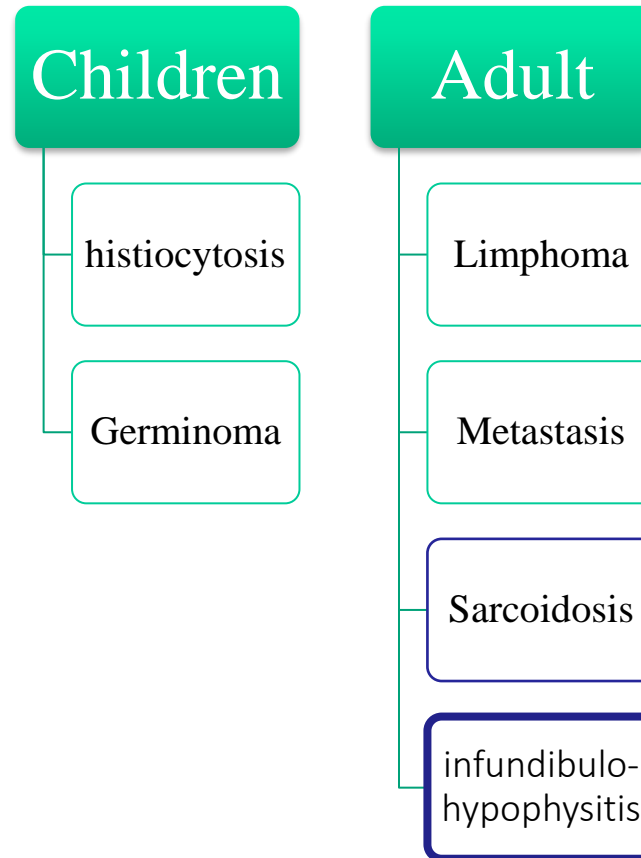
10-20% of germinomas





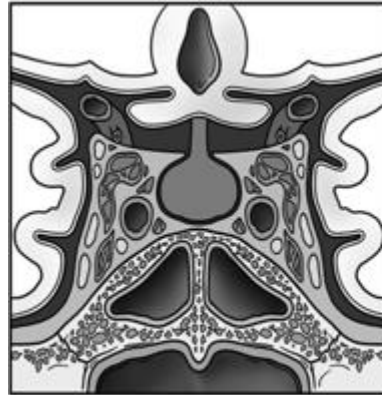
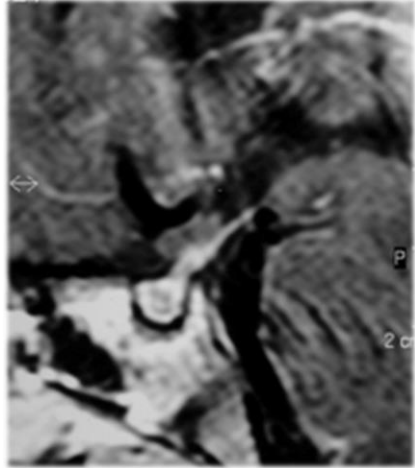
Pituitary stalk thickening

When pituitary stalk thickened (>2mm) + Gd+

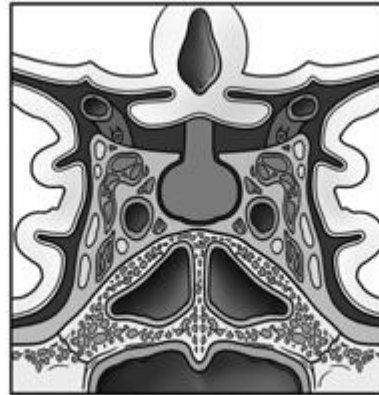




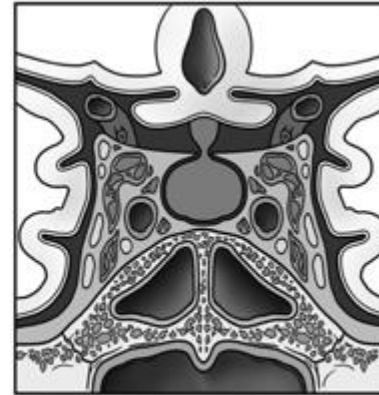
Pituitary stalk thickening



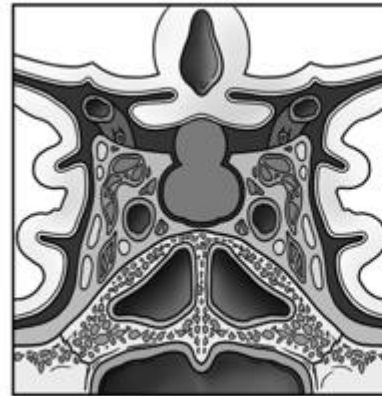
Normal



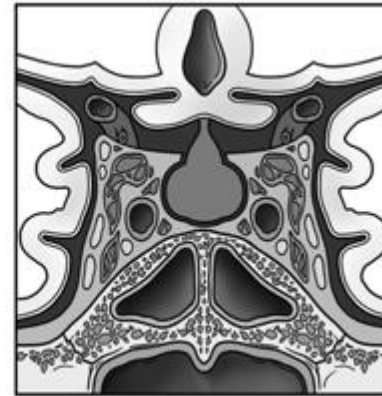
Uniform thickening



V-shaped



Round/Diamond

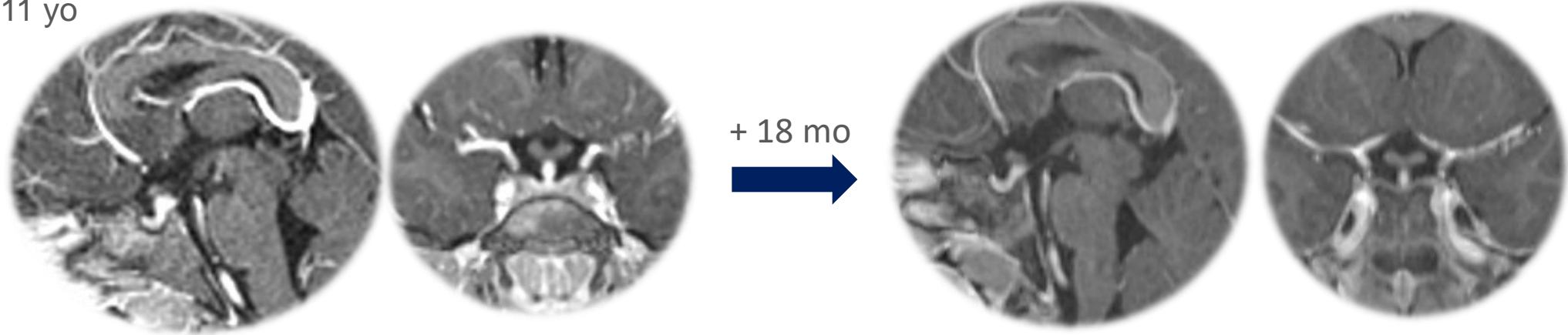


Pyramid



Pituitary stalk thickening

♀, 11 yo



- Repeated brain MRI are essential when the first exam is normal or shows isolated pituitary stalk thickening
 - Serial testing of germ cells tumor markers should also be performed
 - MRI every 6 months for 2 yr, then after 1 yr
 - The search for extra-sellar lesions suggestive of LCH is fundamental and could reduce the need for intracranial biopsies
 - Enlargement of the pituitary stalk (> 6.5-7 mm): indication for biopsy
-



Microadenoma on post-contrast dynamic T1 sequence

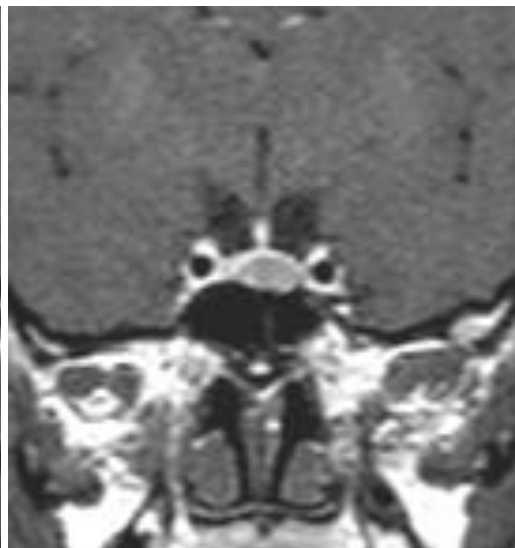
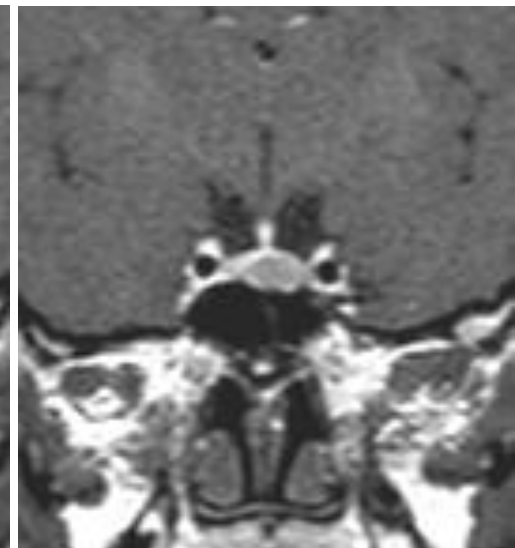
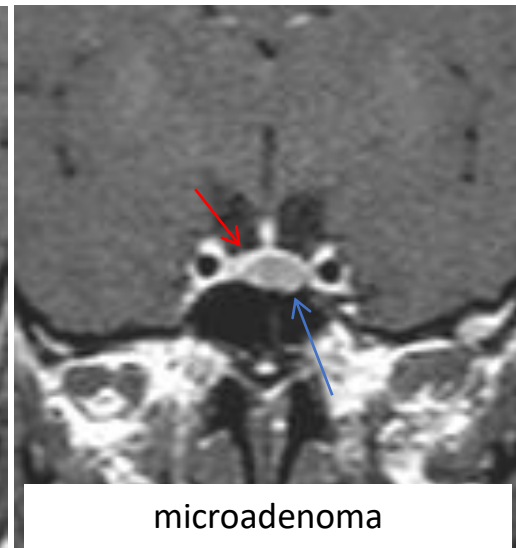
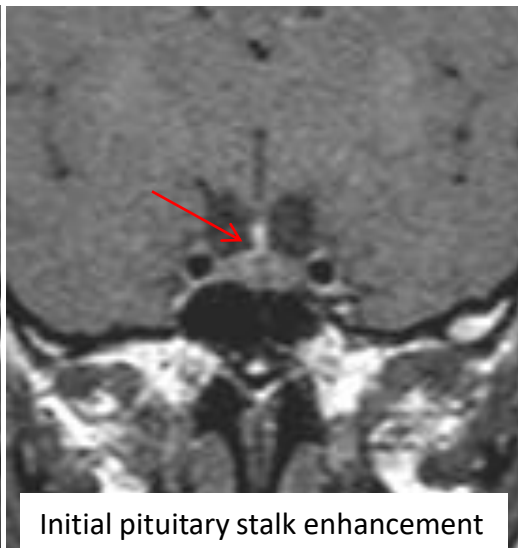
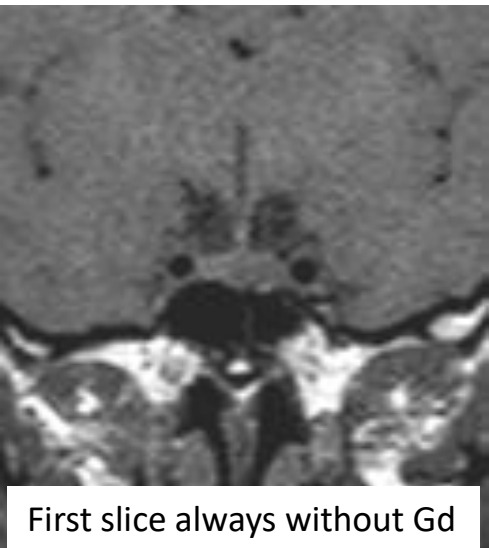
Parenchymal enhancement pattern follows a predictable sequence:

pituitary stalk is the first region to enhance;

followed by enhancement of the normal parenchyma;

and if an adenoma is present, it is the last to undergo Gd enhancement.

♀ 15 yo





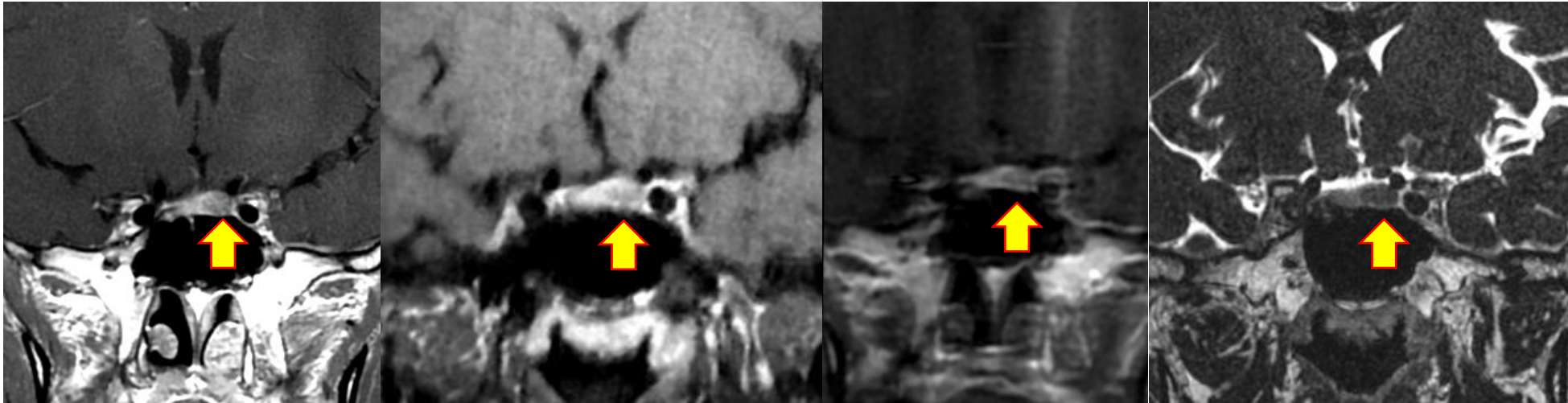
Paediatric patients with Cushing disease

Up to one-third of paediatric and adolescent patients with CD do not have a pituitary tumour visualised in MRI.

A negative MRI is associated with higher odds of nonremission after surgery.

if remission is achieved, long-term risk for recurrence is not associated with the preoperative MRI findings.

♂ 10 y-o



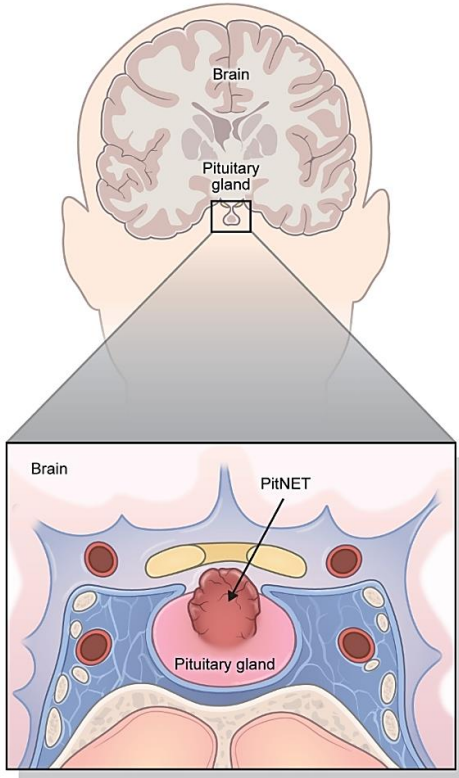
Paediatric patients with Cushing disease and negative pituitary MRI have a higher risk of nonremission after transsphenoidal surgery.

Tatsi C, Bompou ME, Flippo C *et al.*

[Clin Endocrinol \(Oxf\). 2021 Aug 25;95\(6\):856–862. doi: 10.1111/cen.14560.](https://doi.org/10.1111/cen.14560)



Pituitary Neuroendocrine Tumors in Multiple Endocrine Neoplasia



Features of PitNET in MEN1

- Prevalence : 31.5%–52% patients with MEN1
- MEN mutation-positive : 4.5% / negative : 17.0%
- Age of onset : 30–50s (earliest: age 5)
- Size: microadenoma > macroadenoma
- Common subtypes : FPitNET > NFPitNET
PRLoma > GHoma > ACTHoma
Plurihormonal PitENT (4%–11%)
Pituitary carcinoma (*n*=6)

Features of PitNET in MEN4

- Prevalence : unknown
- 22 Cases of PitNET with MEN4 reported to date.
NFPitNETs : 6
GHomas : 4
ACTHomas : 7
Prolactinomas: 5
- Age of onset : unknown due to small number of cases

Management (Including screening)

- Age at screening : at the age of 5, if at high risk for MEN1
- Screening interval and method:
Biochemical - annually
Radiologic - every 3 years
- Treatment : same as PitNET in non MEN1
- Outcome :
PRLoma : hormonal normalization at 50%–91.2%
GHoma : relapse rate after surgery - 14.3%

MEN 1 3Ps

- Caused by mutation MEN1 gene (tumor suppressor on chromosome 11)
 - Pituitary: pituitary neuroendocrine tumors (PitNETs)
 - Functional PitNETs (FPitNETs) are more frequent
 - Prolactinomas predominantly
 - Plurihormonal, larger, and more invasive compared to sporadic types
 - Pancreas: islet cell tumors, including gastrinomas (Zollinger-Ellison syndrome), insulinomas, VIPomas
 - Parathyroid: adenomas more common for MEN1

Pituitary Neuroendocrine Tumors in Multiple Endocrine Neoplasia.

Chin SO, Chik C, and Taten T.

[Endocrinology and Metabolism 2025;40\(1\):39-46. https://doi.org/10.3803/EnM.2024.2074.](https://doi.org/10.3803/EnM.2024.2074)

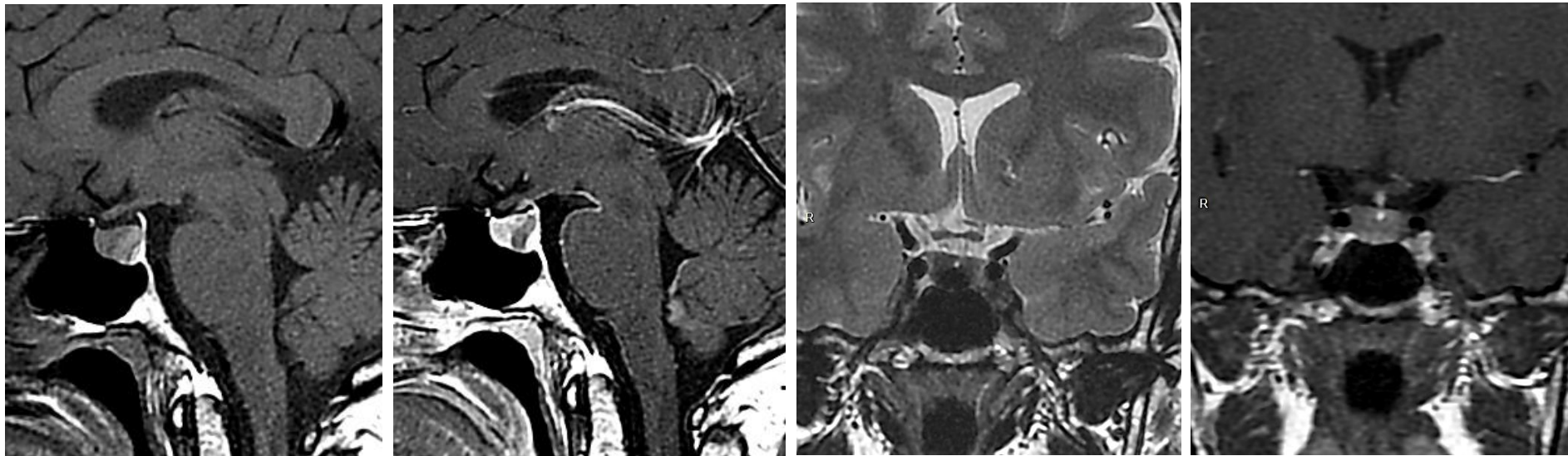

Pars intermedia cyst

Rathke cleft cysts, also known as pars intermedia cysts

non-neoplastic, intrasellar lesion located between the anterior and posterior lobes of the pituitary gland
epithelium-lined cysts arising from the embryologic remnants of Rathke pouch in the pituitary gland.

They are common lesions and usually incidentally identified.



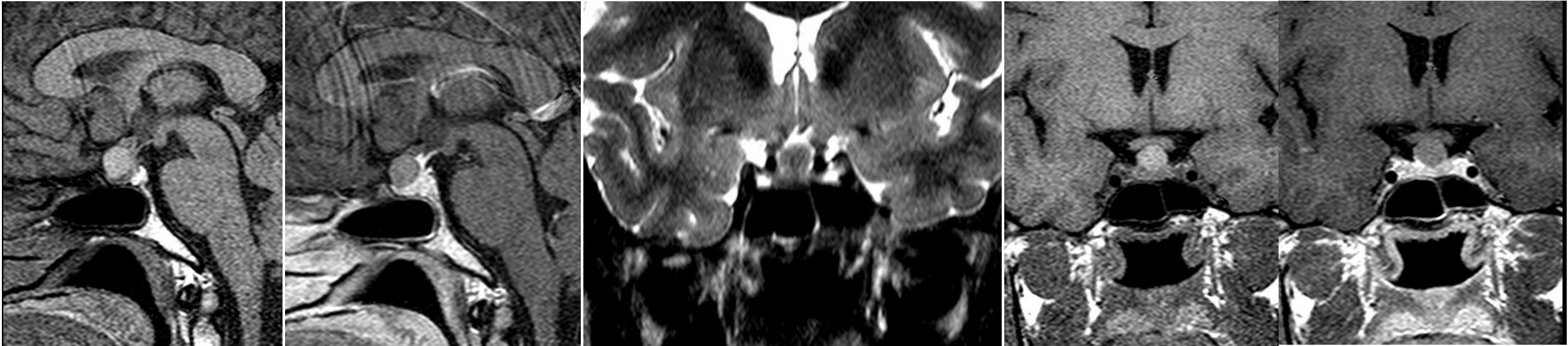


Rathke's cleft cysts

Rathke cleft cysts are non-neoplastic, sellar or suprasellar epithelium-lined cysts arising from the embryologic remnants of Rathke pouch in the pituitary gland.

They are common lesions and usually incidentally identified.

They can compress the pituitary stalk or optic chiasm.





Craniopharyngiomas

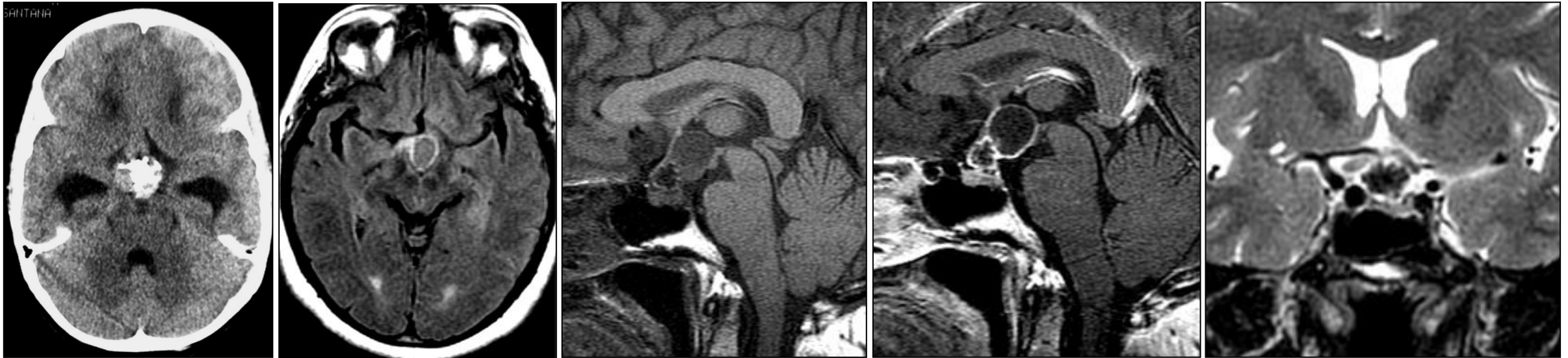Currently considered to denote two separate entities (adamantinomatous craniopharyngiomas and papillary craniopharyngiomas)

(WHO 2021 grade 1) neoplasms that typically arise in the sellar/suprasellar region.

Molecular evidences have demonstrated that they have distinct and mutually exclusive mutations:

β -catenin gene (CTNNB1) mutations CTNNB1 (adamantinomatous) - in all age groups, but predominantly in children (second, less pronounced, peak between 40-59 years of age)

and BRAF (papillary) – considered as a tumor of adult patients





Final remarks

- Neuroimaging can be normal or can demonstrate pituitary-hypothalamic abnormalities like congenital and developmental malformations such as pituitary hypoplasia or absence,
 - ‘ectopic’ posterior pituitary (translocation of pituitary bright spot to median eminence),
 - absence of pituitary bright-spot (may indicate disruption of normal stalk transport mechanism), duplication of pituitary gland/stalk and empty sella syndrome;
 - tumors, mainly craniopharyngiomas, pituitary adenomas (ACTH-releasing adenomas < 11 years of life and, while prolactinomas >12 years),
 - chiasmatic or hypothalamic glioma,
 - hypothalamic hamartoma, germinoma, and leukemia/lymphoma;
 - cystic lesions such as Rathke's cleft cysts that are commonly seen in the gland, even in healthy children (they are nonfunctional, however, may cause mass effect on the gland);
 - and infectious/inflammatory conditions such as Langerhans cell histiocytosis, lymphocytic hypophysitis, tuberculosis, and sarcoidosis.
 - One should also pay careful attention to evaluate midline anomalies (like septo-optic dysplasias or corpus callosum agenesis) commonly associated with pituitary endocrinopathies.
-



Additional remarks

- MRI including FAST 1.2 is helpful in the evaluation of hypothalamic-pituitary disorders, with faster acquisition of images without Gd administration or anesthetic sedation
 - FAST1.2 allows confident recognition of midline structural abnormalities
 - Multiplanar MRI with intravenous Gd administration should be kept for specific settings, identified or suspected in clinical, laboratory, and imaging detailed analysis
 - Differential diagnoses include congenital abnormalities, hamartomatous and neoplastic lesions, in addition to, several inflammatory and infiltrative disorders
-

European Course on
Pediatric Neuroradiology in
Latin America (ECPNR-LATAM)
3rd Cycle - Module 1

MR imaging of the hypothalamus-pituitary
region in children

@drantoniorocha.neurorradio

Antônio Rocha, MD PhD

Radiologista e Neurorradiologista

CBR / SBNR / EDiNR

CRM SP 74453

RQE 34187

Idealização:



Organização:





Capela da Santa Casa de Misericórdia de São Paulo (1903)

