



## SQUAMOUS TEMPORAL SUTURE: AN UPDATED VIEW OF THE IMPORTANCE OF THIS FINDING IN CRANIOSYNOSTOSIS.

Herênio, Y M B <sup>(1)</sup>; Bianco, B F <sup>(2)</sup>; Segundo, L B M <sup>(3)</sup>; Cardim, V L M <sup>(4)</sup>; Silva, A S <sup>(5)</sup> ; Mello, S M B <sup>(6)</sup> ; Haetinger, R G <sup>(7)</sup>

**From the Departments of Head and Neck Radiology and Plastic Surgery of Hospital Beneficência Portuguesa de São Paulo (BP Hospital)**

<sup>(1-3)</sup> Residents at the Radiologic Department at BP Hospital

<sup>(4)</sup> Plastic surgeon at BP Hospital

<sup>(5)</sup> Plastic surgeon at BP Hospital

<sup>(6)</sup> Radiologist for Head and Neck at BP Hospital

<sup>(7)</sup> Radiologist for Head and Neck, head of the Head and Neck Radiology at BP Hospital



**THERE IS NO CONFLICT OF INTEREST  
IN THIS PRESENTATION**



# SUMMARY

- ✓ INTRODUCTION
- ✓ NORMOCEPHALIC SUTURES AND CLOSING AGE
- ✓ SQUAMOUS TEMPORAL SUTURE SYNOSTOSIS SPECTRUM
- ✓ OBJECTIVE
- ✓ DISCUSSION
- ✓ TYPES OF CRANIOSYNOSTOSIS, INCLUDING SQUAMOUS TEMPORAL SUTURE
- ✓ CASE 1 – LEFT POSTERIOR PLAGIOCEPHALY DUE BY EARLY CLOSURE OF THE LEFT LAMBDOID AND SQUAMOUS TEMPORAL SUTURE ON THIS SIDE
- ✓ CASE 2 – BRACHYCEPHALY WITH TOTAL CLOSURE OF THE SQUAMOUS TEMPORAL SUTURES AND TENDENCY TO "BULB SHAPE" OF THE HEAD
- ✓ CASE 3 – BRACHYCEPHALY WITH POSTERIOR CLOSURE OF THE SQUAMOUS TEMPORAL SUTURES AND BULB HEAD SHAPE
- ✓ CASE 4 – BRACHYCEPHALY IN EARLY CLOSURE OF THE TEMOPOROSQUAMOUS SUTURES WITHOUT BULB SHAPE HEAD
- ✓ CASE 5 – NORMAL HEAD SIZE, BUT WITH BILATERAL PARIETAL BOSSAE
- ✓ CASE 6 – SCAPHOCEPHALY WITH EARLY CLOSURE OF THE TEMOPOROSQUAMOUS SUTURES
- ✓ CASE 7 – SQUAMOUS TEMPORAL CRANIOSYNOSTOSIS IN APERT SYNDROME
- ✓ CASE 8 – SQUAMOUS TEMPORAL CRANIOSYNOSTOSIS IN CROUZON SYNDROME
- ✓ TEACHING POINTS
- ✓ CONCLUSION
- ✓ SUGGESTED READING

# INTRODUCTION

- Craniosynostosis refers to premature fusion of single or multiple calvarial sutures. Affected suture: sagittal (with a reported incidence of 60% of cases), coronal (unilateral—or bilateral—25% of cases), metopic (~15%), and lambdoid (~2% of cases; Dos Santos and Cardim, 2021). Although rarely mentioned, unilateral—or bilateral stenosis of the squamosal or temporal sutures may also occur. This condition results from genetics and metabolic anomalies, teratogens, abnormal intrauterine pressures, and restricted underlying brain development among others (Eley et al, 2016). The resulting of calvarial deformities largely obey Virchow law, with restricted growth perpendicular to, and “compensatory growth” at nonfused sutures parallel to the affected suture.
- The impact on cranial shape of synostosis involving the sutures of the lateral skull (squamosal, sphenoparietal, sphenosquamosal, sphenofrontal, parietomastoid, occipitomastoid) and skull base is not nearly so well understood.
- Premature fusion of the squamosal suture has been infrequently reported in the literature, suggesting that it is a relatively rare phenomenon. The morphological effects of squamosal suture synostosis appear to be varied, but may include a degree of occipital flattening with compensatory bossing of the contralateral parietal region.
- Temporosquamosal suture early closure is not uncommon, occurring in roughly 1 in 2500 children (Ranger et al, 2010).
- Squamosal suture synostosis has been described in association with Apert, Crouzon, Pfeiffer, Saethre-Chotzen and Muenke syndromes (Eley et al, 2016; Ranger et al, 2010; Smartt et al, 2012).
- The squamosal temporal suture synostosis may be overlooked when not suspected on morphological grounds.

# NORMOCEPHALIC SUTURES AND CLOSING AGE

Metopic → 3 to 9 m/o

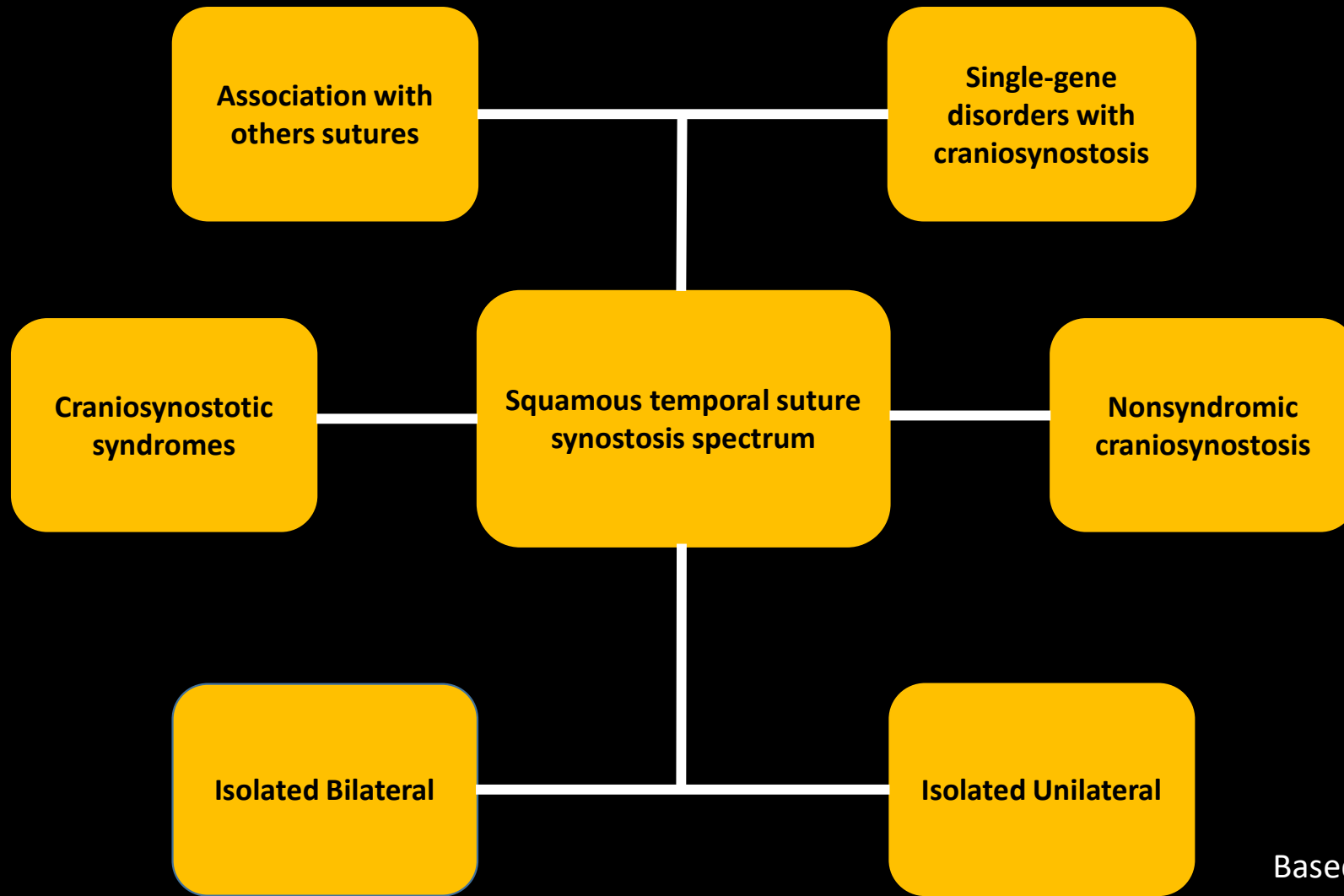
Sagittal → 26 y/o

Coronal → 24 y/o

Lambdoid → 30 to 40 y/o

Squamous temporal → 40 y/o

# SQUAMOUS TEMPORAL SUTURE SYNOSTOSIS SPECTRUM



Based on Eley et al, 2016

## OBJECTIVE

The squamous suture is the main object of our work. While the phenotypic appearances and sequelae of synostosis of the major cranial vault sutures are well documented, little is reported concerning synostosis of the squamous suture. Involvement of this suture can be individual or associated with other sutures, both in syndromic cases and in primary craniosynostosis. This presentation has the objective to demonstrate the importance of the squamous temporal suture, which has been undervalued over the years in literature. It is not a guide, but a pictorial assay showing what we have observed in the last years.

The authors propose to add the lateral view of the head in diagrammatic classification of the different types of craniosynostosis, and not only the usual superior view of the head, as it has been showed in literature for decades.

Further research is necessary to better understand the behavior of early closure of this “forgotten suture”.

# DISCUSSION

Little is reported in literature concerning synostosis of the squamous temporal suture, mainly in the isolated form. But in the last few years some interesting researches are bringing important aspects about and our practice in some cases have brought some doubts.

The embryologic origins and the functional anatomy of the squamous temporal suture are not completely known. Generally, the phenotype described in the literature in patients with isolated squamous synostosis shows some degree of occipital flattening, with compensatory bossing of the forehead or the parietal region.

We have seen different skull configurations related to exclusive squamous temporal synostosis, i.e., plagiocephaly (as shown on **case 1**), brachycephaly (**cases 2, 3, 4 and 8**), only parietal bossae (**case 5**) and scaphocephaly (**case 6**). This paradoxical findings indicate that probably there are other factors associated with this kind of synostosis, currently not clear. Maybe related to bone matrix or other skull base anomaly. Further research will be important to shed some light on this intriguing behavior.

The temporal bone contains elements of both the facial skeleton and the skull base, composed of the squamous and tympanic components, the petrous portion and the styloid process. The squamous and tympanic components of the temporal bone originate from neural crest derived mesenchymal cells of the maxillary prominence of the first branchial arch and undergo intramembranous ossification. The petrosal elements originate from paraxial mesoderm and constitute part of the neurocranium and undergoes endochondral ossification.

# DISCUSSION

Ranger et al (2010) reported 2 cases of synostosis of the squamous temporal suture, one with plagiocephaly and one with brachicephaly (associated with Chiari II malformation).

Smartt et al (2011) studied 14 patients and observed that synostosis of the squamous temporal suture was noted to occur either in an isolated fashion or in the setting of other craniofacial malformations. In cases of isolated squamous temporal synostosis, mild to severe deformities were observed and there was a tendency to improve with time. It may also occur craniofacial dysmorphism related to this type of synostosis. Although there was variability in the clinical presentation of patients, that with synostosis isolated to the squamous temporal suture generally presented with some degree of occipital flattening and compensatory bossing of the parietal region.

Eley et al (2016) evaluated 422 computed tomography (CT) patients, confirming 38 patients (9%) with squamous temporal synostosis (more frequently associated with syndromes), and only 5 patients in the isolated form. From these 5 patients, 1 was normocephalic with exorbitism in Crouzon Syndrome, 2 with scaphocephaly (one with forehead bossae in congenital hyperthyroidism, and one without bossae in Loeys-Dietz syndrome with craniolacunia), 1 with left posterior plagiocephaly and hypertelorism, and 1 with normocephalic head, but mild facial asymmetry. These authors related that the diagnosis may well be challenging to visualize clearly, even with modern CT imaging. They refer a possible false impression of fusion of the squamous temporal suture based on volume rendering with algorithm for bone.

# DISCUSSION

In our department we use routinely the 3-dimension volume rendering algorithm for bone surface and MIP (Maximum Intensity Projection) algorithm (cutting semi-heads to avoid overlapping) to analyze the sutures through transparency. The MIP technique also shows better craniolacunias (see cases presented in this panel).

Doumit et al (2014) reported a case of scaphocephaly due to squamous temporal and fronto-sphenoid sutures. We also have one sample of this kind, demonstrated on case 6.

The presence of craniolacunias is a high indication of intracranial hypertension, which needs to be correlated with clinical aspects. In majority of patients, we have observed this finding not in the whole skull, but segmented, near to the closed sutures. This phenomenon is intriguing, and we have no explanation, since the intracranial pressure should spread out equally in the head. Until now, we didn't find an anatomic subsidy to explain it.

In **case 7** we can see an Apert Syndrome, with a cloverleaf-shaped head, with early closing of all sutures. The squamous temporal sutures play an important role in this configuration. Extensive areas of craniolacunias are seen in the parietal and occipital bones, and an open anterior fontanelle persists, with an elongated and tortuous shape.

In **case 8** is demonstrated a Crouzon syndrome, with brachycephaly, including maxillary hypoplasia, hypertelorbitism, with bone bridges characterizing early partial closure of the squamous temporal sutures. There are signs of craniolacunias in the most posterior regions of the parietal bones and occipital bone. Tandon et al (2014) described a case of bilateral squamous temporal suture synostosis as a rare form of isolated craniosynostosis in Crouzon syndrome. Usually multiple sutures are affected in this syndrome.

# DISCUSSION

As in any case of craniosynostosis, it is essential to look for other anomalies, like associated brain alterations (corpus callosum dysgenesis, hydrocephalus, Chiari, etc).

It is also important to remember that prematurity and/or twin pregnancy may cause skull deformities, as differential diagnosis for plagiocephaly.

The lateral view of the head in diagrammatic classification of the different types of craniosynostosis is essential, and not only the usual superior view of the head, as it has been showed in literature for decades ([see next slide](#)).

# TYPES OF CRANIOSYNOSTOSIS, INCLUDING SQUAMOUS TEMPORAL SUTURE



**Metopic  
Trigonocephaly**



**Normocephaly**



**Bilambdoid  
Brachycephaly**



**Posterior postural  
deformity**



**Unilateral coronal  
Anterior  
plagiocephaly**



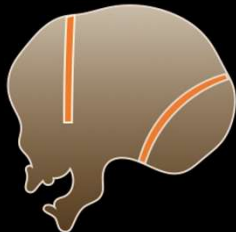**Sagittal  
Scaphocephaly**



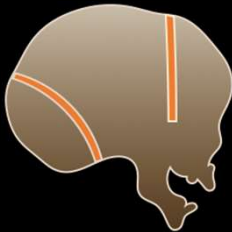**Bilateral coronal  
Brachycephaly**



**Lambdoid  
Posterior  
plagiocephaly**



+



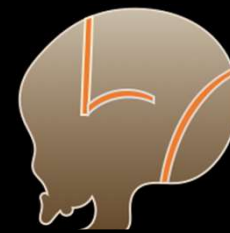=



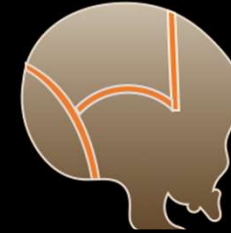or



**Squamous temporal bilateral – brachycephaly with bulb shape or Scaphocephaly.**



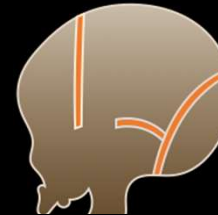+



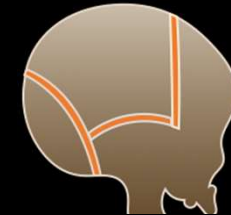
=



**Squamous temporal unilateral – Posterior plagiocephaly**



+



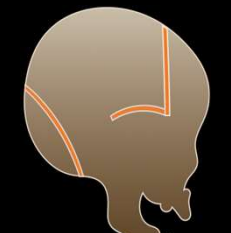
=



**Squamous temporal unilateral – Anterior plagiocephaly**



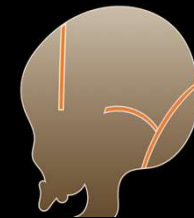+



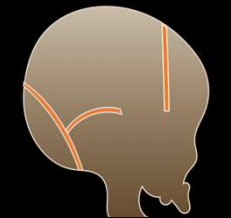
=



**Squamous temporal bilateral posterior – Brachycephaly (eventual bulb shape)**



+

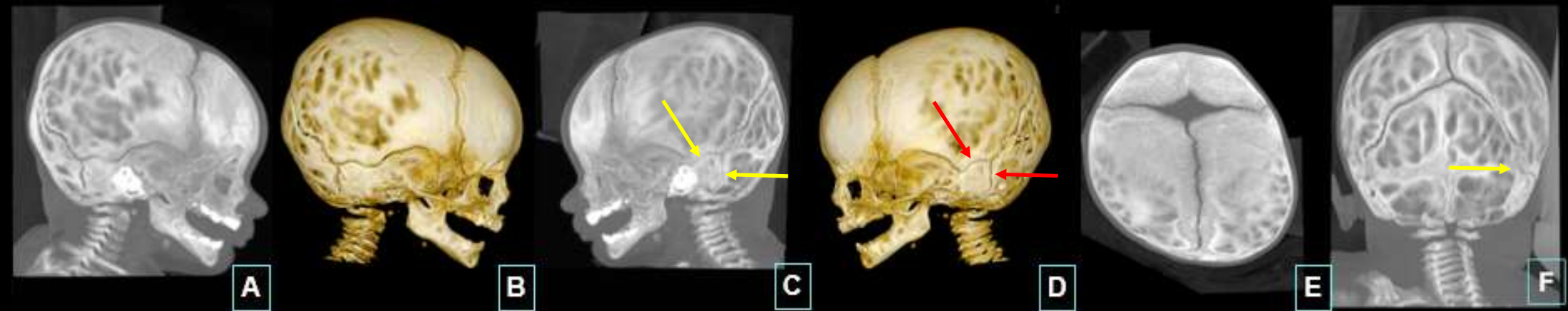


=



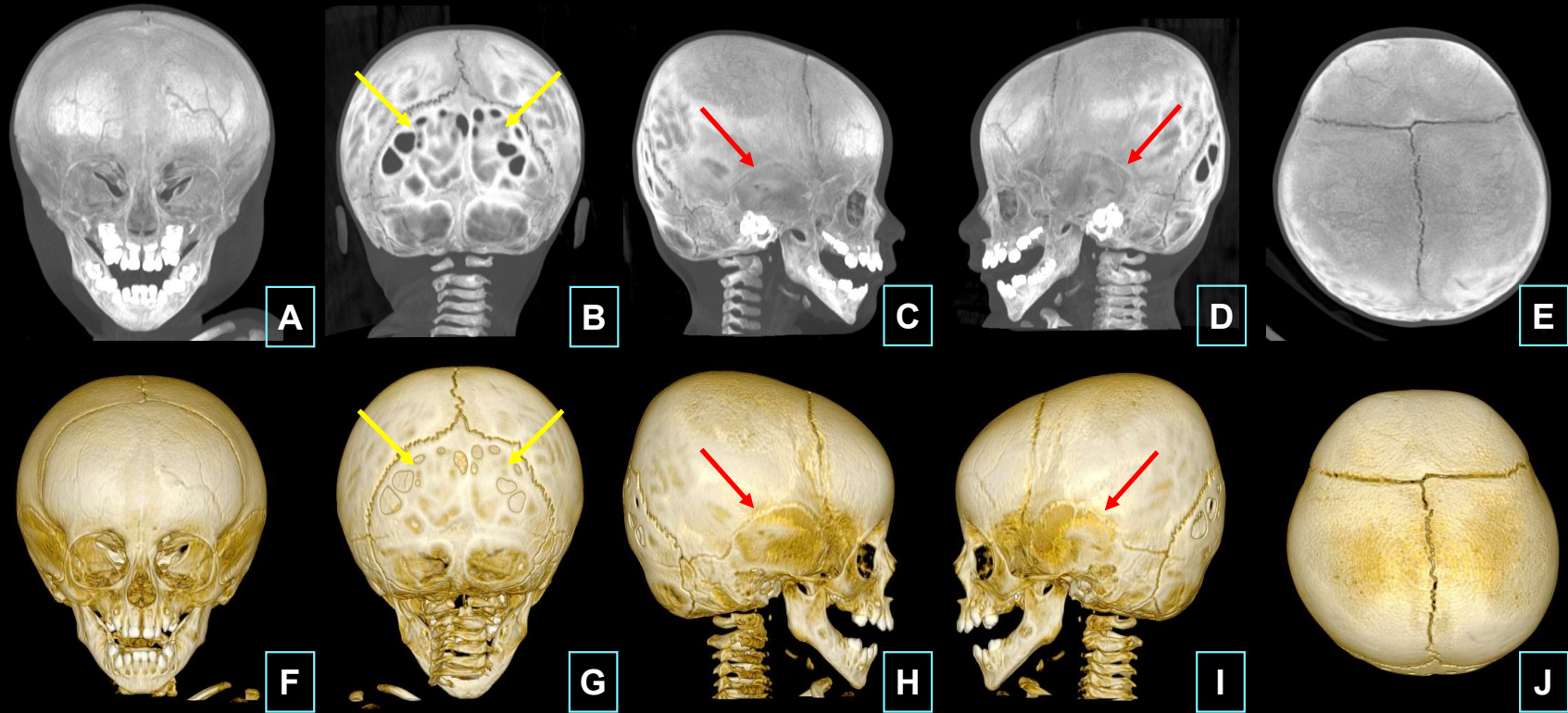
**Squamous temporal bilateral anterior – Brachycephaly**

## CASES



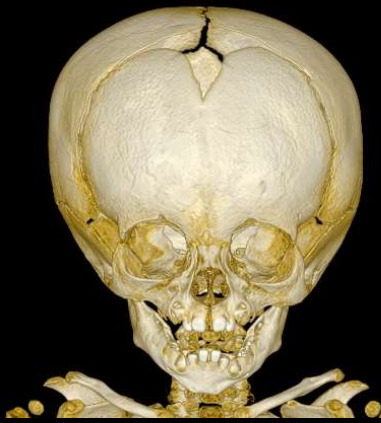Case 1: **6 months-year-old male with posterior plagiocephaly.** Normal appearance of the right squamous temporal (A and B). The most caudal segment of left lambdoid suture is narrower, with a small bone bridge in this region (C and D). Closure of the inferior part of the left lambdoid suture (F). Left posterior plagiocephaly determined by early closure of the lambdoid and squamous temporal sutures on this side (E). Craniolacunias involving the occipital and both parietal bones (all figures, especially E and F).

# CASES

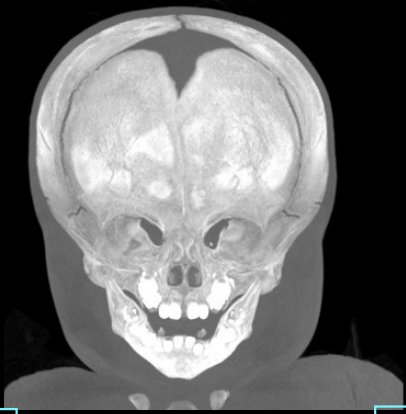


Case 2: **1 year and 3 months old, male, brachycephaly and bulb shape head** (A). Signs of total closure of the squamous temporal sutures, also inferior segments of coronal and lambdoid sutures (B and C). The most cranial segments of the coronal and lambdoid sutures remain anatomically configured (E and J). Bilateral craniolacunias in the occipital bone (B) and bulb shaped head (A).

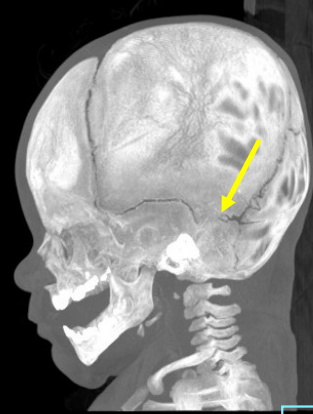
# CASES



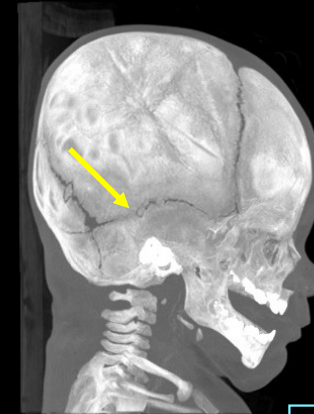
A



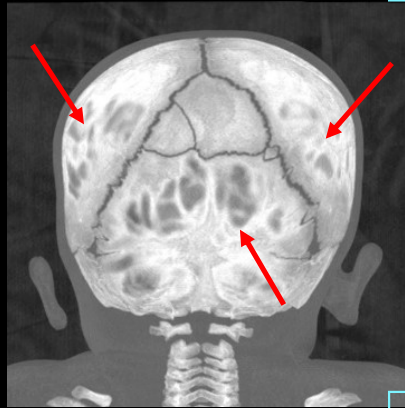
B



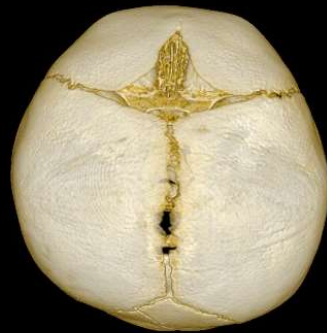C



D



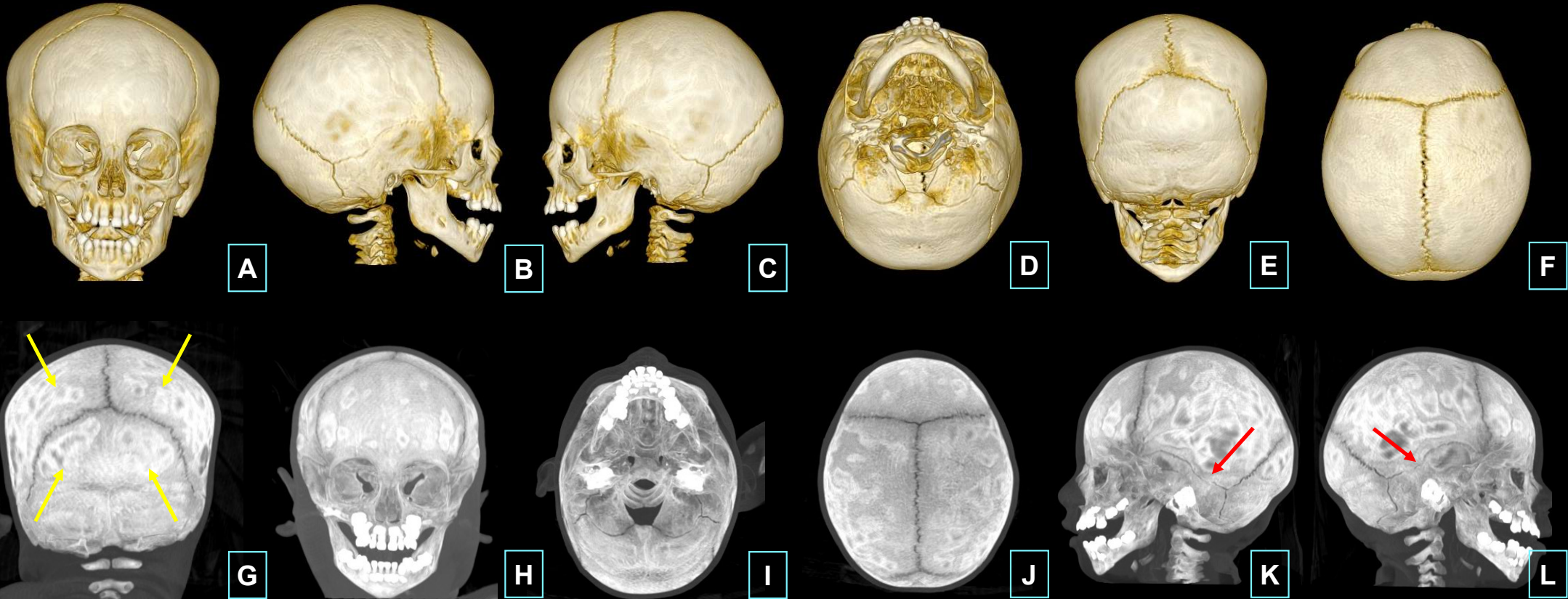
E



F

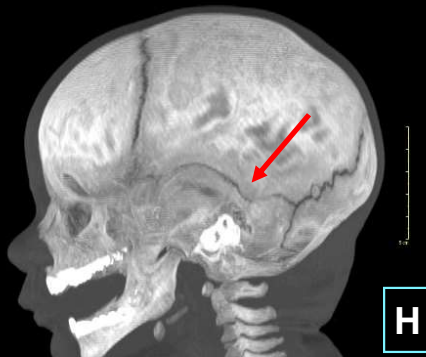
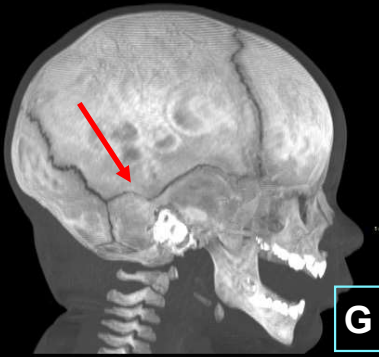
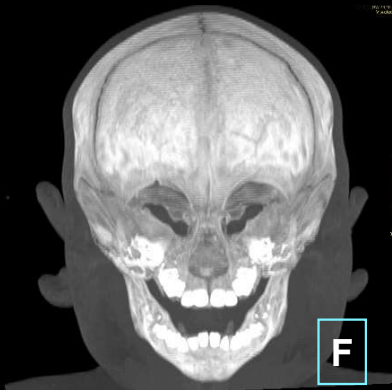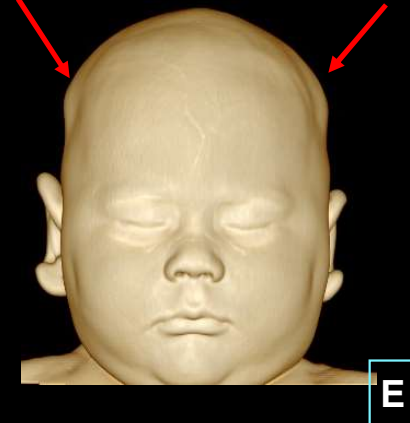
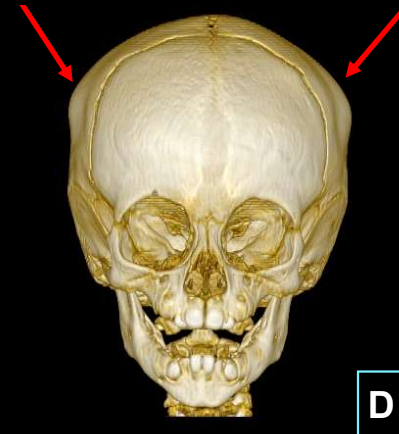
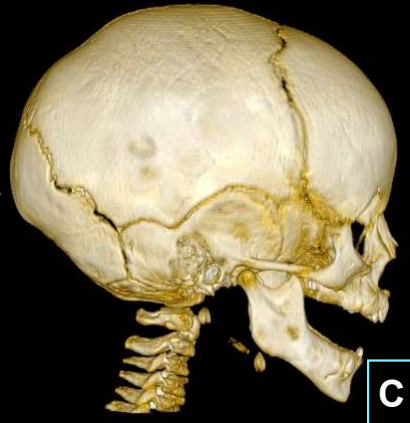
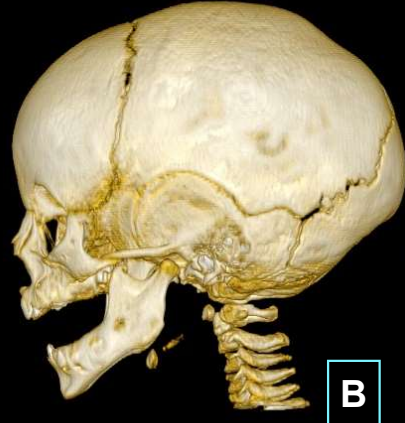
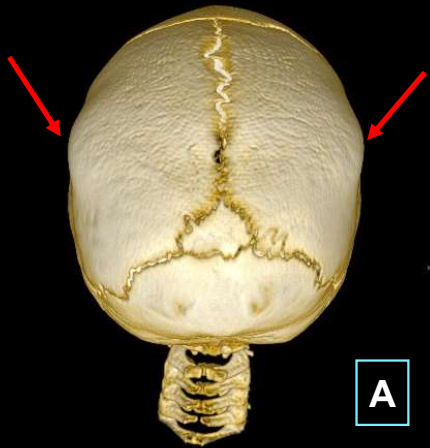
Case 3: **Male, 6 months and 23 days, brachycephaly with tendency to "bulb shape" of the head** (A, B and F), with early closure of the posterior segments of the squamous temporal suture (C and D), signs of craniolacunaria in the occipital bone and in the posterior regions of the parietal bones (E),

## CASES



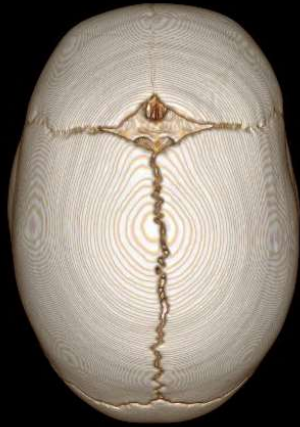Case 4: **Female, 1 year and 8 months old, brachycephaly without “bulb shape head”** (A, G, F and J), early closure of the temporosquamous sutures, including bone bridges in the most posterior segments, clearer with MIP (K and L). Craniolacuniae in the parietal and occipital bones (G).

# CASES

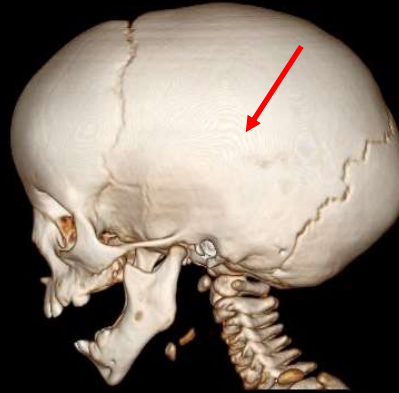


Case 5: 7 months and 22 days, male, head with **bilateral parietal bossae** (figures A, D and E) accompanied by some rectification of the temporoparietal regions. Squamous temporal sutures are smaller compared to coronal (F) and lambdoid sutures, possibly associated with fibrous closure (G and H).

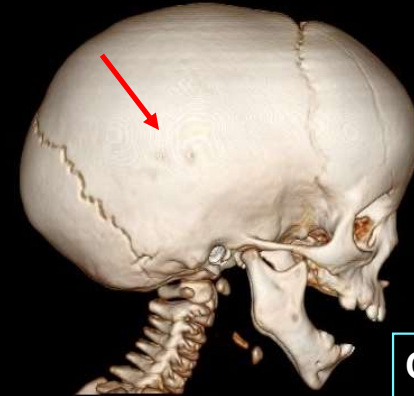
# CASES



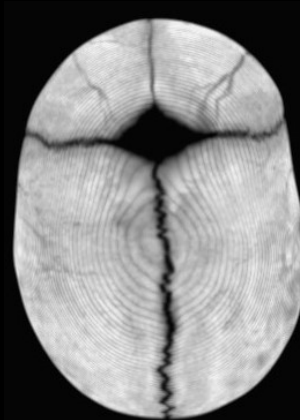
A



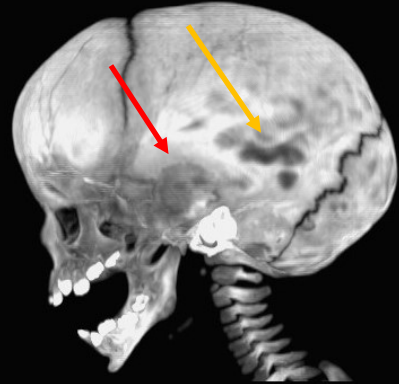
B



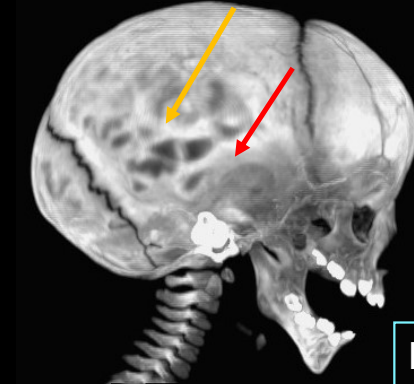
C



D



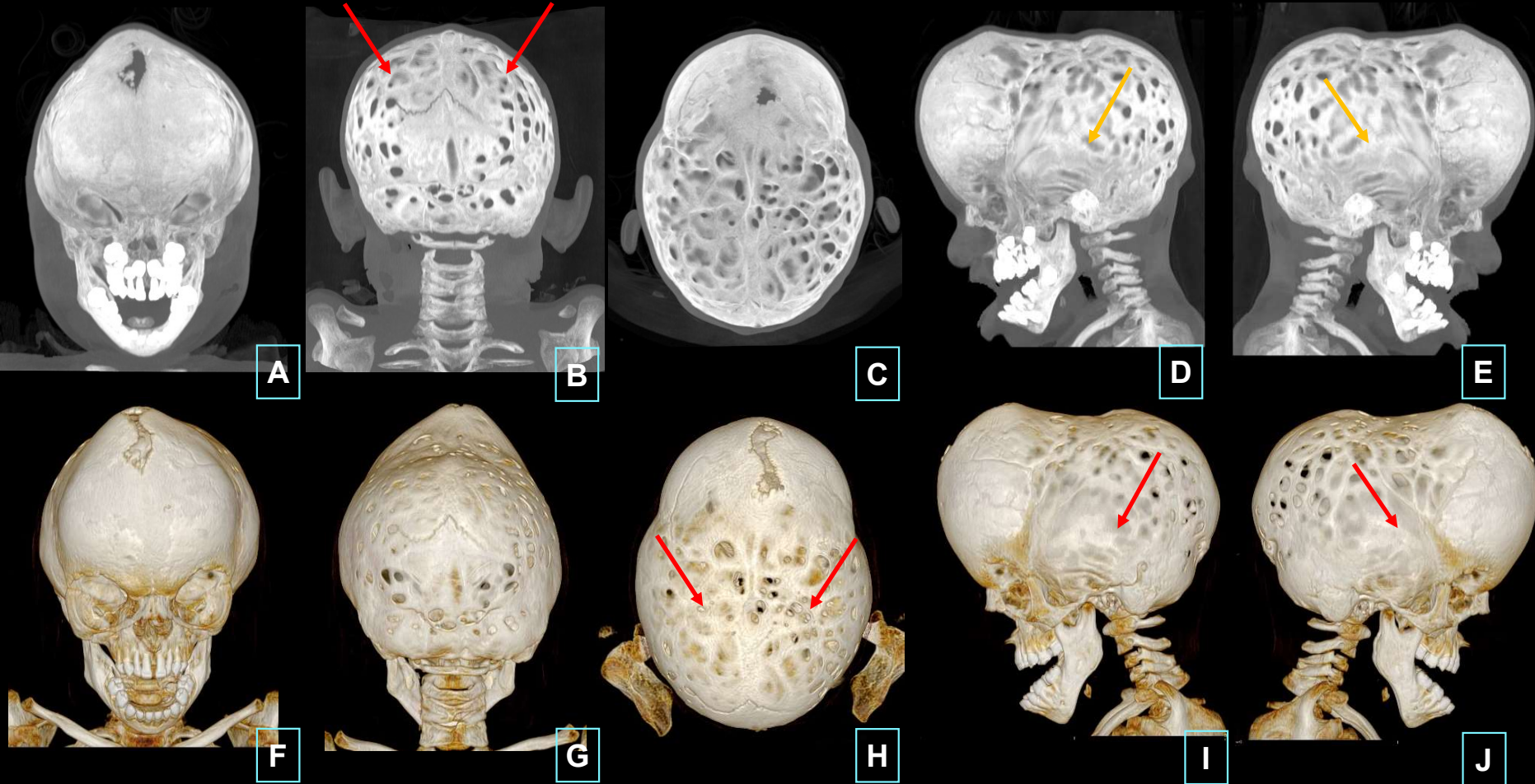
E



F

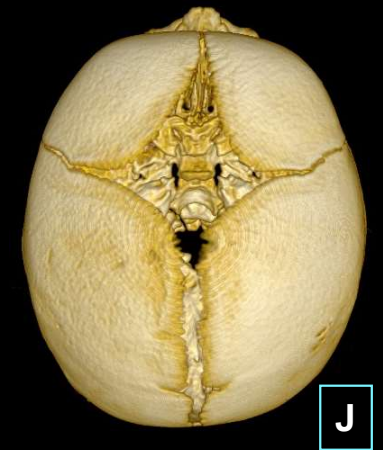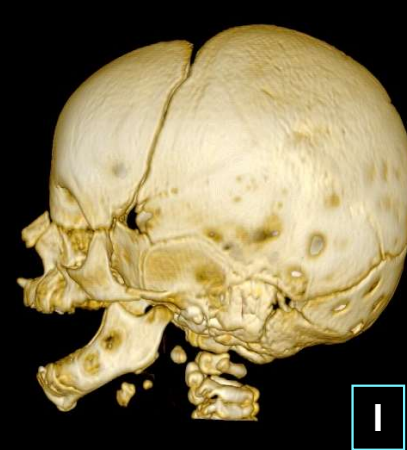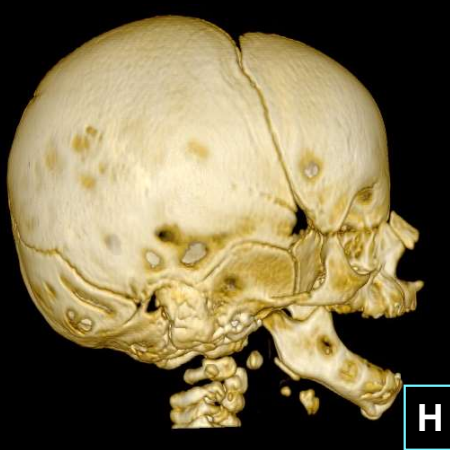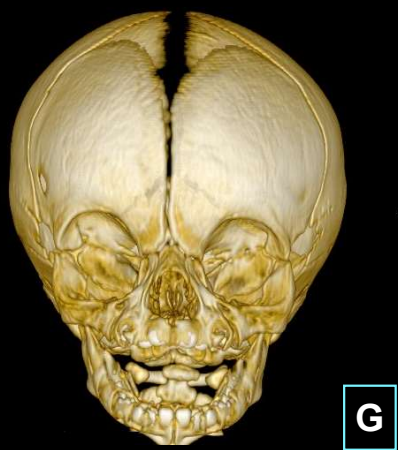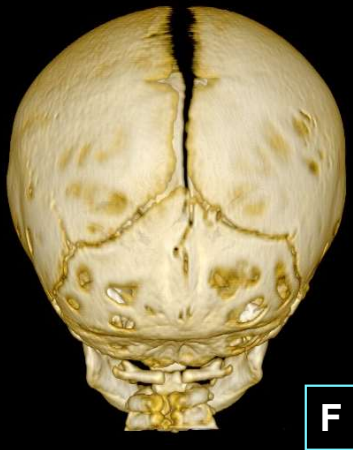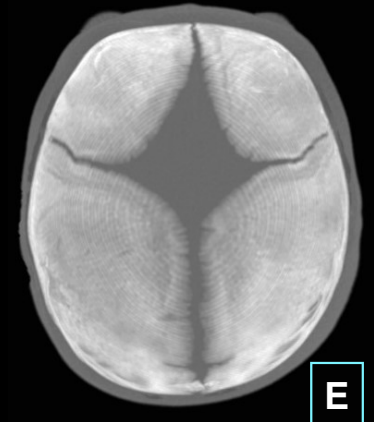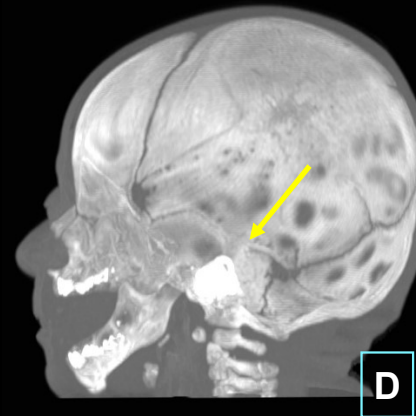
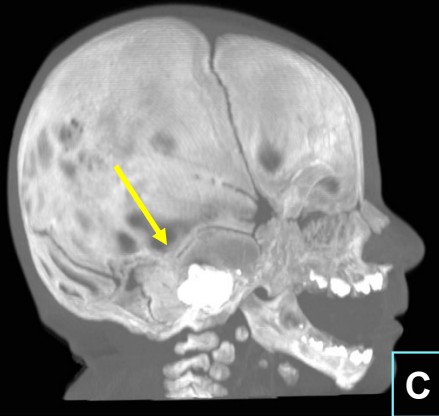
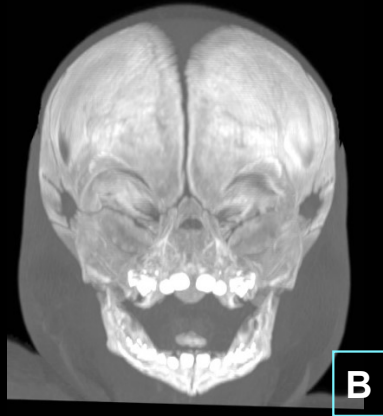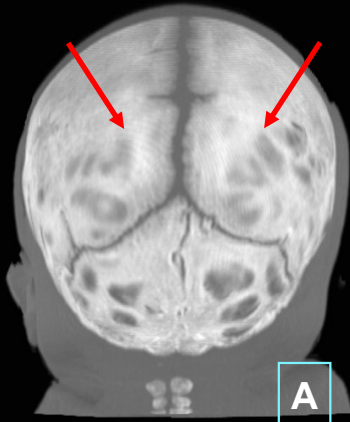Case 6: **Scaphocephaly with early closure of the squamous temporal sutures** (B, C, E and F – red arrows), the sagittal suture is open (D). Signs of craniolacunia in the parietal bones (E and F – yellow arrows).

## CASES



Case 7: **Female, 3 years and 7 months old, Apert Syndrome**, cloverleaf-shaped cranial configuration, with early closure of all sutures, including squamous temporal sutures (Figures D,E, I and J). Extensive areas of craniolacunia in the parietal and occipital bones. An open anterior fontanelle persists (A and F), but with an elongated and tortuous shape.

## CASES



Case 8: **Female, 2 months and 14 days old, diagnosed with Crouzon syndrome, maxillary hypoplasia, hypertelorbitism, brachycephaly, with bone bridges characterizing early partial closure of the squamous temporal sutures (C and D – yellow arrows). There are signs of craniolacuniae in the most posterior regions of the parietal bones and occipital bone (Figure A).**

# TEACHING POINTS!

- ✓ **3D surface volume rendering reconstruction is excellent, but MIP (Maximum Intensity Projection) is essential.**
- ✓ **Check for signs of intracranial hypertension (craniolacunia).**
- ✓ **Axial plan to confirm changes.**
- ✓ **Bossae in parietal bones and parietal bone flattening are important findings to investigate squamous temporal synostosis.**
- ✓ **Search for associated brain alterations (corpus callosum dysgenesis, hydrocephalus, Chiari, etc).**
- ✓ **Always investigate history of prematurity (mainly in case of skull deformities without synostosis).**
- ✓ **Wrong reports can have serious repercussions!**

# CONCLUSION

The evaluation of the squamous temporal suture in craniosynostosis is an exciting challenge, as we have seen different behaviors concerning the skull deformities.

In Diagnostic Imaging we recommend to perform 3-D reconstructions not only with volume rendering for bone tissue, but mainly with MIP technique, which shows the cranial sutures by transparency, reducing the risk of false early closure, especially concerning the squamous temporal suture. This technique also demonstrates better craniolacunias.

As only scarce literature is available and there are many unknown aspects and causes to explain the findings, further research is necessary in a multidisciplinary way. Genetic, histologic, physiologic and other pathways certainly will contribute to shed some light to explain what we have seen at Diagnostic Imaging and Surgery.

The authors propose to add the lateral view of the head in diagrammatic classification of the different types of craniosynostosis, and not only the usual superior view of the head, as it has been showed in literature for decades.

