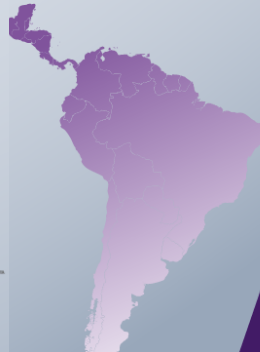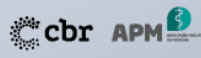


European Course on Pediatric Neuroradiology in Latin America (ECPNR-LATAM)

spr.org.br



3rd Cycle - Module 1
de 1º a 4 de outubro

Local: Sede da APM
Associação Paulista de Medicina
São Paulo - Brasil

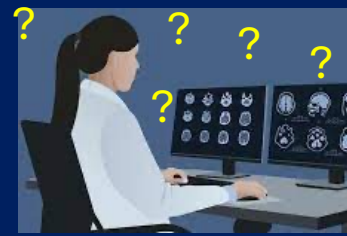CNS Inflammatory diseases – part II

Andrea Righini MD

*Radiology and Neuroradiology Department
Children's Hospital V. Buzzi, Milan, Italy
andrea.righini@asst-fbf-sacco.it*

«No conflicts of interest to disclose»

The core issue



Infective etiology has to be always considered, especially in acute phase

DD among Immune-mediated inflammatory CNS diseases

(MOGAD, AQP4+, ADEM, NMO-neuromyelitis optica, MS, brainstem syndrome, cerebellitis, Arthritis, Myelitis and polio-like syndrome, caudal syndrome-GB

Laboratory tests are mandatory for definitive diagnosis

DD: main groups of disorders that mimic Acquired Demyelinating Diseases (ADS)

- *Systemic diseases with neurological involvement*

- *Systemic Lupus Erythematosus*
- *Neuro-Behçet's disease*
- *Neurosarcoidosis*
- *Vasculitis*
- *CLIPPERS*
- *hemophagocytic lymphohistiocytosis*

- **Metabolic**

- *Mitochondrial (i.e Leigh syndrome)*
- X-linked adrenal leukodystrophy

- **Tumoral**

- Lymphoma

Diseases of the Brain, Head and Neck, Spine 2024-2027: Diagnostic Imaging

Hodler J,

The meninges	
Leptomeninges	Pachymeninges
Neurosarcoidosis	Neurosarcoidosis
Behçet syndrome	IgG4 related disease
Sjogren syndrome and rheumatoid arthritis	Granulomatosis with polyangiitis, ANCA-associated vasculitis
GFAP	Rheumatoid arthritis
Primary and secondary CNS vasculitis	Idiopathic hypertrophic pachymeningitis
Differential: infectious meningitis, subarachnoid hemorrhage, meningioma	Differential: infectious meningitis, meningioma, intracranial hypotension

Pituitary and sellar
Neurosarcoidosis
IgG4 related disease
Granulomatosis with polyangiitis, (ANCA)
CNS histiocytosis

Brainstem
See Table 10-1

Diencephalon (thalamus and hypothalamus)	
Ma1-2, NMDAR, IgLON5, DPPX, AQP4	
Neurosarcoidosis, Behçet syndrome, CNS histiocytosis	
Differential: Wernicke encephalopathy, Whipple disease, deep venous thrombosis, arboviruses	

Cerebellum
Paraneoplastic and autoimmune: ANNA1/Hu, ANNA2/Ri, PCA1/Yo, mGluR1, GAD65, KLH11, Septin-5 and-7 IgGs
Differential: Viral or postinfectious cerebellitis, celiac disease, neurodegeneration such as SCA

Cortical and subcortical area
NMDAR, GABA A/B, DPPX
ADEM, MOG, AQP4, MS
Differential: PML, lymphoma, anoxic injury, inherited leukodystrophies

Striatum
CRMP5/CV2, DR2, NMDAR, LGI1
SLE
Differential: CJD, anoxic injury, toxic metabolic causes, toxoplasmosis, cryptococcus, Wilson disease

Limbic system	
Immune-mediated	Differential diagnosis
Targeting membrane proteins: NMDAR, LGI1, CASPR2, AMPAR, DPPX, GABA B, IgLON5	Viral etiologies: HSV-1, CMV, adenovirus, HHV6, VZV, WNV
Targeting nuclear or cytoplasmic proteins: ANNA1/Hu, GAD65, Ma2/Ta, CRMP5/CV2	Bacterial etiologies: syphilis
	Infiltrative glioma
	Peri-ictal and postictal

Dozens of inflammatory CNS diseases and differential diagnosis entities.

A differential diagnosis labyrinth, to get out of which imaging often NOT sufficient. Clinical features, age, timing, labs NEEDED and merged into a multidisciplinary reasoning

Pathognomonic is the exception NOT the rule!

Pediatric inflammatory CNS diseases

~~infective~~

Immunodisregulation –post-infective

autoimmune

dysimmune

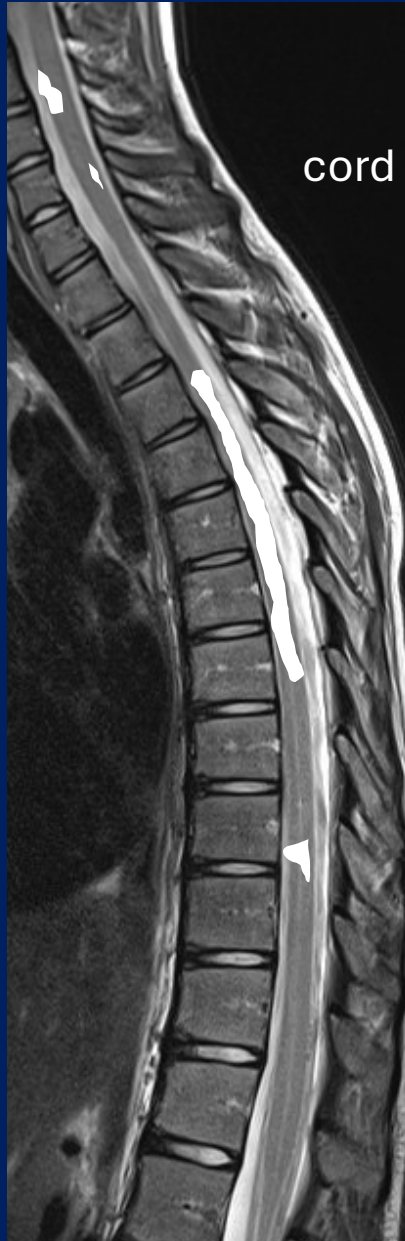MORPHOLOGICAL CRITERIA:

- ADEM, (ADEM-like, ADEM recurrent?)
- Leukoencephalitis
- Cerebritis
- Optic Neuritis
- Myelitis
- Selective Brainstem
- Cauda Equina Neuropathy, cranial nerves
- arterities

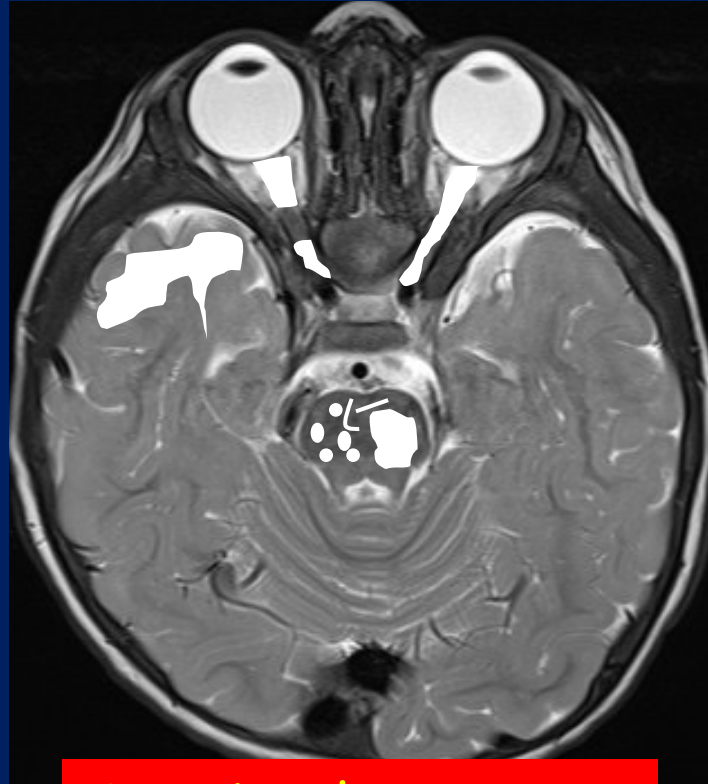
Aetiology-Pathophysiology: MOGAD, NMO related, seronegative lesions, MS

TIME COURSE: One hit, multiple hits, chronic course

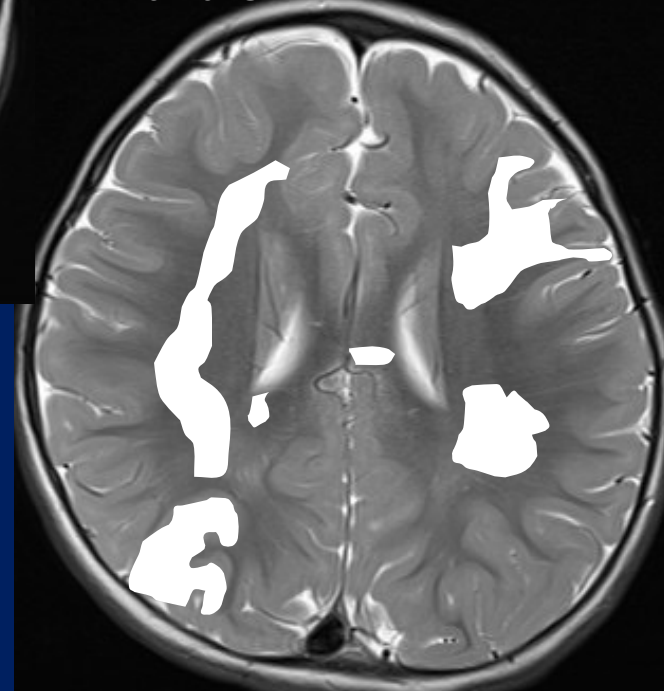
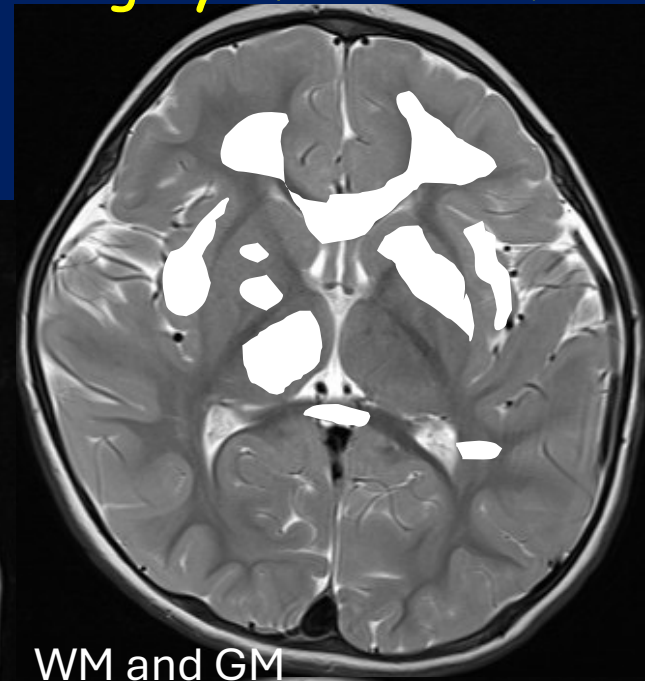CNS inflamm. Ped. T2-FLAIR hyperintense BOTH gray-WM lesions.



optic nerves, brainstem



WM and GM



Acquired
Prevalent White
Matter lesions:
the more difficult
DD diagnosis...

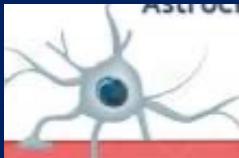PATHOPHYSIOLOGY: 2 MAIN PROTAGONISTS

Antibody related **White Matter** (and gray matter) acquired inflammatory lesions

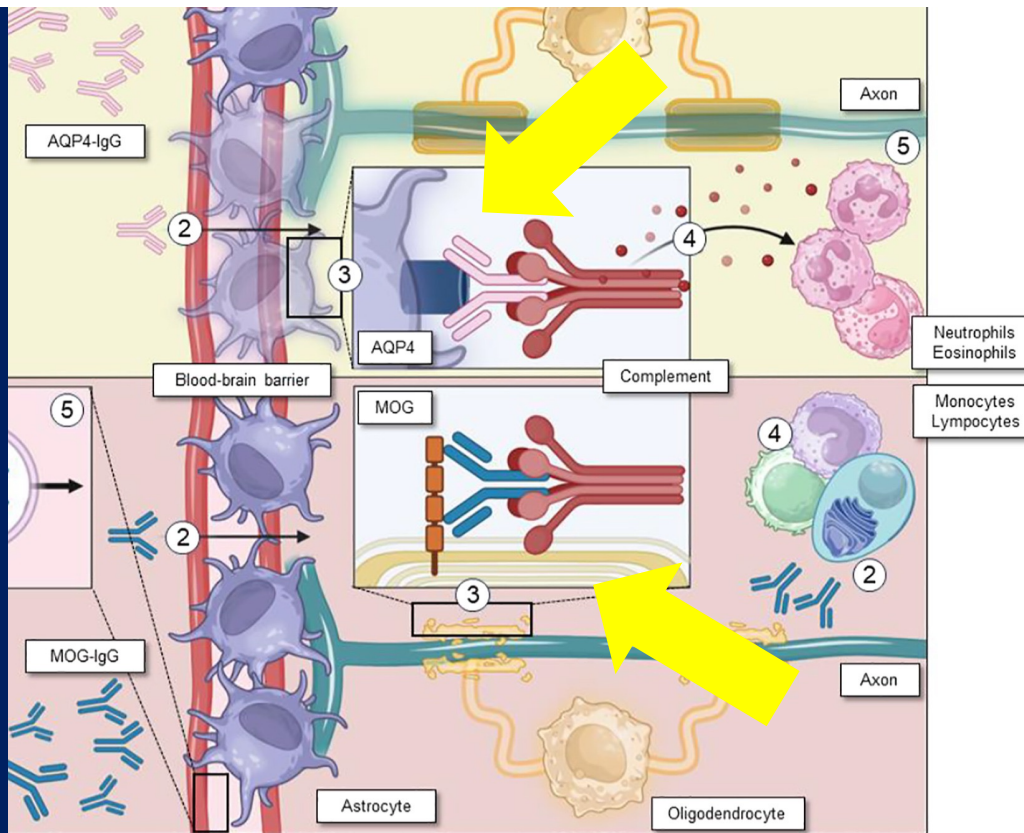
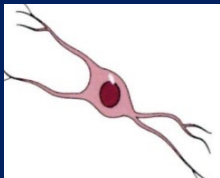
Updates in NMOSD and MOGAD Diagnosis and Treatment. A Tale of Two Central Nervous System Autoimmune Inflammatory Disorders

Laura Cacciaguerra et Al.

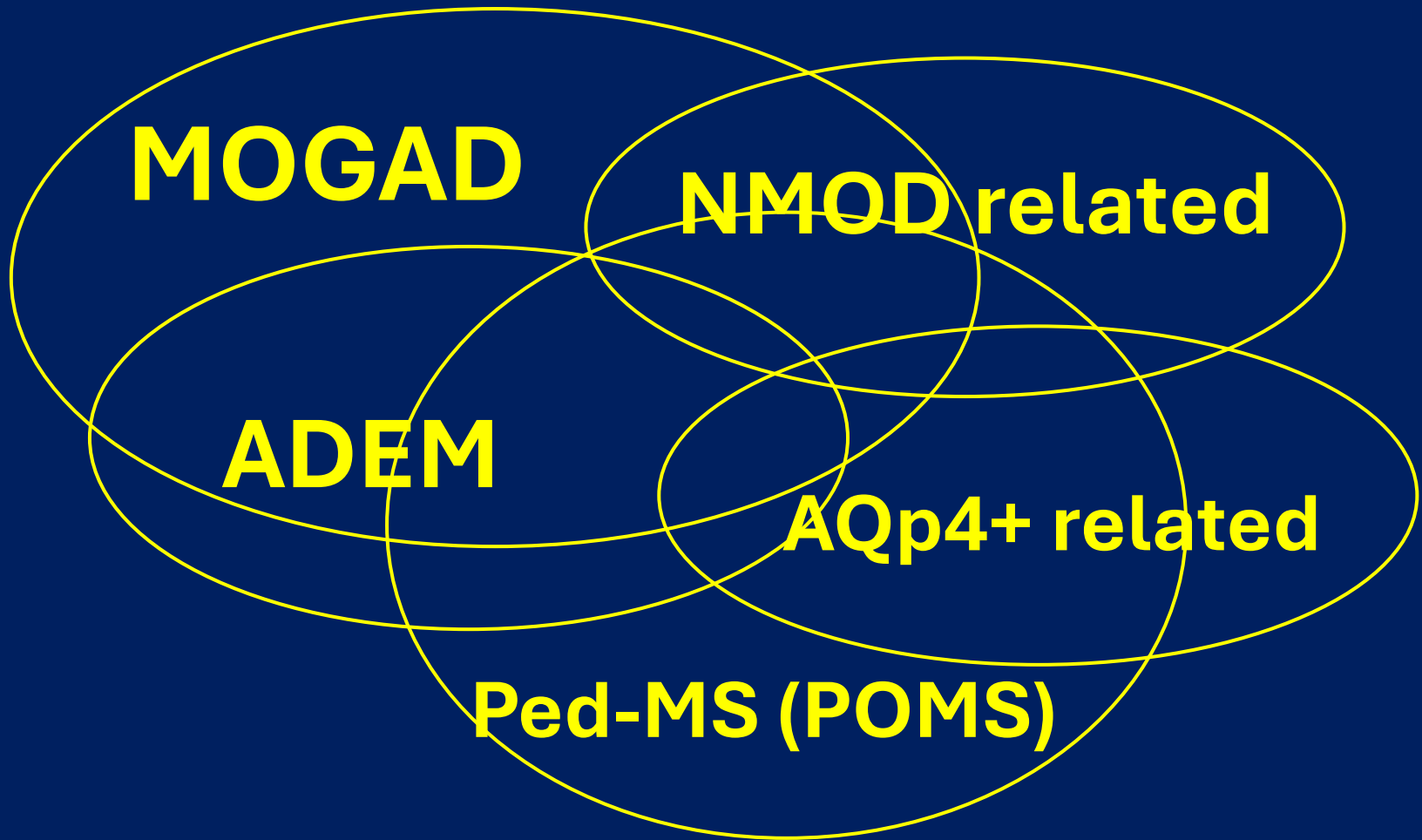
AQP4-IgG
and
astrocytes



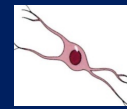MOG
and
oligodendrocytes



Those with mostly **ACQUIRED** White Matter lesions.
JUST PREVALENCE, NOT pure wm LESIONS!

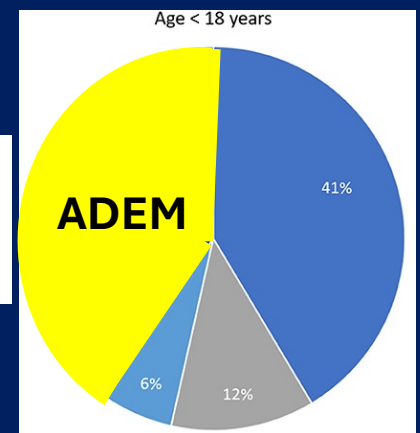


Deeper into MOGAD....



Myelin Oligodendrocyte Glycoprotein Antibody-Associated Disease (MOGAD): A Review of Clinical and MRI Features, Diagnosis, and Management

Elia S et Al.



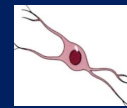
Pediatric Radiology 2025

Neuroimaging spectrum of **myelin oligodendrocyte glycoprotein antibody**-associated disease with brain involvement: description of various cerebral syndromes. Young Hun Choi et Al.

MOG antibody-associated disease (MOGAD) leading cause of acquired demyelinating syndromes **manifesting as (ADEM)**, neuromyelitis optica spectrum disorder (NMOSD) without anti-aquaporin-4 antibodies, optic neuritis, and transverse myelitis

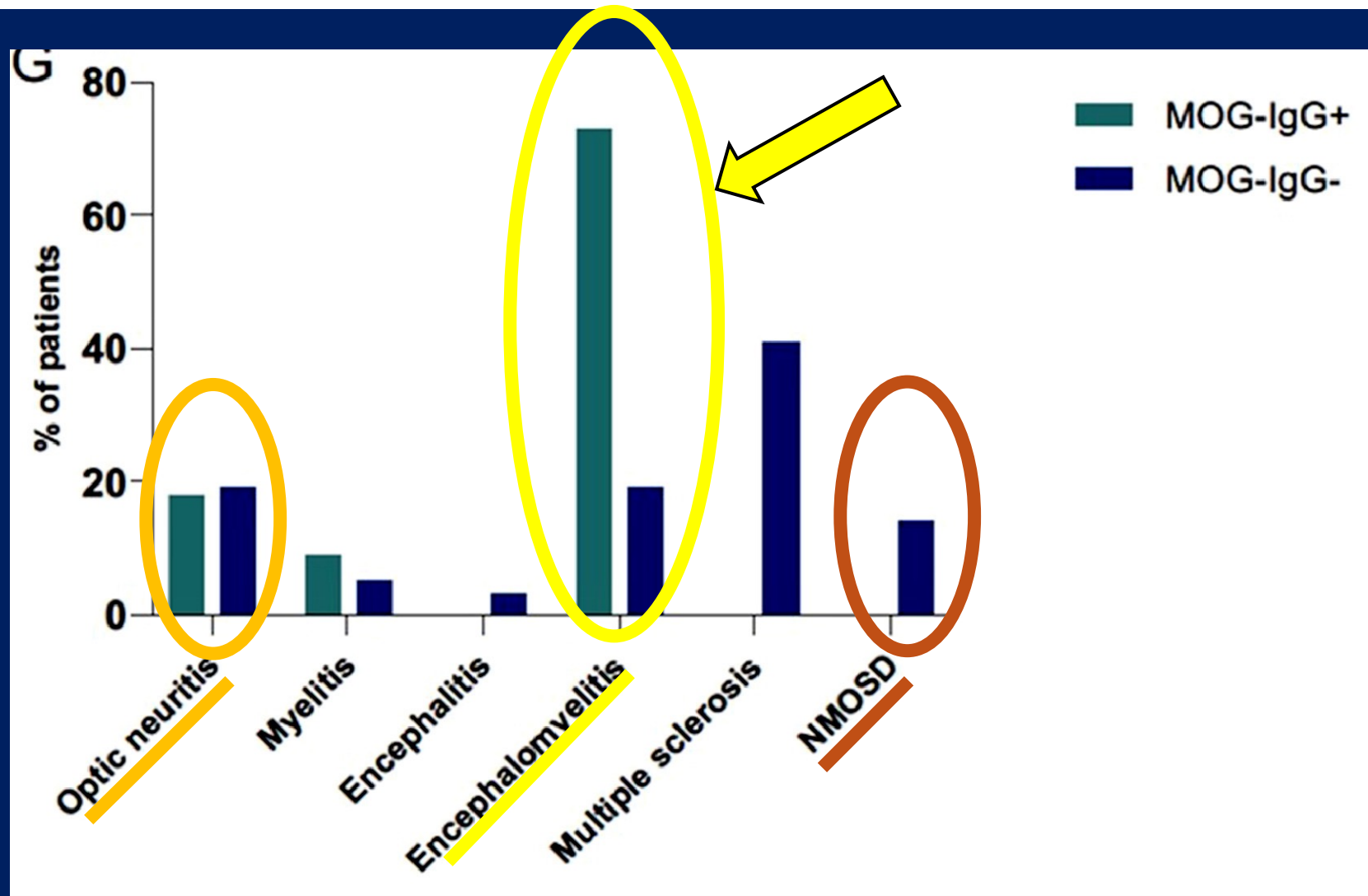
	Acute disseminated encephalomyelitis	Cortical encephalitis	Aseptic meningitis	Tumefactive demyelinating lesion	Cerebellitis/brainstem encephalitis
Key images					
Key findings	<ul style="list-style-type: none"> Most common phenotype Younger age than others Often atypical features (subcortical location (44%) or small lesions (31%)) 	<ul style="list-style-type: none"> Cortical swelling & ↑ T2 signal No white matter involvement 	<ul style="list-style-type: none"> Localized leptomeningeal enhancement / Sulcal FLAIR-hyperintensity 	<ul style="list-style-type: none"> Solitary lesion mimicking a tumor 	<ul style="list-style-type: none"> T2-hyperintense lesions involving the cerebellum and/or brainstem.

Deeper into MOGAD....

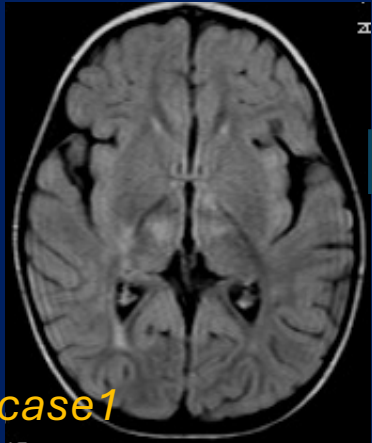
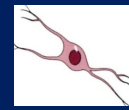

Clinical and neuroimaging characteristics of MOG autoimmunity in children with acquired demyelinating syndromes

Michela Ada Noris Ferilli et Al.

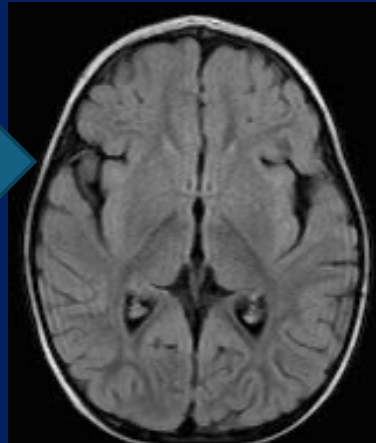


Deeper into MOGAD....



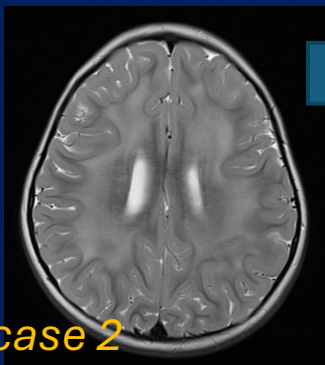
case1

acute

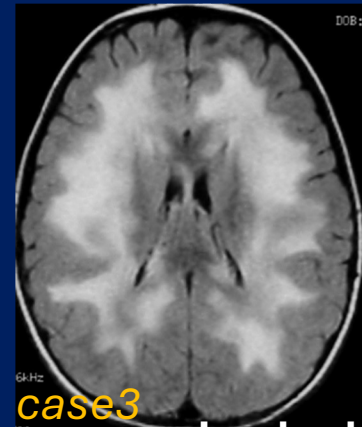
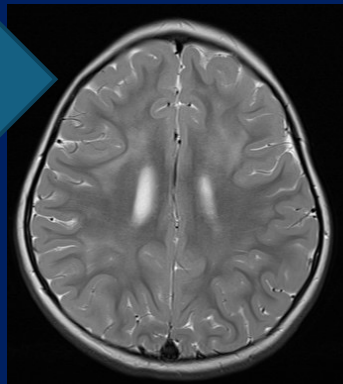


follow-up

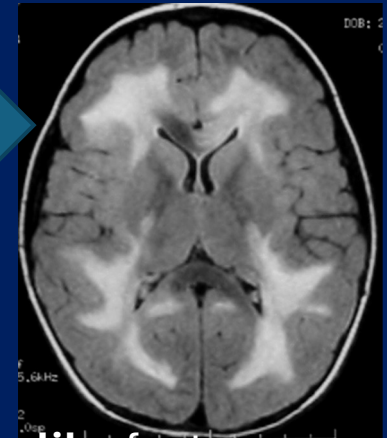
frequent rapid resolution (>50%),
*but prolonged forms or relapsing
may be present*



case 2

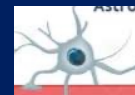

case3



Leukodystrophy like features,
but clinical data help..

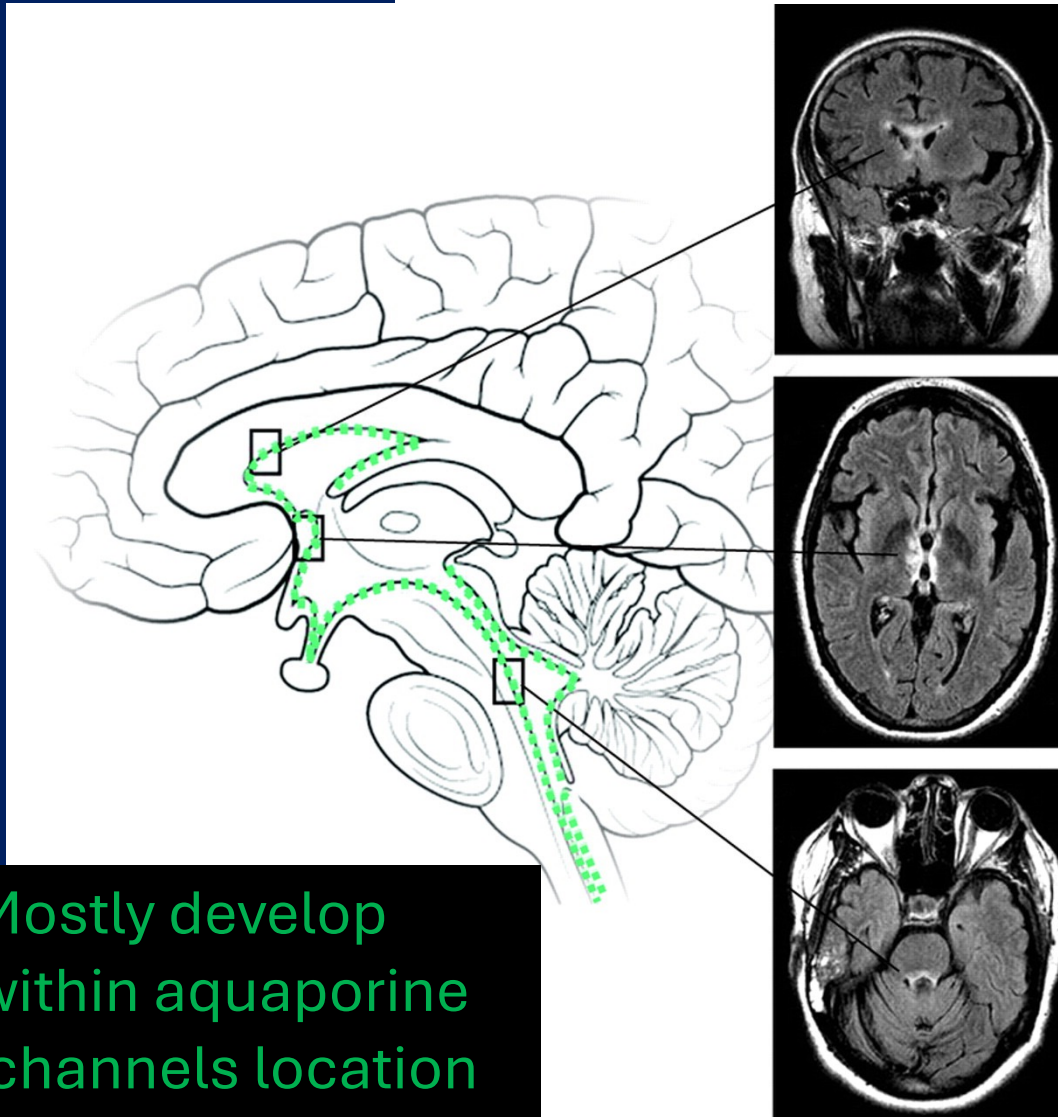
Deeper into AQP+ lesions



Neurology 2007.

Aquaporin-4, homeostasis, and neurologic disease

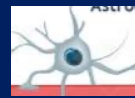Eduardo E. Benarroch, et Al.



Mostly develop
within aquaporine
channels location

NMSOD AQP4+

Deeper into AQP+ lesions

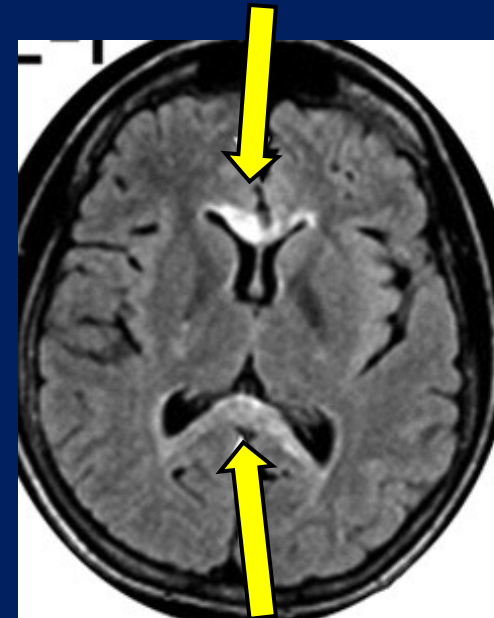
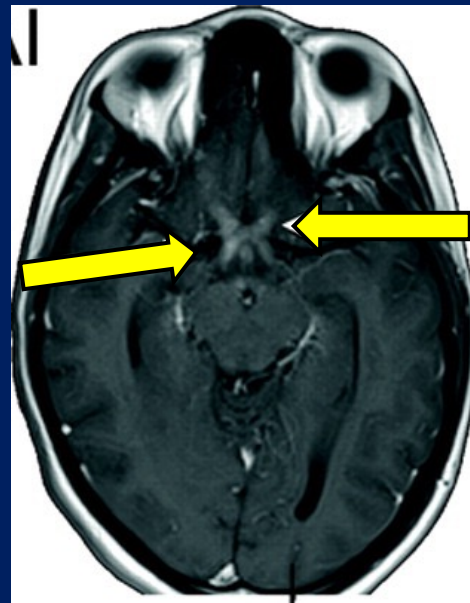
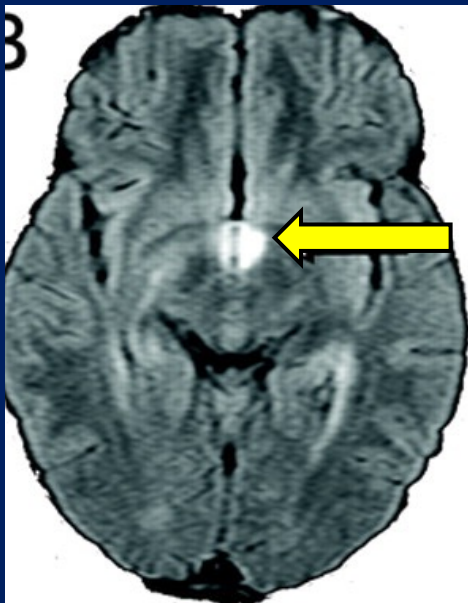


Neurology 2008.

CNS aquaporin-4 autoimmunity in children

A. McKeon

- **periventricular** regions
- **hypothalamic**, thalamic, and diencephalic lesions;
- long spindle or **radial white matter** signal change extending from the lateral ventricles (unlike the short, pericallosal-confined Dawson's fingers of MS);
- white matter abnormalities confluent,
- **brainstem and cerebellar lesions adjacent to the aqueduct and fourth ventricle.**



Deeper into NMOD and NMOD related

DD AQP4-seropositive versus AQP4-seronegative NMOSD

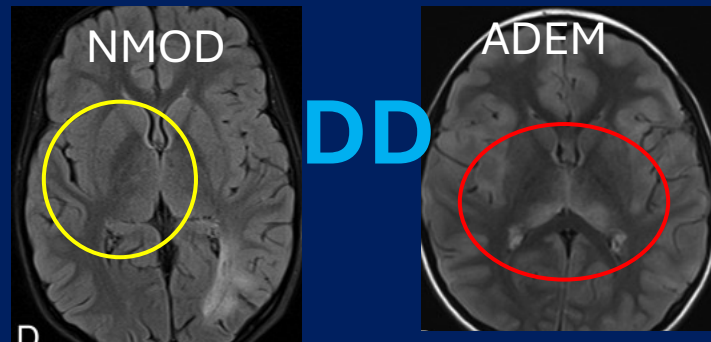
AQP4-seronegative NMOSD:

- bilateral optic neuritis
- simultaneous optic neuritis and transverse myelitis,
- younger age
- monophasic course

AJNR 2019

Brain MRI Findings in Pediatric-Onset Neuromyelitis Optica Spectrum Disorder: Challenges in Differentiation from Acute Disseminated Encephalomyelitis.

E Bulut et Al.



Although overlap in MR imaging findings, **thalamic or internal capsule involvement** could be used to differentiate pediatric-onset NMOSD from ADEM.

Deeper into Ped MS

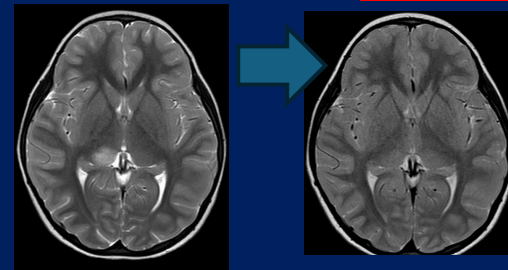
Pediatric-MS (POMS) imaging **DD** MS adulthood

- Larger average lesions
- More numerous at first exam
- Poorly demarcated
- More common iuxtacortical
- More frequently cerebellum and brainstem
- More enhancing lesions at onset
- More similar to ADEM than in adults

Pediatric MS imaging **DD** **ADEM**

ADEM

- Lesions **bilateral (87%),**
- both supra-and infratentorial (50%),
- **basal ganglia (50%).**
- Rare periventricular, perpendicular to the corpus callosum, or black holes.
- **Spinal cord (up to 75%)**
- **25% Gd enhancement.**
- **Complete resolution 45%. Partial resolution 51%, no resolution 4%**



Deeper into Ped MS

Ped. Radiol. 2020. **Pediatric multiple sclerosis: from clinical basis to imaging spectrum and differential diagnosis.** Igor G. Padilha, Ana P. A. Fonseca, Ana L. M. Pettengill, Diego C. Fragoso, Felipe T. Pacheco, Renato H. Nunes, Antonio C. M. Maia Jr, Antônio J. da Rocha

- MS **relapse tends to occur early**, and the recurrence rate is high,.
- The vast majority is relapsing–remitting,.
- The first presentation optic neuritis, sensory disturbances, and cerebellar or motor symptoms
- **Absence of clinical encephalopathy** may distinguish clinically isolated syndrome from acute disseminated encephalomyelitis (ADEM)

FIRST CLINICAL ATTACK

International Pediatric M S Study Group (IPMSSG) diagnostic criteria 2012

Selected
criteria

<12 yrs

ADEM attack followed by one clinically isolated syndrome more than 3 months after with new MRI findings (multifocal lesions) criterion for dissemination in space

>12 years

A clinically isolated syndrome with MRI findings criteria for dissemination in space and in time associated with a simultaneous presence of asymptomatic gadolinium-enhancing and non-enhancing lesions [dissemination in time]

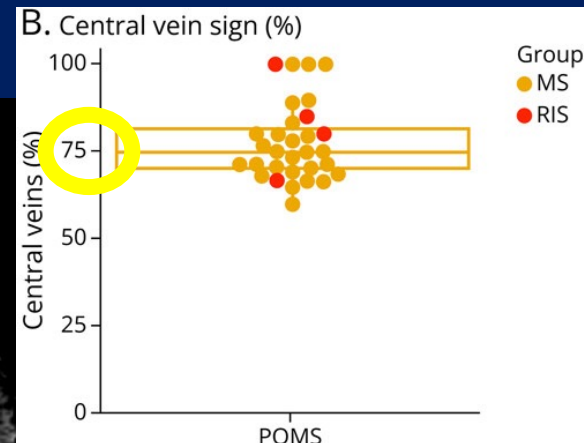
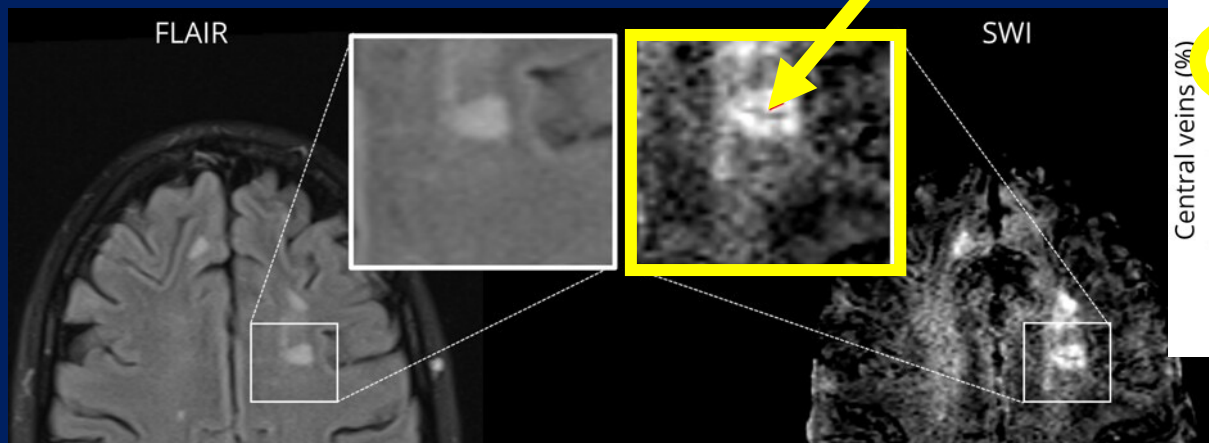
Deeper into Ped MS

Update 2024 Mc Donald's criteria with SWI imaging role: **CVS positivity in $\geq 40\%$ of lesions.**

Neurology, September 2025 .

Prevalence of the **Central Vein Sign on Susceptibility-Weighted** Imaging in People With Pediatric-Onset Multiple Sclerosis. [Joseph Kuchling et Al.](#)

CVS great potential for inclusion also in pediatric MS diagnostic criteria.



Mult. Scler. 2023.

Susceptibility-based imaging aids accurate distinction of pediatric-onset MS from myelin oligodendrocyte glycoprotein antibody-associated disease. Simone Sacco et Al.

CVS+ distinguished POMS cases from MOGAD cases with ROC = 1, $p < 0.0001$, (cutoff 41%).

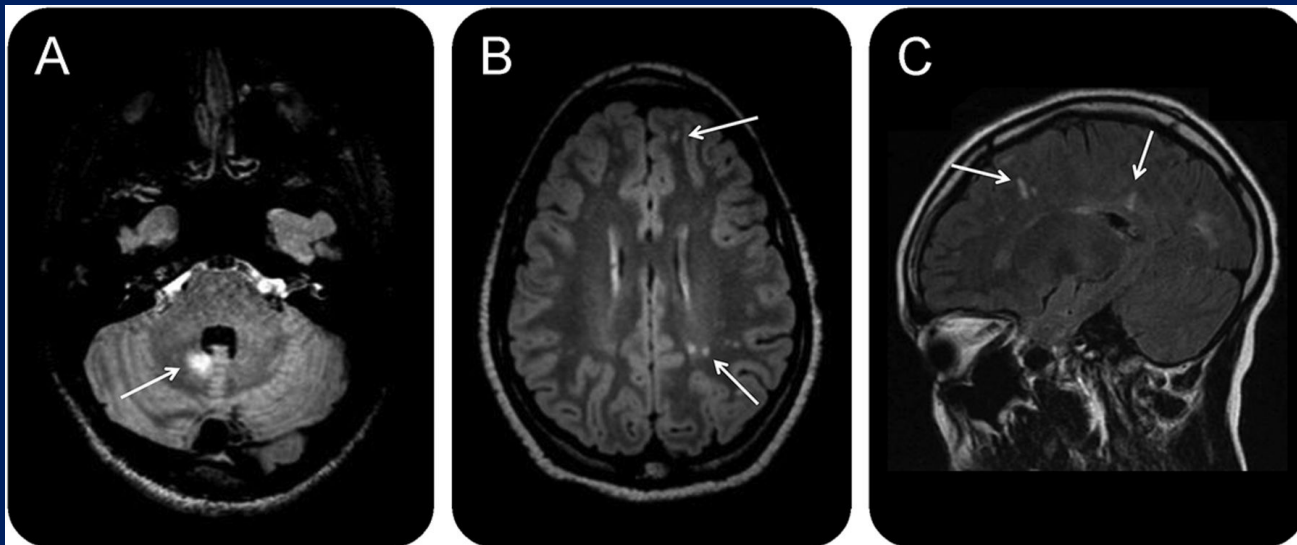
Deeper into Ped MS

Radiological Incidental finding (RIS)

Neurology 2017. **Radiologically isolated syndrome in children: Clinical and radiologic outcomes**, Naila Makhani et Al.

Children with incidental MRI findings highly suggestive of CNS demyelination. -

- Children with **RIS** had a substantial risk of subsequent clinical symptoms and/or radiologic evolution.
- **Oligoclonal bands in CSF and spinal cord lesions** associated with an increased risk of develop clinical event.



Implications of the International Paediatric Multiple Sclerosis Study Group consensus criteria for paediatric acute disseminated encephalomyelitis: a nationwide validation study

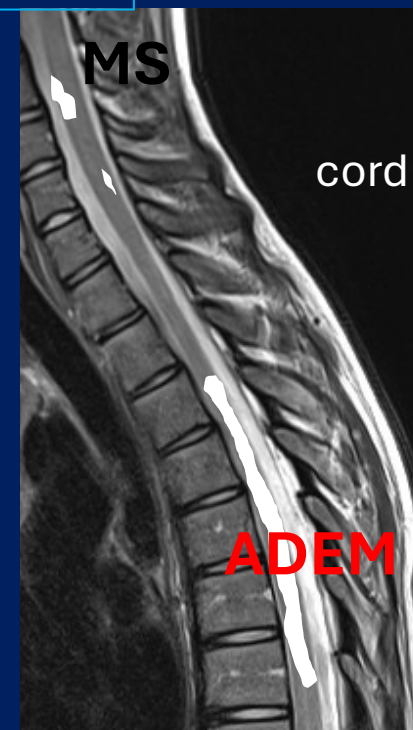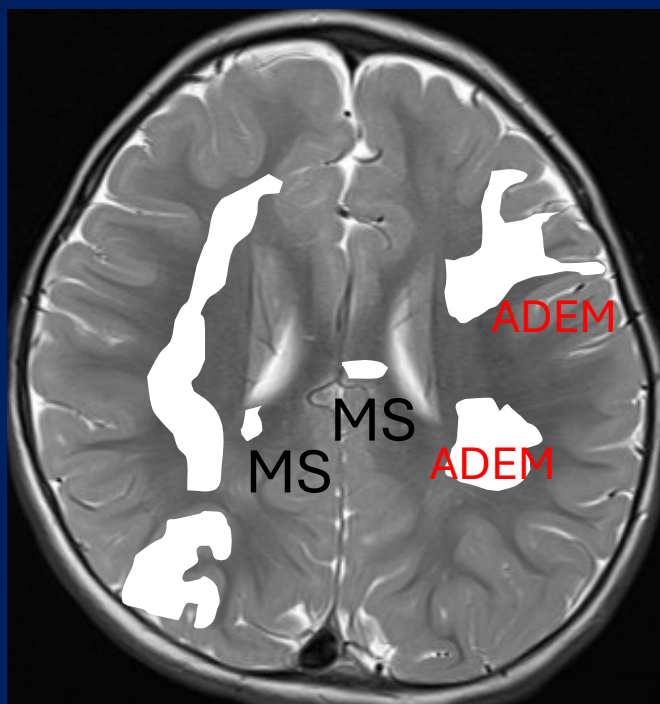
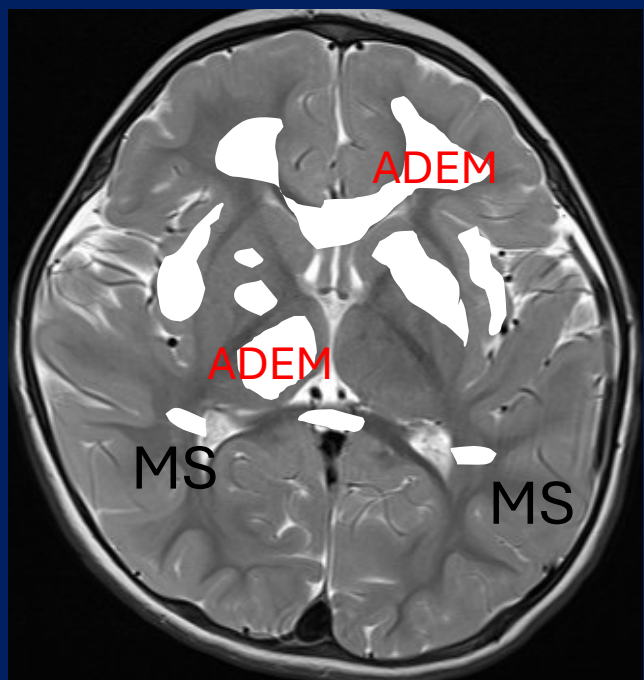
Magnus S Boesen et Al. 2018

MS 2 sets of MRI criteria to distinguish the first attack in MS from monophasic **ADEM**.

1) criteria : (a) **corpus callosum perpendicular lesion**; (b) sole presence of well-defined lesions; (c) **NO** basal ganglia or thalamus lesions.

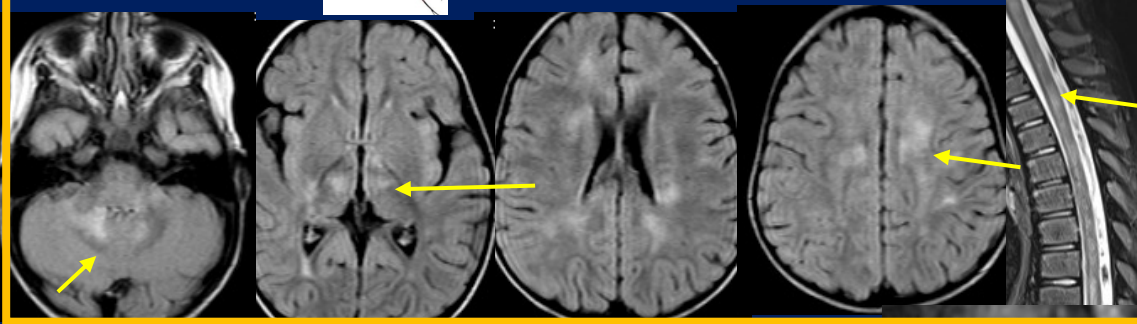
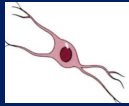
2) criteria a) sole presence of well-defined lesions; (b) corpus callosum long axis perpendicular lesions; (c) **NO** diffuse, poorly demarcated, large lesions; (d) **YES** black holes.

DD first attack of MS and ADEM

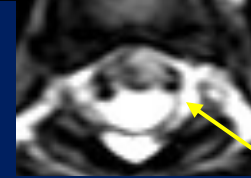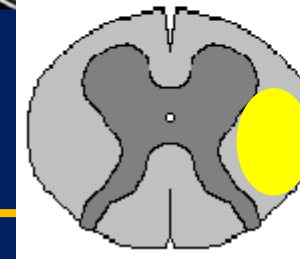
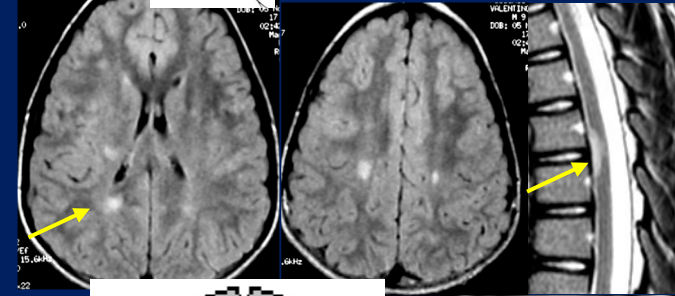
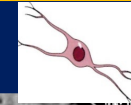


SPINEAL CORD: »typical« features **DD** based aetiology, *but CAVEAT frequent exceptions!*

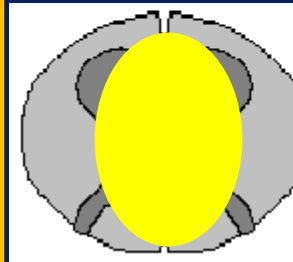
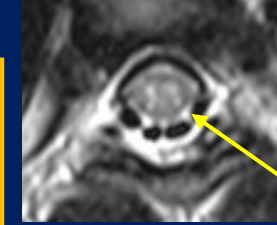
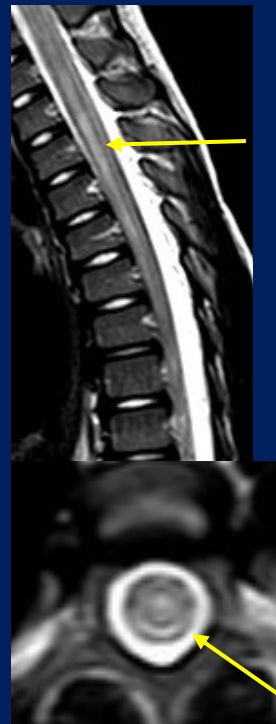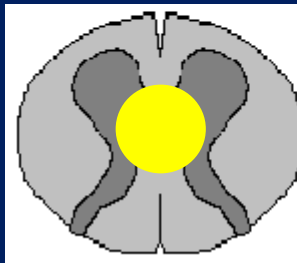
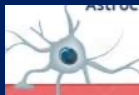MOGAD



MS



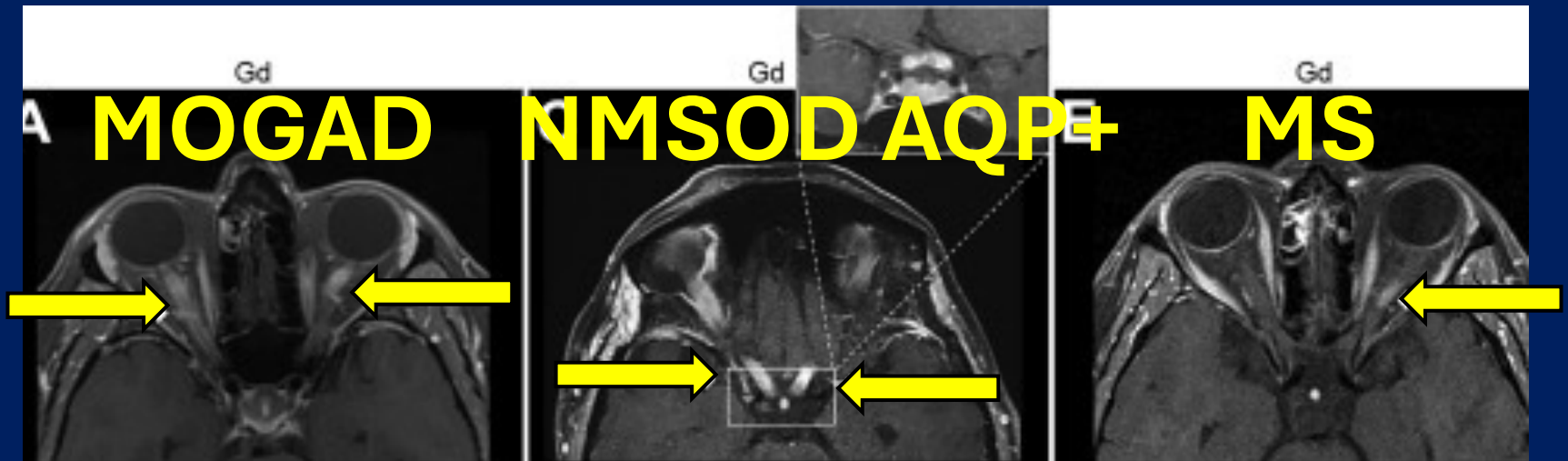
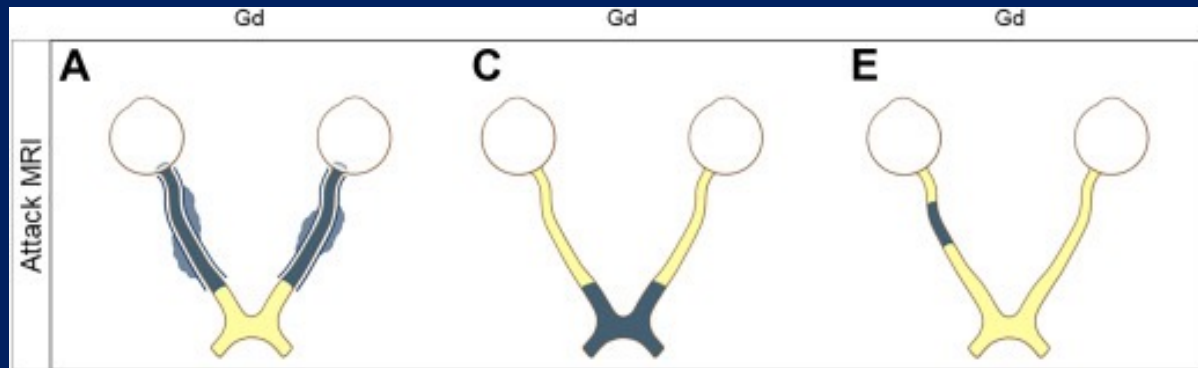
AQp4+



optic nerve involvement: *differences*

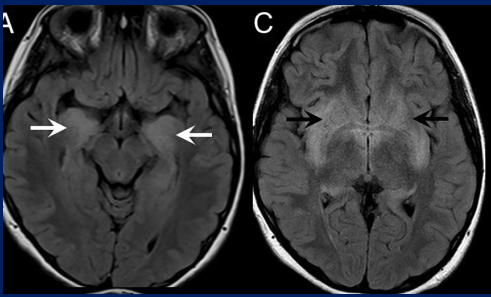
Updates in NMOSD and MOGAD Diagnosis and Treatment A Tale of Two Central Nervous System Autoimmune Inflammatory Disorders

Laura Cacciaguerra et Al.



Prateek Malik. **Infection and inflammation: radiological insights into patterns of pediatric immune-mediated CNS injury.** *Neuroradiology 2022*

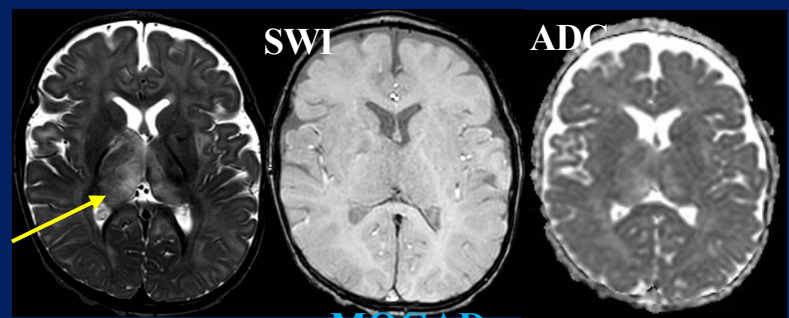
Anti NMDAR encephalitis the presence of IgG against NMDA receptors. Most common type of immune-mediated limbic encephalitis.



MRI normal (~ 65%), followed by a limbic encephalitis pattern]. striatal encephalitis

BASAL GANGLIA AS MAIN TARGET

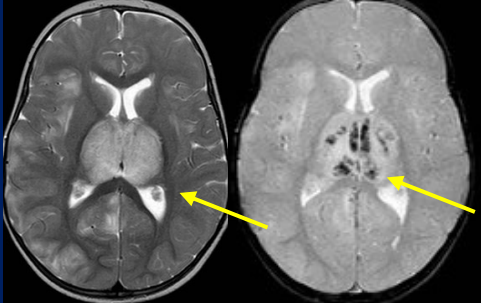
DD Differential Diagnosis



febrile illness-related epilepsy syndrome (**FIRES**), acute encephalitis with refractory repetitive partial seizures (AERRPS) FIRES, following a febrile illness with fever occurring 2 weeks to 24 hours prior to onset of refractory SE. no pathogen has been isolated in a vast majority of cases. Autoimmunity has also been implicated with reports of anti-glutamate receptor antibodies or anti-glutamic acid decarboxylase antibodies and IL6/IL8 obtained from CSF. including SCN2A and PCDH19 have been reported.

Acute Necrotizing Encephalopathy

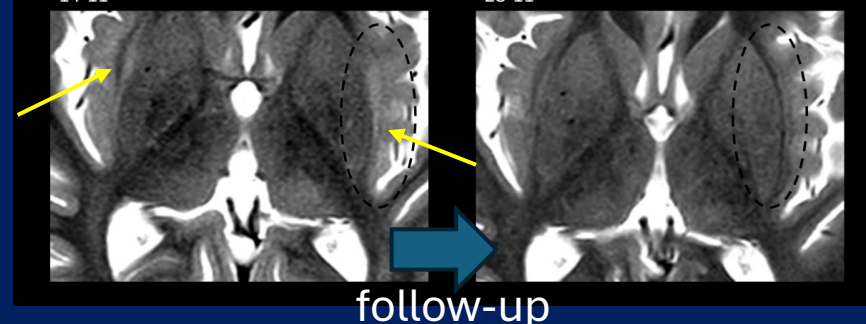
Vivek Paj, 2024
Pediatric CNS Inflammation and Infection: A Review of Immunopathology and Radiology



ANE1 due to RANBP2 mutation mutations in the Ran Binding Protein 2 (RANBP2), susceptibility allele for familial/recurrent cases

ANE is a parainfectious encephalopathy, triggered by a viral infection (influenza A, influenza B, novel influenza A/H1N1, parainfluenza, human herpes virus 6, herpes 7, etc.). an exaggerated immune response to infection (cytokine storm)

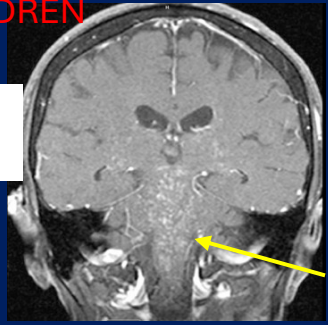
Symmetric T2 hyperintensity involving the caudatum, 'caustral sign' has been reported, however, this is not pathognomonic FIRES



CLIPPERS (Chronic Lymphocytic Inflammation with Pontine Perivascular Enhancement Responsive to Steroids)

- Multiple aetiologies and differential DD challenge
- **Gd enhancing nodules <3 mm**

RARE IN CHILDREN



Kshipra Joshi, Am J Med 2019

BRAINSTEM TARGET

Hemophagocytic lymphohistiocytosis (HLH)

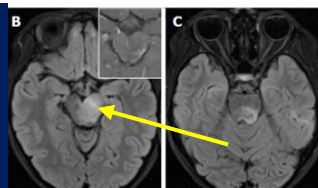
abnormal, excessive activation of the immune system.

Primary HLH, genetic or familial HLH, defects in genes involved in cytotoxic granule exocytosis

Secondary HLH to infection, malignancy, or rheumatologic condition, leukemias

Front. Neurol. 2024
Bickerstaff encephalitis in childhood: a review of 74 cases in the literature from 1951 to today
 Luca Gregorio Giaccari et Al.

AJNR 2021
MRI Patterns in Pediatric CNS Hemophagocytic Lymphohistiocytosis P. Malik,

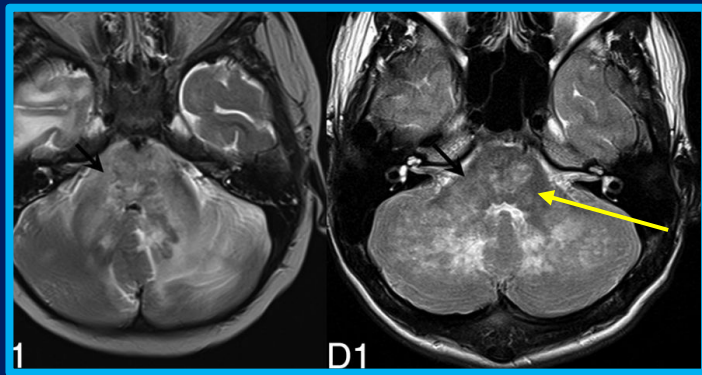


Quattrocchi C World J Radiol. 2016

Bickerstaff brainstem encephalitis (BBE) rare autoimmune disease, presence of the antiganglioside antibody, anti-GQ1b and anti-GM1
RARE IN CHILDREN

DD

The brainstem–predominant pattern similar to CLIPPERS, but extension of T2 signal change beyond the enhancing nodule

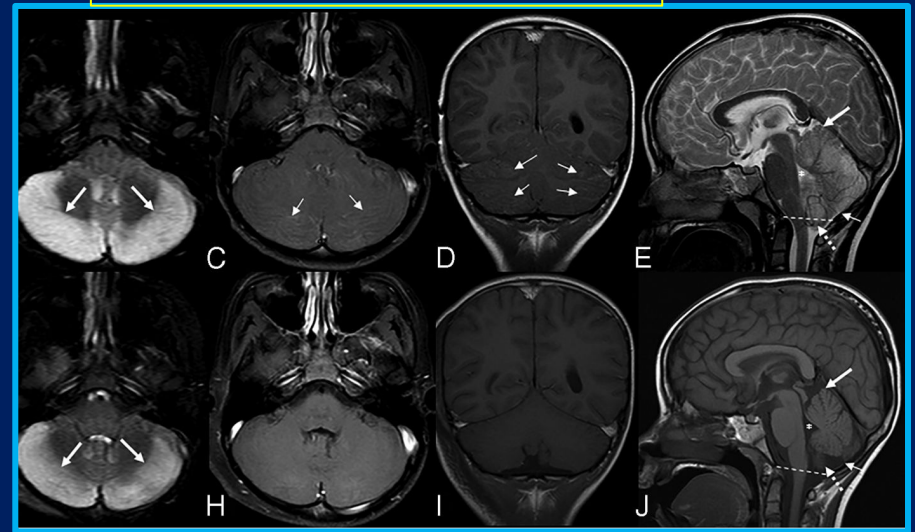
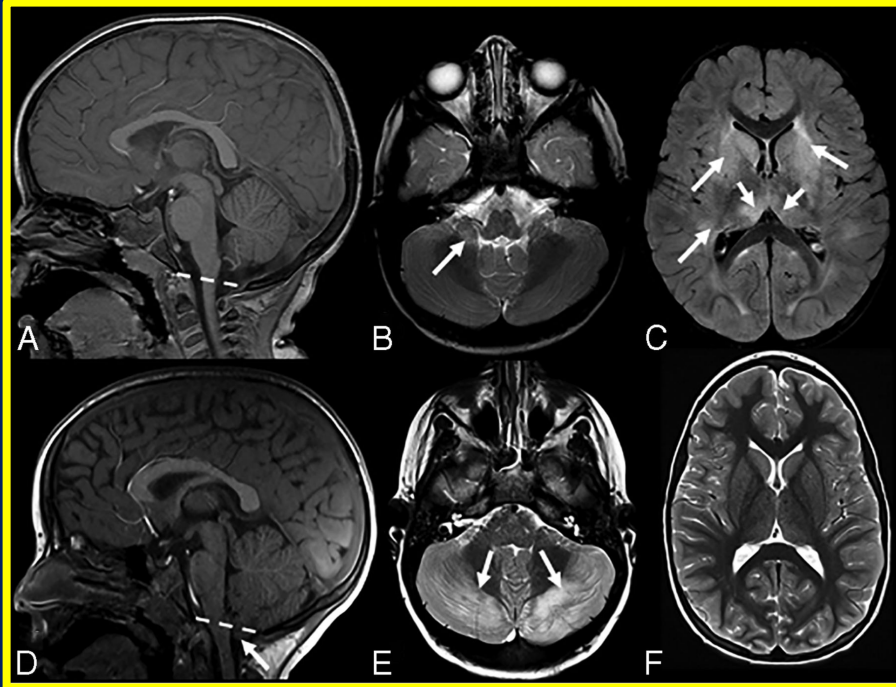


AJNR 2021. **Can MRI Differentiate between Infectious and Immune-Related Acute Cerebellitis?** A Retrospective Imaging Study. G. Orman et Al.

T2 hyperintense signal in brainstem and brain may be indicative of immune-related acute cerebellitis, and downward herniation may be indicative of infectious acute cerebellitis.

CEREBELLAR TARGET

infective



Eur J Paediatr Neurol 2023. **Autoantibody status, neuroradiological and clinical findings in children with acute cerebellitis.** L Quack **36 cerebellitis children**

- MRI alterations in 83 %.
- Anti MOG-abs (5pt), GFAP α -abs (1pt) in CSF, GlyR-abs (1) in CSF, mGluR1-abs (1)

thanks