

Introduction

Neurovascular Diseases across the Pediatric Age Spectrum



Khalid Al-Dasuqi, MD^{a,*}, Darren B. Orbach, MD, PhD^b,
Joanne M. Rispoli, MD^a

KEYWORDS

- Pediatric cerebrovascular disease • Cerebral arteriopathy • Arteriovenous malformations
- Aneurysms • Pediatric neurovascular interventions

KEY POINTS

- Advancements in neuroimaging techniques and improved clinical understanding of pediatric neurovascular disorders have led to increased recognition and diagnosis of these conditions.
- The etiology of cerebrovascular diseases in children differs significantly from adults, often involving unique genetic and developmental factors.
- Effective management of pediatric cerebrovascular disease requires a coordinated, multidisciplinary approach, involving pediatric neuroradiologists, neurosurgeons, neurologists, geneticists, and other specialists to ensure optimal care and intervention.

BACKGROUND

Pediatric cerebrovascular diseases represent a unique group of conditions that differ from adult homologs in presentation, pathophysiology, and management. In addition, pediatric neurovascular pathologies not infrequently occur in the context of multisystem disorders that are important to recognize and address. Although pediatric cerebrovascular disease is rare, morbidity can be high, effects can be lifelong, and knowledge of disease entities is imperative for early diagnosis and optimal treatment. Diagnosis and management require an interdisciplinary approach that includes neuroradiologists, neurologists, neurosurgeons, and neurointerventionalists. This special edition of *Neuroimaging Clinics of North America* focuses on the neuroimaging aspects of commonly encountered pediatric neurovascular disorders, emphasizing key concepts that are relevant to clinical radiologists interpreting diagnostic neuroimaging studies. The study by Schroff M and

colleagues provides an in-depth consideration of practical issues involved in the neuroimaging of children, emphasizing cross-sectional imaging modalities, while the study by Tierradentro-Garcia and colleagues' article, "Catheter-directed Cerebral and Spinal Angiography in Children," in this issue covers practical issues involved in the conduct of catheter-directed neuroangiography in children. Commonly encountered neuroimaging presentations of pediatric neurovascular disorders and age-oriented differential diagnoses are covered in the study on hemorrhagic stroke by Leach and colleagues' article, "Imaging of Hemorrhagic Stroke in Children," in this issue; the study on arterial ischemic stroke by Fileva and colleagues' article, "Arterial Ischemic Stroke in Children," in this issue; and the study on neurovascular trauma by Lee SK and colleagues. Given the fundamental role of cerebral arteriopathies as a cause of childhood arterial ischemic stroke, a study covering the neuroimaging features of commonly encountered

^a Department of Radiology, Boston Children's Hospital, 300 Longwood Avenue, Boston, MA 02115, USA;

^b Neurointerventional Radiology, Boston Children's Hospital, 300 Longwood Avenue, Boston, MA 02115, USA

* Corresponding author.

E-mail address: k.aldasuqi@gmail.com

pediatric cerebral arteriopathies by Kelson and colleagues' article, "Steno-occlusive Intracranial Large Vessel Arteriopathies in Childhood: A Pattern Oriented Approach to Neuroimaging Diagnosis," in this issue is included. Since vascular malformations are among the most common causes of neurologic symptoms in children presenting for diagnostic neuroimaging, a series of studies are dedicated to fetal neurovascular malformations (Qureshi and colleagues' article, "Neurovascular Malformations in the Fetus and Neonate," in this issue), intracranial vascular malformations of childhood (Karim S and colleagues), and spinal vascular malformations of childhood (Shaibani A and colleagues). In this introduction, the authors provide a brief general overview of pediatric neurovascular disorders, from the perspective of imaging approaches, and pathomechanisms, emphasizing specific entities and presentations within distinct age groups, from fetal life through childhood.

FETAL PERIOD

Imaging Considerations

According to the American College of Radiology-American College of Obstetricians and Gynecologists-American Institute of Ultrasound in Medicine-Society for Maternal-Fetal Medicine-Society of Radiologists in Ultrasound, practice parameter guidelines, imaging of the head, face, and neck is a required component of the second-trimester anatomic survey. Although second-trimester screening is typically performed, much fetal cerebrovascular disease is detected in the third trimester. Typically, utilizing an abdominal transducer greater than or equal to 3 MHz is appropriate, with 4 standard views of the fetal head including the transventricular, falx, cavum, and transcerebellar views.¹ Color Doppler can be utilized for evaluation of arterial and venous flow.

Fetal abnormalities identified on screening ultrasound are subsequently referred for MR imaging if a finding cannot be resolved on ultrasound, requires confirmation, or if additional findings are expected. MR imaging protocols include fast T2-weighted imaging with half Fourier single-shot turbo spin-echo and balanced steady-state free precession in 3 orthogonal planes for evaluation of brain parenchyma, T1W images to evaluate for hemorrhage, and echo-planar imaging to evaluate for hemorrhage or mineralization.² DWI can also be helpful to evaluate for destructive brain processes or infarction in the setting of cerebrovascular malformations.³ Given that fetal movement is a frequent contributor to image degradation, quality

control through image review of crucial sequences relevant to the clinical question at hand, before the imaging session is ended, is critical.

Pathomechanisms

Development of the cerebrovascular system is a complex process, genetically driven but subject to environmental and epigenetic demands of embryogenesis. Soon after the neural tube can no longer be nourished by simple diffusion, during the first step of vasculogenesis, multipotent mesodermal cells are differentiated into endothelial cell precursor angioblasts. These angioblasts form primitive longitudinal vessels and a plexus of non-differentiated endothelial cells that proliferate on the surface of the neural tube to form a vascular network, which is soon fixed to the surface by a fibrous stroma called the meninx primitiva.⁴ Invagination into the monoventricle of the closed neural tube carries an island of vascularized meninx primitive into each of what will become the 2 cerebral hemispheres, allowing for oxygenation and nutrient transfer from both the surface and from within the ventricle; these vascularized islands are the precursors of the choroid plexus.⁴

With increasing metabolic demands of the growing embryo, the vascular supply becomes insufficient and the process of sprouting (also known as [A.K.A.] proliferative) angiogenesis occurs. In contrast to intussusceptive (A.K.A. nonproliferative) angiogenesis that occurs in the later stages of central nervous system (CNS) vascular development, sprouting angiogenesis is initiated by the extension of endothelial tubes from existing vessels as directed by chemotactic angiogenic signals (ie, vascular endothelial growth factor A [VEGF-A]).⁵ As the brain grows, VEGF-A produced by thickening, insufficiently perfused tissue stimulates sprouting angiogenesis. The formation of the surface brain arteries has been described as occurring in 7 stages in Padgett's classic work,⁶ with bifurcation of a primitive internal carotid artery and multiple fetal carotid-vertebrobasilar anastomoses in early stages progressing to the more classic circle of Willis anatomy and vascular territory formation by stage 7 at 52 days.

The embryonic choroid plexus serves as a focal point of CNS vascular development, with the earliest formed CNS arteries being choroidal and the early deep CNS venous drainage organized around the embryonic choroid plexus. As the deep venous system initially develops, radially oriented transcerebral medullary veins with ventriculofugal flow connect to the superficial venous vasculature. The anterior embryonic choroid plexus within the developing lateral ventricles

drains to the primitive superior sagittal sinus through a single midline median prosencephalic vein (MPV) of Markowski, while embryonic choroid plexus more posteriorly drains through paired dorsal and ventral diencephalic veins (precursors to the system that forms the basal vein of Rosenthal) to the primitive marginal and primitive tentorial sinuses, respectively. As the cerebral mantle thickens, the subependymal venous system acquires an increasing flow demand, and the subependymal internal cerebral veins form. The internal cerebral veins annex radially oriented transcerebral medullary veins with ventriculopetal flow and drain the anterior embryonic choroid plexus to the posterior segment of the MPV (vein of Galen). Involution of the anterior segment of the MPV within the roof of the third ventricle occurs during the 11th week of gestation under ordinary circumstances. When aberrant embryonic choroidal vascular development results in arteriovenous shunting to the anterior segment of the MPV, the flow-loaded vein fails to involute resulting in the vein of Galen malformation (VOGM), one of several types of congenital arteriovenous lesions covered in the study on fetal neurovascular malformations by Qureshi and colleagues' article, "Neurovascular Malformations in the Fetus and Neonate," in this issue.

A "2 hit hypothesis" has been proposed as the etiology of aberrant vascular development leading to congenital arteriovenous lesions. In this model, a germ line loss-of-function mutation affecting all embryonic cells (asymptomatic in isolation), and a second, spatially restricted somatic loss-of-function mutation in the other allele, affecting only lesional tissue, occurs in response to a localized environmental trigger. Putative environmental triggers include ischemic, infectious, or inflammatory processes though other currently undefined events may be involved.⁷ Homozygous loss-of-function in a gene required for normal vasculogenesis and arteriovenous differentiation results in the formation of a focal choroidal, pial, or dural arteriovenous lesion depending on the location and timing of events.

Some loss-of-function mutations associated with pediatric arteriovenous lesions, such as Ephrin-B2 mutations and ALK1 mutations, contribute to pathologically increased sprouting of the vascular bed (proliferative angiogenesis).⁵ Conversely, other loss-of-function mutations associated with pediatric arteriovenous lesions, such as RASA1 mutations and Ephrin receptor B4 mutations, have been implicated in failed intussusception (nonproliferative angiogenesis). Hereditary vascular malformation syndromes such as hereditary hemorrhagic telangiectasia (HHT) and

capillary malformation-arteriovenous malformation (CM-AVM) syndrome typically involve staged homozygous loss-of-function mutations (one germ line mutation plus one somatic mutation). In contrast, sporadic arteriovenous malformations (AVMs) are typically associated with heterozygous somatic gain-of-function mutations of KRAS and BRAF superfamily genes isolated to lesional tissue. Genetic mutations associated with VOGM have been the subject of multiple studies over the past decade, with recent studies employing whole exome sequencing and single-cell transcriptomics to identify mutations in 6 genes associated with VOGM: RASA1, EPHB4, ACVRL1, NOTCH1, ITGB1, and PTPN11.⁸

It has been hypothesized that in dural sinus malformations (DSMs), aberrant overgrowth of the dural venous sinuses, potentially as a result of aberrant intussusceptive angiogenesis, promotes varying degrees of intraluminal thrombus formation that can lead to the generation of large amounts of VEGF-A during a period of rapid vascular growth. In this setting, disruption of the normal VEGF-A gradient can affect the rate of endothelial cell proliferation and can potentially result in arteriovenous fistulae and maladaptive remodeling of the dural venous sinuses. The postnatal phenotype expressed by DSM includes a range of lesions that variably express different degrees of sinus overgrowth, luminal thrombosis, and arteriovenous shunting as covered in detail by Qureshi and colleagues' article, "Neurovascular Malformations in the Fetus and Neonate," in this issue in the study on fetal vascular malformations.^{9,10}

Pial arteriovenous fistulae, also covered in the study by Qureshi and colleagues' article, "Neurovascular Malformations in the Fetus and Neonate," in this issue, have primarily been described in association with RASA1 and HHT-related germ line mutations, but there is significant overlap with other mutations that have been linked to VOGM. The possibility that a 2 hit model is operative in the pathogenesis of pial AVF is likely but has not yet been thoroughly investigated.

Specific Entities and Presentation

Fetal arteriovenous fistulae such as VOGM may be detected in the third trimester, first by ultrasound (particularly with the use of color Doppler) and then with fetal MR imaging to elaborate the findings. While the malformations themselves are readily discernible, nonvascular brain findings in the prenatal period potentially include brain parenchymal injury in the form of infarction or hemorrhage and ventriculomegaly.¹¹ Fetal imaging of VOGM has recently been shown to reliably predict

the severity of clinical presentation at birth, based on the mediolateral width of the narrowest point of the falcine sinus draining the MPV. Notably, fetuses with a wider sinus are at high risk of an aggressive neonatal clinical course.¹²

Fetal DSMs often present prenatally and are initially detected on fetal ultrasound in the second or third trimester with subsequent evaluation on MR imaging examination. Potential associated findings include hydrocephalus, mass effect on adjacent brain parenchyma, and polyhydramnios.¹³ DSM can occur with concomitant thrombosis, and decrease in size overtime during gestation is a strongly positive prognosticator.⁹

NEONATAL PERIOD

Imaging Considerations

There are many factors that may influence the choice of imaging modality in neonates, including availability of MR imaging and clinical stability of the patient. Ultrasound is often performed as a first-line imaging modality, given ready availability and lack of ionizing radiation; however, ultrasound is limited in field-of-view and evaluation of soft tissue contrast. Computed tomography (CT) may be used if the patient is unstable or if MR imaging is unavailable or contraindicated; however, MR imaging remains the diagnostic test of choice and can be performed within the neonatal intensive care unit in certain facilities.¹⁴

Pathomechanisms

In addition to the fetal vascular malformations previously discussed, hemorrhagic and arterial ischemic stroke are important causes of neonatal neurologic morbidity and mortality. While perinatal hemorrhagic stroke is covered extensively in the study by Leach and colleagues' article, "Imaging of Hemorrhagic Stroke in Children," in this issue, perinatal arterial ischemic stroke is detailed in the study by Fileva and colleagues' article, "Arterial Ischemic Stroke in Children," in this issue. The differential diagnosis of neonatal hemorrhagic stroke is greatly simplified by first considering whether the patient is full term or premature. In term neonates, hemorrhagic stroke is usually due to medullary venous thrombosis, subpial hemorrhage, and coagulopathy. In premature neonates, hemorrhagic stroke is most commonly related to venous thrombosis, coagulopathy, and the spectrum of hemorrhagic germinal matrix pathologies (germinal matrix-intraventricular hemorrhage and periventricular hemorrhagic infarction). All of these entities are covered in detail in the study by Leach and colleagues' article, "Imaging of Hemorrhagic Stroke in Children," in this issue. The pathomechanisms of perinatal arterial ischemic

stroke are multifactorial and are incompletely understood but are well covered in the study by Fileva and colleagues' article, "Arterial Ischemic Stroke in Children," in this issue. A perinatal-specific etiology that is thought to represent an important contributor is that of placental emboli that enter the fetal circulation and then cross a patent foramen ovale.¹⁵ Perinatal changes in maternal hemostasis and thrombophilias likely play an important role as well.¹⁶

Specific Entities and Presentation

Symptomatic neonates with VOGM most commonly present with high-output heart failure and medically refractory pulmonary hypertension in the setting of massive lesional flow. Severely affected patients demonstrate elevated ventricular output, right heart dilation, and diastolic reversal of flow in the descending aorta.¹⁷ These phenomena can result in inadequate perfusion of host tissues in multiple organ systems including the brain and at best can be only somewhat mitigated with medical management in the majority of cases. In symptomatic neonates, definitive treatment frequently requires diminution of lesional flow via embolization.¹⁸ Additional intracranial neuroimaging findings may include ventriculomegaly, parenchymal volume loss, and findings suggestive of intracranial venous hypertension.¹⁹

Unlike older children (adolescents and teenagers) or adults with VOGM who often present with focal neurologic deficits in the setting of hemorrhagic stroke, neonates typically present with nonspecific neurologic symptoms such as seizures and encephalopathy within hours to days of birth.

LATE INFANCY AND CHILDHOOD

Imaging Considerations

MR imaging is the modality of choice for evaluation of neurologic symptoms in late infancy and childhood, particularly if stroke is suspected, given the lack of ionizing radiation and the ability to more accurately make a definitive diagnosis. Nonetheless, CT/CT angiography (CTA) may be performed in the event of limited MR imaging availability, need for sedation, or presence of MR imaging incompatible devices. In patients who are suspected to have an acute arterial ischemic stroke due to intracranial large vessel occlusion, an abbreviated protocol can be performed with diffusion-weighted imaging (DWI), fluid-attenuated inversion recovery (FLAIR), gradient echo (GRE)/susceptibility weighted imaging (SWI) and 3 dimensional time of flight MR angiography or magnetic resonance angiography (MRA) to make a

diagnosis.²⁰ In patients with a high pretest probability of acute intracranial large vessel occlusion due to embolus (child with congenital heart disease, cardiomyopathy, or extracorporeal circulatory device), CT/CTA is preferred over MR imaging given its high sensitivity, specificity, and rapidity in a situation where treatment selection and neurologic outcomes are highly time sensitive. Neuroimaging considerations in the child with arterial ischemic stroke are covered in detail in the study by Fileva and colleagues' article, "Arterial Ischemic Stroke in Children," in this issue. Acute hemorrhagic presentations may also be better assessed with CT and CTA in the initial phase of care for rapid surgical decision-making, with subsequent catheter-directed angiography to fully characterize and/or treat underlying lesions such as aneurysms or AVMs. Additionally, long-term follow-up neuroimaging is required following treatment of these lesions due to the risk of recurrence. An in-depth consideration of neuroimaging for children with hemorrhagic stroke is presented in the study by Leach and colleagues' article, "Imaging of Hemorrhagic Stroke in Children," in this issue. A detailed presentation of neuroimaging considerations in children with intracranial aneurysms and intracranial AVMs is given in the studies by Kartik D. Bhatia and Carmen Parra-Farinas's article, "Intracranial Arterial Aneurysms in Childhood," in this issue and Karim S and colleagues, respectively.

Pathomechanisms

Beyond the neonatal period, infants with VOGM and DSM most often present with macrocephaly as a result of enlarging cerebral ventricles. Ventriculomegaly and symptomatic hydrocephalus in infants with VOGM and DSM is mostly related to hydrovenous dysfunction, though a component of aqueductal compression may be contributory in VOGM. Hydrovenous dysfunction is primarily due to the elevated venous pressures caused by arteriovenous shunting in the setting of arachnoid granulation immaturity. Hydrovenous dysfunction is most commonly expressed as ventriculomegaly, but vasogenic edema, deep white matter injury, and venous ischemia with sequelae of cystic encephalomalacia and parenchymal calcification may also occur.

Congenital arteriovenous lesions, such as VOGM and DSM with associated arteriovenous shunting, often become associated with venous outlet stenosis in late infancy (with a peak at 2–3 years of age), most commonly involving the lower sigmoid sinuses and jugular bulbs. This phenomenon, which has been called jugular bulb

dysplasia, does not appear to be strictly a function of lesional flow, as some infants with low residual lesional flow develop progressive severe stenosis, while others with high flow never develop venous stenosis. Jugular bulb dysplasia aggravates hydrovenous dysfunction and can be complicated by symptomatic cerebral venous hypertension and cerebral venous congestion if redirection of cerebral venous drainage to the anterior venous confluence of the cavernous sinuses is not enabled by postnatal cavernous capture of the superficial middle cerebral veins. In such cases, increasing pressure within the posterior venous confluence (torcular Herophilli) caused by outlet stenosis produces reversal of flow in the superior sagittal sinus, straight sinus, and falcine sinus with retrograde cortical venous drainage. While this flow pattern can cause extensive brain injury, it may be transiently tolerated if the superior sagittal sinus can drain to the cavernous sinuses through the superior anastomotic vein of Trolard and superficial middle cerebral vein.

Nidal-type AVM and intracranial aneurysms in childhood typically present with hemorrhage, although there is an increasing trend toward incidental diagnosis secondary to increasing availability and improving accuracy of cross-sectional imaging modalities. Notably, hemorrhagic presentation of AVM in children can be associated with the presence of high-risk features that signal a higher probability of short-term rebleeding such as flow-related aneurysm, pseudoaneurysm, or draining vein stenosis on initial imaging. Such high-risk features should be recognized by radiologists as they strongly influence clinical decision-making. Flow-related aneurysms or pseudoaneurysms that are closely associated with hematomas, particularly those bearing daughter sacs or teats, should be considered a likely source of acute bleeding and prioritized for endovascular or microneurosurgical occlusion to prevent early rebleeding.

Pediatric nidal-type pial arteriovenous malformation

Nidal-type pial AVMs of the brain (A.K.A. cerebral AVM) are the most common cause of intracranial hemorrhage in children. Although it had been assumed for decades that many or most cerebral AVMs are congenital, these lesions are virtually never seen on fetal imaging and have been shown to develop postnatally in children aged between 5 and 10 years by sequential brain imaging studies. It is now thought that cerebral AVMs most commonly develop postnatally through early childhood. As noted previously, some nidal-type cerebral AVMs are associated with heritable germ

line loss-of-function mutations, such as in HHT. The pathogenesis of AVMs in HHT involves genes related to the transforming growth factor-beta (TGF-beta) and vascular endothelial growth factor signaling pathways. Nevertheless, the great majority of cerebral AVMs in children and adults are sporadic and are characterized by heterozygous somatic activating (gain-of-function) mutations in *KRAS* and *BRAF* genes.^{21,22}

Intracranial arterial aneurysms Pediatric intracranial arterial aneurysms differ from adult aneurysms in presentation, morphology, and underlying pathogenic mechanisms. Underlying arteriopathy resulting from trauma, infection, maladaptive immuno-inflammatory response, mural dysplasia, collagenopathy, elastinopathy, or other defect of arterial wall composition must be considered in approaches to management of these patients. Dissecting aneurysms are more commonly seen in children. Such aneurysms are often fusiform or circumferential and frequently feature a focal stenosis proximal and/or distal to the aneurysm-bearing arterial segment.^{7,23}

Ischemic and hemorrhagic stroke Risk factors and pathomechanisms of arterial ischemic stroke in children differ from both adult and perinatal stroke. Beyond the perinatal period, children most often develop arterial ischemic stroke as a result of heart disease (congenital cardiac malformations and cardiomyopathy), or arteriopathy that is congenital or acquired. The spectrum of arteriopathy in childhood is diverse and includes arterial dissection (cervical and intracranial), inflammatory, and infectious forms of arteriopathy, a variety of moyamoya arteriopathies and arteriopathies caused by hematologic disease (sickle cell disease and other anemias). The Childhood acute ischemic stroke (AIS) Standardized Classification and Diagnostic Evaluation criteria offer a standardized approach and classification system to the various subtypes of childhood acute ischemic stroke.²⁴⁻²⁷ The role of neuroimaging in the evaluation of childhood arterial ischemic stroke, including the differential diagnosis of the most common etiologies encountered in clinical practice, is covered extensively in the study by Severino M and colleagues. Given the importance of cerebral arteriopathy as a cause of arterial ischemic stroke in childhood, a study by Stence N and colleagues is dedicated to this topic. While arteriopathies in children presenting with arterial ischemic stroke in the anterior cerebral circulation usually have an intracranial distribution, arteriopathy in vertebrobasilar arterial ischemic stroke is extracranial in the vast majority of cases. Although new evidence indicates that focal

cerebral arteriopathy has a posterior circulation variant affecting intracranial arteries, nontraumatic vertebral artery dissections involving the atlantoaxial and atlanto-occipital segments of the extracranial vertebral artery are increasingly recognized as the dominant cause of childhood posterior circulation stroke. Moreover, the mechanistic importance of Bowhunter syndrome in such cases has been widely established. In contrast, with the exception of Takayasu's disease and fibromuscular dysplasia, the vast majority of arteriopathy responsible for anterior circulation arterial ischemic stroke has an intracranial distribution.

Hemorrhagic stroke, excluding conversion of arterial ischemic infarction, constitutes more than 50% of childhood stroke. The most common cause is intracranial vascular malformations, with AVM and cerebral cavernous malformation (CCM) accounting for the vast majority of these. A smaller number of hemorrhagic strokes are related to intracranial arterial aneurysms and vessel wall degeneration attributable to chronic progressive arteriopathy (ie, moyamoya arteriopathies). Additional and important causes of pediatric hemorrhagic stroke include tumor-related hemorrhage and congenital or acquired coagulopathy.²⁸⁻³¹ The central role of neuroimaging in the diagnostic evaluation of childhood hemorrhagic stroke, and the age-oriented neuroimaging differential diagnosis of specific hemorrhagic stroke patterns and pathologies, is elaborated in the study by Leach and colleagues' article, "Imaging of Hemorrhagic Stroke in Children," in this issue.

Specific Entities and Presentation

In the setting of VOGM, or DSM that features arteriovenous shunting, severe venous outlet stenosis at the skullbase (ie, jugular bulb dysplasia) results in pressurization of the entire cerebral venous system that is transmitted through the posterior venous confluence (torcular) to the superior sagittal sinus, petrosal sinuses, straight sinus, and falcine sinus. This results in parenchymal vasogenic edema that is manifested as thalamic, brainstem, or corona radiata T2 signal hyperintensity on MR imaging. This is followed by parenchymal calcification and cerebral atrophy. Clinical presentation is typically with headache, followed by seizures, speech and developmental regression, and extraocular movement and bulbar abnormalities. In the setting of chronic reflux into pial veins with advanced stages of venous hypertension, there is also a risk of subarachnoid and parenchymal hemorrhage.¹⁹ In these cases, cortical venous ectasia and tortuosity (venopathy) are important neuroimaging features that may precede hemorrhagic presentation. While

hemorrhage is a late-stage complication of VOGM resulting from parenchymal venous hypertension, typically in school-age children and teenagers, hemorrhage is not a rare complication of cerebral venous hypertension in younger children with DSM featuring arteriovenous shunting. Recurrent epistaxis is another frequent mode of presentation in older children with untreated VOGM and occlusion of the posterior venous outlets. This is a result of cavernous sinus engorgement that is transmitted into ophthalmic veins and submucosal veins of the nasal cavity and paranasal sinuses. Early recognition of venous outlet stenosis and findings of cerebral venopathy should be sought by radiologists evaluating neuroimaging studies because prompt intervention informed by these findings may preempt irreversible brain injury. While dural venous sinus and jugular bulb stenosis are highly resistant to angioplasty and stenting, treatment should therefore be focused on definitive closure of the arteriovenous shunt lesion. The neuroimaging evaluation of children with VOGM, DSM, and other types of congenital arteriovenous lesions is covered in the study by Qureshi and colleagues' article, "Neurovascular Malformations in the Fetus and Neonate," in this issue.

As in the neonatal population, in younger children, there is often lack of specificity of symptoms from arterial ischemic stroke. While older children may present with focal limb or facial weakness, sensory change, or aphasia similar to adults with stroke, younger children can present with a variety of symptoms including headache, neck pain, seizures, nausea/vomiting dizziness, speech alteration, and Horner's syndrome. In addition, a wide range of stroke-like mimics frequently occur in children, such as seizures, demyelinating disease, migraines; these often focus caregivers away from a diagnosis of stroke and delay diagnosis in cases of true stroke. The critical role of neuroimaging in directing the diagnostic evaluation and treatment of children with acute neurologic deficits is detailed in the studies by Fileva and colleagues' article, "Arterial Ischemic Stroke in Children," in this issue and Shrof M and colleagues.

The presentation of hemorrhagic stroke in children does not differ fundamentally from acute arterial ischemic stroke, other than in the case of large hemorrhage with mass effect, which frequently manifests sudden loss of consciousness and seizures. Although brain AVM occurs in adults and children, the presentation is distinct to some degree. Children far more often present with acute hemorrhage (as opposed to seizures). Notably, while acute hemorrhage is reported in up to 80% of pediatric cases,^{32,33} hemorrhage-free survival is reportedly higher in pediatric

patients.³⁴ Similar to AVMs, pediatric aneurysms have an increased incidence of hemorrhagic presentation as compared to adults.³⁵ More recent studies that have focused on longitudinal outcomes in children with small unruptured aneurysms have reported a relatively low cumulative incidence of hemorrhage, particularly for those aneurysms that are incidentally discovered in children with cerebral arteriopathies. The importance of cerebral aneurysms in children with hemorrhagic stroke is covered in the study by Leach JL, while the role of neuroimaging in the evaluation of children with aneurysmal disease is covered in the study by Kartik D. Bhatia and Carmen Parra-Farinas's article, "Intracranial Arterial Aneurysms in Childhood," in this issue.

SYNDROMIC CONSIDERATIONS

A subpopulation of children presenting with intracranial or spinal arteriovenous lesions (nidai-type AVM and/or AVF) have HHT or CM-AVM syndrome, which are the 2 most common monogenic conditions associated with arteriovenous pathology. Whole exome sequencing in unselected pediatric patients with cerebral AVM has revealed that novel variants in HHT genes may be found in children with isolated non-syndromic cerebral AVMs who do not meet standard diagnostic criteria for HHT. While HHT can present with typical nidai-type cerebral AVM angioarchitecture, pial AVF, micro-AVM, cerebral capillary malformation, and transitional forms may also occur. The study by Karim S and colleagues gives an in-depth overview of the different cerebral vascular malformation phenotypes found in HHT. Notably, micro-AVM and capillary malformation should be considered pathognomic for HHT as they are not typically found in isolation. Non-shunting arterial dysplasia has also been described in HHT. Some or all of the lesions listed earlier may be expressed simultaneously or develop asynchronously in individuals with HHT. The coexistence of multiple intracranial arteriovenous lesions should also be considered pathognomic of HHT. The finding of pulmonary AVMs and/or gastrointestinal AVMs in a child with an intracranial or spinal arteriovenous lesion is strong corroborative evidence of HHT. Four major pathogenic gene variants have been described in HHT affecting the ALK1, SMAD4, growth differentiation factor 2, and endoglin (ENG) genes, with mutations in ALK1 being the most common.³⁶ Leading models of arteriovenous lesions in HHT are based on a 2 hit model involving sequential loss-of-function mutations affecting 2 alleles of these genes. CM-AVM syndrome presents with cutaneous capillary malformations and

AVMs (most commonly in the brain, spine, head, and neck but potentially in other organs as well). CM-AVM syndrome is an autosomal dominant disorder with germ line loss-of-function mutations in *RASA1* (for CM-AVM1) or Ephrin Receptor B4 (for CM-AVM2). A second hit somatic mutation in the unaffected allele is thought to be necessary to reveal the AVM phenotype in affected tissues. As mentioned earlier, VOGM has also been associated with *RASA1* and *EPHB4* mutations. Mutations in the *PTEN* gene are associated with a predisposition to both hamartomas and malignant solid tumors (formerly known as Cowden syndrome), but patients also harbor AVM-like lesions of the soft tissues (frequently in the head and neck) that tend to be resistant to embolization therapy.

FUTURE DIRECTIONS

Progress in the understanding of disease pathophysiology and molecular genetics has unveiled numerous gene families and molecular pathways governing vasculogenesis and the development of vascular anomalies. These pathways are implicated in various pediatric neurovascular disorders. Several genetic variants in the *RNF213* gene encoding for a Dynein-like protein have been described in moyamoya arteriopathy across patients with diverse ethnic backgrounds. Additionally, autosomal dominant multisystem disorders of vascular smooth muscle cell phenotype are associated with genetic variants in the *ACTA2* and *MYH11* genes. These monogenic disorders clinically manifest with intracranial arterial steno-occlusive disease. Consequently, genetic screening is now standard practice for childhood cerebral arteriopathy in many centers, especially in cases with a familial history of childhood stroke or suggestive MR imaging findings (eg, *ACTA2* arteriopathy).^{37,38} As our understanding of the biology underlying monogenic cerebral arteriopathy deepens, the promise of effective medical therapies is increasingly within reach. For example, recent advances in laboratory research have suggested that cerebrovascular abnormalities expressed in individuals with *ACTA2* mutations may be at least partially reversed by augmenting the mitochondrial respiration of vascular smooth muscle cells with nicotinamide riboside supplementation.³⁹ Other monogenic causes of cerebral arteriopathy and childhood stroke include *COL4A1/COL4A2*-related disorders, Menke's disease (*ATP7A* mutation), arterial tortuosity syndrome (*SLC2A10* mutation), and adenosine deaminase 2 deficiency. A comprehensive list of these conditions is provided in the study by Fileva and colleagues' article,

"Arterial Ischemic Stroke in Children," in this issue. Notably, screening for cerebral arteriopathy is advised for children with these conditions as well as those with specific chromosomal abnormalities (trisomy 21), monogenic multisystem disorders (Neurofibromatosis type 1, Alagille syndrome, Loeys-Dietz syndrome, type 4 Ehlers-Danlos syndrome, Marfan's syndrome, and microcephalic osteodysplastic primordial dwarfism type 2), and metameric neurocristopathies (posterior fossa brain malformations, hemangiomas, arterial anomalies, cardiac defects, eye abnormalities).⁴⁰

Disordered assembly of normal vessel wall architecture that is the basis of CCMs has been linked to somatic loss of function mutations in the *CCM1*, *CCM2*, and *CCM3* genes. Mutations in one of those genes are found in the vast majority of familial cases of CCMs. Therefore, screening of first-degree relatives is recommended for patients with multiple CCMs or in those with established familial inheritance patterns.^{37,38} Genetic alterations that interrupt the normal function of diverse cellular signaling pathways have been found to play an important role in the development of cerebral vascular malformations. Loss-of-function mutations affecting genes within the TGF-beta and BMP signaling pathways, most commonly *ALK1* and *ENG*, play a central role in the development of vascular malformations in HHT, while loss-of-function mutations in RAS-MEK-ERK and RAS-AKT-mTORC1 pathways (eg, loss-of-function mutations of the *RASA1* and *EPHB4*) are linked to the development of vascular malformations in CM-AVM syndrome.^{37,38}

SUMMARY

Pediatric neurovascular diseases represent a unique group of entities that differ from their adult homologs in both pathomechanism and clinical presentation. Neuroimaging plays a central role in the evaluation of affected children, and important age-related differences in disease expression must be considered in the interpretation of diagnostic neuroimaging studies obtained for affected patients. This introduction provides a framework for the coming studies that individually delve into specific aspects of neurovascular disease across different segments of the pediatric population from fetal life to young adulthood. With deepening insight into the mechanisms of neurovascular disease in childhood, targeted medical and genetic therapies may soon offer effective and enduring remedies for affected children. Neuroimaging is a powerful tool that has illuminated neurovascular disease processes in the past and promises to advance our understanding even further in the future.

CLINICS CARE POINTS

- Six genes have been identified as associated with the development of vein of Galen Malformations: RASA1, EPHB4, ACVRL1, NOTCH1, ITGB1, and PTPN11.
- Screening of first degree relatives is advised in children with multiple cerebral cavernous malformations (CCMs) or in those with established familial inheritance patterns of CCMs owing to the high incidence of genetic alterations.
- Nidal-type pial AVMs are the most common vascular cause of spontaneous intracranial hemorrhage in children.

DISCLOSURE

The authors declare no conflicts of interest related to the content of this article.

REFERENCES

1. Cater SW, Boyd BK, Ghate SV. Abnormalities of the fetal central nervous system: prenatal US diagnosis with postnatal correlation. *Radiographics* 2020; 40(5):1458–72.
2. Shekdar K, Feygin T. Fetal neuroimaging. *Neuroimaging Clinics* 2011;21(3):677–703.
3. Masselli G, Notte MV, Zacharzewska-Gondek A, et al. Fetal MRI of CNS abnormalities. *Clin Radiol* 2020;75(8):640–e1.
4. Raybaud C. Normal and abnormal embryology and development of the intracranial vascular system. *Neurosurgery Clinics* 2010;21(3):399–426.
5. Klostranec JM, Krings T. Cerebral neurovascular embryology, anatomic variations, and congenital brain arteriovenous lesions. *J Neurointerventional Surg* 2022;14(9):910–9.
6. Padget DH. The development of the cranial arteries in the human embryo. *Contribution to embryology*. Carnegie Institution 1948;32:205–61.
7. Lasjaunias P. A revised concept of the congenital nature of cerebral arteriovenous malformations. *Intervent Neuroradiol* 1997;3(4):275–81.
8. Zhao S, Mekbib KY, van der Ent MA, et al. Mutation of key signaling regulators of cerebrovascular development in vein of Galen malformations. *Nat Commun* 2023;14(1):7452.
9. Yang E, Storey A, Olson HE, et al. Imaging features and prognostic factors in fetal and postnatal torcular dural sinus malformations, part II: synthesis of the literature and patient management. *J Neurointerventional Surg* 2018;10(5):471–5.
10. Goldman-Yassen AE, Shifrin A, Mirsky DM, et al. Torcular dural sinus malformation: fetal and postnatal imaging findings and their associations with clinical outcomes. *Pediatr Neurol* 2022;135:28–37.
11. Jaimes C, Machado-Rivas F, Chen K, et al. Brain injury in Fetuses with vein of Galen malformation and Nongalenic arteriovenous fistulas: static snapshot or a portent of more? *Am J Neuroradiol* 2022; 43(7):1036–41.
12. Arko L, Lambrych M, Montaser A, et al. Fetal and neonatal MRI predictors of aggressive early clinical course in vein of Galen malformation. *Am J Neuroradiol* 2020;41(6):1105–11.
13. Sacco A, Pannu D, Ushakov F, et al. Fetal dural sinus thrombosis: a systematic review. *Prenat Diagn* 2021; 41(2):248–57.
14. Goldman-Yassen AE, Dehkharghani S. Chapter 1: Neuroimaging in perinatal stroke and cerebrovascular disease. In: Dehkharghani S, editor. *Stroke*. Brisbane (AU): Exon Publications; 2021. p. 1–24.
15. Curry CJ, Bhullar S, Holmes J, et al. Risk factors for perinatal arterial stroke: a study of 60 mother-child pairs. *Pediatr Neurol* 2007;37(2):99–107.
16. Nelson KB. Perinatal ischemic stroke. *Stroke* 2007; 38(2):742–5.
17. Patel N, Mills JF, Cheung MMH, et al. Systemic haemodynamics in infants with vein of Galen malformation: assessment and basis for therapy. *J Perinatol* 2007;27(7):460–3.
18. Cory MJ, Durand P, Sillero R, et al. Vein of Galen aneurysmal malformation: rationalizing medical management of neonatal heart failure. *Pediatr Res* 2023;93(1):39–48.
19. Burch EA, Orbach DB. Pediatric central nervous system vascular malformations. *Pediatr Radiol* 2015;45(S3):463–72.
20. Jiang B, Mackay MT, Stence N, et al. Neuroimaging in pediatric stroke. *Semin Pediatr Neurol* 2022;43: 100989.
21. Hongo H, Miyawaki S, Teranishi Y, et al. Genetics of brain arteriovenous malformations and cerebral cavernous malformations. *J Hum Genet* 2023; 68(3):157–67.
22. Nikolaev SI, Vetiska S, Bonilla X, et al. Somatic activating *KRAS* mutations in arteriovenous malformations of the brain. *N Engl J Med* 2018;378(3): 250–61.
23. Gross BA, Smith ER, Scott RM, et al. Intracranial aneurysms in the youngest patients: characteristics and treatment challenges. *Pediatr Neurosurg* 2015; 50(1):18–25.
24. Bernard TJ, Manco-Johnson MJ, Lo W, et al. Towards a consensus-based classification of childhood arterial ischemic stroke. *Stroke* 2012;43(2): 371–7.
25. Wintermark M, Hills NK, deVeber GA, et al. Arteriopathy diagnosis in childhood arterial ischemic stroke:

- results of the vascular effects of infection in pediatric stroke study. *Stroke* 2014;45(12):3597–605.
26. Oesch G, Perez FA, Wainwright MS, et al. Focal cerebral arteriopathy of childhood: clinical and imaging correlates. *Stroke* 2021;52(7):2258–65.
 27. Mertens R, Graupera M, Gerhardt H, et al. The genetic basis of moyamoya disease. *Transl Stroke Res* 2022;13(1):25–45.
 28. Boulouis G, Blauwblomme T, Hak JF, et al. Nontraumatic pediatric intracerebral hemorrhage. *Stroke* 2019;50(12):3654–61.
 29. Nash M, Rafay MF. Craniocervical arterial dissection in children: pathophysiology and management. *Pediatr Neurol* 2019;95:9–18.
 30. Debette S, Leys D. Cervical-artery dissections: predisposing factors, diagnosis, and outcome. *Lancet Neurol* 2009;8(7):668–78.
 31. Wilseck ZM, Lin LY, Chaudhary N, et al. Newer updates in pediatric vascular diseases. *Semin Roentgenol* 2023;58:110–30.
 32. Kondziolka D, Humphreys RP, Hoffman HJ, et al. Arteriovenous malformations of the brain in children: a forty year experience. *Can J Neurol Sci* 1992;19(1):40–5.
 33. El-Ghanem M, Kass-Hout T, Kass-Hout O, et al. Arteriovenous malformations in the pediatric population: review of the existing literature. *Interv Neurol* 2016;5(3–4):218–25.
 34. Fullerton HJ, Achrol AS, Johnston SC, et al. Long-term hemorrhage risk in children versus adults with brain arteriovenous malformations. *Stroke* 2005;36:2099.
 35. Requejo F, Teplisky D, Dutra MLG, et al. Pediatric interventional neuroradiology. *Semin Neurol* 2023;43(03):408–18.
 36. Schimmel K, Ali MK, Tan SY, et al. Arteriovenous malformations—current understanding of the pathogenesis with implications for treatment. *Int J Mol Sci* 2021;22(16):9037.
 37. Kahle KT, Duran D, Smith ER. Increasing precision in the management of pediatric neurosurgical cerebrovascular diseases with molecular genetics. *J Neurosurg Pediatr* 2023;31(3):228–37.
 38. Sporns PB, Fullerton HJ, Lee S, et al. Childhood stroke (primer). *Nat Rev Dis Prim* 2022;8(1):12.
 39. Kaw A, Wu T, Starosolski Z, et al. Augmenting mitochondrial respiration in immature smooth muscle cells with an ACTA2 pathogenic variant mitigates moyamoya-like cerebrovascular disease. *Res Sq* 2023;rs.3:rs-3304679.
 40. Sinha R, Ramji S. Neurovascular disorders in children: an updated practical guide. *Transl Pediatr* 2021;10(4):1100.

- Journal of Medicine* case 5-1995 revisited. *Neurology* 1996; 47:1441-6.
21. Zamora RL, Del Priore LV, Storch GA, Gelb LD, Sharp J. Multiple recurrent branch retinal artery occlusions associated with varicella zoster virus. *Retina* 1996;16:399-404.
 22. Gray F, Belec L, Lescsc MC, et al. Varicella-zoster virus infection of the central nervous system in the acquired immune deficiency syndrome. *Brain* 1994;117:987-99.
 23. Kleinschmidt-deMasters BK, Amlie-Lefond C, Gildea DH. The patterns of varicella-zoster virus encephalitis. *Hum Pathol* 1996;27:927-38.
 24. Frank Y, Lim W, Kahn E, et al. Multiple ischemic infarcts in a child with acquired immunodeficiency syndrome, varicella zoster infection, and cerebral vasculitis. *Pediatr Neurol* 1989; 5:64-7.
 25. Frank Y, Lu D, Pavlakis S, Black K, LaRussa P, Hyman RA. Childhood AIDS, varicella zoster, and cerebral vasculopathy. *J Child Neurol* 1997;12:464-6.
 26. Sebire G, Meyer L, Chabrier S. Varicella as a risk factor for cerebral infarction in childhood: a case-control study. *Ann Neurol* 1999;45:679-80.

Pediatr Infect Dis J, 2000;19:653-6
Copyright © 2000 by Lippincott Williams & Wilkins, Inc.

Vol. 19, No. 7
Printed in U.S.A.

Fatal varicella-zoster virus antigen-positive giant cell arteritis of the central nervous system

THOMAS M. BERGER, MD, JÜRIG H. CADUFF, MD AND JAN-OLAF GEBBERS, MD

Central nervous system (CNS) complications of primary varicella zoster virus (VZV) infection are well-recognized and include cerebellar ataxia, encephalitis, aseptic meningitis, transverse myelitis and Reye's syndrome. More recently a number of reports have described an association between chickenpox and acute stroke in children. Imaging studies in some of these patients have demonstrated evidence of localized CNS vasculopathy; however, the histology of these lesions has not yet been described. We report on the clinical and autopsy findings of a 4-year-old girl who died of progressive stroke secondary to VZV antigen-positive giant cell arteritis of the left middle cerebral artery (MCA).

METHODS

Immunohistochemistry was performed by the streptavidin-alkaline phosphatase technique with the use of commercially available antibodies (Dako, Copenhagen, Denmark, unless otherwise stated) to the fol-

lowing antigens: IgA (polyclonal, dilution 1/2000), IgG (polyclonal, dilution 1/2000), IgM (polyclonal, dilution 1/1000), C3c (polyclonal, dilution 1/1500), CD3 (monoclonal, dilution 1/100), CD20 (monoclonal, dilution 1/80), herpes simplex virus (HSV) types I and II (polyclonal, dilutions 1/200), cytomegalovirus (CMV; monoclonal, dilution 1/100), Epstein-Barr virus (EBV; polyclonal, dilution 1/80; Ylem, Rome, Italy), VZV (monoclonal, dilution 1/50; Novo-Castra, Newcastle, UK). Appropriate positive and negative controls were used in every staining run. The histologic sections of formalin-fixed paraffin-embedded material were deparaffinized and pretreated proteolytically with 0.1% protease (type XIV from *Streptomyces griseus*; Sigma Chemical Co., St. Louis, MO) in Tris-buffered saline (pH 7.4) for 10 min at 37°C to unmask antigenic sites before incubation with the primary antibodies against C3c, HSV I and II, CMV and VZV. For the detection of IgA, IgG, IgM, CD3, CD20, and EBV, a heat-induced epitope retrieval technique was utilized that required pressure cooking the sections in 10 mmol/l citrate buffer (pH 6.0) for 1.5 min, followed by cooling in the buffer for 10 min. The primary antibodies were incubated with the histologic sections at room temperature for 1 h. After addition of the biotinylated secondary antibody and the streptavidin-alkaline phosphatase complex, the immunohistochemical reaction was visualized by using naphthol phosphate and new fuchsin as chromogen. A positive reaction produces a purple precipitate. Staining with the commercially

Accepted for publication March 28, 2000.

From the Department of Pediatrics (TMB), Kinderspital Luzern, the Department of Diagnostic Radiology (JHC) and the Institute of Pathology (JOG), Kantonsspital Luzern, Lucerne, Switzerland.

Key words: Varicella-zoster virus, chickenpox, giant cell arteritis, central nervous system, stroke, childhood.

Address for reprints: Thomas M. Berger, M.D., Neonatal and Pediatric Intensive Care Unit, Kinderspital Luzern, 6000 Lucerne 16, Switzerland. Fax: (041) 205 3190; E-mail thomas.berger@ksl.gsd.lu.ch (office), tmberger@access.ch (home).

available monoclonal anti-VZV antibody (Whitacker) is highly specific.¹

CASE REPORT

A 4-year-old girl was admitted 6 h after the sudden onset of right-sided hemiparesis and complete aphasia. Her parents reported of two similar episodes: Seven months earlier they noted weakness of the right arm and leg, facial asymmetry and complete aphasia lasting several hours; 1 week before admission the girl was unable to walk and speak for ~15 min. Because of the transient nature these episodes were not further investigated.

On admission she was awake and communicated nonverbally because of motor aphasia. Apart from a right-sided facial weakness her cranial nerves were intact. Her pupils were equal and reactive to light. An incomplete right-sided hemiparesis affected the arm more severely than the leg with mildly increased tendon reflexes and a positive Babinski's sign. She was unable to sit without support.

A computed tomography (CT) scan of the head with contrast showed decreased flow in the left internal carotid artery (ICA). Flow in the ipsilateral MCA was absent, and a hypodense lesion in the left frontal lobe consistent with infarction was noted. Several lacunar lesions in the white matter of the left frontal and parietal lobes and volume loss of the left basal ganglia were seen suggesting recurrent infarctions. Magnetic resonance imaging and magnetic resonance angiography were obtained on the same day and confirmed the CT findings (Fig. 1, A to C).

The working diagnosis was a vascular process affecting the left ICA, leading to thrombosis or embolization and infarction. Because more than 4 h had elapsed since the onset of symptoms, active clot lysis was not considered an option. Initial laboratory investigations including markers of autoimmune diseases (lupus anticoagulant, antinuclear antibodies, anticardiolipin antibodies, anti-beta-2-glycoprotein 1 antibodies, anti-neutrophil cytoplasmic antibodies), coagulation profile (activated partial thromboplastin time, prothrombin time, fibrinogen), protein S-free antigen, lipid status and screening for homocysteinuria failed to define the etiology of the disorder. Further evaluation for prothrombotic abnormalities (protein C, antithrombin III, activated protein C resistance, factor V Leiden) was planned for the convalescent period and was not obtained during the initial evaluation. Blood and urine cultures were negative as were serologic tests for HIV, syphilis, toxoplasmosis, CMV and hepatitis B and C.

Low dose aspirin therapy was started. Thirty hours after admission the girl's condition rapidly deteriorated. Her left pupil became dilated and intermittent decerebrate posturing was noted. She was intubated and a repeat CT scan of the head showed extensive infarction of

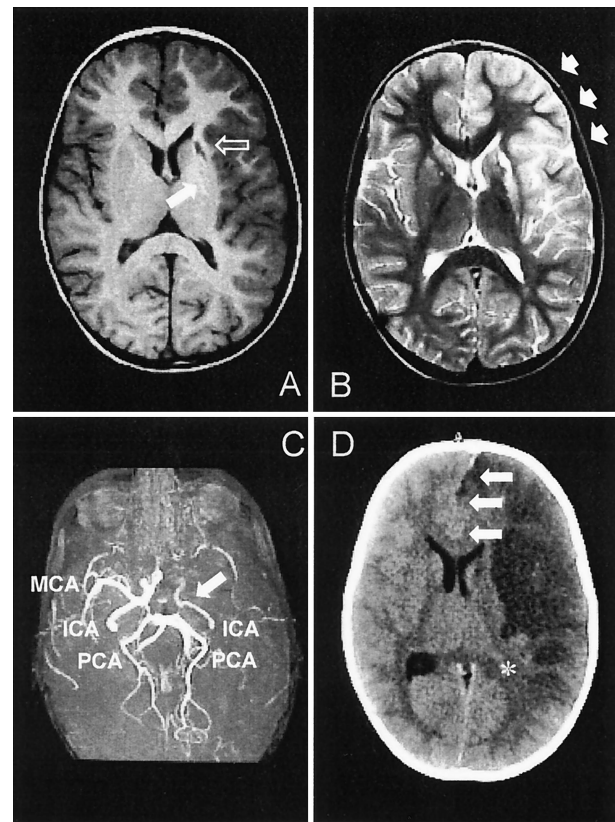


FIG. 1. Imaging studies: A, T1-weighted axial magnetic resonance (MR) scan (first hospital day) demonstrates decreased volume of the lentiform nucleus (*white arrow*) and a lacunar lesion in the white matter adjacent to the head of the caudate nucleus (*open arrow*) consistent with old infarcts; B, T₂-weighted axial MR scan (first hospital day): in addition to the postischemic changes described above, the hyperintense swollen cortex of the left frontal and parietal lobes (*arrows*) consistent with edema is easily recognized; C, MR angiography (first hospital day). There is decreased flow in the left internal carotid artery (ICA) and absent flow in the left MCA (*arrow*) with symmetric posterior cerebral arteries (PCA); D, axial CT scan (third hospital day). There is a large hypodense lesion of the left hemisphere with mass effect, leading to midline shift (*arrows*) and compression of the occipital horn of the left lateral ventricle (*asterisk*).

the left cerebral hemisphere leading to midline shift with transtentorial herniation (Fig. 1D) and compression of the brainstem. She was brain dead within 6 h. The parents consented to multiorgan donation.

At autopsy there was a large subacute infarct of the left cerebral hemisphere. We found an active granulomatous arteritis of the left MCA with characteristic multinuclear giant cells, a lymphocytic infiltrate (predominantly CD3⁺ T lymphocytes) of the vascular wall and segmental destruction of the internal elastic lamina (Fig. 2, *top*). Fresh and organized thrombi occluded the left MCA and extended into the left ICA. Immunohistochemical examinations revealed no vascular immune complex deposits (negative for IgA, IgG, IgM and C3a), but staining of the affected vessel was positive for VZV and negative for

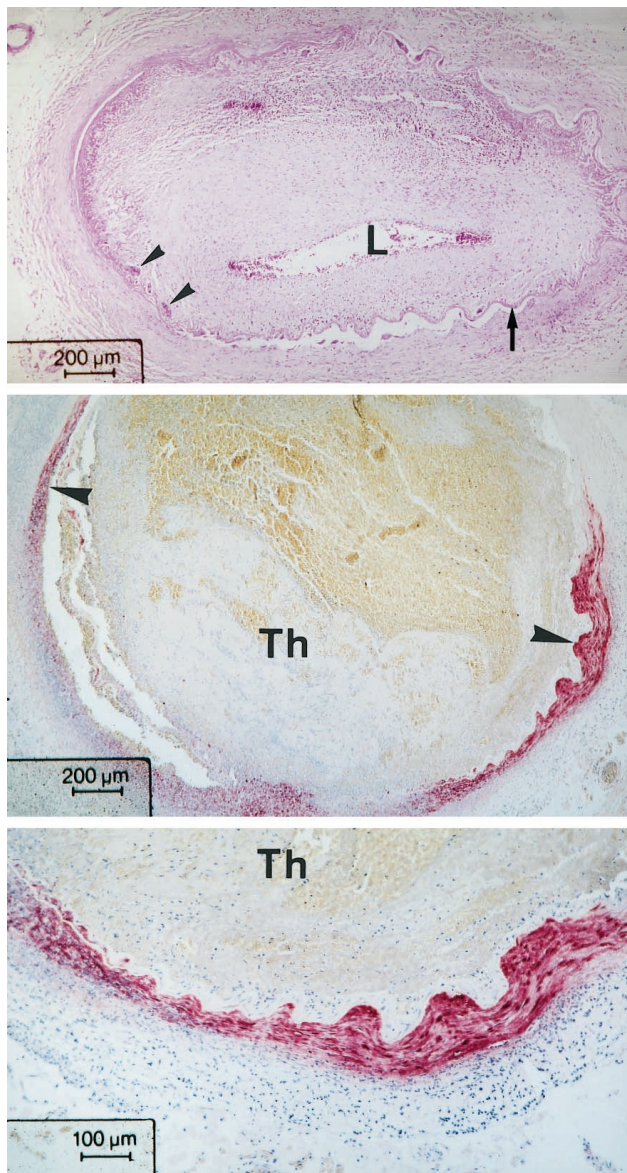


FIG. 2. Histopathology of cerebral giant cell arteritis of the left MCA. *Top*, mononuclear cell infiltrate of the vessel wall with intimal fibrotic thickening and luminal narrowing (L), fragmentation of the internal elastic lamina (arrow) and profuse giant cell reaction (arrowheads); hematoxylin and eosin. *Middle, bottom*, immunohistochemical demonstration of segmental VZV antigen in the smooth muscle cell layer of the vessel wall (purple stain, arrowheads); the lumen is almost completely obliterated by an intraluminal thrombus (Th); streptavidin-alkaline phosphatase technique.

HSV, CMV and EBV (Fig. 2, *middle, bottom*). VZV antigen deposition was in a segmental distribution and limited to the smooth muscle cell layer of the vessel wall. The contralateral MCA was negative for all immunohistochemical markers. The patient had had chickenpox 13 months earlier, and VZV serology performed on a serum specimen from the current hospitalization revealed positive IgG and negative IgM.

DISCUSSION

More than 30 cases of acute ischemic strokes in children after chickenpox have been reported in the literature. Although the outcome was good for most patients, recovery can be incomplete, and recurrent ischemic events do occur. The present report is the first description of the histology of VZV-associated CNS arteritis in children after chickenpox.

In adults herpes zoster ophthalmicus (HZO) with delayed contralateral hemiparesis is a well-known CNS syndrome characterized by unilateral vasculopathy affecting larger cerebral arteries.² The mean interval between the onset of HZO and the neurologic disorder is 2 months (range, a few days to 6 months).³ Pathologic studies in some adult patients have demonstrated a granulomatous angiitis with multinucleated giant cells⁴⁻⁶ and virus-like particles^{4,5} or VZV-specific antigens within histiocytes⁵ and smooth muscle cells of the affected vessel walls,^{6,7} further supporting an important role of VZV in the pathogenesis of this form of CNS arteritis. In HZO with delayed contralateral hemiparesis, VZV-associated CNS arteritis is thought to be caused by direct viral spread along intracranial branches of the trigeminal nerve to the ipsilateral arterial walls.⁸ However, cerebral vasculopathies have been observed in adult patients with segmental herpes zoster infection without trigeminal nerve involvement, suggesting that other mechanisms for viral access to the cerebral vessels exist, such as hematogenous seeding or spreading via sympathetic nervous system pathways.^{3,9}

In our patient the interval between chickenpox and the first transient ischemic attack was 8 months. The third ischemic event occurred 13 months after primary VZV infection and culminated in a rapidly fatal stroke. Findings on magnetic resonance angiography were consistent with localized cerebral vasculopathy (Fig. 1C). Similar to the histology findings in adults with HZO with delayed contralateral hemiparesis,⁴⁻⁷ we demonstrated VZV antigen deposition in the smooth muscle cell layer of the affected cerebral vessel (Fig. 2, *middle, bottom*), associated with an inflammatory infiltrate. This provides convincing evidence that VZV plays a role in the pathogenesis of some forms of acute childhood strokes.

We suggest that VZV-associated CNS vasculitis should be considered in children with transient ischemic attacks or ischemic strokes. Although the prognosis is generally favorable, some patients will have persistent neurologic deficits, and recurrent ischemic attacks can occur and can be fatal.

ADDENDUM

According to the national transplant coordination center (Swiss-transplant), some transplant centers would not have accepted the patient's organs had the diagnosis been known at the time of brain death determination. However, no VZV-associated compli-

cations have been observed in the transplant recipients (follow-up 1 year). In one patient (liver recipient) who had been VZV antibody-negative before transplantation, no seroconversion was noted after transplantation (M Seha, Swisstransplant, personal communication).

REFERENCES

1. Perez JL, Garcia A, Niubo J, Salva J, Podzamczar D, Martin R. Comparison of techniques and evaluation of three commercial monoclonal antibodies for laboratory diagnosis of varicella-zoster virus in mucocutaneous specimens. *J Clin Microbiol* 1994;32:1610-3.
2. Hilt DC, Buchholz D, Krumholz A, Weiss H, Wolinsky JS. Herpes zoster ophthalmicus and delayed contralateral hemiparesis caused by cerebral angiitis: diagnosis and management approaches. *Ann Neurol* 1983;14:543-53.
3. Ichiyama T, Houdou S, Kisa T, Ohno K, Takeshita K. Varicella with delayed hemiplegia. *Pediatr Neurol* 1990;6:279-81.
4. Doyle PW, Gibson G, Dolman CL. Herpes zoster ophthalmicus with contralateral hemiplegia: identification of cause. *Ann Neurol* 1983;14:84-5.
5. Fukumoto S, Kinjo M, Hokamura K, Tanaka K. Subarachnoid hemorrhage and granulomatous angiitis of the basilar artery: demonstration of the varicella-zoster-virus in the basilar artery lesions. *Stroke* 1986;17:1024-8.
6. Linnemann CC Jr., Alvira MM. Pathogenesis of varicella-zoster angiitis in the CNS. *Arch Neurol* 1980;37:239-40.
7. Eidelberg D, Sotrel A, Horoupian DS, Neumann PE, Pumarola-Sune T, Price RW. Thrombotic cerebral vasculopathy associated with herpes zoster. *Ann Neurol* 1986;19:7-14.
8. Caekebeke JF, Peters AC, Vandvik B, Brouwer OF, de Bakker HM. Cerebral vasculopathy associated with primary varicella infection [see comments]. *Arch Neurol* 1990;47:1033-5.
9. Hausler MG, Ramaekers VT, Reul J, Meilicke R, Heimann G. Early and late onset manifestations of cerebral vasculitis related to varicella zoster. *Neuropediatrics* 1998;29:202-7.

Towards a Consensus-Based Classification of Childhood Arterial Ischemic Stroke

Timothy J. Bernard, MD; Marilyn J. Manco-Johnson, MD; Warren Lo, MD; Mark T. MacKay, MD; Vijeya Ganesan, MBChB, MD; Gabrielle deVeber, MD; Neil A. Goldenberg, MD, PhD; Jennifer Armstrong-Wells, MD, MPH; Michael M. Dowling, MD, PhD, MSCS; E. Steve Roach, MD, FAHA; Mark Tripputi, PhD; Heather J. Fullerton, MD, MAS; Karen L. Furie, MD, MPH; Susanne M. Benseler, MD; Lori C. Jordan, MD, PhD; Adam Kirton, MD; Rebecca Ichord, MD

Background and Purpose—The implementation of uniform nomenclature and classification in adult arterial ischemic stroke (AIS) has been critical for defining outcomes and recurrence risks according to etiology and in developing risk-stratified treatments. In contrast, current classification and nomenclature in childhood AIS are often overlapping or contradictory. Our purpose was to develop a comprehensive consensus-based classification system for childhood AIS.

Methods—Using a modified-Delphi method, members of the International Pediatric Stroke Study (IPSS) developed the Childhood AIS Standardized Classification And Diagnostic Evaluation (CASCADE) criteria. Two groups of pediatric stroke specialists from the IPSS classified 7 test cases using 2 methods each: (1) classification typical of the individual clinician's current clinical practice; and (2) classification based on the CASCADE criteria. Group 1 underwent in-person training in the utilization of the CASCADE criteria. Group 2 classified the same cases via an online survey, including definitions but without training. Inter-rater reliability (IRR) was assessed via multi-rater unweighted κ -statistic.

Results—In Group 1 (with training), IRR was improved using CASCADE criteria ($\kappa=0.78$, 95% CI=[0.49, 0.94]), compared with typical clinical practice ($\kappa=0.40$, 95% CI=[0.11, 0.60]). In Group 2 (without training), IRR was lower than among trained raters ($\kappa=0.61$, 95% CI=[0.29, 0.77]), but higher than current practice ($\kappa=0.23$, 95% CI=[0.03, 0.36]).

Conclusions—A new, consensus-based classification system for childhood AIS, the CASCADE criteria, can be used to classify cases with good IRR. These preliminary findings suggest that the CASCADE criteria may be particularly useful in the setting of prospective multicenter studies in childhood-onset AIS, where standardized training of investigators is feasible. (*Stroke*. 2012;43:371-377.)

Key Words: pediatric ■ classification

The adoption of uniform nomenclature and a validated classification system in arterial ischemic stroke (AIS) in adults has been critical to the study of neurological outcomes, risk-stratified therapies and recurrence risk.^{1,2} Multiple classification systems exist for adult AIS that have been validated and used for the purposes of multicenter collaborative efforts.

As an example, the Trial of ORG 10172 in Acute Stroke Treatment (TOAST) classification system has been utilized in more than 180 peer-reviewed publications in adult stroke, facilitating the study of differences in adult stroke subtypes with respect to etiology, risk factors (including genetic polymorphisms), treatment, and outcomes.³⁻⁵ Use of the

Received April 27, 2011; accepted October 3, 2011.

Ralph L. Sacco, MD, was the Guest Editor for this paper.

From the Sections of Child Neurology (T.J.B., J.A.-W.), Hematology/Oncology/BMT (M.J.M.-J., N.A.G.), and the Hemophilia and Thrombosis Center, Department of Pediatrics (T.J.B., M.J.M.-J., N.A.G., J.A.-W.), and the Department of Biostatistics and Informatics (M.T.), School of Public Health, University of Colorado, Aurora, CO; Department of Pediatrics and Section of Child Neurology, Ohio State University, Columbus, OH (W.L., E.S.R.); Children's Neuroscience Centre (M.T.M.), The Royal Children's Hospital, Murdoch Children's Research Institute, Melbourne, Australia; Neurosciences Unit (V.G.), Institute of Child Health (University College London), London, United Kingdom; Division of Neurology (G.d.V.), and Division of Rheumatology (S.M.B.), Hospital for Sick Children, University of Toronto, Ontario, Canada; Division of Pediatric Neurology (M.M.D.), Department of Pediatrics and Neurology, University of Texas Southwestern Medical Center Dallas, TX; Division of Neurology (H.F.), University of California, San Francisco, CA; Department of Neurology (K.L.F.), Massachusetts General Hospital, Boston, MA; Department of Neurology (L.C.J.), Division of Pediatric Neurology, Johns Hopkins University School of Medicine, Baltimore, MD; Calgary Pediatric Stroke Program (A.K.), Division of Neurology, Alberta Children's Hospital, University of Calgary, AB, Canada; and Department Neurology (R.I.), Children's Hospital of Philadelphia, University of Pennsylvania School of Medicine, Philadelphia, PA.

The online-only Data Supplement is available at <http://stroke.ahajournals.org/lookup/suppl/doi:10.1161/STROKEAHA.111.624585/-/DC1>.

Correspondence to Timothy J. Bernard, MD, Pediatric Neurology, B155, Children's Hospital Colorado, 13123 East 16th Avenue, Aurora, CO 80045. E-mail timothy.bernard@ucdenver.edu

© 2011 American Heart Association, Inc.

Stroke is available at <http://stroke.ahajournals.org>

DOI: 10.1161/STROKEAHA.111.624585

TOAST criteria has, in turn, led to the development and successful conduct of clinical trials evaluating risk-stratified approaches to treatment in adult AIS.

Over the past decade, collaborative groups have made considerable progress in understanding the epidemiology, etiology, pathophysiology, outcomes, and prognostic factors in childhood AIS.^{6–9} Nevertheless, current research efforts are hampered by the lack of standardized nomenclature and classification in the childhood form of this disease.^{10–12} Initial attempts at classification in childhood AIS using adult criteria found that the majority of children with AIS do not meet criteria for atherothrombotic, cardioembolic or small-vessel disease, as seen in adults.^{13,14} Subsequent efforts toward childhood-specific nomenclature and classification in AIS have been proposed (the Pediatric Stroke Classification and the Sebire Criteria), but no one system has been widely adopted.^{15,16}

The Pediatric Stroke Classification was created by adding subtypes that were identified in the literature to selected subtypes from the TOAST criteria.¹⁵ Although the system has good IRR, with ICC=0.92, it has not been widely adopted in the childhood stroke literature, possibly due to the lack of consensus development, overlap with the Sebire criteria nomenclature, and inability to classify changes in arteriopathy over time. Although the Sebire criteria are consensus-based, the authors did not attempt to categorize strokes of nonvascular etiology, making it an incomplete system for classification.¹⁶ In addition, these 2 systems also have overlapping and, sometimes, contradictory nomenclature, especially in regard to arteriopathies, which are common in childhood AIS. The pediatric rheumatology literature provides additional definitions for inflammatory arteriopathies by adapting the adult Calabrese criteria for primary angitis of the nervous system, which have even further potential overlap with the Sebire and Pediatric Stroke Classification definitions for arteriopathy.^{17,18}

In order to devise a consensus-based classification system and uniform nomenclature for childhood AIS, the International Pediatric Stroke Study (IPSS) established a working group in childhood AIS classification in November 2007. The objectives of this report are to describe the methodology used to develop the Childhood AIS Standardized Classification and Diagnostic Evaluation (CASCADE) criteria, and to provide evidence of inter-rater reliability using this new, comprehensive classification system in childhood AIS.

Methods

The IPSS is an international research network that created a registry of patients with pediatric cerebrovascular disease, established in 2003 with the long-term goal of developing multinational clinical trials in pediatric ischemic stroke.^{7,19} Investigators of the IPSS created a working group to construct a consensus-based classification system for childhood AIS. The working group consisted of 14 volunteers from the IPSS: 10 pediatric neurologists, 1 adult neurologist, 2 pediatric hematologists, and 1 pediatric rheumatologist. The initial version of the CASCADE criteria represented a compilation of criteria from 3 published systems: (1) the Pediatric Stroke Classification,¹⁵ (2) the Sebire definitions for cerebral arteriopathy,¹⁶ and (3) Calabrese criteria for childhood primary central nervous system vasculitis.^{17,20,21} In subsequent versions, the working group established a unifying theme for the new classification system: an

anatomically based system. In order to minimize subjectivity, the primary classification is largely based on objective anatomic evidence of any identifiable disease contributing to stroke causation, including disorders of the heart and cervical and intracranial vasculature.

The CASCADE criteria was revised using a modified-Delphi method (Figure 1).^{22,23} Each revision incorporated critiques solicited from members of the working group regarding the clinical relevance and conceptual validity of the overall system as well as each subtype. The cochairs (T.B. and R.I.) evaluated all responses and incorporated the critiques and suggestions into the next revision. Reviewers were asked to specify their assessments as: (1) agreement, (2) agreement with minor modifications, or (3) disagreement. In addition, there was a section provided for additional comments and suggested revisions. The proposal for the CASCADE criteria underwent 4 revisions. When disagreements arose, the working group was polled regarding possible solutions, and the majority opinion was accepted.

Based on this consensus-driven process, the 4th revision was presented to the IPSS members attending the IPSS investigators' meeting in February 2009. After a 20-minute training session, 7 childhood stroke vignettes were presented to the membership by the working group chairs, and the IPSS members in attendance were asked to classify the cases using 2 methods: (1) the approach typical of the clinician's current practice, via entry of free text (individual classification), and (2) the CASCADE criteria. Group 1 was comprised of the 6 members who volunteered to classify all 7 cases. Each vignette was based on real cases selected from stroke registries at the Children's Hospital of Philadelphia or Children's Hospital Colorado and contained a synopsis of clinical history, selected neurovascular imaging, echocardiogram results, and thrombophilia testing. T.B. and R.I. selected real-life cases from the Children's Hospital of Philadelphia or Children's Hospital Colorado to represent a broad range of stroke etiologies, including cardioembolic intracranial arteriopathy (2 cases), dissection, postinfectious, multiple causes (moyamoya disease and cardiac catheterization procedure) and idiopathic. Group 2 was comprised of members of IPSS who did not participate in Group 1 and responded to a call for volunteers. They reviewed the same cases via an e-mail survey. Group 2 raters classified the cases in the same manner as Group 1, via individual classification and the CASCADE criteria but were not given a training session.

Description of the CASCADE Classification System

The primary CASCADE criteria^{15–17,24–26} are presented in Figure 2 and the Table. The IPSS defines childhood AIS as follows: (1) neurological deficit of acute onset; (2) radiographic image(s) (magnetic resonance imaging or computed tomography), showing cerebral parenchymal infarct(s) conforming to known arterial territory(ies) and corresponding to clinical manifestations; and (3) occurring in children 29 days to 18 years of age. The CASCADE criteria are not designed to classify perinatal stroke, defined as stroke occurring before 29 days of life, which has unique risk factors.²⁷

The primary CASCADE criteria is based on anatomic site of disease (Table), which provides the capacity to classify any patient with childhood AIS into a single acute primary category at the time of initial diagnosis (within 1 month of presentation). Standardized definitions for vascular lesions are provided in online-only Supplemental Table 1a (<http://stroke.ahajournals.org>).

The classification at presentation is based on the location and nature of any identifiable anatomic abnormality involving the heart, great vessels in the neck, or the intracranial vessels that could explain AIS in an individual patient (Figure 2). It is based on the investigator's assessment of the anatomic site of disease after interpreting the results of the following clinical data: echocardiogram, vascular imaging (magnetic resonance angiography, computed tomography angiography, and/or conventional angiogram), and pattern of anatomic distribution of infarct as demonstrated by magnetic resonance imaging or computed tomography and clinical history.

There are wide variations in vascular imaging capabilities, algorithms, and interpretation across medical centers—and these can change over time. We designed this system to be applicable

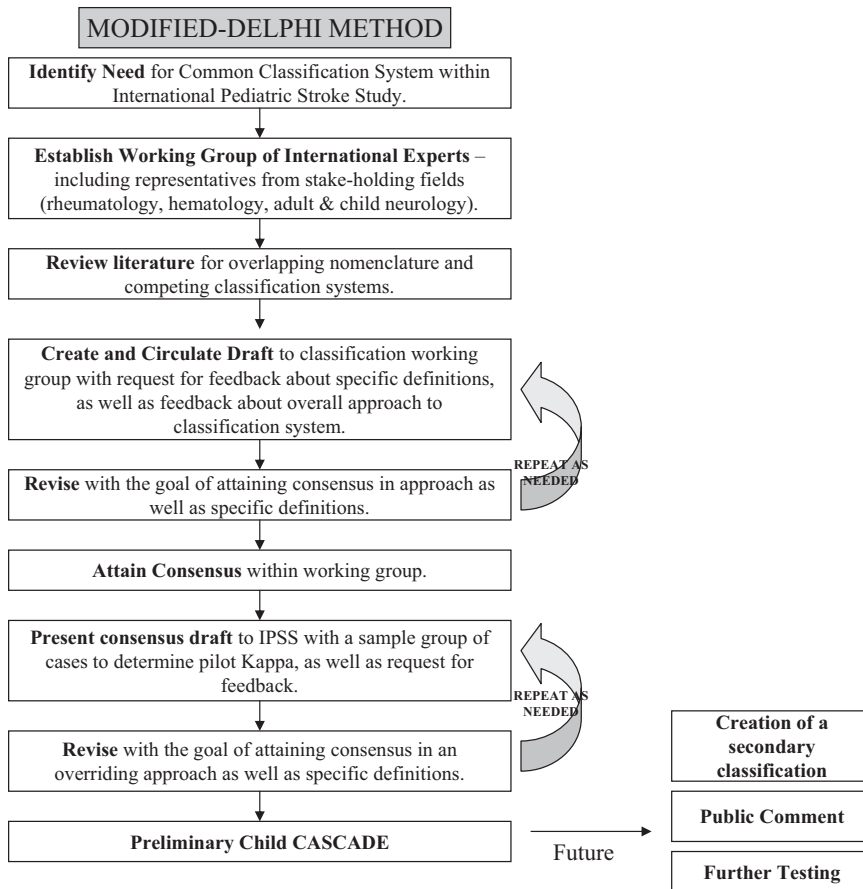


Figure 1. Method for creating a consensus-based childhood arterial ischemic stroke classification system. IPSS indicates International Pediatric Stroke Study.

regardless of the specific imaging modality or techniques used in the evaluation of an individual patient. For the purposes of this classification system, computed tomography angiography and magnetic resonance angiography are considered an adequate evaluation, while conventional angiogram, when performed, is considered the gold standard.

In cases with multiple anatomic locations of disease potentially contributing to stroke mechanism (eg, dissection in a patient with congenital heart disease), the stroke is classified as multifactorial (and the multiple categories will be recorded). Finally, strokes in patients with normal cardiac and vascular imaging (that might be viewed as “unknown”) or strokes with an atypical anatomic etiology (ie, AIS during an endovascular procedure) are classified as “other.”

Statistical Methods

The inter-rater reliability was measured among raters for each of the major 7 classification categories represented by the cases. Agreement for individualized classification was defined as those cases that utilized the same or similar nomenclature within their response and was inclusive of multiple spellings and/or tenses. If agreement was uncertain, T.B. and M.T. reviewed the responses, with agreement being awarded as a default in uncertain situations. We generated a κ -statistic for each of these categories, utilizing the Fleiss unweighted κ -statistic for multiple raters.²⁸ In addition, 95% confidence intervals were determined using the Wald method. Employing the parameters proposed by Landis and Koch,²⁹ we considered a value above 0.8 to represent near perfect agreement; a value between 0.61 to 0.80, substantial agreement; a value 0.41 to 0.60, moderate agreement; a value 0.21 to 0.40, fair agreement; and a value <0.20, slight agreement.

Results

In Group 1 (with training), 6 raters provided complete data on all test cases (ie, raters who classified all 7 subjects for both

the CASCADE criteria and individual system). Using these data from the 6 raters, we calculated an unweighted κ -statistic as a measure of inter-rater reliability. In the 7 test cases presented to Group 1, interobserver agreement (average among subjects of the percentage of raters that give the majority score for each subject) and κ -statistics are better when using CASCADE criteria (90%, range=4/6 to 6/6 and $\kappa=0.78$, 95% CI=[0.49, 0.94]), as compared with using individual classification (64%, range=1/6 to 6/6 and $\kappa=0.40$, 95% CI=[0.11, 0.60]). The pairwise rater kappas for the CASCADE criteria (ie, each rater versus all others) ranged from 0.61 to 1.0, indicating moderate to excellent agreement across all raters.

In Group 2, 17 untrained raters evaluated the 7 test cases. Interobserver agreement and κ -statistics are better when using CASCADE criteria (82%, range=10/17 to 17/17 and $\kappa=0.61$, 95% CI=[0.29, 0.77]), as compared with using individual classification (52%, range=6/17 to 15/17 and $\kappa=0.23$, 95% CI=[0.03, 0.36]). The pairwise kappas for the CASCADE criteria ranged from 0.04 to 0.86.

Discussion

The CASCADE criteria offer a novel and unique approach to classification of stroke subtype in childhood AIS compared with previous efforts. The criteria are derived from a consensus-based process involving pediatric AIS experts and are comprehensive with respect to childhood-onset AIS etiologies and, therefore, seem more likely to be widely

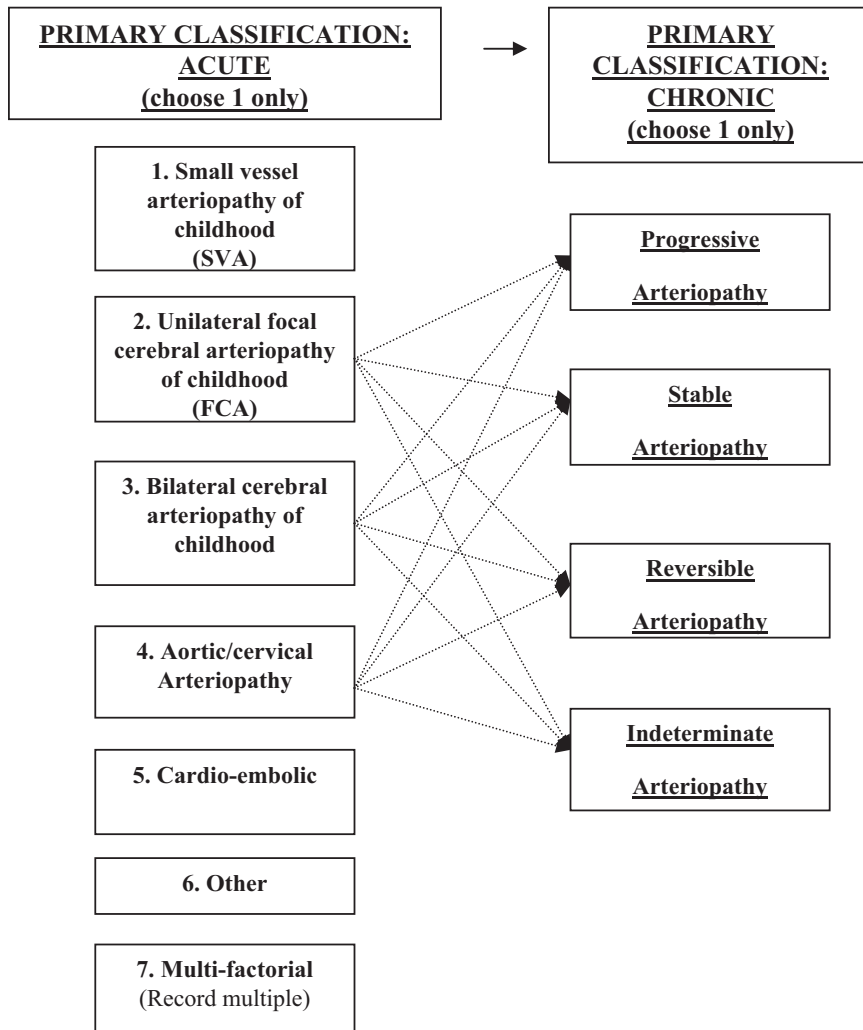


Figure 2. CASCADE Criteria (Childhood AIS Standardized Classification and Diagnostic Evaluation).

adopted than previously proposed schemes. In addition, the CASCADE criteria unifies previously published classification systems with the aim of eliminating terms with overlapping and/or nonspecific definitions, such as focal cerebral arteriopathy, primary angiitis of the central nervous system of childhood, transient cerebral arteriopathy, and stenocclusive arteriopathy.^{6,15–17} As arteriopathy is associated with increased recurrence risk and adverse outcomes,^{8,30} standardizing the nomenclature employed in describing vascular disorders will be essential to developing risk-stratified therapies in childhood AIS.

While the initial κ -statistic of the CASCADE criteria is encouraging ($\kappa=0.61$ to 0.78), it is based on a limited number of raters in an unpowered analysis of few cases. Future efforts to establish inter-rater reliability and validity are warranted, using larger cohorts, prospectively collected cases and consistently trained raters. The decreased κ found in Group 2 highlights the need for training to maximize the reliability of the CASCADE criteria. In addition, the discrepancy between groups may have resulted from Group 1 sharing their answers with each other (although they were asked not to do so) or a discrepancy between the imaging qualities presented to Group 1 and Group 2. The importance of imaging quality and the need for training (possibly Web-based) before classifica-

tion should be addressed by future studies of reliability. Finally, construct validity needs testing, possibly by determining the predictive utility of the CASCADE criteria on recurrence risk and clinical outcomes.

A limitation of the system is its reliance on consensus expert opinion when there is a lack of evidence-based data. In addition, the primary classification is anatomically based but has subcategories that are not purely anatomic. This compromise was reached within the modified Delphi method in order to include established and accepted clinical definitions (such as dissection or Takayasu arteritis) within the 7 major anatomic categories. Similar to the initial TOAST classification, the CASCADE criteria provide a starting point for consensus-based classification in childhood AIS and has the potential for ongoing modification as new information about childhood-onset AIS is uncovered.

Additionally, there are many important risk factors that are not related to structural disease of the heart or blood vessels, such as inflammation, thrombophilias, genetic syndromes, hemoglobinopathies, and infections. Future modifications of the CASCADE criteria will need to further unify and elaborate classification of these factors in a secondary classification system, using the same modified-Delphi methods, as well as further test our ability to revise classification beyond

Table. CASCADE Criteria Acute Primary Classification: Anatomic Features

| Primary Classification— Select One Only | Definition |
|--|--|
| 1. Small-vessel arteriopathy of childhood | <p>a. Definitive—Confirmation of the definitive diagnosis of small-vessel arteriopathy of childhood requires multifocal arterial narrowing of small-caliber vessels on conventional angiogram and evidence of small-vessel arteriopathy on biopsy, including evidence of intramural/vasocentric inflammation of the small muscular arteries, capillaries, and/or venules on brain biopsy. Supportive evidence can be obtained from electron microscopy demonstrating endothelial cell activations and/or tubular reticular inclusions. Perivascular demyelination and/or gliosis can be found; however, specific histological features of other inflammatory brain diseases of childhood must be absent (ie, diffuse parenchymal demyelination).</p> <p>b. Radiographic—Confirmation of the radiographic-proven diagnosis of small-vessel arteriopathy of childhood requires multifocal arterial narrowing of small-caliber vessels on conventional angiogram.</p> <p>c. Biopsy—Confirmation of the biopsy-proven diagnosis of small-vessel arteriopathy of childhood requires evidence of small-vessel arteriopathy on biopsy, including evidence of intramural/vasocentric inflammation of the small muscular arteries, capillaries, and/or venules on brain biopsy. Supportive evidence can be obtained from electron microscopy demonstrating endothelial cell activations and/or tubular reticular inclusions. Perivascular demyelination and/or gliosis can be found; however, specific histological features of other inflammatory brain diseases of childhood have to be absent (ie, diffuse parenchymal demyelination).</p> <p>d. Probable—Suspected small vessel arteriopathy is based upon a small vessel distribution of infarct (without another identified etiology), noninvasive imaging, and/or a known disease process associated with small-vessel arteriopathy (ie, meningitis or lupus).</p> |
| 2. Unilateral focal-cerebral arteriopathy of childhood (FCA) | <p>a. Anterior Circulation with collaterals (would include some types of possible moyamoya disease and some patients with progressive primary angitis of the central nervous system of childhood).—Confirmation of the diagnosis requires magnetic resonance angiography (MRA), computed tomography angiography (CTA), or computed angiography (CA) displaying both (1) unilateral stenosis or vessel irregularity of a large intracranial artery (internal carotid artery, middle cerebral artery, anterior cerebral artery) supplying the territory of infarct, and (2) evidence of an excessive collateral network of vessels distal to the occluded artery.</p> <p>b. Anterior Circulation without collaterals (would include conditions such as transient-cerebral arteriopathy, post-varicella arteriopathy, and large-vessel childhood primary angitis of the central nervous system).^{16,17,24}—Confirmation of the diagnosis requires MRA, CTA, or CA displaying both (1) unilateral stenosis or vessel irregularity of a large intracranial artery (internal carotid artery, middle cerebral artery, anterior cerebral artery) supplying the territory of infarct, and (2) no evidence of excessive collateral network of vessels distal to the occluded artery.</p> <p>c. Posterior Circulation (would include conditions such as basilar artery stenosis)—Confirmation of the diagnosis of focal-cerebral arteriopathy within the cerebral posterior circulation requires MRA, CTA or CA displaying unilateral stenosis or vessel irregularity of a large intracranial artery (posterior cerebral artery, basilar or vertebral) supplying the territory of infarct and not meeting definition of dissection.</p> <p>d. Other—such as congenital anomaly.</p> |
| 3. Bilateral cerebral arteriopathy of childhood | <p>a. With collaterals (would include conditions such as moyamoya disease or fibromuscular dysplasia)—Confirmation of the diagnosis requires MRA, CTA, or CA showing (1) bilateral stenosis or vessel irregularity of a large intracranial artery (internal carotid artery, middle cerebral artery, anterior cerebral artery, posterior cerebral artery) supplying the territory of infarct, and (2) evidence of excessive collateral network of vessels distal to the occluded arteries.</p> <p>b. Without collaterals (would include some types of possible moyamoya disease)—Confirmation of the diagnosis requires MRA, CTA, or CA showing (1) bilateral stenosis or vessel irregularity of a large intracranial artery (internal carotid artery, middle cerebral artery, anterior cerebral artery, posterior cerebral artery) supplying the territory of infarct, and (2) no evidence of excessive collateral network of vessels distal to the occluded arteries.</p> <p>c. Other—such as congenital anomaly.</p> |
| 4. Aortic/Cervical Arteriopathy | <p>a. Dissection—Confirmation of the diagnosis of intracranial- or cervical-arterial dissection requires CTA, magnetic resonance imaging/MRA, or CA with 1 of the following 3 patterns:</p> <ol style="list-style-type: none"> (1) angiographic findings of a double-lumen, intimal flap, or pseudo aneurysm, or, on axial T1 fat saturation magnetic resonance imaging images, a “bright crescent sign” in the arterial wall; (2) the sequence of cervical or cranial trauma, or neck pain, or head pain less than 6 weeks preceding angiographic findings of segmental arterial stenosis (or occlusion) located in the cervical arteries; (3) angiographic segmental stenosis (or occlusion) of the vertebral artery at the level of the C2 vertebral body, even without known traumatic history. <p>(Adapted from Sebire and colleagues, 2004)¹⁶</p> <p>b. Takayasu arteritis—Confirmation of the diagnosis of Takayasu arteritis requires angiographic abnormalities (CA, CTA, or MRA) of the aorta or its major branches (mandatory criterion) plus at least 1 of the following 4 features:</p> <ul style="list-style-type: none"> – Decreased peripheral artery pulse(s) and /or claudication of the extremities – Blood pressure difference ≥ 10mm Hg – Bruits over aorta or its major branches – Hypertension (related to childhood normative data)²⁵ <p>c. Other—such as congenital anomaly or cervical Fibromuscular Dysplasia</p> |

(Continued)

Table. Continued

| Primary Classification— Select One Only | Definition |
|--|---|
| 5. Cardio- embolic | <p>a. Definite—High-risk for cardiac source of cerebral embolism (such as congenital heart disease with abnormal cardiac function, arrhythmia, or endocarditis) or cardiac procedure within 30 days of stroke and territory of large/medium-sized cerebral artery or >1 arterial territory, may be large and/or hemorrhagic.</p> <p>b. Probable—>1 arterial territory, may be large and/or hemorrhagic in a child without another identifiable etiology and 1 of the following:</p> <ol style="list-style-type: none"> 1) patent foramen ovale with right-to left shunt or other subtle cardiac anomaly; 2) Occlusion: a discrete and abrupt blockage of an artery consistent with a clot, without any surrounding irregularity or stenosis suggestive of arteriopathy. <p>(Modified from Wraige et al, 2005; and Ay et al, 2007)^{15,26}</p> |
| 6. Other | <p>a. Undetermined etiology—etiology unclear despite complete workup (including echocardiogram, MRI, and vascular imaging of head and neck)</p> <p>b. Other (ie, other location of identifiable disease that cannot be classified)</p> |
| 7. Multi-factorial | <p>>1 anatomic site of disease (ie, patients who have >1 site of the primary classifications and in whom we are unable to determine the predominant site of disease.</p> <p>(Modified from Sebire et al, 2004; & Wraige et al, 2005)^{15,16}</p> |

the acute period of childhood AIS. This secondary classification is under development (online-only Supplemental Table 1b) and will be further defined and validated in future studies. In addition, a temporal dimension to the criteria (online-only Supplemental Table 1c) is also under development and will classify the natural history of the patient's vascular disease as stable, reversible, or progressive, based on follow-up imaging.

Despite these limitations, this represents the first consensus-based classification system developed by a large consortium of childhood stroke investigators that is inclusive of all childhood AIS. These findings suggest that the CASCADE criteria may be particularly useful in the setting of prospective multicenter studies in childhood-onset AIS, where standardized training of investigators is feasible.

Acknowledgments

We would like to acknowledge all of the IPSS members who participated as raters in the cases: Ruth Nass, Veronica Gonzalez Alvarez, Steven Pavlakis, Paola Pergami, Neil Friedman, Mubeen Rafay, Marta Isabel Hernandez Chavez, Mahendra Moharir, Lisa Abraham, Ilona Kopyta, Clarisa Maxit, Virginia Wong, Lisa M. Nassif, Vesna Brankovic-Sreckovic, and Anneli Kolk.

Sources of Funding

T.J.B. was supported by a grant from the National Institutes of Health, National Heart, Lung, and Blood Institute (1K23HL096895-01A1). M.J.M.-J. was supported by the Centers for Disease Control and Prevention (UR6/CCU820552). N.A.G. was supported by the National Institutes of Health, National Heart Lung and Blood Institute (1K23HL084055-01A1); M.M.D. was supported by the National Institutes of Health, North and Central Texas Clinical and Translational Science Initiative (KL2RR024983) and First American Real Estate Information Services, Inc. R.I. was supported by the National Institutes of Health, National Institute of Neurological Disease and Stroke (R01NS050488).

Disclosures

None.

References

1. Kang DW, Chalela JA, Ezzeddine MA, Warach S. Association of ischemic lesion patterns on early diffusion-weighted imaging with TOAST stroke subtypes. *Arch Neurol*. 2003;60:1730–1734.
2. Kolominsky-Rabas PL, Weber M, Gefeller O, Neundoerfer B, Heuschmann PU. Epidemiology of ischemic stroke subtypes according to TOAST criteria: incidence, recurrence, and long-term survival in ischemic stroke subtypes: a population-based study. *Stroke*. 2001;32:2735–2740.
3. Markus HS, Khan U, Birns J, Evans A, Kalra L, Rudd AG, et al. Differences in stroke subtypes between black and white patients with stroke: the South London Ethnicity and Stroke Study. *Circulation*. 2007;116:2157–2164.
4. Leoo T, Lindgren A, Petersson J, von Arbin M. Risk factors and treatment at recurrent stroke onset: results from the Recurrent Stroke Quality and Epidemiology (RESQUE) Study. *Cerebrovasc Dis*. 2008;25:254–260.
5. Diener HC, Sacco R, Yusuf S. Rationale, design and baseline data of a randomized, double-blind, controlled trial comparing two antithrombotic regimens (a fixed-dose combination of extended-release dipyridamol plus ASA with clopidogrel) and telmisartan versus placebo in patients with strokes: the Prevention Regimen for Effectively Avoiding Second Strokes Trial (PROFESS). *Cerebrovasc Dis*. 2007;23:368–380.
6. Amlie-Lefond C, Bernard TJ, Sebire G, Friedman NR, Heyer GL, Lerner NB, et al. Predictors of cerebral arteriopathy in children with arterial ischemic stroke: results of the International Pediatric Stroke Study. *Circulation*. 2009;119:1417–1423.
7. Golomb MR, Fullerton HJ, Nowak-Gottl U, DeVeber G. Male predominance in childhood ischemic stroke: findings from the international pediatric stroke study. *Stroke*. 2009;40:52–57.
8. Goldenberg NA, Bernard TJ, Fullerton HJ, Gordon A, DeVeber G. Antithrombotic treatments, outcomes, and prognostic factors in acute childhood-onset arterial ischaemic stroke: a multicentre, observational, cohort study. *Lancet Neurol*. 2009;8:1120–1127.
9. Mackay MT, Wiznitzer M, Benedict SL, Lee KJ, deVeber GA, Ganesan V. Arterial ischemic stroke risk factors: the International Pediatric Stroke Study. *Ann Neurol*. 2011;69:130–140.
10. Dowling, MM. Pediatric Stroke Treatment Comes of Age. American Heart Association Web site. <http://pt.wkhealth.com/pt/re/aha/addcontent.9467673.htm?jsessionid=KgHGB169hGKT3yWrMgKTK5KwTz6Jln3mnhqktGTLhqZ469ns1LJ1-701738752!181195629!8091!-1>. Published 2008. Accessed October 7, 2011.
11. Biller J. Stroke: Improving characterization of childhood cerebral arteriopathies. *Nat Rev Cardiol*. 2009;6:395–397.
12. Ganesan V. Pediatric stroke guidelines: where will these take future research and treatment options for childhood stroke? *Expert Rev Neurother*. 2009;9:639–648.
13. Williams LS, Garg BP, Cohen M, Fleck JD, Biller J. Subtypes of ischemic stroke in children and young adults. *Neurology*. 1997;49:1541–1545.
14. Wraige E, Hajat C, Jan W, Pohl KR, Wolfe CD, Ganesan V. Ischaemic stroke subtypes in children and adults. *Dev Med Child Neurol*. 2003;45:229–232.
15. Wraige E, Pohl KR, Ganesan V. A proposed classification for subtypes of arterial ischaemic stroke in children. *Dev Med Child Neurol*. 2005;47:252–256.

16. Sebire G, Fullerton H, Riou E, DeVeber G. Toward the definition of cerebral arteriopathies of childhood. *Curr Opin Pediatr*. 2004;16:617–622.
17. Benseler SM, Silverman E, Aviv RI, Schneider R, Armstrong D, Tyrrell PN, et al. Primary central nervous system vasculitis in children. *Arthritis Rheum*. 2006;54:1291–1297.
18. Cellucci T, Benseler SM. Central nervous system vasculitis in children. *Curr Opin Rheumatol*. 2010;22:590–597.
19. deVeber G. The International Paediatric Stroke Study. The Hospital for Sick Children (SickKids) Web site. <http://www.ccb.sickkids.ca/index.php/the-international-paediatric-stroke-study-ipss.html>. Accessed October 7, 2011.
20. Calabrese LH, Mallek JA. Primary angitis of the central nervous system. Report of 8 new cases, review of the literature, and proposal for diagnostic criteria. *Medicine (Baltimore)*. 1988;67:20–39.
21. Benseler SM, DeVeber G, Hawkins C, Schneider R, Tyrrell PN, Aviv RI, et al. Angiography-negative primary central nervous system vasculitis in children: a newly recognized inflammatory central nervous system disease. *Arthritis Rheum*. 2005;52:2159–2167.
22. Fink A, Kosecoff J, Chassin M, Brook RH. Consensus methods: characteristics and guidelines for use. *Am J Public Health*. 1984;74:979–983.
23. Dalkey NC. The Delphi method: an experimental study in group opinion. Santa Monica, CA: RAND Corporation, 1969.
24. Benseler SM. Central nervous system vasculitis in children. *Curr Rheumatol Rep*. 2006;8:442–449.
25. Ozen S, Ruperto N, Dillon MJ, Bagga A, Barron K, Davin JC, et al. EULAR/PReS endorsed consensus criteria for the classification of childhood vasculitides. *Ann Rheum Dis*. 2006;65:936–941.
26. Ay H, Benner T, Arsava EM, Furie KL, Singhal AB, Jensen MB, et al. A computerized algorithm for etiologic classification of ischemic stroke: the Causative Classification of Stroke System. *Stroke*. 2007;38:2979–2984.
27. Raju TN, Nelson KB, Ferriero D, Lynch JK. Ischemic perinatal stroke: summary of a workshop sponsored by the National Institute of Child Health and Human Development and the National Institute of Neurological Disorders and Stroke. *Pediatrics*. 2007;120:609–616.
28. Fleiss JL. Measuring nominal scale agreement among many raters. *Psychol Bull*. 1971;76:378–382.
29. Landis JR, Koch GG. The measurement of observer agreement for categorical data. *Biometrics*. 1977;33:159–174.
30. Fullerton HJ, Wu YW, Sidney S, Johnston SC. Risk of recurrent childhood arterial ischemic stroke in a population-based cohort: the importance of cerebrovascular imaging. *Pediatrics*. 2007;119:495–501.

Focal Cerebral Arteriopathy of the Young: Clinical Profile, Outcomes, and Utility of High-Resolution Vessel Wall Imaging

Ankith Bhasi^a Naveen Kumar Paramasivan^a Adarsh Anil Kumar^b
Rohith Maraludevanapura Govindaiah^a Chandrasekharan Kesavadas^b
Jayadevan Enakshy Rajan^b Sapna Erat Sreedharan^a
Padmavathy Narayanan Sylaja^a

^aComprehensive Stroke Care Program, Department of Neurology, Sree Chitra Tirunal Institute for Medical Sciences and Technology, Thiruvananthapuram, India; ^bDepartment of Imaging Science and Interventional Radiology, Sree Chitra Tirunal Institute for Medical Sciences and Technology, Thiruvananthapuram, India

Keywords

Focal cerebral arteriopathy · Young stroke · Vessel wall imaging · Outcomes

Abstract

Introduction: The data on focal cerebral arteriopathy (FCA) in young adults are limited to very few series, and the role of high-resolution magnetic resonance vessel wall imaging (MRVWI) has not been adequately explored. **Methods:** FCA was defined as unilateral, unifocal nonprogressive stenosis/irregularity of the distal internal carotid artery (ICA) or its proximal branches. All young patients aged 18–55 years admitted to our institute between 2010 and 2022 were retrospectively reviewed, and functional outcomes were quantified using the modified Rankin scale. **Results:** We identified 10 patients (9 males) with FCA giving an incidence rate of 2.8 per 1,000 person-years. Nine patients had an ischemic presentation (transient ischemic attacks = 5, minor strokes = 3, and major stroke = 1), while 1 patient had a cortical subarachnoid hemorrhage. The supraclinoid ICA and proximal middle cerebral artery (MCA) were the most common segments involved. Nine patients were treated with antiplatelets, and 3 received additional steroids. All cases underwent MRVWI, with

concentric wall enhancement noted in most (80%). Follow-up imaging showed improvement in stenosis in 2 patients and a reduction in vessel wall enhancement in 3 patients. Except for the patient with a major stroke, all others had excellent short- and long-term outcomes with no recurrence of ischemic events. The presence of vessel wall enhancement did not predict short- or long-term outcomes. **Conclusion:** FCA is a rare cause of young stroke that preferentially involves the supraclinoid ICA and proximal MCA with excellent outcomes. MRVWI can be useful in ruling out mimics, but the presence of contrast enhancement did not predict outcome.

© 2025 The Author(s).
Published by S. Karger AG, Basel

Introduction

Focal cerebral arteriopathy (FCA) refers to a unilateral focal irregularity or stenosis of a large intracranial artery of the anterior circulation that supplies the area of infarction [1–3]. FCA could have a transient (nonprogressive stenosis) or a progressive course, determined primarily by follow-up angiography [1, 2]. Despite being widely reported in the pediatric literature, where it accounts for about 25% of

pediatric stroke etiologies, description of adult cases is restricted to a few case series [4, 5]. Moreover, the utility of a high-resolution magnetic resonance vessel wall imaging (MRVWI) has not been explored in adult FCA patients. We aimed to describe the clinical profile of a cohort of young adults with focal cerebral arteriopathy and explore the role of high-resolution MRVWI in the diagnostic workup and outcome of these patients.

Methods

We retrospectively reviewed our electronic medical records of all young patients (aged 18–55 years) admitted to our institute with acute ischemic stroke between 2010 and 2022. We defined FCA as unilateral, unifocal, nonprogressive stenosis/irregularity of the distal internal carotid artery (ICA) or its proximal branches [3]. We excluded cases that had a clear alternative diagnosis, such as moyamoya disease, intracranial atherosclerosis, or reversible cerebral vasoconstriction syndrome. Data on clinical presentation, parenchymal imaging (CT brain or MRI brain), and vessel imaging (CT angiogram, MR TOF angiogram, or digital subtraction angiography) including a high-resolution MRVWI performed at presentation and during follow-up were reviewed. Vessel wall enhancement and grading of its intensity were done using previously published criteria [6]. FCA severity score (FCASS) was calculated for the initial and final angiograms [7]. Short-term and long-term outcomes were noted at 3-month and 1-year follow-ups, respectively, with poor outcome defined as a modified Rankin Scale (mRS) >2. Workup for alternative etiologies included antinuclear antibodies, anti-neutrophil and cytoplasmic antibodies, anti-double-stranded DNA antibody, anti-Ro and anti-L antibodies, serum venereal disease research laboratory test, viral serologies for human immunodeficiency virus, hepatitis B surface antigen, anti-hepatitis C antibodies, serum varicella antibodies, homocysteine levels, sickling test, hemoglobin electrophoresis, echocardiogram, and an electrocardiogram. Results of cerebrospinal fluid (CSF) were collected when available. The study was approved by the Institutional Ethics Committee (IEC). As it was a retrospective review, a waiver of informed consent was obtained from the IEC.

Results

Between 2010 and 2022, we identified 295 young adults admitted with a first-ever stroke, of whom 17 satisfied the criteria for FCA. However, seven cases were

excluded (progression of arteriopathy in subsequent imaging suggestive of unilateral moyamoya disease = 5, no clinical follow-up = 2). We thus included 10 patients (9 males) with focal cerebral arteriopathy, giving us an incidence rate of 2.8 cases per 1,000 person-years. The median age of the cohort was 28.5 (range 19–43) years. Vascular risk factors like hypertension, diabetes, and dyslipidemia were noted in four (40%) patients. The majority (90%) had an ischemic event at presentation, while 1 patient (10%) presented with headache and cortical subarachnoid hemorrhage. At the presentation, 5 patients had transient ischemic attacks (TIAs), three had minor strokes (median National Institute of Health Stroke Scale score [NIHSS] 2) and one had a major stroke with an NIHSS of 13.

Six patients underwent CT angiograms, and 8 patients underwent digital subtraction angiography at the time of admission, which ruled out the involvement of other vessels. The maximum luminal narrowing ranged from 50 to >95%. All 10 patients underwent MRVWI at initial admission. Nine (90%) patients had a characteristic involvement of the supraclinoid ICA with or without involvement of the proximal M1 middle cerebral artery (MCA) or A1 anterior cerebral artery (A1 ACA) (Table 1). Concentric and eccentric patterns of vessel wall enhancement were noted in 8 and 2 patients, respectively. The median length of vessel wall enhancement was 9 mm (range 2.8–16 mm), and most (80%) patients had a grade 2 enhancement. Six patients had a follow-up MRVWI with a reduction in grade of contrast enhancement noted in 3 patients (Fig. 1), and a reduction in length of enhancement (median 1.75 mm) was noted in 4 patients. The FCA severity score (FCASS) was obtained in all patients with a median of 8 (range 2–12) at initial imaging and a median of 7 (range 2–14) at follow-up imaging. In the entire cohort, only 2 patients had improvement in the focal stenosis (Fig. 2), while 8 patients had no change in their stenosis.

Serum varicella IgG was positive in 4/5 cases tested. Six of the 7 patients had a non-inflammatory CSF, while one had an isolated mild elevation of protein (64 mg/dL) without pleocytosis. All other workups for etiologies of young stroke were noncontributory in these patients.

All 9 patients with an ischemic presentation were treated with antiplatelets. Three patients received additional oral corticosteroids that were tapered gradually over 3–12 months, two of whom had reduction in vessel wall enhancement, while one had partial resolution of stenosis on follow-up. However, except for the patient with a major stroke who continued to remain at mRS 3, both at 3 months and 1 year, all other patients had

Table 1. Clinical and imaging profile and outcomes of the cohort

| Patient n | Clinical presentation | Site involved at initial angiogram (CTA/DSA) | Initial MRVWI thickening and enhancement | Treatment | Resolution of stenosis on follow-up angiogram (CTA/DSA) | Resolution of contrast enhancement on follow-up MRVWI | FCASS initial | FCASS follow-up | mRS of 3 months | mRS final | Years of follow-up |
|-----------|---------------------------|--|--|---------------|---|---|---------------|-----------------|-----------------|-----------|--------------------|
| 1 | Minor stroke | Left supraclinoid ICA | Concentric thickening and grade 2 enhancement | AP | N/a | N/a | 8 | 8 | 0 | 0 | 4 |
| 2 | TIA | Right supraclinoid ICA terminal narrowing with significant narrowing of right M1 MCA | Concentric thickening and grade 2 enhancement | AP | N/a | N/a | 8 | 6 | 0 | 0 | 2 |
| 3 | Headache and cortical SAH | Right supraclinoid ICA and A1 ACA narrowing present with proximal M1 occlusion | Focal thickening, eccentric grade 2 enhancement | Supportive | Resolution of stenosis to <50% | N/a | 8 | 4 | 0 | 0 | 2 |
| 4 | TIA | Right supraclinoid ICA and M1 MCA | Focal thickening, eccentric grade 2 enhancement | AP + steroids | Resolution of stenosis to <50% | Yes | 11 | 8 | 0 | 0 | 1 |
| 5 | TIA | Right supraclinoid ICA, proximal M1 MCA, and A1 ACA | Concentric thickening and grade 2 enhancement | AP | No | Yes | 12 | 10 | 0 | 0 | 2 |
| 6 | Minor stroke | Left supraclinoid ICA and proximal M1 MCA | Concentric thickening and grade 2 enhancement ⁷ | AP | No | N/a | 9 | 7 | 0 | 0 | 3 |
| 7 | Major stroke | Right terminal ICA, proximal M1 MCA, and A1 ACA | Concentric thickening and grade 3 enhancement | AP | No | No | 12 | 14 | 3 | 3 | 1 |
| 8 | TIA | Left distal M1 MCA | Concentric thickening and grade 2 enhancement | AP | No | N/a | 5 | 6 | 0 | 0 | 1 |

Table 1 (continued)

| Patient n | Clinical presentation | Site involved at initial angiogram (CTA/DSA) | Initial MRVWI thickening and enhancement | Treatment | Resolution of stenosis on follow-up angiogram (CTA/DSA) | Resolution of contrast enhancement on follow-up MRVWI | FCASS initial | FCASS follow-up | mRS of 3 months | mRS final | Years of follow-up |
|-----------|-----------------------|--|---|---------------|---|---|---------------|-----------------|-----------------|-----------|--------------------|
| 9 | TIA | Left supraclinoid ICA and proximal M1 MCA | Concentric thickening and grade 2 enhancement | AP + steroids | No | Yes | 8 | 6 | 0 | 0 | 5 |
| 10 | Minor stroke | Left supraclinoid ICA and proximal M1 MCA | Concentric thickening and grade 2 enhancement | AP + steroids | No | No | 9 | 8 | 0 | 0 | 1 |

AP, antiplatelets; ACA, anterior cerebral artery; CTA, computed tomography angiogram; DSA, digital subtraction angiography; FCASS, focal cerebral arteriopathy severity score; ICA, internal carotid artery; MCA, middle cerebral artery; MRVWI, magnetic resonance vessel wall imaging; M, males; SAH, subarachnoid hemorrhage; TIA, transient ischemic attack.

recovered completely to mRS 0 by the time of discharge. The median follow-up duration was 2 (range 1–4) years, and there were no recurrences. There was no significant difference in short- or long-term outcomes between those who received steroids compared to those who did not. Similarly, the persistence of the contrast enhancement in MRVWI was not associated with poor outcomes. The only patient with a poor outcome had a change in FCASS from 12 to 14, while the change in FCASS did not influence the outcome in any of the other patients.

Discussion

We present a series of young adults with focal cerebral arteriopathy, most of whom had an ischemic presentation (TIAs or minor strokes); a characteristic involvement of the supraclinoid ICA and proximal M1 MCA by angiography, with excellent short-term and long-term functional outcomes. Most patients had an active concentric grade 2 enhancement on MRVWI which improved in 30% of cases albeit without a correlation with functional outcomes. Although FCASS was useful in capturing the severity of the stenosis, we did not find the scores to predict outcomes as all patients had a monophasic course and 90% recovered completely from the initial event.

FCA is an uncommon cause of stroke in young adults as shown by our incidence rate of 2.8 per 1,000 person-years. This contrasts with an estimated incidence rate of 2.4% over a single year in an Irish cohort, reflecting differences in epidemiology between countries [5]. Although this previous series identified a crescendo pattern of symptom evolution, all patients in our cohort had an acute presentation and had no recurrences.

We did not find MRVWI to predict progression of stenosis, contrary to that reported in the pediatric literature [8]. However, high-resolution MRVWI helped better clarify the diagnosis in these patients as it offers additional information compared to other luminal imaging modalities. None of the patients had imaging features of alternative etiologies such as intracranial atherosclerosis, reversible cerebral vasoconstriction syndrome, or an intracranial dissection. The absence of characteristic T2/FLAIR changes and microbleeds in the MRI brain, along with the focal angiographic findings, argued against the possibility of CNS vasculitis in these patients. At the initial evaluation, it is often very difficult to differentiate between focal cerebral arteriopathy and unilateral moyamoya disease, which is

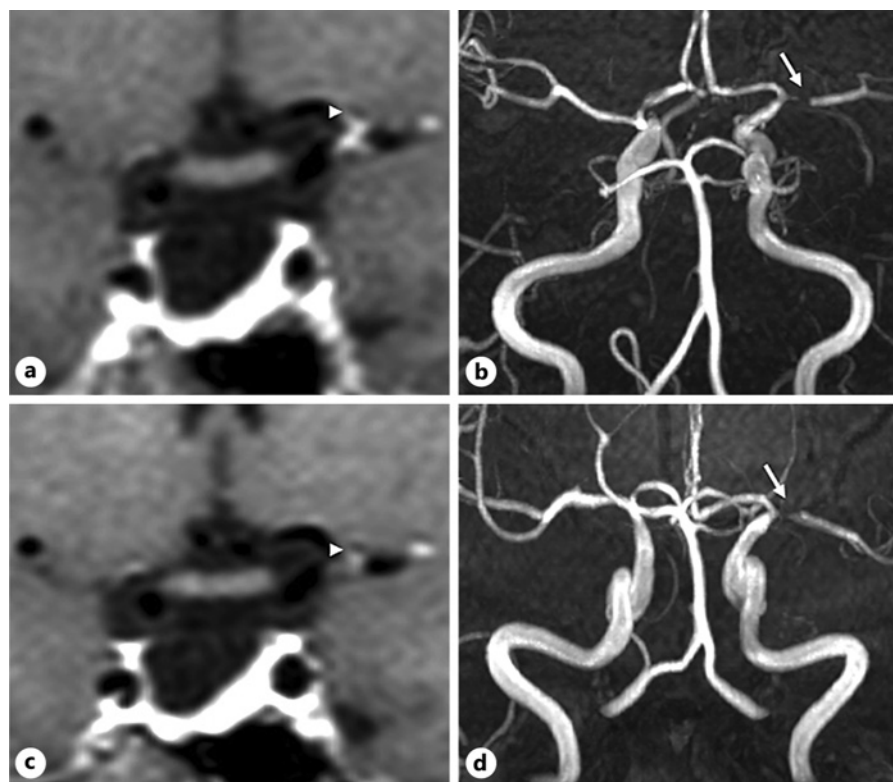


Fig. 1. Coronal reformat of 3D T1 FS sequence of a patient at baseline demonstrating concentric grade 3 enhancement (white arrowheads) with 3D TOF MRA (a) showing narrowing (white arrows) of the left terminal ICA, proximal M1 MCA, and proximal A1 ACA (FCA score = 8) (b). Follow-up coronal 3D T1 FS demonstrating the reduction in degree of enhancement to grade 2 (white arrowheads) with similar extent (c) and 3D TOF MRA showing reduction in FCA score to 6 (d).

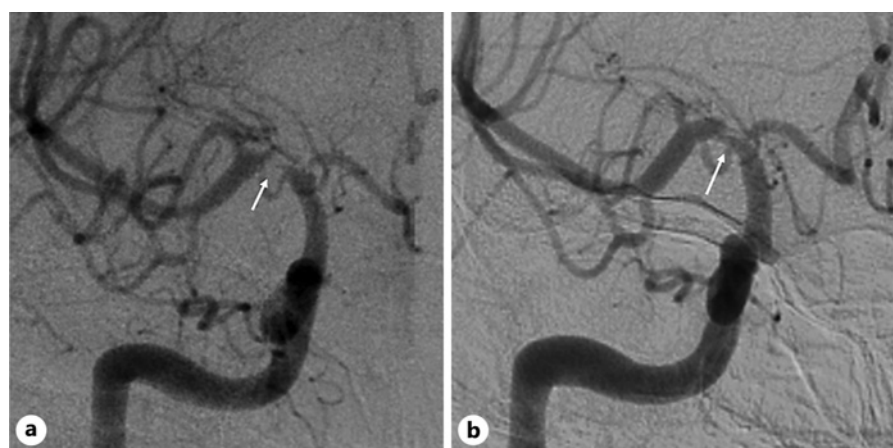

Fig. 2. a Right ICA AP angiogram of a patient at baseline demonstrating the significant narrowing (white arrows) of right terminal ICA, proximal M1 MCA, and proximal A1 ACA (FCA score = 9). b Follow-up angiogram demonstrating the interval improvement in narrowing (FCA score = 7). AP, antiplatelets.

another close differential. Detailed evaluation and follow-up imaging will help identify important clues such as involvement of the terminal ICA in-conjunction with the proximal M1 MCA and A1 ACA and the appearance of collateral vessels on follow-up imaging. It is important to differentiate them as the prognosis as well as management strategy varies. Recognition of FCA with confirmation by follow-up imaging often helps in prognostication as these patients often have excellent

outcomes. The absence of further recurrence of ischemic events and the absence of progression of vessel stenosis may suggest FCA.

With regard to treatment, there exists no evidence-based guidelines for the management of FCA. Addition of steroids has been shown to improve functional outcomes, and antiplatelets have been shown to have reduced recurrence rates in pediatric literature [2, 9]. However, no such studies were explored in adults, and we did not find

any differences between those who were treated with additional steroids compared to standard antiplatelets. In addition, based on our results, we find that persistent MR vessel wall enhancement does not necessarily mandate immunotherapy.

The strengths of our study include systematic high-resolution MRVWI at onset and follow-up. Few limitations of our case series included its retrospective nature and small size, which is expected with these rare diseases. Serum varicella IgG was not available for 60% of patients, and we were not able to verify CSF varicella IgG as it was not routinely done in our institute. Although none of our patients had a history or findings of varicella-zoster infection or reactivation, we recognize this limitation as FCA could be a para- or post-infectious phenomenon [1, 9].

Conclusion

FCA is an important cause of young stroke that often presents as a TIA or minor stroke, has a predilection for the supraclinoid ICA and proximal M1 MCA with very good outcomes. MR vessel wall imaging does not predict the outcomes. Future studies with larger sample sizes might shed light on the role of corticosteroids in patients with persistent vessel wall enhancement and whether they offer any additional benefit beyond antiplatelet therapy.

Acknowledgments

We are grateful to all patients who participated in this study.

References

- 1 Braun KP, Bulder MM, Chabrier S, Kirkham FJ, Uiterwaal CS, Tardieu M, et al. The course and outcome of unilateral intracranial arteriopathy in 79 children with ischaemic stroke. *Brain*. 2009;132(Pt 2):544–57. <https://doi.org/10.1093/brain/awn313>
- 2 Steinlin M, Bigi S, Stojanovski B, Gajera J, Regényi M, El-Koussy M, et al. Focal cerebral arteriopathy: do steroids improve outcome? *Stroke*. 2017;48(9):2375–82. <https://doi.org/10.1161/STROKEAHA.117.016818>
- 3 Wintermark M, Hills NK, DeVeber GA, Barkovich AJ, Bernard TJ, Friedman NR, et al. Clinical and imaging characteristics of arteriopathy subtypes in children with arterial ischemic stroke: results of the VIPS study. *AJNR Am J Neuroradiol*. 2017;38(11):2172–9. <https://doi.org/10.3174/ajnr.A5376>
- 4 Bulder MM, Braun KP, Leeuwis JW, Lo RT, van Nieuwenhuizen O, Kappelle LJ, et al. The course of unilateral intracranial arteriopathy in young adults with arterial ischemic stroke. *Stroke*. 2012;43(7):1890–6. <https://doi.org/10.1161/STROKEAHA.112.653212>
- 5 McKenna MC, Fanning N, Cronin S. Focal cerebral arteriopathy in young adult patients with stroke. *Stroke*. 2020;51(5):1596–9. <https://doi.org/10.1161/STROKEAHA.119.028343>
- 6 Adhithyan R, Kesav P, Thomas B, Sylaja PN, Kesavadas C. High-resolution magnetic resonance vessel wall imaging in cerebrovascular diseases. *Neurol India*. 2018;66(4):1124–32. <https://doi.org/10.4103/0028-3886.236964>
- 7 Fullerton HJ, Stence N, Hills NK, Jiang B, Amlie-Lefond C, Bernard TJ, et al. Focal cerebral arteriopathy of childhood: novel severity score and natural history. *Stroke*. 2018;49(11):2590–6. <https://doi.org/10.1161/STROKEAHA.118.021556>
- 8 Stence NV, Pabst LL, Hollatz AL, Mirsky DM, Herson PS, Poisson S, et al. Predicting progression of intracranial arteriopathies in childhood stroke with vessel wall imaging. *Stroke*. 2017;48(8):2274–7. <https://doi.org/10.1161/STROKEAHA.117.017922>
- 9 Chabrier S, Sébire G, Fluss J. Transient cerebral arteriopathy, postvaricella arteriopathy, and focal cerebral arteriopathy or the unique susceptibility of the M1 segment in children with stroke. *Stroke*. 2016;47(10):2439–41. <https://doi.org/10.1161/STROKEAHA.116.014606>

Statement of Ethics

The study was approved by the Institutional Ethics Committee (IEC) of Sree Chitra Tirunal Institute for Medical Sciences and Technology (SCTIMST), IEC number: 2094 on August 2023. As it was a retrospective review, a waiver of written informed consent was obtained from the IEC.

Conflict of Interest Statement

P.N. Sylaja was a member of the journal's Editorial Board at the time of submission. All other authors declare no conflict of interest.

Funding Sources

No funding was received for this study.

Author Contributions

A.B. contributed to conceptualization of the study and data collection. N.K.P. analyzed the data and drafted the manuscript. A.A.K. and R.M.G. contributed to data collection and analysis. C.K., J.E.R., and S.E.S. critically revised the manuscript. S.P.N. conceptualized and designed the study, drafted the manuscript, and critically revised it.

Data Availability Statement

All data generated or analyzed during this study are included in this article. Further inquiries can be directed to the corresponding author.

Association Between Thrombectomy and Functional Outcomes in Pediatric Patients With Acute Ischemic Stroke From Large Vessel Occlusion

Kartik D. Bhatia, MBBS, PhD; Samyami Chowdhury, MBChB; Ian Andrews, MBBS; Robert Goetti, MBBS; Richard Webster, MBBS; Christopher Troedson, MBBS; Russell C. Dale, MBBS, PhD; Prakash Muthusami, MD; Carmen Parra-Farinas, MD; Nomazulu Dlamini, MD; Mahendra Moharir, MD; Christina Miteff, MBBS; Ferdinand Miteff, MBBS; John Worthington, MBBS; Kylie Tastula, RN; Timothy Ang, MBBS; Romain Briest, MBBS; Elizabeth Pulcine, MD

 Supplemental content

IMPORTANCE Pediatric large vessel occlusion (LVO) stroke has a poor natural history. However, uptake of mechanical thrombectomy is hindered by a lack of clinical trial data in children. A randomized clinical trial is not feasible due to small sample sizes and absence of equipoise.

OBJECTIVE To evaluate whether pediatric patients with acute LVO stroke who undergo thrombectomy have better clinical outcomes than matched patients managed conservatively.

DESIGN, SETTING, AND PARTICIPANTS This matched case-control study used pooled stroke registry data from 5 tertiary referral hospitals in Australia and Canada from January 2011 to April 2022. Patients were aged 1 month to younger than 18 years with acute LVO stroke. Pooled data identified 31 thrombectomy patients and 46 control patients. Five patients undergoing thrombectomy with basilar artery occlusion were excluded due to insufficient controls. Using a hierarchical matching system (site of occlusion, age group, side of occlusion, and sex), deidentified consensus matching of patients and controls was undertaken while blinded to clinical outcome. Data were analyzed from July to November 2022.

EXPOSURE In the case cohort, mechanical thrombectomy was undertaken for management of acute LVO stroke. The control cohort received medical treatment only.

MAIN OUTCOMES AND MEASURES The primary outcome was the functional clinical status 3 months following stroke, measured by the pediatric modified Rankin Scale (mRS). Clinical outcomes were compared between groups using ordinal regression analysis.

RESULTS Of 52 included patients, 31 (60%) were male, and the mean (SD) age was 10.3 (4.4) years. Matching was achieved for 26 children undergoing thrombectomy with 26 controls. There was no significant difference between groups for site or side of occlusion, age, sex, etiology, thrombolysis status, baseline Alberta Stroke Programme Early CT Score, or time since last seen well to presentation. Patients undergoing thrombectomy had superior clinical outcomes than control patients at 3 months on the pediatric mRS (odds ratio, 3.76; 95% CI, 1.32-10.67; $P = .01$). These superior outcomes were maintained at final follow-up (odds ratio, 3.65; 95% CI, 1.25-10.68; $P = .02$).

CONCLUSIONS AND RELEVANCE In the absence of a randomized clinical trial, this case-control study demonstrates better clinical outcomes with thrombectomy than medical management alone for pediatric patients aged 2 to 18 years with anterior circulation LVO stroke.

Author Affiliations: Author affiliations are listed at the end of this article.

Corresponding Author: Kartik D. Bhatia, MBBS, PhD, Department of Medical Imaging, Children's Hospital at Westmead, Hawkesbury Road and Hainsworth Street, Westmead, NSW 2145, Australia (kartik.bhatia@health.nsw.gov.au).

JAMA Neurol. 2023;80(9):910-918. doi:10.1001/jamaneurol.2023.2303
Published online July 24, 2023. Corrected on September 11, 2023.

Mechanical thrombectomy is the standard of care for adults with large vessel occlusion (LVO) stroke after the publication of 5 positive randomized clinical trials in 2015.¹⁻⁵ None of these trials included patients younger than 18 years. As a result, mechanical thrombectomy for pediatric LVO stroke remains less accepted, with limited recommendations for its use in pediatric stroke treatment guidelines.^{6,7}

We previously published a population-based study of clinical outcomes in pediatric LVO stroke.⁸ For patients managed conservatively, unfavorable clinical outcomes occurred in 73.1% at 3 months and 57.7% at final follow-up.⁹ Therefore, the natural history of pediatric LVO stroke managed conservatively is poor, with most experiencing long-term moderate to severe disability or death.⁹ These results demonstrate the need for effective reperfusion therapies in children.

More than 400 pediatric patients undergoing mechanical thrombectomy are reported in the literature, including case reports, case series, retrospective single-arm cohort studies,⁹⁻¹¹ and national inpatient database analyses.^{8,12} Favorable clinical outcomes in these studies, equivalent to a modified Rankin Scale (mRS) score of 0 to 2, vary from 55.3% to 89.5%.⁸⁻¹² Adolescents are disproportionately represented in these studies, relative to younger children.⁸⁻¹⁰ Given the meta-analysis rate of favorable outcomes with mechanical thrombectomy in adults at 3 months is 46.0%,¹³ these observations raise concerns of selection and publication bias.

We reasoned a randomized clinical trial for thrombectomy in pediatric patients with LVO stroke would now be unethical due to loss of equipoise. In addition, such a trial is unlikely to be feasible due to small sample sizes and recruitment challenges, as observed in the abandoned randomized clinical trial for intravenous thrombolysis in pediatric stroke.¹⁴ Therefore, we undertook a case-control study matching patients undergoing thrombectomy and control patients for age, site of occlusion, and sex, aiming to provide the next highest level of comparative evidence.

Methods

Study Design

Institutional ethics approval was obtained from each participating center and from the Sydney Children's Hospital Network Human Research Ethics Committee. Informed consent was waived due to the retrospective design and long period of time covered in the cohort. This was a multicenter retrospective matched case-control study, pooling data from pediatric stroke registries and databases across 5 centers in New South Wales, Australia, and Ontario, Canada, covering the period January 2010 to April 2022. This study followed the Strengthening the Reporting of Observational Studies in Epidemiology (STROBE) reporting guideline.

Registry data from each center were filtered using the following inclusion criteria: (1) age of 1 month to younger than 18 years at initial assessment, (2) acute arterial ischemic stroke diagnosed by a neurologist with supportive imaging findings, and (3) LVO demonstrated on baseline computed tomography angiography, magnetic resonance

Key Points

Question Does mechanical thrombectomy result in better clinical outcomes for pediatric patients with large vessel occlusion stroke?

Findings In this case-control study, mechanical thrombectomy (n = 26) was associated with superior clinical outcomes on the pediatric modified Rankin Scale score at 3 months compared with matched controls (n = 26) who received medical treatment only. The difference between groups was statistically significant, and these superior outcomes were maintained at final available follow-up.

Meaning In this study, mechanical thrombectomy resulted in better clinical outcomes than conservative management for acute large vessel occlusion stroke in children and adolescents aged 2 to 18 years.

angiography, or digital subtraction angiography. Neonatal patients with stroke (younger than 29 days) were excluded.

Patients who received mechanical thrombectomy were matched 1:1 with control patients who received medical therapy only (ie, neuroprotective measures with or without antithrombotic therapy with antiplatelets, anticoagulants, or fibrinolytics), using a hierarchical matching system. Patients consented for mechanical thrombectomy who received bridging intravenous thrombolytic and had recanalization on digital subtraction angiography were also included as cases, using an intention-to-treat analysis.

Definition of LVO

The definition of LVO for this study is detailed in the eAppendix in [Supplement 1](#) and has been previously published in our prior study on the natural history of pediatric LVO.⁹

Matching Process

All pediatric patients with LVO fulfilling the inclusion criteria were deidentified and allocated a study identifier; clinical outcome data were separated, and deidentified data blinded to clinical outcome were pooled across all 5 centers. Patients undergoing mechanical thrombectomy and controls were separated into 2 lists. Matching (1:1) was undertaken at a single teleconference session by a committee of 5 investigators (2 pediatric neurologists [S.C. and E.P.] and 3 pediatric neurointerventionists [K.D.B., P.M., and C.P.F.]) from both countries, using deidentified data while blinded to clinical outcome. Disputes were resolved by majority vote.

Matching was undertaken using a 4-tier hierarchical system with primary matching by location of the most proximal intracranial vascular occlusion (intracranial internal carotid artery [ICA]; proximal to mid M1; M1-2 junction and M2; basilar artery including vertebro-basilar junction), then secondary matching by age group (younger than 2 years, aged 2-6 years, aged 7-11 years, or aged 12-16 years), then by side of occlusion (left, right, or midline), and lastly by sex. Patients that could not be matched by the primary criteria (site of occlusion) were excluded from the study. Age matching was tailored to minimize age differences between patients undergoing thrombectomy and controls. The pooled matched deidentified data set was then linked to clinical outcome data and other imaging data via the study identifier for further analyses.

Outcome Measures

The primary outcome for this study was the functional clinical outcome 3 months after stroke onset, measured using the pediatric mRS score.¹⁵ For patients whose pediatric mRS score was not prospectively recorded in the stroke registries, it was obtained by conversion from Pediatric Stroke Outcome Measure (PSOM) scores (eTable in Supplement 1) or retrospectively derived based on prior assessments undertaken by a pediatric neurologist, neurosurgeon, or rehabilitation physician 2 to 4 months after stroke onset. The primary safety outcome was the rate of symptomatic intracranial hemorrhage (sICH), as defined in the protocol for the European Co-operative Acute Stroke Study III.¹⁶

The secondary outcomes were final pediatric mRS score available and its timing poststroke, PSOM scores at 3 months and at final available follow-up, etiology, timing of initial vascular imaging (hours since last seen well), baseline Alberta Stroke Programme Early CT Score (ASPECTS; a measure of baseline established infarct on noncontrast computed tomography imaging ranging from 0 to 10, with lower scores indicating greater infarct extent)¹⁷ or diffusion-weighted imaging (DWI)-ASPECTS¹⁸ on last available imaging study prior to treatment decision-making. In addition, we evaluated timing of clinical presentation, intravenous and intra-arterial thrombolysis status, and selection criteria fulfilment status (other than age) for the Multicenter Randomized Clinical Trial of Endovascular Treatment of Acute Ischaemic Stroke in the Netherlands (MR-CLEAN) trial,¹ DWI or CTP Assessment with Clinical Mismatch in the Triage of Wake-Up and Late Presenting Stroke Undergoing Neurointervention with Trevo (DAWN) trial,¹⁹ or American Heart Association class I-IIb recommendations for use of thrombectomy in adults.²⁰ Where available, pediatric National Institute of Health Stroke Scale scores at initial assessment and 24 hours later were recorded, but these were not retrospectively derived. The secondary safety outcomes included decompressive craniectomy status and major access site complications requiring blood transfusion, surgery, or endovascular treatment.

Imaging Analysis

ASPECTS was determined from the last available imaging study prior to treatment decision-making, based on either computed tomography or magnetic resonance imaging (DWI). The presence and location of the most proximal intracranial occlusion were independently assessed by a pediatric neuroradiologist blinded to clinical outcome in each country.

Statistical Analysis

The primary analysis, comparing pediatric mRS scores at 3 months after stroke onset between the case and control groups, was undertaken with ordinal logistic regression to determine the odds ratio (OR) and *P* value for a better outcome on the pediatric mRS (ie, a lower score on the scale from 0 to 6). Secondary analyses were undertaken using ordinal logistic regression for pediatric mRS and PSOM data, χ^2 testing for categorical variables, and the unpaired *t* test for continuous variables. Complete-case analysis was used to account for missing data. All *P* values were 2-tailed, and significance was set

at *P* < .05. All statistical analyses were undertaken using the statistical software MiniTab version 19.2020.2.0 (MiniTab).

Results

Initial pooling of stroke registry data yielded 31 potential patients (with 34 thrombectomy procedures) and 46 potential controls. A total of 5 patients undergoing thrombectomy could not be matched due to insufficient control patients with basilar artery occlusion.

Of 52 included patients, 31 (60%) were male, and the mean (SD) age was 10.3 (4.4) years. Matching was achieved for 26 children undergoing thrombectomy with 26 controls. Of the 26 patients in each group, 24 had LVO involving the anterior circulation. Two matched patients underwent a second thrombectomy procedure, due to recurrent occlusion in the same angiographic location within 96 hours of the original occlusion; each achieved successful recanalization at both of their procedures. Because the primary outcome was measured at 3 months poststroke, these 2 patients were each counted once only for pediatric mRS outcome data.

There was no significant difference between the case and control groups for age, sex, site or side of occlusion, intravenous or intra-arterial thrombolysis status, stroke etiology, baseline ASPECTS, or time since last seen well until initial clinical presentation. More patients in the thrombectomy group received intravenous thrombolysis compared with the control group, but this difference was not statistically significant (4 vs 1; *P* = .16). Baseline demographic and imaging data for each group are summarized in Table 1.

Primary Outcome

Pediatric patients with LVO who underwent thrombectomy were significantly more likely to have a better functional outcome on the pediatric mRS at 3 months after stroke than control patients with LVO managed with medical therapy alone (OR, 3.76; 95% CI, 1.32-10.67; *P* = .01). The absolute risk reduction for a poor outcome (pediatric mRS of 3 to 6) with thrombectomy at 3 months was 19.2% (number needed to treat, 6). There was no significant difference in the rate of sICH (1 in each group). Better functional outcomes in the thrombectomy group at 3 months were also confirmed when comparing PSOM scores (OR, 4.72; 95% CI, 1.69-13.15; *P* = .003). Primary outcome results are detailed in Table 2 and the Figure.

Secondary Outcomes

Patients undergoing mechanical thrombectomy were significantly more likely to have a better functional outcome on the pediatric mRS at final available follow-up than control patients (mean [SD] follow-up, 33.0 [26.7] months; OR, 3.65; 95% CI, 1.25-10.68; *P* = .02). The absolute risk reduction for a poor outcome with thrombectomy at final follow-up was 26.9% (number needed to treat, 4). These better outcomes in the thrombectomy group were also confirmed when comparing final PSOM scores (OR, 4.33; 95% CI, 1.56-12.01; *P* = .005). Control patients had significantly longer final follow-up than patients undergoing thrombec-

Table 1. Baseline Demographic, Imaging, and Clinical Characteristics

| Characteristic | No. (%) | | P value ^a |
|---|-----------------------|-----------------------|----------------------|
| | Thrombectomy group | Control group | |
| Patients, No. | 26 | 26 | NA |
| Thrombectomy procedures, No. | 28 ^b | 0 | NA |
| Sex | | | |
| Female | 10 (38.5) | 11 (42.3) | .78 |
| Male | 16 (61.5) | 15 (57.7) | |
| Age, y | | | |
| Mean (SD) | 10.9 (4.4) | 9.8 (4.4) | .37 |
| Median (range) | 12.5 (3.1-16.0) | 10.5 (1.9-17.0) | |
| Age group, y | | | |
| 0-2 | 0 | 1 (3.8) | .62 |
| 3-6 | 6 (23.1) | 5 (19.2) | |
| 7-11 | 6 (23.1) | 9 (34.6) | |
| 12-17 | 14 (53.8) | 11 (42.3) | |
| Thrombolysis status | | | |
| Intravenous tPA given | 4 (15.4) | 1 (3.8) | .16 |
| Intra-arterial tPA given | 0 | 2 (7.7) | .15 |
| Intravenous or intra-arterial tPA given | 4 (15.4) | 3 (11.5) | .69 |
| Site of occlusion | | | |
| Intracranial ICA | 10 (38.4) | 10 (38.4) | >.99 |
| MCA, proximal to mid M1 | 9 (34.6) | 9 (34.6) | |
| MCA, M1-2 junction to M2 | 5 (19.2) | 5 (19.2) | |
| Basilar/vertebrobasilar | 2 (7.7) | 2 (7.7) | |
| Side of occlusion | | | |
| Left | 14 (53.8) | 13 (50.0) | .96 |
| Right | 10 (38.4) | 11 (42.3) | |
| Midline | 2 (7.7) | 2 (7.7) | |
| Baseline ASPECTS, No./total No. (%) | | | |
| CT available | 22/28 (78.6) | 17/26 (65.4) | .13 |
| DWI available | 12/28 (42.9) | 21/26 (80.8) | |
| Both CT and DWI available | 6/28 (21.4) | 12/26 (46.2) | |
| ASPECTS, mean (SD) ^c | 6.8 (2.25) | 6.7 (2.74) | .94 |
| ASPECTS ≤5 | 6/28 (21.4) | 7/26 (26.9) | .64 |
| Stroke etiology | | | |
| Cardio-embolic | 10 (38.5) | 8 (30.8) | .66 |
| Idiopathic | 5 (19.2) | 3 (11.5) | |
| Dissection | 4 (15.4) | 7 (26.9) | |
| Other | 7 (26.9) ^d | 8 (30.8) ^e | |
| Time since LSW, mean (SD), min | | | |
| Initial clinical presentation | 157 (159) | 226 (346) | .43 |
| Arrival at pediatric hospital | 344 (400) | 554 (655) | .24 |
| Initial angiographic imaging | 301 (318) | 661 (909) | .07 |
| Clinical presentation timing, No./total No. (%) | | | |
| <6 h | 24/28 (85.7) | 16/26 (61.5) | NA |
| 6-24 h | 4/28 (14.3) | 8/26 (30.8) | |
| >24 h | 0 | 2/26 (7.7) | |
| Total <24 h | 28/28 (100) | 24/26 (92.3) | |

(continued)

Table 1. Baseline Demographic, Imaging, and Clinical Characteristics (continued)

| Characteristic | No. (%) | | P value ^a |
|---|--------------------|---------------|----------------------|
| | Thrombectomy group | Control group | |
| Selection criteria fulfilled | | | |
| MR-CLEAN ¹ | 15 (53.6) | 8 (30.8) | NA |
| DAWN ¹⁹ | 5 (17.9) | 6 (23.1) | NA |
| AHA class I-IIb criteria, No./total No. (%) ²⁰ | 22/28 (78.6) | 16/26 (61.5) | .17 |
| Excluded for ASPECTS ≤5 | 6 (21.4) | 7 (26.9) | NA |
| Excluded for presentation >24 h | 0 | 2 (7.7) | NA |

Abbreviations: AHA, American Heart Association; ASPECTS, Alberta Stroke Program Early CT Score; CT, computed tomography; DAWN, DWI or CTP Assessment With Clinical Mismatch in the Triage of Wake-Up and Late Presenting Stroke Undergoing Neurointervention With Trevo Study¹⁹; DWI, diffusion-weighted imaging; ICA, internal carotid artery; LSW, last seen well; MCA, middle cerebral artery; MR-CLEAN, Multicenter Randomized Clinical Trial of Endovascular Treatment of Acute Ischaemic Stroke in the Netherlands Study¹; NA, not applicable; tPA, tissue plasminogen activator.

^a P values calculated using χ^2 or t tests, as appropriate.

^b Two patients underwent a second thrombectomy procedure within 96 hours of the initial procedure, in both cases due to reocclusion in the same angiographic location (right intracranial ICA and left proximal M1, respectively). For the purposes of measuring clinical outcome at 3 months and final follow-up, both patients were counted once only.

^c For pooled ASPECTS analyses in patients with both baseline CT and DWI available, the final imaging modality used for acute clinical decision-making was included. Both patients with posterior circulation occlusion in each group had ASPECTS of 10.

^d A total of 7 patients undergoing thrombectomy with stroke etiology classified as other included 4 with paradoxical embolus, 1 with acute thrombosis following radiotherapy for adjacent suprasellar pilocytic astrocytoma, 1 with hypercoagulable state, and 1 with extracorporeal membrane oxygenation system-related embolus.

^e A total of 8 control patients with stroke etiology classified as other included 3 with focal cerebral arteriopathy with superimposed acute thrombotic occlusion, 2 with large-vessel vasculitis, 1 with hypercoagulable state, 1 with drug-induced vasculopathy, and 1 with Bowhunter syndrome with secondary thrombotic occlusion.

Table 2. Pediatric Modified Rankin Scale (mRS) Scores at 3 Months Following Stroke

| Outcome | No. (%) | | OR (95% CI) | P value ^a |
|-------------------------------------|-----------------------------|------------------------|-------------------|----------------------|
| | Thrombectomy group (n = 26) | Control group (n = 26) | | |
| Pediatric mRS score 3 mo poststroke | | | | |
| 0 | 5 (19.2) | 0 | | |
| 1 | 4 (15.4) | 1 (3.8) | | |
| 2 | 8 (30.8) | 11 (42.3) | | |
| 3 | 7 (26.9) | 7 (26.9) | 3.76 (1.32-10.67) | .01 |
| 4 | 2 (7.7) | 6 (23.1) | | |
| 5 | 0 | 1 (3.8) | | |
| 6 | 0 | 0 | | |
| 0-2 | 17 (65.4) | 12 (46.2) | NA | NA |
| 3-6 | 9 (34.6) | 14 (53.8) | NA | NA |
| PSOM score 3 mo poststroke | | | | |
| 0 | 5 (19.2) | 0 | | |
| 0.5 | 4 (15.4) | 1 (3.8) | | |
| 1.0-2.5 | 8 (30.8) | 11 (42.3) | | |
| 3.0-5.0 | 7 (26.9) | 7 (26.9) | 4.72 (1.69-13.15) | .003 |
| 6.0-7.0 | 2 (7.7) | 6 (23.1) | | |
| 8.0-9.0 | 0 | 1 (3.8) | | |
| 10.0 | 0 | 0 | | |
| Primary safety outcome | | | | |
| Symptomatic ICH ^b | 1 (3.8) | 1 (3.8) | NA | >.99 |

Abbreviations: ICH, intracranial hemorrhage; NA, not applicable; OR, odds ratio; PSOM, Pediatric Stroke Outcome Measure.

^a P values calculated using ordinal linear regression or χ^2 tests, as appropriate.

^b The definition used for symptomatic ICH was from the European-Australian Co-operative Acute Stroke Study III trial.¹⁶ Symptomatic ICH was defined as any apparently extravascular blood in the brain or within the cranium that was associated with clinical deterioration, as defined by an increase of 4 points or more in the score on the National Institute of Health Stroke Scale, or that led to death and that was identified as the predominant cause of the neurological deterioration.¹⁶

tomy (mean [SD] follow-up of 46.4 [29.0] vs 17.3 [15.7] months; $P < .001$). Secondary outcome results are detailed in Table 3.

No significant difference was present between groups for decompressive craniectomy status (thrombectomy group, 5 [19.2%]; control group, 6 [23.1%]; $P = .73$). Two patients undergoing thrombectomy had major access site complications (Table 3); neither patient had long-term sequelae from these complications.

In the thrombectomy group, the rate of successful recanalization (modified Treatment in Cerebral Ischaemic score of 2b/3) was 89.3% (25 of 28 procedures). The mean (range) time from last seen well to final recanalization was 695 (130-3840) minutes. The mean reduction in pediatric NIHSS scores at 24 hours postprocedure (data available for 18 of 28 procedures) was 6.1 (5.3) points. While there was heterogeneity of thrombectomy techniques used, most procedures (23 of 28) used a stent-retriever. Secondary out-

Figure. Pediatric Modified Rankin Scale (mRS) Scores Measured 3 Months After Stroke Onset in the Thrombectomy and Control Groups

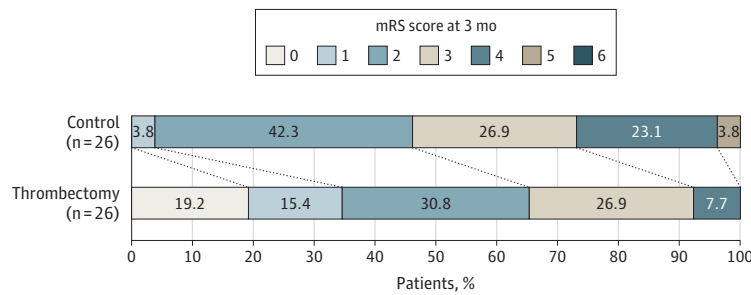


Table 3. Pediatric Modified Rankin Scale (mRS) Scores at Final Available Follow-up

| Outcome | No. (%) | | OR (95% CI) | P value ^a |
|---|-----------------------------|------------------------|-------------------|----------------------|
| | Thrombectomy group (n = 26) | Control group (n = 26) | | |
| Pediatric mRS score at final follow-up | | | | |
| 0 | 7 (26.9) | 1 (3.8) | 3.65 (1.25-10.68) | .02 |
| 1 | 2 (7.7) | 3 (11.5) | | |
| 2 | 13 (50.0) | 11 (42.3) | | |
| 3 | 3 (11.5) | 9 (34.6) | | |
| 4 | 0 | 1 (3.8) | | |
| 5 | 0 | 0 | | |
| 6 | 1 (3.8) | 1 (3.8) | | |
| 0-2 | 22 (84.6) | 15 (57.7) | NA | NA |
| 3-6 | 4 (15.4) | 11 (42.3) | NA | NA |
| PSOM score at final follow-up | | | | |
| 0 | 7 (26.9) | 1 (3.8) | 4.33 (1.56-12.01) | .005 |
| 0.5 | 2 (7.7) | 3 (11.5) | | |
| 1.0-2.5 | 13 (50.0) | 11 (42.3) | | |
| 3.0-5.0 | 3 (11.5) | 9 (34.6) | | |
| 6.0-7.0 | 0 | 1 (3.8) | | |
| 8.0-9.0 | 0 | 0 | | |
| 10.0 | 1 (3.8) | 1 (3.8) | | |
| Timing of final follow-up poststroke, mean (SD), mo | 19.7 (15.7) | 46.4 (29.0) | NA | <.001 |
| Secondary safety outcomes | | | | |
| Craniectomy | 5 (19.2) | 6 (23.1) | NA | .73 |
| Major access site complications ^b | 2 (7.7) | 0 | NA | .15 |

Abbreviations: NA, not applicable; OR, odds ratio; PSOM, Pediatric Stroke Outcome Measure.

^a P values calculated using ordinal linear regression, χ^2 , or t tests, as appropriate.

^b Major access site complications were defined as a complication arising from the arterial access site requiring blood transfusion, surgery, or endovascular treatment. In the thrombectomy arm, 1 patient had a retroperitoneal hemorrhage requiring blood transfusion and placement of a covered stent. The second patient developed a delayed common femoral artery pseudoaneurysm while taking anticoagulation, successfully treated with percutaneous thrombin injection.

comes specific to the thrombectomy group only are detailed in Table 4.

Discussion

In this case-control study of pediatric acute LVO stroke, mechanical thrombectomy resulted in significantly better functional outcomes than medical therapy alone at 3 months (OR, 3.76; 95% CI, 1.32-10.67; $P = .01$). These improved outcomes were sustained into the long-term at final available follow-up (OR, 3.65; 95% CI, 1.25-10.68; $P = .02$). Through appropriately matching patients undergoing thrombectomy and controls by site and side of occlusion, age, and sex, the impact of selection bias was markedly reduced. In addition, the groups were well balanced for thrombolysis status, baseline ASPECTS, and timing of initial clinical presentation.

Mechanical Thrombectomy in Children

The Save ChildS Study, a large single-arm retrospective cohort study of pediatric mechanical thrombectomy, published results from 73 children across 27 centers.¹⁰ They reported favorable clinical outcomes (mRS score of 0 to 2) in 80% of patients at discharge and 86% at 6 months poststroke.¹⁰ To our knowledge, the largest cohort published ($n = 190$) was a national inpatient database analysis from the US (2010-2019) in which 55.3% of patients had favorable functional outcomes.⁸ These pediatric results are superior to those published in adult randomized trials (favorable outcomes in 46.0%).¹³

Variable selection criteria, differences in stroke etiology, enhanced neuroplasticity, and collaterals in children may account in part for this variance.^{6,8,10,12,21} However, selection bias is likely present, partly reflected in the disproportionate representation of adolescents in pediatric cohorts (42.5% to

Table 4. Technical Outcomes in the Thrombectomy Group

| Outcome | Thrombectomy group, No. (%) |
|--|-----------------------------|
| Patients, No. | 26 |
| Thrombectomy procedures, No. | 28 |
| Symptom onset in hospital | 7 (26.9) ^a |
| Time to clinical presentation, mean (range), min | |
| LSW to arrival at peripheral hospital ED (8 patients) | 247.6 (27-549) |
| LSW to arrival at pediatric/interventional hospital (21 patients) ^a | 345.9 (51-1170) |
| Peripheral hospital arrival to interventional hospital arrival (9 patients) ^a | 457.9 (95-960) |
| Time to initial angiographic imaging, mean (range), min | |
| LSW to initial angiographic imaging (CTA, MRA, or DSA) (28 episodes) | 300.9 (34-1264) |
| Initial ED arrival to initial angiographic imaging (20 episodes) | 175.4 (25-1048) |
| Inpatient LSW to initial angiographic imaging (8 episodes) | 221.9 (34-725) |
| Time to recanalization, mean (range), min (28 procedures) | |
| LSW to final recanalization | 695.0 (130-3840) |
| Initial angiographic imaging to DSA suite arrival | 318.4 (10-3105) |
| DSA suite arrival to groin puncture | 24.2 (4-62) |
| Groin puncture to final recanalization | 53.3 (5-135) |
| Time from LSW to final recanalization, time groups (n = 28 procedures) | |
| <6 h | 14 (50.0) |
| 6-12 h | 7 (25.0) |
| 12-24 h | 5 (17.9) |
| >24 h | 2 (7.1) |
| Preprocedure pediatric NIHSS score | |
| Mean (range) | 11.8 (0-22) ^b |
| Missing data, No. | 7 |
| Postprocedure pediatric NIHSS score at 24 h ^c | |
| Mean (range) | 4.6 (0-19) |
| Missing data, No. | 9 |
| Reduction in pediatric NIHSS score from prestroke to poststroke | |
| Mean (range) | 6.1 (-3 to 19) |
| Missing data, No. | 10 |
| Recanalization status (mTICI score) | |
| 0 | 0 |
| 1 | 0 |
| 2a | 3 (10.7) |
| 2b | 11 (39.3) |
| 3 | 14 (50.0) |
| Successful recanalization (mTICI score of 2b/3), No./total No. (%) | 25/28 (89.3) |
| No. of passes ^d | |
| Mean (SD) | 1.9 (1.57) |
| Median (range) | 1.0 (0-7) |
| Most successful recanalization technique | |
| Aspiration only | 3 (10.7) |
| Stent-retriever only | 6 (21.4) |
| Combined stent-retriever and aspiration | 17 (60.7) |
| Balloon angioplasty | 1 (3.6) |
| Intravenous tPA only ^d | 1 (3.6) |
| Additional flow-diverter stent placement | 2 (7.1) |

(continued)

Table 4. Technical Outcomes in the Thrombectomy Group (continued)

| Outcome | Thrombectomy group, No. (%) |
|--|-----------------------------|
| Postprocedure intracranial hemorrhage on CT or MRI | |
| Asymptomatic, petechial | 5 (19.2) |
| Asymptomatic, subarachnoid | 2 (7.7) |
| Asymptomatic, lobar | 1 (3.8) |
| Symptomatic, lobar | 1 (3.8) |
| Decompressive craniectomy | |
| For malignant edema | 4 (15.4) |
| For symptomatic lobar hemorrhage | 1 (3.8) |
| Major access site complications | |
| Retroperitoneal hemorrhage | 1 (3.8) |
| Femoral artery pseudoaneurysm | 1 (3.8) |

Abbreviations: CT, computed tomography; CTA, computed tomography angiography; DSA, digital subtraction angiography; ED, emergency department; LSW, last seen well; MRA, magnetic resonance angiography; MRI, magnetic resonance imaging; mTICI, modified Treatment in Cerebral Ischaemic; NIHSS, National Institute of Health Stroke Scale; tPA, tissue plasminogen activator.

^a Seven patients had symptomatic onset of stroke as a hospital inpatient. One patient underwent 2 thrombectomy procedures due to 2 inpatient episodes of occlusion within 96 hours in the same vessel. A second patient had initial symptom onset at home and was treated with thrombectomy but then had recurrent occlusion within 96 hours in the same vessel while an inpatient, leading to a second procedure. A third patient had symptom onset while an inpatient at a peripheral hospital, where they underwent initial angiographic imaging prior to transfer to a pediatric hospital for thrombectomy.

^b One patient who received thrombectomy had a pediatric NIHSS score of 0 at the time of final treatment decision-making. This patient had a flow-limiting dissection with adjacent thrombus in the intracranial internal carotid artery and presented with mild contralateral hemiparesis that resolved within several hours and was initially managed with heparin infusion. However, 2 additional MRI studies and a CT perfusion study performed in the next 48 hours demonstrated progressive large areas of watershed infarct developing in the ipsilateral deep white matter, and the patient described subjective episodes of receptive dysphasia at night. Based on this, it was decided to proceed to thrombectomy and flow-diverter placement, with successful recanalization at 3840 minutes since last seen well.

^c Pediatric NIHSS score at 24 hours included scores measured between 20 and 36 hours postprocedure.

^d One patient who received bridging intravenous tPA en route to the angiography suite after consenting to mechanical thrombectomy had an mTICI score of 3 and successful recanalization on the initial angiographic run and received zero passes.

76.3%).^{8-10,12} Children younger than 5 years represented less than 6% of thrombectomy cases in the US inpatient analysis discussed above, despite forming 37.5% of the overall stroke cohort.⁸

Reduced angiographic diameters²² and limited equipment choices may dampen enthusiasm for intervention in young children. However, newer low-profile distal aspiration catheters and smaller stent-retrievers are likely compatible with known angiographic diameters in toddlers and preschool children.^{22,23} In our study, children younger than 6 years represented 23.1% of both patients undergoing thrombectomy and controls. No neonates or infants were included in our study.

In the thrombectomy group, 6 of 26 patients had a baseline low ASPECTS of 1 to 5 (3 of 6 on computed tomography and 3 of 6 on DWI), of which 5 patients had a favorable final pediatric mRS score of 2 and 1 patient had a pediatric mRS score of 3. Thus, large infarct extent on baseline imaging did not necessarily portend a poor long-term clinical outcome for pediatric patients who received thrombectomy. Exclusion of pe-

diatric patients based on ASPECTS or infarct volume appears difficult to justify but warrants further research.

A total of 6 patients undergoing thrombectomy were excluded during the matching process because there were insufficient control patients with basilar artery occlusion. This may reflect a more aggressive treatment approach toward basilar occlusion. However, their exclusion limits the applicability of our results in the posterior circulation.

Natural History of Pediatric LVO Stroke

To address the shortfall in natural history data, we previously published a population-based study of pediatric patients with acute arterial ischemic stroke.⁹ In the conservatively managed cohort (26 of 39 patients), unfavorable clinical outcomes (pediatric mRS score of 3 to 6) occurred in 73.1% of patients at 3 months.⁹ This updated case-control study further confirms the poor outcomes in pediatric patients with LVO managed conservatively (mRS score of 3 to 6 in 14 [53.8%] at 3 months and 11 [42.3%] at final follow-up), even when control patients are extensively matched to patients undergoing thrombectomy. There was an overlap between the natural history and case-control studies for 12 of 26 patients undergoing thrombectomy and 14 of 26 control patients.

Timing of Clinical Presentation

In this case-control study, all 26 patients undergoing thrombectomy and 24 control patients (92.3%) presented within 24 hours since last seen well. Therefore, most patients with LVO presented early enough to be eligible for thrombectomy using adult selection criteria. In addition, 22 of 28 patients undergoing thrombectomy (78.6%) and 16 of 26 control patients (61.5%) fulfilled selection criteria (other than age) for American Heart Association class I-IIb recommendations supporting thrombectomy in adult stroke,²⁰ with most exclusions resulting from low ASPECTS. Given the strength of collaterals in children, it may not be appropriate to restrict thrombectomy access using adult timelines, and perfusion imaging may be useful in late-presenting cases.²⁴

In this study, 26 of 28 thrombectomy procedures (92.9%) were completed less than 24 hours since last seen well (Table 4). The remaining 2 patients both had flow-limiting dissections of the intracranial ICA with adjacent thrombus and were initially managed with anticoagulation prior to clinical decline. Both patients had excellent outcomes (pediatric mRS score of 0).

There was no significant difference between the thrombectomy and control groups for time since last seen well to initial clinical presentation (mean [SD] time, 157 [159] vs 226 [346] minutes; $P = .43$). However, the groups diverged for time to arrival at a dedicated pediatric hospital (mean [SD] time, 344 [400] vs 554 [655] minutes; $P = .24$) and to initial angiographic/vascular imaging (mean [SD] time, 301 [318] vs 661 [909] minutes; $P = .07$). There were nonsignificantly greater transfer and imaging delays in the control group. These results suggest that pediatric patients with LVO are presenting in appropriate time for thrombectomy (50 of 52 within 24 hours), but our triage, transfer, imaging, and decision-making pathways require streamlining. Such improvements would be aided by strengthened treatment guidelines and referral networks.

Safety Outcomes

In this study, there was no significant difference between the case and control groups for sICH or decompressive craniectomy status. There were 2 major access site complications in the thrombectomy group (1 retroperitoneal hemorrhage and 1 femoral pseudoaneurysm) that both required endovascular/percutaneous treatment. In both instances, the patients were anticoagulated for cardiac disease. Overall, the risk-benefit profile still favored thrombectomy.

Limitations

This study is impacted by several limitations. First, despite extensive matching of patients with controls, the absence of randomization leaves an ongoing degree of selection bias, such as preferential allocation of thrombectomy to patients with lower triage and transfer times. Second, conversion of PSOM to pediatric mRS scores and retrospective derivation of pediatric mRS scores from clinical records are more prone to bias. In particular, the PSOM is a summated score across 5 functional domains, with potential loss of subtle differences when converted to a single pediatric mRS score.²⁵ Third, dichotomous classification of pediatric mRS outcomes into favorable (score of 0 to 2) and unfavorable (score of 3 to 6) is not validated in children as it is in adults, and therefore ordinal regression was used for the primary analysis. There are also differing views in the literature regarding what constitutes good vs bad outcomes in children with stroke.²⁶ Fourthly, pediatric NIHSS data were not available for most control patients and as such could not be used in the matching process.

Fifthly, the dedicated modified pediatric ASPECTS (a magnetic resonance imaging-based system²⁷) was not used, as the modified system incorporates anterior cerebral artery and posterior cerebral artery territories, but none of our matched patients had anterior cerebral artery or posterior cerebral artery occlusion (all anterior circulation patients had occlusion of the internal carotid artery or middle cerebral artery). Sixthly, control patients had significantly longer final follow-up than patients undergoing thrombectomy (46.4 [29.0] vs 17.3 [15.7]; $P < .001$). Additionally, only 2 patients in each group had posterior circulation occlusions, limiting applicability of the results in this subgroup.

Most patients in this study were assessed by pediatric neurologists and treated by interventionists with pediatric experience. The superior outcomes demonstrated with thrombectomy, therefore, should not be generalized to settings without pediatric neurology expertise.²⁸ Specific subgroups that may benefit (or not benefit) from thrombectomy need to be further defined. These results may not be applicable to children younger than 2 years or with focal cerebral arteriopathy, as they were not represented in the thrombectomy cohort.

Conclusions

In the absence of a randomized trial, this case-control study demonstrates better clinical outcomes with thrombectomy than medical management for pediatric patients aged 2 to 18 years with anterior circulation LVO stroke.

ARTICLE INFORMATION

Accepted for Publication: May 12, 2023.

Published Online: July 24, 2023.
doi:10.1001/jamaneurol.2023.2303

Correction: This article was corrected on September 11, 2023, to fix Dr Parra-Farinas' surname.

Author Affiliations: Department of Medical Imaging, Children's Hospital at Westmead, Westmead, Australia (Bhatia, Goetti); Children's Hospital at Westmead Clinical School, Faculty of Medicine and Health, University of Sydney, Sydney, Australia (Bhatia, Goetti, Webster, Troedson, Dale); Division of Neurology, Department of Pediatrics, Hospital for Sick Children, Toronto, Ontario, Canada (Chowdhury, Dlamini, Moharir, Pulcine); Department of Neurology, Sydney Children's Hospital, Randwick, Australia (Andrews, Briest); T.Y. Nelson Department of Neurology and Neurosurgery, Children's Hospital at Westmead, Westmead, Australia (Webster, Troedson, Dale); Division of Image-Guided Therapy, Department of Radiology, Hospital for Sick Children, Toronto, Ontario, Canada (Muthusami, Parra-Farinas); Department of Neurology, John Hunter Children's Hospital, Newcastle, Australia (C. Miteff); Department of Neurology, John Hunter Hospital, Newcastle, Australia (F. Miteff); Department of Neurology, Royal Prince Alfred Hospital, Camperdown, Australia (Worthington, Tastula, Ang); The Neurology and Clinical Neurophysiology Department, Women's and Children's Hospital, Adelaide, Australia (Briest).

Author Contributions: Drs Bhatia and Pulcine had full access to all of the data in the study and take responsibility for the integrity of the data and the accuracy of the data analysis.

Study concept and design: Bhatia, Chowdhury, Muthusami, Moharir, Worthington, Pulcine.
Acquisition, analysis, or interpretation of data: All authors.

Drafting of the manuscript: Bhatia, Chowdhury, F. Miteff, Worthington, Ang, Briest.

Critical review of the manuscript for important intellectual content: Bhatia, Chowdhury, Andrews, Goetti, Webster, Troedson, Dale, Muthusami, Parra-Farinas, Dlamini, Moharir, C. Miteff, Tastula, Ang, Pulcine.

Statistical analysis: Bhatia, Chowdhury, Briest.
Administrative, technical, or material support: Bhatia, Chowdhury, Andrews, Dale, Muthusami, C. Miteff, F. Miteff, Worthington, Tastula, Pulcine.
Study supervision: Muthusami, Moharir, Pulcine.

Conflict of Interest Disclosures: Dr Chowdhury has received grants from The Bugher Foundation outside the submitted work. Dr Dlamini has received personal fees from Bayer Pharmaceuticals outside the submitted work. No other disclosures were reported.

Data Sharing Statement: See Supplement 2.

REFERENCES

- Berkhemer OA, Fransen PS, Beumer D, et al; MR CLEAN Investigators. A randomized trial of intraarterial treatment for acute ischemic stroke. *N Engl J Med*. 2015;372(1):11-20. doi:10.1056/NEJMoa1411587
- Goyal M, Demchuk AM, Menon BK, et al; ESCAPE Trial Investigators. Randomized assessment of rapid endovascular treatment of ischemic stroke. *N Engl J Med*. 2015;372(11):1019-1030. doi:10.1056/NEJMoa1414905
- Jovin TG, Chamorro A, Cobo E, et al; REVASCAT Trial Investigators. Thrombectomy within 8 hours after symptom onset in ischemic stroke. *N Engl J Med*. 2015;372(24):2296-2306. doi:10.1056/NEJMoa1503780
- Saver JL, Goyal M, Bonafe A, et al; SWIFT PRIME Investigators. Stent-retriever thrombectomy after intravenous t-PA vs. t-PA alone in stroke. *N Engl J Med*. 2015;372(24):2285-2295. doi:10.1056/NEJMoa1415061
- Campbell BC, Mitchell PJ, Kleinig TJ, et al; EXTEND-IA Investigators. Endovascular therapy for ischemic stroke with perfusion-imaging selection. *N Engl J Med*. 2015;372(11):1009-1018. doi:10.1056/NEJMoa1414792
- Ferriero DM, Fullerton HJ, Bernard TJ, et al; American Heart Association Stroke Council and Council on Cardiovascular and Stroke Nursing. Management of stroke in neonates and children: a scientific statement from the American Heart Association/American Stroke Association. *Stroke*. 2019;50(3):e51-e96. doi:10.1161/STR.000000000000183
- Medley TL, Miteff C, Andrews I, et al. Australian Clinical Consensus Guideline: the diagnosis and acute management of childhood stroke. *Int J Stroke*. 2019;14(1):94-106. doi:10.1177/1747493018799958
- Dicpinigaitis AJ, Gandhi CD, Pisapia J, et al. Endovascular thrombectomy for pediatric acute ischemic stroke. *Stroke*. 2022;53(5):1530-1539. doi:10.1161/STROKEAHA.121.036361
- Bhatia KD, Briest R, Goetti R, et al. Incidence and natural history of pediatric large vessel occlusion stroke: a population study. *JAMA Neurol*. 2022;79(5):488-497. doi:10.1001/jamaneurol.2022.0323
- Sporns PB, Sträter R, Minnerup J, et al. Feasibility, safety, and outcome of endovascular recanalization in childhood stroke: the Save ChildS study. *JAMA Neurol*. 2020;77(1):25-34. doi:10.1001/jamaneurol.2019.3403
- Shoirah H, Shallwani H, Siddiqui AH, et al. Endovascular thrombectomy in pediatric patients with large vessel occlusion. *J Neurointerv Surg*. 2019;11(7):729-732. doi:10.1136/neurintsurg-2018-014320
- Kossorotoff M, Kerleroux B, Boulouis G, et al; KidClot Group. Recanalization treatments for pediatric acute ischemic stroke in France. *JAMA Netw Open*. 2022;5(9):e2231343. doi:10.1001/jamanetworkopen.2022.31343
- Goyal M, Menon BK, van Zwam WH, et al; HERMES collaborators. Endovascular thrombectomy after large-vessel ischaemic stroke: a meta-analysis of individual patient data from five randomised trials. *Lancet*. 2016;387(10029):1723-1731. doi:10.1016/S0140-6736(16)00163-X
- Rivkin MJ, deVeber G, Ichord RN, et al. Thrombolysis in pediatric stroke study. *Stroke*. 2015;46(3):880-885. doi:10.1161/STROKEAHA.114.008210
- Bigi S, Fischer U, Wehrli E, et al. Acute ischemic stroke in children versus young adults. *Ann Neurol*. 2011;70(2):245-254. doi:10.1002/ana.22427
- Hacke W, Kaste M, Bluhmki E, et al; ECASS Investigators. Thrombolysis with alteplase 3 to 4.5 hours after acute ischemic stroke. *N Engl J Med*. 2008;359(13):1317-1329. doi:10.1056/NEJMoa0804656
- Barber PA, Demchuk AM, Zhang J, Buchan AM. Validity and reliability of a quantitative computed tomography score in predicting outcome of hyperacute stroke before thrombolytic therapy. ASPECTS Study Group. Alberta Stroke Programme Early CT Score. *Lancet*. 2000;355(9216):1670-1674. doi:10.1016/S0140-6736(00)02237-6
- Barber PA, Hill MD, Eliasziw M, et al; ASPECTS Study Group. Imaging of the brain in acute ischaemic stroke: comparison of computed tomography and magnetic resonance diffusion-weighted imaging. *J Neurol Neurosurg Psychiatry*. 2005;76(11):1528-1533. doi:10.1136/jnnp.2004.059261
- Nogueira RG, Jadhav AP, Haussen DC, et al; DAWN Trial Investigators. Thrombectomy 6 to 24 hours after stroke with a mismatch between deficit and infarct. *N Engl J Med*. 2018;378(1):1-21. doi:10.1056/NEJMoa1706442
- Powers WJ, Rabinstein AA, Ackerson T, et al. Guidelines for the early management of patients with acute ischemic stroke: 2019 update to the 2018 guidelines for the early management of acute ischemic stroke: a guideline for healthcare professionals from the American Heart Association/American Stroke Association. *Stroke*. 2019;50(12):e344-e418. doi:10.1161/STR.0000000000000211
- Bhatia K, Kortman H, Blair C, et al. Mechanical thrombectomy in pediatric stroke: systematic review, individual patient data meta-analysis, and case series. *J Neurosurg Pediatr*. Published online August 9, 2019. doi:10.3171/2019.5.PEDS19126
- He L, Ladner TR, Pruthi S, et al. Rule of 5: angiographic diameters of cervicocerebral arteries in children and compatibility with adult neurointerventional devices. *J Neurointerv Surg*. 2016;8(10):1067-1071. doi:10.1136/neurintsurg-2015-012034
- Haussen DC, Eby B, Al-Bayati AR, et al. A comparative analysis of 3MAX aspiration versus 3 mm Trevo Retriever for distal occlusion thrombectomy in acute stroke. *J Neurointerv Surg*. 2020;12(3):279-282. doi:10.1136/neurintsurg-2019-014990
- Lee S, Mlynash M, Christensen S, et al. Hyperacute perfusion imaging before pediatric thrombectomy: analysis of the Save ChildS study. *Neurology*. 2023;100(11):e1148-e1158. doi:10.1212/WNL.000000000000201687
- Kitchen L, Westmacott R, Friefeld S, et al. The Pediatric Stroke Outcome Measure: a validation and reliability study. *Stroke*. 2012;43(6):1602-1608. doi:10.1161/STROKEAHA.111.639583
- Slim M, Fox CK, Friefeld S, et al; SIPS Investigators. Validation of the Pediatric Stroke Outcome Measure for classifying overall neurological deficit. *Pediatr Res*. 2020;88(2):234-242. doi:10.1038/s41390-020-0842-5
- Beslow LA, Vossough A, Ichord RN, et al. Association of pediatric ASPECTS and NIH Stroke Scale, hemorrhagic transformation, and 12-month outcome in children with acute ischemic stroke. *Neurology*. Published online August 13, 2021. doi:10.1212/WNL.00000000000012558
- Roach ES, Bernard T, deVeber G. Defining a pediatric stroke center. *Pediatr Neurol*. 2020;112:11-13. doi:10.1016/j.pediatrneurol.2020.08.008

Incidence and Natural History of Pediatric Large Vessel Occlusion Stroke

A Population Study

Kartik D. Bhatia, MBBS, PhD; Romain Briest, MBBS; Robert Goetti, MBBS; Richard Webster, MBBS; Christopher Troedson, MBBS; Russell C. Dale, MBBS, PhD; Prakash Muthusami, MD; Christina Miteff, MBBS; Ferdinand Miteff, MBBS; John Worthington, MBBS; Kylie Tastula, RN; Timothy Ang, MBBS; Ian Andrews, MBBS

 Supplemental content

IMPORTANCE The incidence and natural history of large vessel occlusion (LVO) stroke in children is largely unknown. These knowledge gaps limit the uptake of reperfusion therapies and reduce the efficiency of pediatric acute stroke pathways.

OBJECTIVE To determine the incidence and natural history of pediatric LVO stroke.

DESIGN, SETTING, AND PARTICIPANTS This retrospective population-based cohort study was conducted between January 2010 and December 2019, with a mean (SD) follow-up of 37.0 (28.8) months. Admissions from all pediatric hospitals in the state of New South Wales, Australia, with a final diagnosis of arterial ischemic stroke (AIS) in patients 1 month to younger than 17 years were included. A total of 85 of 251 identified cases were excluded based on selection criteria. Data were analyzed from July 2020 to June 2021.

EXPOSURES One-third of patients with LVO received mechanical thrombectomy with or without intravenous thrombolysis while the remainder were treated conservatively.

MAIN OUTCOMES AND MEASURES The primary outcome was the pediatric modified Rankin Scale (ped-mRS) score 3 months after stroke. Ordinal logistic regression was used to compare non-LVO, LVO without thrombectomy, and LVO with thrombectomy groups.

RESULTS Of 161 included patients, 56 (34.8%) were female, and the mean (SD) age was 6.1 (5.4) years. A total of 166 AIS admissions were studied, and clinical follow-up was available for 164 of 166 admissions. LVO was present in 39 admissions (23.5%). The incidence of LVO stroke was 0.24 per 100 000 patients per year (95% CI, 0.13-0.35). Patients with LVO who did not receive thrombectomy ($n = 26$) had poor neurological outcomes, with 19 (73.1%) experiencing moderate to severe disability or death (ped-mRS score of 3 to 6) at 3 months (6 of 12 patients receiving thrombectomy [50.0%]; 25 of 38 patients with LVO [65.8%]). Patients with LVO without thrombectomy had significantly worse clinical outcomes than patients with non-LVO at 3 months (odds ratio, 3.64; 95% CI, 1.68-7.87; $P = .001$). Most patients with LVO presented within time windows suitable for thrombectomy (27 of 39 [69.2%] within 6 hours; 35 of 39 [89.7%] within 24 hours).

CONCLUSIONS AND RELEVANCE In this population-based cohort study, the natural history of pediatric patients with LVO stroke treated conservatively was poor, with most experiencing lifelong disability or death. Nearly 90% of pediatric patients with LVO presented within time windows suitable for thrombectomy.

Author Affiliations: Author affiliations are listed at the end of this article.

Corresponding Author: Kartik D. Bhatia, MBBS, PhD, Department of Medical Imaging, Children's Hospital at Westmead, Cnr Hainsworth Street and Hawkesbury Road, Westmead, NSW 2145, Australia (kartik.bhatia@health.nsw.gov.au).

JAMA Neurol. 2022;79(5):488-497. doi:10.1001/jamaneurol.2022.0323
Published online March 28, 2022.

Large vessel occlusion (LVO) causes approximately one-quarter of arterial ischemic stroke (AIS) presentations in adults¹ and has worse long-term outcomes than non-LVO stroke.² Five randomized clinical trials showed mechanical thrombectomy within 6 to 8 hours since last seen well improved outcome compared with standard medical therapy in those with anterior circulation LVO.³⁻⁹ The time window of benefit was extended to 16 and then 24 hours by 2 additional trials in selected adult patients.^{10,11}

Children and adolescents were not included in those trials, and to our knowledge, there are no randomized clinical trials for mechanical thrombectomy or any acute therapies for pediatric AIS. Evidence for thrombectomy in children is predominantly from studies that are retrospective and single arm and have small sample sizes.¹² A recent larger retrospective multicenter cohort study assessing outcomes following thrombectomy in 73 children reported favorable long-term outcomes, with a median modified Rankin Scale (mRS) score of 1.0.¹³ Current guidelines for treatment of LVO stroke in children make only cautious recommendations on its use,^{14,15} although recent literature suggests increasing uptake of thrombectomy.^{12,13}

Absence of population data regarding the natural history of LVO stroke in children has hindered confident interpretation of the existing pediatric data. Randomizing pediatric patients to noninterventional treatment would be unethical given the benefit in adults (number needed to treat of 2.6).⁸ In addition, such a trial would likely not be feasible, as observed in attempts to undertake a trial for intravenous (IV) thrombolysis in children.¹⁶ Further limitations on the uptake of reperfusion therapies include absence of LVO stroke incidence data in children,¹² slow triage and imaging pathways,¹⁷ and historic beliefs that children with LVO present too late for reperfusion and have better outcomes than adults when treated conservatively.^{18,19} Addressing these evidence gaps may support resource allocation and facilitate formation of stronger, evidence-based guidelines for pediatric stroke.

In this study, we aim to address the following gaps in knowledge: (1) the annual incidence of pediatric LVO stroke; (2) the proportion of pediatric AIS cases caused by LVO; (3) the proportion of pediatric LVO cases that would fulfill adult selection criteria for mechanical thrombectomy (other than age); and (4) the long-term clinical outcomes of pediatric LVO stroke without thrombectomy.

Methods

Study Design

Ethics approval was granted by the Sydney Children's Hospital Network Human Research Ethics Committee, including a waiver for consent. The design was a multicenter retrospective cohort study of all pediatric patients (1 month to younger than 17 years) with acute AIS across the state of New South Wales (NSW), Australia, covering the 10 years from January 1, 2010, to December 31, 2019. Four centers were included: all 3 pediatric hospitals in NSW and an adult comprehensive stroke center that provides thrombectomy to older adolescents. This

Key Points

Question What is the incidence and natural history of arterial ischemic stroke due to large vessel occlusion in the pediatric population?

Findings In this cohort study that included 166 admissions for pediatric arterial ischemic stroke, 39 (23.5%) had a large vessel occlusion. The incidence of pediatric large vessel occlusion stroke was 0.24 per 100 000 children per year, and patients with large vessel occlusion who were treated conservatively had poor neurological outcomes, with 19 (73.1%) experiencing moderate to severe disability or death at 3 months.

Meaning In this study, the natural history of large vessel occlusion stroke in children was poor when treated conservatively, contrary to historic beliefs.

study followed the Strengthening the Reporting of Observational Studies in Epidemiology (STROBE) reporting guideline.

Three centers had existing prospective databases for AIS, while the fourth center required creation of a retrospective database using diagnostic coding from which AIS cases were identified. Clinical and imaging records were then assessed for the inclusion and exclusion criteria to confirm the case. The presence of AIS was based on the final clinical diagnosis made by the treating pediatric neurologist.

Inclusion Criteria

Inclusion criteria were age 1 month to younger than 17 years on the date of initial assessment, admission, or follow-up at one of the 4 involved centers between January 2010 and December 2019, and *International Statistical Classification of Diseases and Related Health Problems, Tenth Revision (ICD-10)* diagnostic codes of I63 (cerebral infarction), I65 (occlusion and stenosis of precerebral arteries, not resulting in cerebral infarction), or I66 (occlusion and stenosis of cerebral arteries, not resulting in cerebral infarction).

Exclusion Criteria

The following patient groups were excluded because they have markedly different etiologies, presentations, treatments, and outcomes: those with hemorrhagic stroke, neonatal stroke (younger than 29 days) (n = 35); those with cerebral venous sinus thrombosis (n = 9); those with group B *Streptococcal* meningitis-related stroke (n = 7); those with herniation syndromes from traumatic brain injury resulting in stroke (n = 8); and those with global hypoxic-ischemic injury (eg, cardiac arrest, drowning) (n = 26). Clinical and imaging records of patients identified with *ICD-10* diagnostic codes I65 and I66 were assessed for evidence of infarction; in the absence of infarction or reperfusion therapy, these patients were excluded. Patients 17 years and older were excluded because a substantial proportion were treated at adult hospitals.

Definition of LVO

For this study, LVO was defined as acute occlusion of the intracranial segments of the internal carotid artery (ICA), M1 (first) or M2 (second) segments of the middle cerebral artery, A1 or

A2 segments of the anterior cerebral artery (ACA), intracranial segment of the vertebral artery, basilar artery, and P1 or P2 segments of the posterior cerebral artery (PCA), as demonstrated on computed tomography angiography (CTA), magnetic resonance angiography (MRA), or digital subtraction angiography (DSA). Acute vs chronic occlusion was differentiated based on presence or absence of well-developed lenticulostriate or transdural collaterals.

This definition as it applies to the anterior circulation is derived from the first and largest positive randomized clinical trial for mechanical thrombectomy in AIS (Multicenter Randomized Clinical Trial of Endovascular Treatment for Acute Ischemic Stroke in the Netherlands [MR CLEAN] trial: ICA, M1, M2, A1, A2),³ supported by Class I (ICA, M1) and Class IIb (ACA, M2) recommendations for mechanical thrombectomy in adults from the American Heart Association (AHA).^{3,9} For the posterior circulation, it is based on AHA Class IIb recommendations in adults.⁹

Epidemiological Data Collection

The population of persons younger than 17 years in NSW as estimated in June of each year from 2010 to 2019 by the Australian Bureau of Statistics was used to determine the state pediatric population.²⁰ The annual and mean incidence rates measured in cases per 100 000 persons younger than 17 per year were calculated for pediatric patients with AIS and LVO.

Outcome Measures and Analyses

The primary outcome was the functional clinical outcome 3 months after stroke onset measured using the pediatric mRS (ped-mRS) score. The primary analysis compared patients with LVO who did not undergo mechanical thrombectomy and/or IV thrombolysis with patients with non-LVO. Ped-mRS score was assessed retrospectively by a pediatric neurologist or pediatric interventional neuroradiologist based on prior assessments undertaken by a pediatric neurologist, neurosurgeon, or rehabilitation physician 2 to 4 months after AIS. Ped-mRS scores were able to be derived from the clinical records in 164 of 166 admissions (98.8%). The primary safety outcome was the rate of symptomatic intracranial hemorrhage.

Selection of patients with LVO to receive reperfusion therapy was not randomized or based on standardized selection criteria but rather was determined by the treating pediatric neurologist in the context of the clinical presentation and resource availability. The study period extended before and after mechanical thrombectomy became widely used in adults (2015 onwards), affecting patient selection. An a priori decision was thus made to make the primary analysis a comparison of the LVO without thrombectomy and non-LVO groups.

Secondary outcomes were final ped-mRS score available (including timing), stroke etiology, method of initial angiographic imaging (CTA, MRA, or DSA), timing of imaging (hours since last seen well), timing of clinical presentation (less than 6, 6 to 24, 24 to 48, or more than 48 hours since last seen well), IV thrombolysis status, mechanical thrombectomy status, and selection criteria fulfillment status (other than age) for the MR CLEAN trial,³ DWI or CTP Assessment with Clinical Mismatch in the Triage of Wake-Up and Late Presenting Strokes Under-

going Neurointervention with Trevo (DAWN) trial,¹¹ and AHA Class I-IIb recommendations⁹ for use of thrombectomy in adults. Note that the MR CLEAN trial³ included only patients with anterior circulation stroke presenting within 6 hours since last seen well, and for the DAWN trial,¹¹ within 6 to 24 hours since last seen well. These criteria are detailed in eMethods 1 and 2 in the Supplement. Secondary analyses included comparison of ped-mRS scores between patients with LVO with and without thrombectomy, and dichotomous assessment of 3-month and final ped-mRS scores classified into favorable outcome (ped-mRS score of 0 to 2) or poor outcome (ped-mRS score of 3 to 6).

Imaging Analysis

All available CTA, MRA, and DSA studies for patients with AIS were analyzed independently by a pediatric interventional neuroradiologist (K.D.B.) for the presence of LVO. Imaging for all LVO cases was further independently assessed by 2 pediatric neuroradiologists at separate centers, blinded to the clinical presentation and outcome (R.G. and P.M.). Assessors recorded the presence, side, and location of the primary (most proximal) intracranial occlusion.

Statistical Analysis

The primary analysis was assessed by ordinal logistic regression using MiniTab version 19.2020.2.0 (MiniTab LLC) to determine the odds ratio (OR) and *P* value for a worse outcome on the ped-mRS score (ie, higher score on the scale from 0 to 6) comparing patients with non-LVO, LVO without thrombectomy, and LVO with thrombectomy. For secondary analyses, ped-mRS score data were compared using ordinal logistic regression, dichotomous variables using the χ^2 test, and continuous variables using the unpaired *t* test. Confounders contributing to selection for thrombectomy were analyzed using binary logistic regression. Complete-case analysis was used to account for missing data. All *P* values were 2-tailed, and significance was set at *P* < .05.

Results

From January 2010 to December 2019, 166 AIS admissions in 161 pediatric patients were identified in NSW. Of 161 included patients, 56 (34.8%) were female, and the mean (SD) age was 6.1 (5.4) years. A total of 166 AIS admissions were studied, and clinical follow-up was available for 164 of 166 admissions. Demographic characteristics, etiology, and timing of presentation are reported in **Table 1**.

LVO Status and Imaging

LVO was present in 39 of 166 admissions (23.5%). Initial angiographic imaging was available in 36 of 39 patients with LVO, with 100% agreement of occlusion location between blinded assessors. Follow-up imaging was available for the remaining 3 cases, all demonstrating territorial infarcts consistent with previous LVO. Imaging results are reported in **Table 2**.

A total of 13 patients (33.3%) underwent mechanical thrombectomy (10 underwent thrombectomy alone; 3 underwent

Table 1. Demographic Characteristics, Timing of Presentation, and Etiology

| Characteristic | No. (%) | | | P value, non-LVO vs LVO |
|--|----------------|-----------------|----------------|-------------------------|
| | AIS | Non-LVO | LVO | |
| Admissions | 166 (100) | 127 (76.5) | 39 (23.5) | NA |
| Patients | 161 (100) | 122 (75.8) | 39 (24.2) | NA |
| Age, y | | | | |
| Mean (SD) | 6.1 (5.4) | 5.5 (5.2) | 8.2 (5.5) | .007 ^a |
| Median (IQR) | 5.9 (1.0-11.5) | 4.0 (0.95-10.0) | 8.0 (3.0-13.0) | |
| Sex | | | | |
| Female | 56 (34.8) | 40 (32.8) | 16 (41.0) | |
| Male | 105 (65.2) | 82 (67.2) | 23 (59.0) | |
| Intravenous thrombolysis, No. | 4 | 1 | 3 | .35 ^b |
| Mechanical thrombectomy, No. | 13 | 0 | 13 | |
| Timing of clinical presentation since last seen well, h | | | | |
| <6 | 71 (42.8) | 44 (34.6) | 27 (69.2) | <.001 ^b |
| 6-24 | 56 (33.7) | 48 (37.8) | 8 (20.5) | |
| 24-48 | 13 (7.8) | 11 (8.7) | 2 (5.1) | |
| >48 | 26 (15.7) | 24 (18.9) | 2 (5.1) | |
| Total <24 h | 127 (76.5) | 92 (72.4) | 35 (89.7) | |
| Fulfilled adult selection criteria for mechanical thrombectomy | | | | |
| MR CLEAN trial ³ | NA | NA | 20 (51.3) | |
| DAWN trial ¹¹ | NA | NA | 7 (17.9) | |
| Posterior circulation ⁹ | NA | NA | 5 (12.8) | |
| Total | NA | NA | 32 (82.1) | |
| Stroke etiology | | | | |
| Cardioembolic | 46 (27.7) | 34 (26.8) | 12 (30.8) | .02 ^b |
| Dissection | 17 (10.2) | 9 (7.1) | 8 (20.5) | |
| Focal cerebral arteriopathy | 8 (4.8) | 4 (3.1) | 4 (10.3) | |
| Hypercoagulable | 3 (1.8) | 0 | 3 (7.7) | |
| Iatrogenic | 23 (13.9) | 20 (15.7) | 3 (7.7) | |
| Idiopathic | 32 (19.3) | 26 (20.5) | 6 (15.4) | |
| Moyamoya | 9 (5.4) | 9 (7.1) | 0 | |
| Other | 12 (7.2) | 11 (8.7) | 1 (2.6) | |
| Paradoxical embolus | 5 (3.0) | 3 (2.4) | 2 (5.1) | |
| Traumatic vasculopathy | 4 (2.4) | 4 (3.1) | 0 | |
| Vasculitis | 7 (4.2) | 7 (5.5) | 0 | |

Abbreviations: AIS, arterial ischemic stroke; DAWN, DWI or CTP Assessment With Clinical Mismatch in the Triage of Wake-up and Late Presenting Strokes Undergoing Neurointervention With Trevo; LVO, large vessel occlusion; MR CLEAN, Multicenter Randomized Clinical Trial of Endovascular Treatment for Acute Ischemic Stroke in the Netherlands; NA, not applicable.

^a t Test.

^b χ^2 Test.

thrombectomy and IV thrombolysis), and 26 patients (66.7%) did not (ie, conservative treatment). Patients with LVO were older than patients with non-LVO (mean [SD] age, 8.23 [5.45] years vs 5.48 [5.23] years; $P = .007$). Patients with LVO undergoing thrombectomy were older than conservatively treated patients (mean [SD; range] age, 12.41 [4.41; 4.0-16.9] years vs 6.23 [4.73; 0.4-14.5] years; $P < .001$).

Incidence of Pediatric AIS and LVO

Across the 10-year period, the mean (SD) annual incidence of pediatric (ie, younger than 17 years) AIS was 1.02 (0.18) cases per 100 000 persons per year (95% CI, 0.89-1.16). The mean (SD) annual incidence of acute pediatric LVO was 0.24 (0.15) cases per 100 000 persons per year (95% CI, 0.13-0.35). Annual estimated incidence data are reported in the eTable in the Supplement.

Primary Outcome

At 3 months following stroke, ped-mRS score was 3 to 6 in 19 of 26 patients with LVO without thrombectomy (73.1%), 6 of 12 with LVO with thrombectomy (50.0%), and 52 of 126 with non-LVO (41.2%) (Table 3). A total of 24 of 26 cases involved the anterior circulation, of which 18 patients (75%) had a poor outcome at 3 months. Patients with LVO without thrombectomy had significantly worse outcomes than patients with non-LVO on the ped-mRS 3 months after stroke using ordinal logistic regression analysis (OR, 3.64; 95% CI, 1.68-7.87; $P = .001$) (Table 3).

Secondary Outcomes

Patients with LVO without thrombectomy also had significantly worse outcomes than patients with non-LVO on final available ped-mRS assessment (mean [SD] time from stroke,

Table 2. Angiographic Imaging Modality, Timing, and Occlusion Location

| Characteristic | No. (%) | | | P value, non-LVO vs LVO |
|---|-----------------|------------------|----------------|-------------------------|
| | AIS | Non-LVO | LVO | |
| Admissions, No. | 166 | 127 | 39 | NA |
| Initial imaging modality | | | | |
| CTA | 38 (22.9) | 15 (11.8) | 23 (59.0) | <.001 ^a |
| MRA | 128 (77.1) | 112 (88.2) | 16 (41.0) | |
| Time to angiographic imaging since last seen well, h ^b | | | | |
| Mean (SD) | 39.1 (52.8) | 46.7 (57.7) | 14.4 (15.8) | <.001 ^c |
| Median (IQR) | 20.0 (8.0-48.0) | 22.0 (11.0-63.0) | 7.5 (4.0-21.0) | |
| Occlusion location | | | | |
| Intracranial ICA | NA | NA | 14 (35.9) | NA |
| MCA | | | | |
| M1 segment | NA | NA | 12 (30.8) | NA |
| M2 segment | NA | NA | 7 (17.9) | NA |
| ACA | | | | |
| A1 segment | NA | NA | 0 | NA |
| A2 segment | NA | NA | 1 (2.6) | NA |
| Anterior circulation, total | NA | NA | 34 (87.2) | NA |
| Intracranial vertebral artery | NA | NA | 1 (2.6) | NA |
| Basilar artery | NA | NA | 3 (7.7) | NA |
| PCA | | | | |
| P1 segment | NA | NA | 1 (2.6) | NA |
| P2 segment | NA | NA | 0 | NA |
| Posterior circulation - total | NA | NA | 5 (12.8) | NA |

Abbreviations: ACA, anterior cerebral artery; AIS, arterial ischemic stroke; CTA, computed tomography angiography; DSA, digital subtraction angiography; ICA, internal carotid artery; LVO, large vessel occlusion; MCA, middle cerebral artery; MRA, magnetic resonance angiography; NA, not applicable; PCA, posterior cerebral artery.

^a χ^2 Test.

^b Time in hours since last seen well until first diagnostic angiographic imaging was performed (CTA, MRA, or DSA).

^c t Test.

37.0 [28.8] months; OR, 3.23; 95% CI, 1.50-6.95; $P = .003$) (Table 4). Dichotomous analysis results comparing ped-mRS scores of 0 to 2 vs 3 to 6 between groups were also significantly worse for patients with LVO without thrombectomy than for patients with non-LVO at 3 months ($\chi^2_2 = 8.803$; $P = .01$) and final assessment ($\chi^2_2 = 7.695$; $P = .02$).

Patients with LVO without thrombectomy had significantly worse outcomes than those treated with thrombectomy at (3 months: OR, 3.75; 95% CI, 1.05-13.45; $P = .04$; final assessment: OR, 6.07; 95% CI, 1.55-23.73; $P = .01$). These worse outcomes were more pronounced in the anterior circulation subgroup (Table 5).

Safety Outcomes

Among 13 patients undergoing thrombectomy, there were no occurrences of symptomatic intracranial hemorrhage. One patient had a retroperitoneal hemorrhage from the access site (treated with a covered stent) (Table 5). Two patients with dissection and 1 with focal cerebral arteriopathy were treated with thrombectomy, with no procedural complications.

Timing of Presentation and Eligibility for Thrombectomy

Patients with LVO presented more quickly than patients with non-LVO (Table 1). Most with LVO (27 of 39 [69.2%]) presented to the hospital within 6 hours since last seen well and 35 of 39 (90%) presented within 24 hours. Selection criteria other than age for the MR CLEAN trial³ were fulfilled in 20 of 39 patients (51.3%) and the DAWN trial¹¹ in an additional 7 patients (17.9%). If posterior circulation occlusions are included

(AHA Class IIb recommendations⁹), then 32 of 39 patients (82.1%) were potentially eligible. Binary logistic regression analysis of potential confounders (age, sex, timing of imaging, year, site of occlusion) only identified age (OR, 1.31; 95% CI, 1.06-1.61; $P = .01$) as a significant predictor that patients with LVO underwent thrombectomy.

Discussion

The Natural History of Pediatric LVO Stroke

In our study, outcomes for pediatric LVO stroke treated conservatively were poor. Moderate to severe disability or death (ped-mRS score of 3 to 6) was present in 19 of 26 (73.1%) at 3 months (75% of anterior circulation LVO cases). The HERMES collaboration,⁸ which pooled data from 5 randomized trials on thrombectomy for anterior circulation LVO in adults, found 73.5% of control patients had a poor outcome (mRS score of 3 to 6) at 3 months—remarkably similar to the rate we identified in children (75%). In their interventional group, 54.0% had a poor outcome, and the OR of a favorable outcome following thrombectomy was 2.35.⁸ These results indicate children with LVO stroke treated conservatively have similarly poor outcomes to adults with LVO and worse outcomes than adult patients undergoing thrombectomy.

With only 5 posterior circulation strokes due to LVO, we have insufficient data to comment on this cohort. A recent literature review of pediatric basilar artery occlusion, however, reported poor long-term neurological outcomes in patients

Table 3. Clinical Outcomes at 3 Months After Stroke (Primary Outcome)

| Outcomes | No. (%) | | | | | OR (95% CI) | P value |
|--|-----------|-----------|-----------|-----------------|--------------|-------------------|---------|
| | AIS | Non-LVO | LVO | | | | |
| | | | All | No thrombectomy | Thrombectomy | | |
| ped-mRS score at 3 mo, No. | | | | | | | |
| 0 | 21 | 19 | 2 | 0 | 2 | NA | NA |
| 1 | 30 | 26 | 4 | 1 | 3 | NA | NA |
| 2 | 36 | 29 | 7 | 6 | 1 | NA | NA |
| 3 | 39 | 29 | 10 | 7 | 3 | NA | NA |
| 4 | 25 | 14 | 11 | 9 | 2 | NA | NA |
| 5 | 3 | 1 | 2 | 2 | 0 | NA | NA |
| 6 | 10 | 8 | 2 | 1 | 1 | NA | NA |
| Total | 164 | 126 | 38 | 26 | 12 | NA | NA |
| Data missing | 2 | 1 | 1 | 0 | 1 | NA | NA |
| Anterior circulation | NA | NA | 33 | 24 | 9 | NA | NA |
| Ordinal logistic regression analysis: OR of a worse functional outcome at 3 mo | | | | | | | |
| LVO with no thrombectomy vs non-LVO ^a | NA | NA | NA | NA | NA | 3.64 (1.68-7.87) | .001 |
| LVO with thrombectomy vs non-LVO ^a | NA | NA | NA | NA | NA | 1.13 (0.30-3.22) | .82 |
| LVO with no thrombectomy vs LVO with thrombectomy ^b | NA | NA | NA | NA | NA | 3.75 (1.05-13.45) | .04 |
| LVO with no thrombectomy (anterior circulation) vs LVO with thrombectomy (anterior circulation) ^b | NA | NA | NA | NA | NA | 7.14 (1.59-23.10) | .01 |
| Dichotomous analysis ^c | | | | | | | |
| ped-mRS score | NA | NA | NA | NA | NA | | |
| 0-2 | 87 (53.0) | 74 (58.7) | 13 (34.2) | 7 (26.9) | 6 (50.0) | χ^2 , 8.803 | .01 |
| 3-6 | 77 (47.0) | 52 (41.2) | 25 (65.8) | 19 (73.1) | 6 (50.0) | | |
| 0-2 (anterior circulation) | NA | NA | 11 (33.3) | 6 (25.0) | 5 (55.6) | NA | NA |
| 3-6 (anterior circulation) | NA | NA | 22 (66.7) | 18 (75.0) | 4 (44.4) | | |

Abbreviations: AIS, arterial ischemic stroke; LVO, large vessel occlusion; NA, not applicable; OR, odds ratio; ped-mRS, pediatric modified Rankin Scale.

^a Primary analysis performed with ordinal logistic regression comparing ped-mRS score at 3 months after stroke between 3 groups: non-LVO, LVO with no thrombectomy, and LVO with thrombectomy. Non-LVO was the reference group. OR of a worse functional outcome (higher score on the ped-mRS scale from 0 to 6) compared with the non-LVO group was determined.

^b Secondary analysis performed with ordinal logistic regression comparing ped-mRS score at final available assessment after stroke between patients with LVO with thrombectomy and patients with LVO with no thrombectomy.

LVO with no thrombectomy was the reference group. OR of a worse functional outcome (higher score on the ped-mRS scale from 0 to 6) comparing LVO with no thrombectomy with the LVO with thrombectomy group was determined. Subgroup analysis was performed using the same method but including only individuals with anterior circulation (34 of 39 patients with LVO and 9 of 13 with thrombectomy and data available; 24 without thrombectomy).

^c Secondary dichotomous analysis performed using Pearson χ^2 test for favorable (ped-mRS score of 0 to 2) vs poor (ped-mRS score of 3 to 6) clinical outcomes 3 months after stroke between 3 groups: non-LVO, LVO with no thrombectomy, and LVO with thrombectomy groups.

treated conservatively (n = 111), with moderate to severe disability or death in 58%.²¹

Our natural history cohort consists of patients not treated with thrombectomy or IV thrombolysis. This group may have had a worse baseline prognosis, and their outcomes may be affected by selection bias. However, 73% of patients with LVO without thrombectomy fulfilled adult selection criteria for thrombectomy, patients were included from before (2010 to 2014) and after (2015 to 2019) the publication of positive adult trials, and uptake of thrombectomy in children was variable until recently.

Previous studies assessing outcomes from pediatric AIS did not analyze patients by LVO status.^{15,22,23} Pooling of patients with LVO among all stroke cases allowed for a potential underestimate of LVO stroke severity. Pediatric patients with LVO (Table 1) have differing stroke etiology to patients with non-LVO, with higher proportions of cardioembolic, dissection, and focal cerebral arteriopathy cases. However, dem-

onstration of worse outcomes for adult patients with LVO^{1,2} was a major impetus for the thrombectomy trials.^{3,8} Demonstration of worse outcomes in children with LVO is important to distinguish an identifiable subgroup with poor outcomes when treated conservatively.

Evidence for Mechanical Thrombectomy in Children

In our study, patients with LVO treated conservatively had significantly worse functional outcomes than patients undergoing thrombectomy (final assessment: OR, 6.07; 95% CI, 1.55-23.73; $P = .01$). However, the sample size is small, and these patients were older than those in the conservatively treated group. Therefore, these results should be interpreted with caution.

A retrospective single-arm cohort study of pediatric patients who underwent thrombectomy (n = 73) demonstrated favorable neurological outcomes, with 87% having an mRS score of 0 to 2 at 6 months.¹³ Symptomatic intracranial hem-

Table 4. Clinical Outcomes at Final Available Assessment After Stroke (Secondary Outcome)

| Outcome | No. (%) | | | | | OR (95% CI) | P value |
|--|------------------|------------------|-------------------|------------------|-------------------|-------------------|---------|
| | AIS | Non-LVO | LVO | | | | |
| | | | All | No thrombectomy | Thrombectomy | | |
| ped-mRS Score at final available assessment, No. | | | | | | | |
| 0 | 33 | 29 | 4 | 0 | 4 | NA | NA |
| 1 | 32 | 29 | 3 | 1 | 2 | NA | NA |
| 2 | 43 | 31 | 12 | 10 | 2 | NA | NA |
| 3 | 31 | 18 | 13 | 10 | 3 | NA | NA |
| 4 | 4 | 2 | 2 | 2 | 0 | NA | NA |
| 5 | 1 | 1 | 0 | 0 | 0 | NA | NA |
| 6 | 20 | 16 | 4 | 3 | 1 | NA | NA |
| Total | 164 | 126 | 38 | 26 | 12 | NA | NA |
| Data missing | 2 | 1 | 1 | 0 | 1 | NA | NA |
| Anterior circulation | NA | NA | 33 | 24 | 9 | NA | NA |
| Timing of final available ped-mRS score poststroke, mo | | | | | | | |
| Mean (SD) | 37.0 (28.8) | 34.7 (26.7) | 44.6 (34.1) | 53.0 (37.0) | 26.4 (16.6) | NA | NA |
| Median (IQR) | 35.0 (12.0-48.0) | 30.0 (12.0-48.0) | 36.0 (16.75-60.0) | 41.0 (24.0-94.5) | 27.0 (10.5-42.75) | NA | NA |
| Ordinal logistic regression analysis: OR of a worse functional outcome at final assessment | | | | | | | |
| LVO with no thrombectomy vs non-LVO ^a | NA | NA | NA | NA | NA | 3.23 (1.50-6.95) | .003 |
| LVO with thrombectomy vs non-LVO ^a | NA | NA | NA | NA | NA | 0.80 (0.28-2.29) | .68 |
| LVO with no thrombectomy vs LVO with thrombectomy ^b | NA | NA | NA | NA | NA | 6.07 (1.55-23.73) | .01 |
| LVO with no thrombectomy (anterior circulation) vs LVO with thrombectomy (anterior circulation) ^b | NA | NA | NA | NA | NA | 8.60 (1.78-41.53) | .007 |
| Dichotomous analysis ^c | | | | | | | |
| ped-mRS score | NA | NA | NA | NA | NA | | |
| 0-2 | 108 (65.9) | 89 (70.6) | 19 (50.0) | 11 (42.3) | 8 (66.7) | $\chi^2 = 7.695$ | .02 |
| 3-6 | 56 (34.1) | 37 (29.4) | 19 (50.0) | 15 (57.7) | 4 (33.3) | | |
| 0-2 (anterior circulation) | NA | NA | 16 (48.5) | 10 (41.7) | 6 (66.7) | | |
| 3-6 (anterior circulation) | NA | NA | 17 (51.5) | 14 (58.3) | 3 (33.3) | | |

Abbreviations: AIS, arterial ischemic stroke; LVO, large vessel occlusion; NA, not applicable; OR, odds ratio; ped-mRS, pediatric modified Rankin Scale.

^a Primary analysis performed with ordinal logistic regression comparing ped-mRS score at final available assessment after stroke between 3 groups: non-LVO, LVO with no thrombectomy, and LVO with thrombectomy. Non-LVO was the reference group. OR of a worse functional outcome (higher score on the ped-mRS scale from 0 to 6) compared with the non-LVO group was determined.

^b Secondary analysis performed with ordinal logistic regression comparing ped-mRS score at final available assessment after stroke between LVO with thrombectomy and LVO with no thrombectomy. LVO with no thrombectomy

was the reference group. OR of a worse functional outcome (higher score on the ped-mRS scale from 0 to 6) comparing LVO with no thrombectomy with the LVO with thrombectomy group was determined. Subgroup analysis was performed using the same method but including only anterior circulation cases (34 of 39 patients with LVO and 9 of 13 with thrombectomy and data available; 24 without thrombectomy).

^c Secondary dichotomous analysis performed using Pearson χ^2 test for favorable (ped-mRS score of 0 to 2) vs poor (ped-mRS score of 3 to 6) clinical outcomes at final available assessment after stroke between 3 groups: non-LVO, LVO with no thrombectomy, and LVO with thrombectomy groups.

orrhage occurred in 1 patient.¹³ A meta-analysis of pediatric patients undergoing thrombectomy (n = 113) demonstrated favorable long-term outcomes in 90.6%.¹² These results were superior to adult trials (mRS score of 0 to 2 in 46% at 3 months⁸) and are likely affected by selection bias.¹³ However, they indicate mechanical thrombectomy in children is feasible and effective.^{12,13} In our study, 50% of patients undergoing thrombectomy had a ped-mRS score of 0 to 2 at 3 months and 67% at final assessment.

Our results can now provide a natural history reference group for this population. Given the poor natural history and

feasibility of thrombectomy in children, the risk-benefit balance for intervention is likely altered, and pediatric guidelines should be updated. Prospective multinational registries should be encouraged and funded.

Timing of Clinical Presentation in Pediatric LVO Stroke

In our cohort, 69% of children with LVO presented within 6 hours since last seen well, and 90% presented within 24 hours. Four of 5 children with LVO (82.1%) fulfilled adult selection criteria for consideration of thrombectomy other than age.^{3,9,11} These high rates of early presentation likely reflect the sever-

Table 5. Clinical Presentation and Outcomes in Patients With Large Vessel Occlusion (LVO)

| Outcome | LVO, No. (%) | | P value |
|--|-----------------------|------------------------|--------------------|
| | No thrombectomy | Thrombectomy | |
| Patients, No. | 26 | 13 | |
| Age, mean (SD; range), y | 6.23 (4.73; 0.4-14.5) | 12.41 (4.41; 4.0-16.9) | <.001 ^a |
| Sex | | | |
| Female | 13 (50.0) | 3 (23.1) | .11 ^b |
| Male | 13 (50.0) | 10 (76.9) | |
| Clinical presentation | | | |
| Timing of clinical presentation since last seen well, h | | | |
| <6 | 17 (65.4) | 10 (76.9) | NA |
| 6-24 | 5 (19.2) | 3 (23.1) | NA |
| 24-48 | 2 (7.7) | 0 | NA |
| >48 | 2 (7.7) | 0 | NA |
| Total <24 h | 22 (84.6) | 13 (100) | NA |
| Fulfilled adult selection criteria for mechanical thrombectomy | | | |
| MR CLEAN trial ³ | 12 (46.2) | 8 (61.5) | NA |
| DAWN trial ¹¹ | 5 (19.2) | 2 (15.4) | NA |
| Posterior circulation ⁹ | 2 (7.7) | 3 (23.1) | NA |
| Total | 19 (73.1) | 13 (100) | NA |
| Stroke etiology | | | |
| Cardioembolic | 8 (30.8) | 4 (30.8) | NA |
| Dissection | 6 (23.1) | 2 (15.4) | NA |
| Focal cerebral arteriopathy | 3 (11.5) | 1 (7.7) | NA |
| Hypercoagulable | 2 (7.7) | 1 (7.7) | NA |
| Iatrogenic | 3 (11.5) | 0 | NA |
| Idiopathic | 4 (15.4) | 2 (15.4) | NA |
| Other | 0 | 1 (7.7) | NA |
| Paradoxical embolus | 0 | 2 (15.4) | NA |
| IV thrombolysis | 0 | 3 (23.1) | NA |
| Clinical outcome | | | |
| ped-mRS Score at 3 mo poststroke, No. | | | |
| 0 | 0 | 2 | NA |
| 1 | 1 | 3 | NA |
| 2 | 6 | 1 | NA |
| 3 | 7 | 3 | NA |
| 4 | 9 | 2 | NA |
| 5 | 2 | 0 | NA |
| 6 | 1 | 1 | NA |
| Total | 26 | 12 | .04 ^c |
| Data missing, No. | 0 | 1 | NA |
| Anterior circulation, No. | 24 | 9 | NA |
| 0-2 | 7 (26.9) | 6 (50.0) | NA |
| 3-6 | 19 (73.1) | 6 (50.0) | NA |
| Timing of final available ped-mRS score poststroke, mo | | | |
| Mean (SD) | 53.0 (37.0) | 26.4 (16.6) | NA |
| Median (IQR) | 41.0 (24.0-94.5) | 27.0 (10.5-42.75) | NA |
| Safety outcomes | | | |
| Symptomatic ICH ^d | 4 (15.4) | 0 | .03 ^e |
| Access site complications | NA | 1 (7.7) ^f | NA |

Abbreviations: ICH, intracranial hemorrhage; LVO, large vessel occlusion; NA, not applicable; ped-mRS, pediatric modified Rankin Scale.

^a t Test.

^b χ^2 Test.

^c Ordinal regression analysis: odds ratio, 3.75; 95% CI, 1.05-13.45. Ordinal logistic regression analysis performed comparing ped-mRS score at 3 months poststroke between LVO with no thrombectomy and LVO with thrombectomy groups to determine the odds ratio of a worse functional outcome for the conservatively treated group on the ped-mRS scale (ie, higher score on the scale from 0 to 6).

^d Symptomatic ICH defined as radiologically confirmed acute intracranial hemorrhage associated with acute worsening in neurological state, specifically an increase in the Pediatric National Institutes of Health Stroke Scale score of 4 or more.

^e Two-proportions test.

^f Single case of retroperitoneal hemorrhage arising from the femoral access site, treated with a covered stent.

ity of the neurological syndrome in LVO. The focus of pediatric stroke pathways should therefore be on reducing triage and imaging times with appropriate anesthetic support.^{15,18}

While we have used adult stroke criteria for reference, time-based limits from adult practice may be too restrictive for children. Children have strong pial collaterals, providing greater

compensation in acute ischemic stroke.^{24,25} Low Pediatric National Institutes of Health Stroke Scale score or presentation more than 24 hours since last seen well should not be absolute contraindications for thrombectomy in children. Rather, imaging assessment of perfusion or infarct volume may be valuable.^{23,24,26}

Epidemiology of Pediatric LVO Stroke

LVO was present in nearly one-quarter of pediatric AIS admissions (23.5%)—similar to the rate in adults (18% to 24%).^{1,27,28} Even if ACA and PCA occlusions are excluded, the rate of LVO in our study was 22.3% (37 of 166). Our estimate of pediatric AIS incidence (1.02 cases per 100 000 persons per year) is concordant with that of the Canadian Pediatric Ischemic Stroke Registry when neonatal strokes are excluded (1.2).²² Our cohort was predominantly male (65.2%), and this sex imbalance is well established for pediatric AIS.^{15,22,29} In the state of NSW, with a pediatric population of approximately 1.7 million persons²⁰ and a mean annual LVO incidence of 0.24 cases per 100 000 persons per year (95% CI, 0.13-0.35), we could anticipate 2 to 6 pediatric LVO cases per year. This data allows for greater planning of pediatric stroke services.

Limitations

There are several limitations of this study. Patients from border communities may have been transferred to interstate centers. However, we expect a similar number of transfers into our state. Pediatric patients with no deficit may have been treated in community hospitals. We deviated from our original protocol by excluding patients aged 17 years after determining that a substantial proportion were treated in adult hospitals. We ex-

cluded neonatal stroke because of differing presentation, etiology, and treatment.¹⁵

The absence of randomization or standardized selection criteria for thrombectomy is a major limitation owing to selection bias. Comparison of patients with LVO treated with thrombectomy with conservatively treated patients is also weakened by the small sample size and age difference. Patients with AIS are more likely to have underlying long-term health conditions that may also affect long-term outcomes.^{15,22,28}

Our study used retrospective assessment of ped-mRS scores, which is more prone to bias. Reviewers of the ped-mRS score were not blinded to thrombectomy status. The mRS score was originally adapted for children by Bigi et al³⁰ but has not been validated in prospective pediatric stroke studies. Dichotomous classification of outcome into favorable (ped-mRS score of 0 to 2) and poor (ped-mRS score of 3 to 6) is not validated in children, and thus, the primary analysis was undertaken using ordinal logistic regression.

Conclusions

In this population-based cohort study, LVO was present in nearly one-quarter of pediatric patients with AIS, and most fulfilled adult selection criteria for mechanical thrombectomy. Pediatric patients with LVO treated conservatively had poor long-term outcomes that were significantly worse than those with non-LVO and those treated with thrombectomy. Future pediatric stroke guidelines may take account of this poor natural history.

ARTICLE INFORMATION

Accepted for Publication: January 28, 2022.

Published Online: March 28, 2022.
doi:10.1001/jamaneurol.2022.0323

Author Affiliations: Department of Medical Imaging, Children's Hospital at Westmead, Westmead, Australia (Bhatia, Goetti); Children's Hospital at Westmead Clinical School, Faculty of Medicine and Health, University of Sydney, Westmead, Australia (Bhatia, Webster, Troedson, Dale); Faculty of Medicine, Macquarie University, Sydney, Australia (Bhatia); Department of Neurology, Sydney Children's Hospital, Randwick, Sydney, Australia (Briest, Andrews); T.Y. Nelson Department of Neurology and Neurosurgery, Children's Hospital at Westmead, Westmead, Australia (Webster, Troedson, Dale); Division of Image-Guided Therapy, Department of Radiology, Hospital for Sick Children, Toronto, Ontario, Canada (Muthusami); Department of Neurology, John Hunter Children's Hospital, New Lambton Heights, Australia (C. Miteff); Department of Neurology, John Hunter Hospital, New Lambton Heights, Australia (F. Miteff); Department of Neurology, Royal Prince Alfred Hospital, Camperdown, Australia (Worthington, Tastula, Ang); School of Women's and Children's Health, Faculty of Medicine, University of New South Wales, Randwick, Australia (Andrews).

Author Contributions: Messrs Bhatia and Andrews had full access to all the data in the study and take

responsibility for the integrity of the data and the accuracy of the data analysis.

Study concept and design: Bhatia, Muthusami, Worthington, Andrews.

Acquisition, analysis, or interpretation of data: All authors.

Drafting of the manuscript: Bhatia, Goetti, Ang.
Critical revision of the manuscript for important intellectual content: Bhatia, Briest, Webster, Troedson, Dale, Muthusami, C. Miteff, F. Miteff, Worthington, Tastula, Andrews.

Statistical analysis: Bhatia, Briest.

Administrative, technical, or material support: Bhatia, Briest, Goetti, Webster, Dale, C. Miteff, Tastula, Andrews.

Study supervision: Ang, Andrews.

Conflict of Interest Disclosures: None reported.

REFERENCES

- Dozois A, Hampton L, Kingston CW, et al. PLUMBER study (Prevalence of Large Vessel Occlusion Strokes in Mecklenburg County Emergency Response). *Stroke*. 2017;48(12):3397-3399. doi:10.1161/STROKEAHA.117.018925
- Smith WS, Lev MH, English JD, et al. Significance of large vessel intracranial occlusion causing acute ischemic stroke and TIA. *Stroke*. 2009;40(12):3834-3840. doi:10.1161/STROKEAHA.109.561787
- Berkhemer OA, Fransen PS, Beumer D, et al; MR CLEAN Investigators. A randomized trial of intraarterial treatment for acute ischemic stroke.

N Engl J Med. 2015;372(1):11-20. doi:10.1056/NEJMoa1411587

4. Saver JL, Goyal M, Bonafe A, et al; SWIFT PRIME Investigators. Stent-retriever thrombectomy after intravenous t-PA vs. t-PA alone in stroke. *N Engl J Med*. 2015;372(24):2285-2295. doi:10.1056/NEJMoa1415061

5. Jovin TG, Chamorro A, Cobo E, et al; REVASCAT Trial Investigators. Thrombectomy within 8 hours after symptom onset in ischemic stroke. *N Engl J Med*. 2015;372(24):2296-2306. doi:10.1056/NEJMoa1503780

6. Goyal M, Demchuk AM, Menon BK, et al; ESCAPE Trial Investigators. Randomized assessment of rapid endovascular treatment of ischemic stroke. *N Engl J Med*. 2015;372(11):1019-1030. doi:10.1056/NEJMoa1414905

7. Campbell BC, Mitchell PJ, Kleinig TJ, et al; EXTEND-IA Investigators. Endovascular therapy for ischemic stroke with perfusion-imaging selection. *N Engl J Med*. 2015;372(11):1009-1018. doi:10.1056/NEJMoa1414792

8. Goyal M, Menon BK, van Zwam WH, et al; HERMES collaborators. Endovascular thrombectomy after large-vessel ischaemic stroke: a meta-analysis of individual patient data from five randomised trials. *Lancet*. 2016;387(10029):1723-1731. doi:10.1016/S0140-6736(16)00163-X

9. Powers WJ, Rabinstein AA, Ackerson T, et al. Guidelines for the early management of patients

- with acute ischemic stroke: 2019 update to the 2018 guidelines for the early management of acute ischemic stroke: a guideline for healthcare professionals from the American Heart Association/American Stroke Association. *Stroke*. 2019;50(12):e344-e418. doi:10.1161/STR.0000000000000211
10. Albers GW, Lansberg MG, Kemp S, et al. A multicenter randomized controlled trial of endovascular therapy following imaging evaluation for ischemic stroke (DEFUSE 3). *Int J Stroke*. 2017;12(8):896-905. doi:10.1177/1747493017701147
11. Nogueira RG, Jadhav AP, Haussen DC, et al; DAWN Trial Investigators. Thrombectomy 6 to 24 hours after stroke with a mismatch between deficit and infarct. *N Engl J Med*. 2018;378(1):11-21. doi:10.1056/NEJMoa1706442
12. Bhatia K, Kortman H, Blair C, et al. Mechanical thrombectomy in pediatric stroke: systematic review, individual patient data meta-analysis, and case series. *J Neurosurg Pediatr*. 2019;24(5):1-14. doi:10.3171/2019.5.PEDS19126
13. Sporns PB, Sträter R, Minnerup J, et al. Feasibility, safety, and outcome of endovascular recanalization in childhood stroke: the Save Childs study. *JAMA Neurol*. 2020;77(1):25-34. doi:10.1001/jamaneurol.2019.3403
14. Medley TL, Miteff C, Andrews I, et al. Australian Clinical Consensus Guideline: the diagnosis and acute management of childhood stroke. *Int J Stroke*. 2019;14(1):94-106. doi:10.1177/1747493018799958
15. Ferriero DM, Fullerton HJ, Bernard TJ, et al; American Heart Association Stroke Council and Council on Cardiovascular and Stroke Nursing. Management of stroke in neonates and children: a scientific statement from the American Heart Association/American Stroke Association. *Stroke*. 2019;50(3):e51-e96. doi:10.1161/STR.0000000000000183
16. Rivkin MJ, deVeber G, Ichord RN, et al. Thrombolysis in pediatric stroke study. *Stroke*. 2015; 46(3):880-885. doi:10.1161/STROKEAHA.114.008210
17. Harrar DB, Salussolia CL, Kapur K, et al. A stroke alert protocol decreases the time to diagnosis of brain attack symptoms in a pediatric emergency department. *J Pediatr*. 2020;216:136-141.e6. doi:10.1016/j.jpeds.2019.09.027
18. deVeber GA. Delays in the timely diagnosis of stroke in children. *Nat Rev Neurol*. 2010;6(2):64-66. doi:10.1038/nrneuro.2009.228
19. Lagman-Bartolome AM, Pontigon AM, Moharir M, et al. Basilar artery strokes in children: good outcomes with conservative medical treatment. *Dev Med Child Neurol*. 2013;55(5):434-439. doi:10.1111/dmcn.12092
20. Australia Bureau of Statistics. National, state, and territory population. Accessed September 1, 2021. <https://www.abs.gov.au/statistics/people/population/national-state-and-territory-population/latest-release#data-downloads-data-cubes>
21. Macdonald-Laurs E, Wenderoth J, Cardamone M, Sampaio H, Andrews PI. Endovascular clot retrieval for acute ischaemic stroke due to basilar artery occlusion in childhood. *Dev Med Child Neurol*. 2020;62(10):1221-1223. doi:10.1111/dmcn.14449
22. deVeber GA, Kirton A, Booth FA, et al. Epidemiology and outcomes of arterial ischemic stroke in children: the Canadian Pediatric Ischemic Stroke Registry. *Pediatr Neurol*. 2017;69:58-70. doi:10.1016/j.pediatrneurol.2017.01.016
23. Steinlin M, Pfister I, Pavlovic J, et al; Swiss Societies of Paediatric Neurology and Neonatology. The first three years of the Swiss Neuropaediatric Stroke Registry (SNPSR): a population-based study of incidence, symptoms and risk factors. *Neuropediatrics*. 2005;36(2):90-97. doi:10.1055/s-2005-837658
24. Khalaf A, Iv M, Fullerton H, Wintermark M. Pediatric stroke imaging. *Pediatr Neurol*. 2018;86: 5-18. doi:10.1016/j.pediatrneurol.2018.05.008
25. Wintermark M, Lepori D, Cotting J, et al. Brain perfusion in children: evolution with age assessed by quantitative perfusion computed tomography. *Pediatrics*. 2004;113(6):1642-1652. doi:10.1542/peds.113.6.1642
26. Grigoriadis S, Gomori JM, Grigoriadis N, Cohen JE. Clinically successful late recanalization of basilar artery occlusion in childhood: what are the odds? case report and review of the literature. *J Neurol Sci*. 2007;260(1-2):256-260. doi:10.1016/j.jns.2007.03.028
27. Waqas M, Mokin M, Primiani CT, et al. Large vessel occlusion in acute ischemic stroke patients: a dual-center estimate based on a broad definition of occlusion site. *J Stroke Cerebrovasc Dis*. 2020;29(2):104504. doi:10.1016/j.jstrokecerebrovasdis.2019.104504
28. Rennert RC, Wali AR, Steinberg JA, et al. Epidemiology, natural history, and clinical presentation of large vessel ischemic stroke. *Neurosurgery*. 2019;85(suppl 1):S4-S8. doi:10.1093/neuros/nyz042
29. Golomb MR, Fullerton HJ, Nowak-Gottl U, DeVeber G; International Pediatric Stroke Study Group. Male predominance in childhood ischemic stroke: findings from the International Pediatric Stroke Study. *Stroke*. 2009;40(1):52-57. doi:10.1161/STROKEAHA.108.521203
30. Bigi S, Fischer U, Wehrli E, et al. Acute ischemic stroke in children versus young adults. *Ann Neurol*. 2011;70(2):245-254. doi:10.1002/ana.22427

MR Perfusion Imaging in Moyamoya Syndrome Potential Implications for Clinical Evaluation of Occlusive Cerebrovascular Disease

F. Calamante, PhD; V. Ganesan, MD; F.J. Kirkham, MB, BChir; W. Jan, MBBS;
W.K. Chong, MD, FRCR; D.G. Gadian, DPhil; A. Connelly, PhD

Background and Purpose—Ischemic symptoms in patients with moyamoya syndrome (MMS) are usually due to hemodynamically mediated perfusion failure, and identification of abnormal tissue perfusion in these patients is therefore clinically important. Although dynamic susceptibility contrast (DSC) MRI can be used to study tissue perfusion, there are potential technical problems in MMS. This study investigates the scope and limitations of perfusion MRI in the clinical evaluation of such patients.

Methods—Thirteen patients with bilateral MMS were studied with the use of structural, diffusion, and perfusion MRI. The DSC MRI data were analyzed both visually and by a quantitative regional analysis, and the relationship between perfusion status and clinical symptoms was investigated.

Results—Extensive bilateral DSC MRI abnormalities were observed in all the patients. There was a very heterogeneous distribution of bolus arrival time. The areas of abnormality included the major arterial border zones in all cases, although these usually appeared normal on structural and diffusion MRI. Only the most clinically unstable patients had peak width (defined as time to peak minus bolus arrival time) >5 seconds on the quantitative regional analysis. Several technical limitations of perfusion quantification in MMS are described, as well as the implications of these limitations in patients with other forms of occlusive large-vessel disease.

Conclusions—The technical limitations of DSC MRI described in this study are important for the accurate interpretation of perfusion MRI in MMS. Despite these limitations, these preliminary findings suggest that the use of quantitative regional analysis of summary parameters may provide clinically useful information in patients with MMS. (*Stroke*. 2001;32:2810-2816.)

Key Words: cerebral ischemia ■ hypoperfusion ■ moyamoya disease ■ perfusion ■ stenosis

Moyamoya syndrome (MMS) is an angiographically defined cerebrovascular disorder with terminal internal carotid artery (ICA) occlusion and basal collateral vessels that may be idiopathic or may occur secondary to many disorders, including neurofibromatosis and sickle cell anemia.¹ The most common presentation is with recurrent transient ischemic attacks (TIAs) or stroke in childhood, resulting in significant morbidity. Ischemic symptoms are usually due to hemodynamically mediated perfusion failure rather than thromboembolism.² One possible treatment is surgical cerebral revascularization, which aims to increase the blood supply to hypoperfused tissue. Identification of abnormal tissue perfusion is therefore an important aspect of the evaluation of these patients. Although positron emission tomography and single-photon emission CT can delineate areas of cerebral hypoperfusion,^{2,3} they are not optimal for repeated examinations and do not provide information about the structural integrity of hypoperfused tissue.

Dynamic susceptibility contrast (DSC) MRI allows noninvasive investigation of the tissue perfusion⁴ and could therefore be useful in the clinical evaluation of patients with MMS. In addition, the ability to simultaneously perform structural and diffusion imaging means that there is potential to identify tissue with mismatch between areas of diffusion and perfusion abnormality. In patients with acute stroke, such areas are believed to represent tissue “at risk.”⁵ In patients with chronic cerebral ischemia, the presence of diffusion-perfusion mismatch could potentially identify areas of hypoperfused tissue that are not irreversibly damaged.

Although some studies using perfusion MRI in MMS have been reported,^{6–8} interpretation of DSC MRI data in these patients is not straightforward. The presence of collaterals can introduce delay and dispersion in the bolus of contrast agent, making quantification of perfusion MRI data less reliable.⁹ With the use of numerical simulations, it has been shown that a delay of only 1 to 2 seconds (with associated bolus

Received August 3, 2001; final revision received September 6, 2001; accepted September 19, 2001.

From the Radiology and Physics (F.C., D.G.G., A.C.) and Neurosciences (V.G., F.J.K.) Units, Institute of Child Health, University College London, and the Department of Radiology, Great Ormond Street Hospital (W.J., W.K.C.), London, UK.

Correspondence to Dr Fernando Calamante, Radiology and Physics Unit, Institute of Child Health, University College London, 30 Guilford St, London WC1N 1EH, UK. E-mail cfeman@ich.ucl.ac.uk

© 2001 American Heart Association, Inc.

Stroke is available at <http://www.strokeaha.org>

dispersion) can introduce a large underestimation (>40%) of cerebral blood flow (CBF) and overestimation (>60%) of mean transit time (MTT),⁹ making these maps potentially misleading. Awareness of this possible source of error is important because of the increasingly widespread availability of the software and hardware for performing analysis of perfusion MRI.

The aim of this study is to explore the scope and limitations of perfusion MRI in the clinical evaluation of patients with MMS.

Subjects and Methods

All patients in this study had angiographically confirmed MMS and were being evaluated for surgical revascularization. We have used the term moyamoya “syndrome” in all cases, whether or not there was an associated diagnosis, to describe the angiographic syndrome of ICA occlusion with basal collaterals. The MR data were obtained as part of this clinical evaluation, and their analysis was approved by the local research ethics committee. Conventional cerebral arteriograms were reviewed to grade the severity of the MMS according to the classification of Suzuki.¹ This classification describes angiographic stages of progressive ICA occlusion and appearance of basal collateral vessels from stage 1 (bilateral terminal ICA stenosis) to stage 6 (complete obliteration of the ICA circulation with supply of brain derived entirely from the external carotid artery). Obliteration of the posterior cerebral arteries constitutes stage 4 in this classification. The patients were categorized according to their clinical symptoms into the following classifications: absent, patients who were cognitively and clinically stable (category A); moderate, patients with occasional (less than once a month) TIAs (category B); and severe, patients who had TIAs occurring more than once a month or recurrent stroke within the previous 12 months (category C).

All patients underwent MR examination with the use of a 1.5-T Siemens Vision system that included structural MRI (T1- and T2-weighted imaging), time-of-flight MR angiography, and MR diffusion and perfusion imaging.

MR Diffusion Imaging

Diffusion imaging was performed with a fluid-attenuated inversion recovery (FLAIR) spin-echo echo-planar imaging (EPI) sequence, with a pair of diffusion gradients on either side of the refocusing pulse (echo time [TE]=86 ms; repetition time [TR]=8700 ms; inversion time=2100 ms). The diffusion parameters were as follows: diffusion gradient duration (δ)=15 ms; time interval between diffusion gradients (Δ)=40.2 ms; b values=0 and 617 s/mm². Maps of the apparent diffusion coefficient (ADC) were calculated in 3 orthogonal directions, which were combined to generate average ADC maps (ADC_{AV}).

MR Perfusion Imaging

DSC MRI was performed with a spin-echo EPI sequence. The imaging parameters were TE=100 ms, TR=1500 ms. Six slices were acquired, with 1 of the slices including the middle cerebral artery to enable estimation of the arterial input function (AIF). A bolus of 0.15 mmol/kg body wt contrast agent (Gd-DTPA; Magnevist, Schering AG) was injected intravenously (rate \approx 4 mL/s) with the use of an MR-compatible power injector (Medrad Inc), followed by a saline flush.

The DSC MRI data were analyzed in 2 different ways.⁴ The first method used deconvolution,¹⁰ which can, in principle, generate accurate measurements of CBF, cerebral blood volume (CBV), and MTT. In addition, because of the potential errors in the calculation of CBF and MTT associated with bolus delay and dispersion (see above), the data were also analyzed by calculating summary parameters (see below and Figure 1).



Figure 1. Schematic concentration-time curve illustrating summary parameters (see text). $C(t)$ indicates concentration of contrast agent over time.

Analysis of Perfusion Data Using Deconvolution

The signal intensity–time course was converted to a concentration-time course, and the AIF was used to deconvolve the concentration-time curve by singular value decomposition.¹⁰ A 3×3 uniform smoothing kernel was applied to the raw image data before deconvolution. Maps of CBF, CBV, and MTT were calculated on a pixel-by-pixel basis. The data were assessed for the presence of bolus arrival delay and bolus dispersion.⁹

Analysis of Perfusion Data Using Summary Parameters

Several summary parameters obtained directly from the concentration-time course profile can be used as indirect measures of perfusion (Figure 1). The most commonly used include time to peak (TTP), bolus arrival time (BAT), a measure of the peak width (PW), maximum peak concentration (MPC), and the peak area (PA, proportional to CBV). Fitting to an analytical function (eg, gamma-variate function¹¹) is usually used to eliminate the presence of recirculation at the end of the peak and to calculate the summary parameters more accurately. This fitting is difficult on a pixel-by-pixel basis because of the low signal-to-noise ratio and is particularly problematic with data from children because the peak is usually much narrower than that from adults. Nevertheless, TTP and MPC can be calculated in a fairly robust way for each pixel because they can be obtained with only the measurements around the maximum of the peak, without requiring the identification of the start and end of the peak. In this study TTP and MPC maps were calculated by fitting a second-order polynomial to the 5 points across the peak maximum. The same 3×3 smoothing kernel was used on the raw data before the fitting.

Quantitative Regional Analysis of Summary Parameter Maps

For a more accurate quantitative analysis of summary parameters in children, a regional analysis was also performed. It has been shown that summary parameters can show large variability due to differences in AIF.¹² To minimize this effect and to allow a better comparison between patients, a region of interest in the cerebellum was used as a reference. The noninfarcted tissue was segmented into 3 categories: Δ TTP values from 0 to 5, 5 to 10, and 10 to 15 seconds, where Δ TTP=TTP–TTP_{REF}. The signal intensities of the pixels in each category were averaged to increase signal-to-noise ratio and allow a more robust calculation of the various summary parameters. The averaged signal in each segmented region was fitted to a gamma-variate function to calculate mean values of TTP, BAT, PW (PW=TTP–BAT), MPC, and PA for each category (Figure 1). All these parameters were referenced to the corresponding values in the cerebellum. The resulting relative values and percentage of pixels in each segmented region were used to investigate the relationship between perfusion status and clinical symptoms.

In the patients with multiple MRI scans, all the studies were analyzed with the use of deconvolution and by visual inspection of the summary parameter maps. For the quantitative analysis of summary parameters, only the most recent scan was analyzed, except in patients who had had scans before and after revascularization, for whom the latest preoperative scan was used.

For the remainder of this report, a region will be considered to have a hemodynamic abnormality if there was any abnormality on DSC MRI (either in a summary parameter or in a map obtained from the deconvolution analysis).

Results

Thirteen children and young adults (aged 22 months to 18.5 years; median age, 11.5 years) were studied; 6 patients were scanned more than once. Seven of 13 patients had had surgical revascularization involving a total of 12 hemispheres before their first MR examination. All patients had bilateral MMS, which was Suzuki stage 3 in 9 cases and stage 4 in 4 cases. Eleven of 13 had areas of established cerebral infarction. Five patients were in category A (symptoms absent), 3 in category B (moderate), and 5 in category C (severe).

General Findings

Bilateral hemodynamic abnormalities were observed in all the patients, including those who had had revascularization. There was a very heterogeneous distribution of BAT, with some areas displaying a delay in bolus arrival (Δ BAT, relative to the cerebellum) of >5 seconds (Table). The severity of the abnormality varied within the population despite the similarity of the angiographic severity of MMS. On visual inspection of the DSC MRI maps, the areas of abnormality included the major arterial border zones in all cases, although these appeared normal on structural and diffusion imaging in all but 1 case in which there had been a previous infarct.

Deconvolution Analysis

The observed heterogeneous pattern of very long delays (and likely dispersion due to the presence of collaterals) makes quantification of CBF very unreliable. This is illustrated in the data from 2 children with MMS shown in Figure 2. The patient in Figure 2A is a 6-year-old boy (patient 6 in the Table), who had had recurrent headaches and TIAs affecting the left leg. The T2/diffusion data showed some small nonacute infarcts in the right caudate (not shown). However, there was an extensive hemodynamic abnormality in both hemispheres, with reduced CBF and prolonged MTT in noninfarcted regions bilaterally. The CBF ratio of 2 regions of interest in the right side (the anterior with relatively lower signal intensity in the CBF map; see inset in Figure 2A) was ≈ 0.50 . The gamma-variate fitting to the regional concentration-time course indicated that the bolus arrived at both regions at approximately the same time. Therefore, the ≈ 0.50 ratio is likely to reflect (in the absence of significant dispersion) a true $\approx 50\%$ CBF reduction in the anterior region compared with the posterior region. On the other hand, Figure 2B shows data from a 12-year-old girl (patient 5 in the Table) in whom the deconvolution analysis gives misleading information. Although no abnormality was observed in the occipital areas on structural/diffusion MRI, these areas have an apparent perfusion abnormality (arrows). The CBF ratios of 2 occipital regions to a "normal" region in the basal ganglia were both ≈ 0.45 (the occipital regions also show increased MTT). A regional analysis of the concentration-time course for the 3 regions showed that the bolus arrived at approximately the same time in the occipital regions but was delayed

Summary Parameter Values for the Different Segmented Regions

| Patient (Category) | Region (Δ TTP) | Δ BAT, s | Δ TTP, s | Δ PW, s | MPC _{REL} | PA _{REL} | % Pixels |
|--------------------|------------------------|-----------------|-----------------|----------------|--------------------|-------------------|----------|
| 1 (A) | 0-5 | 0.49 | 2.45 | 1.97 | 1.20 | 1.59 | 87 |
| | 5-10 | 3.78 | 6.11 | 2.33 | 0.65 | 1.17 | 12 |
| | 10-15 | ... | ... | ... | ... | ... | 0 |
| 2 (A) | 0-5 | -0.66 | 0.91 | 1.56 | 1.04 | 1.02 | 73 |
| | 5-10 | 2.27 | 5.18 | 2.91 | 0.53 | 0.66 | 1 |
| | 10-15 | ... | ... | ... | ... | ... | 0 |
| 3 (A) | 0-5 | 0.39 | 1.51 | 1.12 | 1.07 | 1.11 | 96 |
| | 5-10 | 1.64 | 4.98 | 3.33 | 0.64 | 0.88 | 1 |
| | 10-15 | ... | ... | ... | ... | ... | 0 |
| 4 (A) | 0-5 | 0.28 | 2.95 | 2.67 | 1.24 | 1.65 | 66 |
| | 5-10 | 2.24 | 6.04 | 3.80 | 0.88 | 1.32 | 33 |
| | 10-15 | ... | ... | ... | ... | ... | 0 |
| 5 (A) | 0-5 | -0.66 | 2.62 | 3.29 | 1.23 | 1.93 | 73 |
| | 5-10 | 2.02 | 5.63 | 3.61 | 0.83 | 1.39 | 24 |
| | 10-15 | ... | ... | ... | ... | ... | 0 |
| 6 (B) | 0-5 | 0.31 | 2.14 | 1.83 | 1.08 | 1.37 | 88 |
| | 5-10 | 1.20 | 5.91 | 4.72 | 0.62 | 1.18 | 12 |
| | 10-15 | ... | ... | ... | ... | ... | 0 |
| 7 (B) | 0-5 | 1.93 | 2.43 | 0.50 | 1.01 | 1.47 | 84 |
| | 5-10 | 2.61 | 4.90 | 2.29 | 0.59 | 1.02 | 16 |
| | 10-15 | ... | ... | ... | ... | ... | 0 |
| 8 (B) | 0-5 | 0.85 | 1.84 | 0.99 | 0.88 | 0.96 | 90 |
| | 5-10 | 4.19 | 5.98 | 1.79 | 0.41 | 0.57 | 8 |
| | 10-15 | ... | ... | ... | ... | ... | 0 |
| 9 (C) | 0-5 | -0.84 | 3.19 | 4.03 | 1.04 | 1.59 | 39 |
| | 5-10 | 1.27 | 6.85 | 5.57 | 0.66 | 1.29 | 53 |
| | 10-15 | 7.36 | 11.51 | 4.15 | 0.43 | 1.03 | 8 |
| 10 (C) | 0-5 | 0.39 | 2.74 | 2.36 | 1.19 | 1.52 | 65 |
| | 5-10 | 2.46 | 6.25 | 3.79 | 0.83 | 1.23 | 33 |
| | 10-15 | 5.52 | 11.68 | 6.16 | 0.47 | 0.96 | 2 |
| 11 (C) | 0-5 | 0.46 | 2.10 | 1.64 | 1.22 | 1.40 | 76 |
| | 5-10 | 1.09 | 6.14 | 5.05 | 0.63 | 0.86 | 17 |
| | 10-15 | ... | ... | ... | ... | ... | 0 |
| 12 (C) | 0-5 | 0.51 | 2.68 | 2.16 | 1.27 | 1.87 | 67 |
| | 5-10 | 1.49 | 6.67 | 5.18 | 1.09 | 2.13 | 26 |
| | 10-15 | -0.30 | 11.04 | 11.35 | 0.74 | 1.79 | 6 |
| 13 (C) | 0-5 | -0.36 | 1.53 | 1.89 | 0.96 | 1.34 | 87 |
| | 5-10 | 1.95 | 7.08 | 5.13 | 0.47 | 1.07 | 4 |
| | 10-15 | ... | ... | ... | ... | ... | 0 |

The cerebellum was used as reference. Category indicates clinical category of the patient; Region, segmented regions from the Δ TTP maps; REL, relative (ie, ratio) to the value in the cerebellum; % Pixels, number of pixels in the corresponding segmented region as a percentage of the total number of pixels. The remainder of the pixels (from 100%) consist of negative Δ TTP (ie, TTP shorter than that in the cerebellum) pixels (not included in the Table).

≈ 2 seconds compared with the basal ganglia. This delay will introduce an underestimation in the calculated CBF in the occipital regions of $\approx 40\%$,⁹ and the perfusion maps in Figure 2B are therefore misleading. Although both patients show maps with very similar relative decreases in CBF, the actual

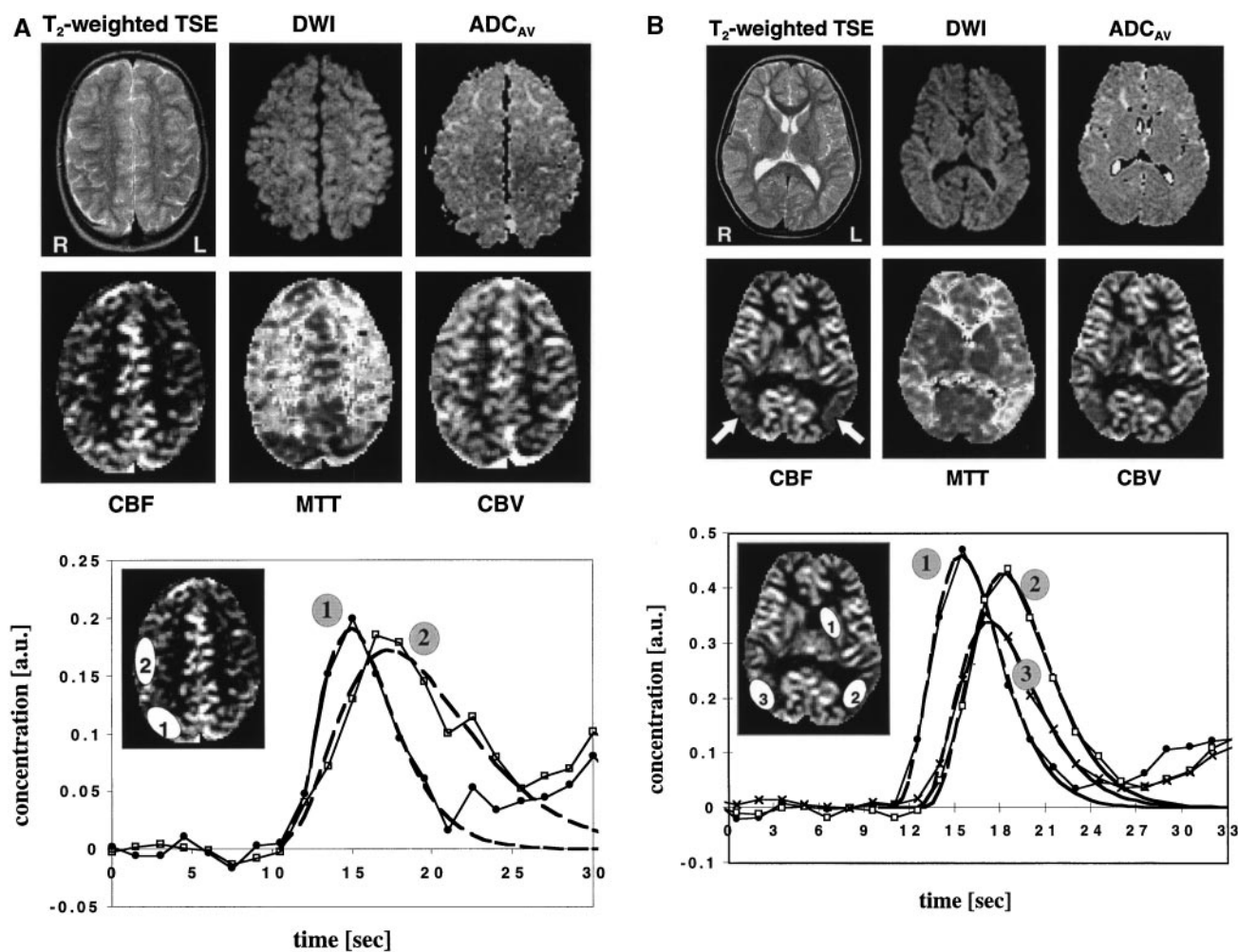


Figure 2. Data from 2 children illustrating a potential problem of using deconvolution analysis. A, Six-year-old boy (patient 6 in the Table). Although the T2/diffusion images shown here were normal (top row), there were extensive bilateral abnormalities, with reduced CBF and prolonged MTT (bottom row). Graph shows the concentration-time course for 2 regions (see inset). B, Twelve-year-old girl (patient 5 in the Table) in whom the deconvolution analysis gives misleading information. The occipital areas were normal on T2/diffusion MRI (top row) but had a hemodynamic abnormality (bottom row, arrows). Graph shows the concentration-time course for 3 regions (see inset). Although both patients show maps with very similar relative decreases in CBF, the actual tissue perfusion status is very different (see text for further details). R indicates right; L, left; and TSE, turbo spin-echo.

tissue perfusion status is very different; the CBF could in fact be normal in patient 5.

Analysis Using Summary Parameters: Visual Inspection

Bilateral abnormalities were seen on visual inspection of the TTP and MPC maps in all patients. Most of these abnormalities comprised prolonged TTP with normal or reduced MPC relative to the cerebellum. Some patients also showed focal areas with reduced TTP and increased MPC after revascularization in cortical areas close to the operative site (eg, see Figure 3, bottom row). There were no abnormalities detected in the cerebellum on visual inspection, even in those patients with posterior circulation involvement. All but 1 patient (patient 3 in category A) had at least 1 hemisphere in which the abnormality affected more than half the middle cerebral artery territory. Although very extensive bilateral abnormalities were seen in all the children in category C, these were also observed in some patients in categories A and B.

Therefore, there was no clear relationship between the extent of abnormality on the TTP and MPC maps and the clinical symptoms.

Analysis Using Summary Parameters: Quantitative Regional Analysis

The Table shows the summary of the results obtained after segmenting the tissue according to its Δ TTP value (eg, see Figure 4). Although most of the patients showed large abnormalities in various summary parameters, the patients in category C (severe) tended to have more severe hemodynamic abnormalities. The general pattern in the children from category C was that of the following: very prolonged Δ BAT (including segments with Δ BAT >5 seconds in 2 of 5 children, exclusively seen in this category); very prolonged Δ TTP (including segments with Δ TTP >7 seconds in 4 of 5 children, exclusively seen in this category); very prolonged Δ PW (including segments with Δ PW >5 seconds in 5 of 5 children, exclusively seen in this category); decreased relative

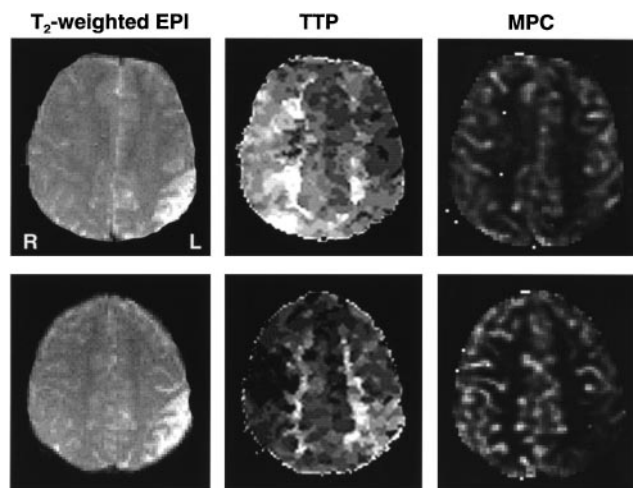


Figure 3. Effect of revascularization on perfusion. T2-weighted EPI (first column), TTP maps (second column), and MPC maps (third column) for an 8-year-old boy with bilateral MMS (category C; patient 9 in the Table). The top row shows the data after left-sided surgery, the bottom row after subsequent right-sided surgery. The T2-weighted images show a chronic left posterior parietal infarct. There is a clear TTP reduction and MPC increase in the right hemisphere after right-sided surgery. The data in the Table correspond to the top row (see Subjects and Methods). R indicates right; L, left.

MPC; increased relative PA; and segmented regions with Δ TTP between 10 and 15 seconds (in 3 of 5 children, exclusively seen in this category). However, some of these characteristics were not exclusive to patients in category C.

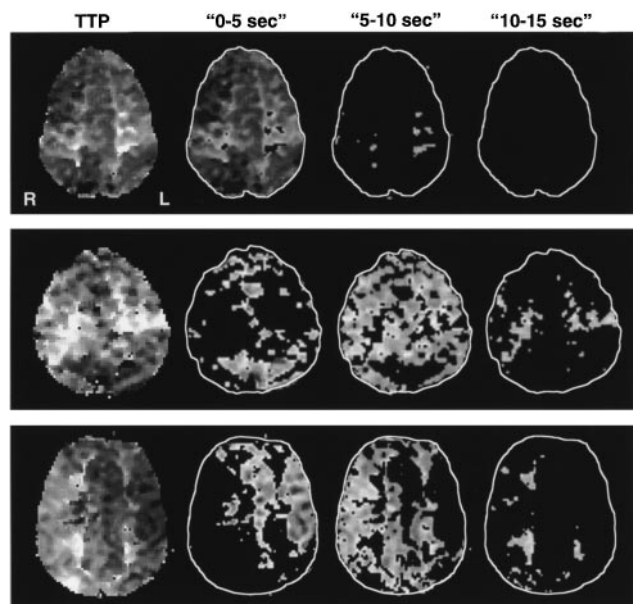


Figure 4. Examples of TTP maps (left column) and segmented regions (second through fourth columns, Δ TTP categories; see Subjects and Methods) from 3 patients. Top row, Sixteen-year-old girl (category A; patient 3 in the Table) with mature left basal ganglia infarct (not shown); scan performed after bilateral revascularization. Middle row, Thirteen-year-old boy (category C; patient 10 in the Table) with normal T2/diffusion imaging after bilateral revascularization. Bottom row, Eight-year-old boy (category C; patient 9 in the Table) with mature left posterior parietal infarct; scan performed after left-sided revascularization. R indicates right; L, left.

Some other patients (1 of 3 in category B and 2 of 5 in category A; see patient 4 in the Table for the worst case) also showed some of these abnormalities, but none had Δ PW >5 seconds.

This quantitative regional analysis suggests that a threshold value of 5 seconds for PW differentiated the most clinically unstable patients (category C) from the rest. Despite the lack of relationship between the extent of the hemodynamic abnormality and the clinical symptoms, only the patients in category C had segmented areas of the brain with Δ PW >5 seconds.

Discussion

Extensive areas of abnormality on the DSC MRI data were observed in all the patients with MMS. This is consistent with previous studies of MMS.^{2,3,6-8} The abnormalities observed were most evident in the arterial border zones and persisted even after surgical revascularization. The abnormalities tended to be more extensive in the most clinically unstable patients, although they were also observed in less clinically severe patients. The distribution of the abnormalities, involving the major arterial border zones, is consistent with a hemodynamic mechanism for ischemia in MMS.¹³

The main dilemma in the management of patients with MMS is the identification of individuals likely to benefit from surgical revascularization, who are most likely to be those with symptomatic cerebral hypoperfusion. However, as found here, the angiographic severity of cerebrovascular disease does not appear to predict the hemodynamic status of tissue. These issues may also be relevant to adults with severe carotid stenosis or occlusion due to atheroma since there is an active debate in the literature regarding any potential benefit from surgical revascularization.¹⁴ Delineation of areas of abnormal tissue perfusion, in combination with clinical symptomatology, may direct the target for revascularization and provide a means of evaluating the efficacy of treatment. As shown in Figure 3, DSC MRI can detect hemodynamic changes after revascularization, indicating which areas have been affected by the surgery. However, interpretation of these findings in terms of true tissue perfusion status is not straightforward since direct comparison of quantitative measures on 2 separate occasions may be misleading (see below).

MMS presents a considerable challenge for measurement of perfusion with MRI. The presence of collateral vessels introduces very large delays (>5 seconds in some of the patients in this study) and likely dispersion to the bolus of contrast agent. These effects are not accounted for in the kinetic model used in the quantification of perfusion,⁴ and therefore the maps generated with the use of deconvolution can be very misleading in that they will tend to underestimate the CBF and overestimate the MTT.⁹ The main problem is the impossibility of measuring the true AIF, which is generally estimated from a large artery (eg, middle cerebral artery or ICA) that, in practice, may be relatively distant from the tissue that is being studied. For MMS, this estimation will be an inaccurate representation of the true AIF. Until a correction for this effect is found (which will require modeling of the vascular bed^{9,15} and generalization of the kinetic model), any maps generated with the use of deconvolution should be

inspected for the presence of significant delay and dispersion before interpretation is attempted. This study has shown that delays as long as 7 seconds are possible in MMS. A continuous range of shorter delays is expected to be possible in other forms of cerebrovascular disease. Therefore, these limitations should also be considered in patients with other forms of occlusive large-vessel disease, such as occlusive carotid artery disease due to atheroma, since these patients may also have significant delay and dispersion of the bolus.^{16,17}

It should be noted that many of these limitations also affect the MR techniques for measuring perfusion with the use of arterial spin labeling.⁴ In particular, the long transit times due to the presence of collaterals is one of the fundamental limitations of arterial spin labeling techniques. Because of the loss of labeling during these long transit times (due to T1 decay), the arterial spin labeling techniques have the potential problem of not being able to differentiate between no flow (CBF=0, no signal in the arterial spin labeling image) and very long transit times (full relaxation of the labeled blood, no signal in the arterial spin labeling image regardless of CBF). Although DSC MRI cannot measure CBF accurately in these situations, it can at least differentiate these cases, which have different clinical implications.

The use of summary parameters as an alternative to the deconvolution analysis of DSC MRI also presents some difficulties in MMS. First, delay and dispersion of the bolus can also affect many of the summary parameters (eg, TTP). Second, none of the summary parameters gives a direct measure of CBF,¹⁸ which makes it difficult to infer the status of the tissue from any of these measures. Therefore, their relative clinical importance remains to be determined. While BAT provides information about the delay in bolus arrival and PA about CBV, all the other parameters can be influenced by many factors (such as AIF, CBF, MTT, and dispersion) in an unknown way. A multivariate analysis (including all the parameters) could indicate which parameters are most clinically useful. This was not possible in the present study because of the relatively small number of children and large number of parameters. Third, they do not take account of differences in AIF between patients and in follow-up studies,¹² and any analysis involving setting up thresholds to differentiate tissue states or compare between maps should be performed with caution. For example, in this study a relatively broad interval was chosen for segmenting the Δ TTP maps (5-second intervals) to reduce the possibility of misclassification of tissue types (Perthen et al¹² reported a Δ TTP variability of \approx 2 seconds for a range of AIFs characteristic of children). Fourth, since all the summary parameters only provide relative information about cerebral hemodynamics, there is an additional difficulty in MMS, in which the abnormalities are often bilateral. For the quantitative analysis performed in this study, a region of interest in the cerebellum was selected as a reference. It should be noted that 4 patients (those with Suzuki stage 4) had posterior circulation involvement. Although there were no abnormalities in the cerebellum detectable on visual inspection of their DSC MRI maps, we cannot discount the possibility of a global reduction in CBF. Therefore, these patients may not have had normal perfusion

in the cerebellum, and, as a result, it is possible that any hemodynamic abnormality in the cerebral hemispheres may have been underestimated. This emphasizes the need for techniques that measure absolute perfusion in bilateral MMS.

Despite these limitations, the quantitative regional analysis performed in this study suggests that the most clinically unstable patients (category C) showed more severe DSC MRI abnormalities. A Δ PW threshold value of 5 seconds appeared to differentiate this group of patients from those in the other categories. A recent study in patients with acute stroke has shown a correlation between the volume of tissue with TTP >4 seconds and the clinical status.¹⁹ However, that study is not directly comparable to our study because ours was concerned with chronic hypoperfusion rather than the functional effects of acute ischemia. Although our data suggest that Δ PW is a good discriminator, sample size was not sufficient to determine the sensitivity and specificity of this classification, and the threshold criterion may need refinement. Furthermore, the ability of perfusion MRI to predict the future clinical course in individual patients remains to be shown.

Apart from the problems with quantification of DSC MRI data in MMS previously discussed, there are a number of other potential issues to be taken into account. The clinical classification that we used categorized patients with frequent TIAs and those with recurrent stroke in the same group. However, these groups of patients may be different in terms of their cerebral hemodynamic status. An important factor not considered in this study is cerebrovascular reserve.²⁰ This may distinguish patients who respond to hemodynamic stress with less severe and more transient symptoms (ie, TIA) from those who are unable to maintain an adequate level of CBF and who develop cerebral infarction under conditions of hemodynamic stress. This suggestion is supported by comparing patient 13, who had 3 cerebral infarcts within a 6-month period, with patient 10, who has TIAs several times each week but has never had any cerebral infarcts. Despite the more aggressive clinical course of patient 13, the DSC MRI data suggest that patient 10 has more extensive and more severe hemodynamic abnormality in the "resting" state. Perfusion MRI could be used to explore this issue by measuring cerebrovascular reactivity in response to carbon dioxide or acetazolamide.²⁰ However, this is not straightforward in MMS because these studies require serial measurements of perfusion (before and after challenge), and all the aforementioned problems of quantification and comparison of perfusion data will also apply.

In conclusion, DSC MRI provides a noninvasive method for the evaluation of regional cerebral perfusion in patients with MMS, with useful clinical applications. However, the technical limitations of DSC MRI described in this study are important for the accurate interpretation of perfusion MRI in MMS. If these issues are not taken into account, misleading results can be obtained, which may lead to erroneous decisions about future treatment. These limitations should also be considered in patients with other forms of occlusive large-vessel disease, such as occlusive carotid artery disease due to atheroma, since these patients may also have significant delay and dispersion of the bolus. It is therefore essential that DSC MRI data are checked for the presence of delays to avoid

misinterpretation of the perfusion maps. Despite these limitations, the findings in this study suggest that the use of quantitative regional analysis of summary parameters can provide clinically useful information in patients with MMS.

Acknowledgments

This study was supported by the Wellcome Trust. Research at the Institute of Child Health and Great Ormond Street Hospital for Children NHS Trust benefits from research and development funding received from the NHS Executive. We thank Dr Martin D. King for helpful discussions and Dr Leif Østergaard for providing the software for the singular value decomposition analysis.

References

1. Suzuki J, Kodama N. Moyamoya disease: a review. *Stroke*. 1983;14:104–109.
2. Ikezaki K, Matsushima T, Kuwabara Y, Suzuki SO, Nomura T, Fukui M. Cerebral circulation and oxygen metabolism in childhood moyamoya disease: a perioperative positron emission tomography study. *J Neurosurg*. 1994;81:843–849.
3. Kuroda S, Houkin K, Kamiyama H, Abe H, Mitsumori K. Regional cerebral hemodynamics in childhood moyamoya disease. *Childs Nerv Syst*. 1995;11:584–590.
4. Calamante F, Thomas DL, Pell GS, Wiersma J, Turner R. Measuring cerebral blood flow using magnetic resonance techniques. *J Cereb Blood Flow Metab*. 1999;19:701–735.
5. Baird AE, Warach S. Magnetic resonance imaging of acute stroke. *J Cereb Blood Flow Metab*. 1998;18:583–609.
6. Tzika AA, Robertson RL, Barnes PD, Vajapeyam S, Burrows PE, Treves ST, Scott RM. Childhood moyamoya disease: hemodynamic MRI. *Pediatr Radiol*. 1997;27:727–735.
7. Tsuchiya K, Inaoka S, Mizutani Y, Hachiya J. Echo-planar perfusion MR of moyamoya disease. *AJNR Am J Neuroradiol*. 1998;19:211–216.
8. Yamada I, Himeno Y, Nagaoka T, Akimoto H, Matsushima Y, Kuroiwa T, Shibuya H. Moyamoya disease: evaluation with diffusion-weighted and perfusion echo-planar MR imaging. *Radiology*. 1999;212:340–347.
9. Calamante F, Gadian DG, Connelly A. Delay and dispersion effects in dynamic-susceptibility-contrast MRI: simulations using singular value decomposition. *Magn Reson Med*. 2000;44:466–473.
10. Østergaard L, Weisskoff RM, Chesler DA, Gyldensted C, Rosen BR. High resolution measurement of cerebral blood flow using intravascular tracer bolus passages, part I: mathematical approach and statistical analysis. *Magn Reson Med*. 1996;36:715–725.
11. Starmer CF, Clark DO. Computer computations of cardiac output using the gamma function. *J Appl Physiol*. 1970;28:219–220.
12. Perthen JE, Calamante F, Gadian DG, Connelly A. Is quantification of bolus-tracking MRI reliable without deconvolution? *Magn Reson Med*. In press.
13. Ringelstein EB, Stogbauer F. Border zone infarcts. In: Bogousslavsky J, Caplan LR, eds. *Stroke Syndromes*. Cambridge, UK: Cambridge University Press; 2001:564–582.
14. Bamford J. Risk stratification and carotid surgery: new technology but old trials. *Brain*. 2001;124:455–456.
15. Østergaard L, Chesler DA, Weisskoff RM, Sorensen AG, Rosen BR. Modeling cerebral blood flow and flow heterogeneity from magnetic resonance residue data. *J Cereb Blood Flow Metab*. 1999;19:690–699.
16. Lythgoe DJ, Østergaard L, Williams SCR, Cluckie A, Buxton-Thomas M, Simmons A, Markus HS. Quantitative perfusion imaging in carotid artery stenosis using dynamic-susceptibility contrast-enhanced magnetic resonance imaging. *Magn Reson Imaging*. 2000;18:1–11.
17. Neumann-Haefelin T, Witsack H-J, Fink GR, Wenserski F, Li T-Q, Seitz RJ, Siebler M, Mödder U, Freund H-J. Diffusion- and perfusion-weighted MRI: influence of severe carotid artery stenosis on the DWI/PWI mismatch in acute stroke. *Stroke*. 2000;31:1311–1317.
18. Weisskoff RM, Chesler D, Boxerman JL, Rosen BR. Pitfalls in MR measurement of tissue blood flow with intravascular tracers: which mean transit-time? *Magn Reson Med*. 1993;29:553–559.
19. Neumann-Haefelin T, Witsack H-J, Wenserski F, Siebler M, Seitz RJ, Mödder U, Freund H-J. Diffusion- and perfusion-weighted MRI: the DWI/PWI mismatch region in acute stroke. *Stroke*. 1999;30:1591–1597.
20. Derdeyn CP, Grubb RL Jr, Powers WJ. Cerebral hemodynamic improvement: methods of measurement and association with stroke risk. *Neurology*. 2000;53:251–259.

MR Perfusion Imaging in Moyamoya Syndrome: Potential Implications for Clinical Evaluation of Occlusive Cerebrovascular Disease

F. Calamante, V. Ganesan, F.J. Kirkham, W. Jan, W.K. Chong, D.G. Gadian and A. Connelly

Stroke. 2001;32:2810-2816

doi: 10.1161/hs1201.099893

Stroke is published by the American Heart Association, 7272 Greenville Avenue, Dallas, TX 75231

Copyright © 2001 American Heart Association, Inc. All rights reserved.

Print ISSN: 0039-2499. Online ISSN: 1524-4628

The online version of this article, along with updated information and services, is located on the World Wide Web at:

<http://stroke.ahajournals.org/content/32/12/2810>

Permissions: Requests for permissions to reproduce figures, tables, or portions of articles originally published in *Stroke* can be obtained via RightsLink, a service of the Copyright Clearance Center, not the Editorial Office. Once the online version of the published article for which permission is being requested is located, click Request Permissions in the middle column of the Web page under Services. Further information about this process is available in the [Permissions and Rights Question and Answer](#) document.

Reprints: Information about reprints can be found online at:
<http://www.lww.com/reprints>

Subscriptions: Information about subscribing to *Stroke* is online at:
<http://stroke.ahajournals.org/subscriptions/>



Closing the Gap in Pediatric Hemorrhagic Stroke: A Systematic Review

Samyami S. Chowdhury, BSc(hons), MBChB, MRCPCH,* Alfred P. See, MD,[†]
Lars P. Eriksson, BA, Grad Dip Lib,[‡] Gregoire Boulouis, MD, MPH, PhD,[§]
Laura L. Lehman, MD, MPH,[†] Dana B. Hararr, MD, PhD,^{||} Veda Zabih, MPH,*
Nomazulu Dlamini, MD, MBBS, MRCPCH, MSc (Lon), PhD,* Christine Fox, MD, MAS,[¶] and
Michaela Waak, MD, FCICM, FRACP,^{‡,**}

Pediatric hemorrhagic stroke (HS) accounts for a large proportion of childhood strokes, 1 of the top 10 causes of pediatric deaths. Morbidity and mortality lead to significant socio-economic and psychosocial burdens. To understand published data on recognizing and managing children with HS, we conducted a systematic review of the literature presented here. We searched PubMed, Embase, CINAHL and the Cochrane Library databases limited to English language and included 174 studies, most conducted in the USA (52%). Terminology used interchangeably for HS included intraparenchymal/intracranial hemorrhage, spontaneous ICH, and cerebrovascular accident (CVA).

Key assessments informing prognosis and management included clinical scoring (Glasgow coma scale), and neuroimaging. HS etiologies reported were systemic coagulopathy (genetic, acquired pathologic, or iatrogenic), or focal cerebrovascular lesions (brain arteriovenous malformations, cavernous malformations, aneurysms, or tumor vascularity). Several scales were used to measure outcome: Glasgow outcome score (GOS), Kings outcome score for head injury (KOSCHI), modified Rankin scale (mRS) and pediatric stroke outcome measure (PSOM). Most studies described treatments of at-risk lesions. Few studies described neurocritical care management including raised ICP, seizures, vasospasm, or blood pressure.

Predictors of poor outcome included ethnicity, comorbidity, location of bleed, and hematoma >2% of total brain volume. Motor and cognitive outcomes followed independent patterns. Few studies reported on cognitive outcomes, rehabilitation, and transition of care models. Interdisciplinary approach to managing HS is urgently needed, informed by larger cohort studies targeting key clinical question (eg development of a field-guide for the clinician managing patients with HS that is reproducible internationally).

Semin Pediatr Neurol 43:101001 © 2022 Elsevier Inc. All rights reserved.

Introduction

Hemorrhagic stroke accounts for half of strokes in children which occur at 1.2 to 8 per 100,000 per year.¹⁻³

From the *The Hospital for Sick Children, Toronto, Canada.

[†]Boston Children's Hospital, Boston, MA.

[‡]The University of Queensland, Australia.

[§]University Hospital of Tours (CHRU de Tours), Paris, France.

^{||}National Children's hospital, Washington, DC.

[¶]Benioff Children's Hospital, San Francisco, CA.

^{**}Children's Health Queensland Hospital, Brisbane, Australia.

Address reprint requests to Samyami S. Chowdhury, The Hospital for Sick Children, 555 University Avenue, Toronto, Ontario, M5G 1X8, Canada.
E-mail: samyami.chowdhury@sickkids.ca

Etiologies are divided into cerebrovascular lesions (eg bAVM, aneurysms, cavernomas), hematological disease, intracerebral pathologies that increase risk of bleeding (eg oncological, infection, inflammation), systemic disease states or treatments that increase risk of bleeding (eg conditions effecting vasculature, necessitating systemic anticoagulation) and rare genetic disorders. Individual characteristics of specific etiologies (eg aneurysm morphology) as well as nuances of these etiologies (eg type of vascular malformations) differ between pediatrics and adults, thus requiring an alternative approach to diagnosis and management. Outcome trajectories are unique to the brain development in childhood (acquisition of skills and attaining milestones), in

contrast to adults with recovery of lost function.⁴ Health economic impacts of HS on the child and family are significant.⁵ Whilst robust studies in pediatric ischemic stroke have established evidence-based practice and protocols that are internationally accepted,⁶⁻⁸ in hemorrhagic stroke this is still an understudied, developing area.

Aims

- 1) Provide description of standardized methods to determine etiology of intracerebral hemorrhage.
- 2) Describe management decision methods.
- 3) Identify long term outcomes and rehabilitation needs for survivors of ICH.
- 4) Assess current diagnostic, treatment, and management approaches described globally and identify challenges in practice to inform future directions. This could inform consensus-based guidance for managing HS, minimal data sets and precise definitions.

Methods

Data sources and search strategy

This review followed the Preferred Reporting Items for Systematic reviews and Meta-Analyses (PRISMA)

guidelines (see supplementary section for access to full protocol). We searched PubMed, EMBASE, CINAHL and EBM Reviews-Cochrane library databases from inception to January 2022. Search terms were developed in consultation with a literature search expert. Search strategy combined terms related to pediatric population and domain or disease specific terms (haemorrhagic stroke, cerebral haemorrhage). Details of the search strategy in [Figure 1](#) and [supplementary section](#).

Screening and study selection

Studies were selected if they met the inclusion criteria: 1) Original research studies that reported diagnosis (including bleeding prediction of unruptured bAVM or aneurysm), treatment, or outcomes of haemorrhagic stroke as a result of intracerebral hemorrhage, intraparenchymal haemorrhage, ruptured aneurysms or arteriovenous malformations 2) Studies that recruited children >28 days - <18 years or a subset of age criteria 3) >10 relevant patients reported 4) Cohort studies, randomized controlled trials, case-control studies 4) Studies published in English language. We excluded studies related to microhaemorrhages in children on ECMO (Cardiac/Pulmonary), traumatic intracerebral haemorrhage, exclusive extradural

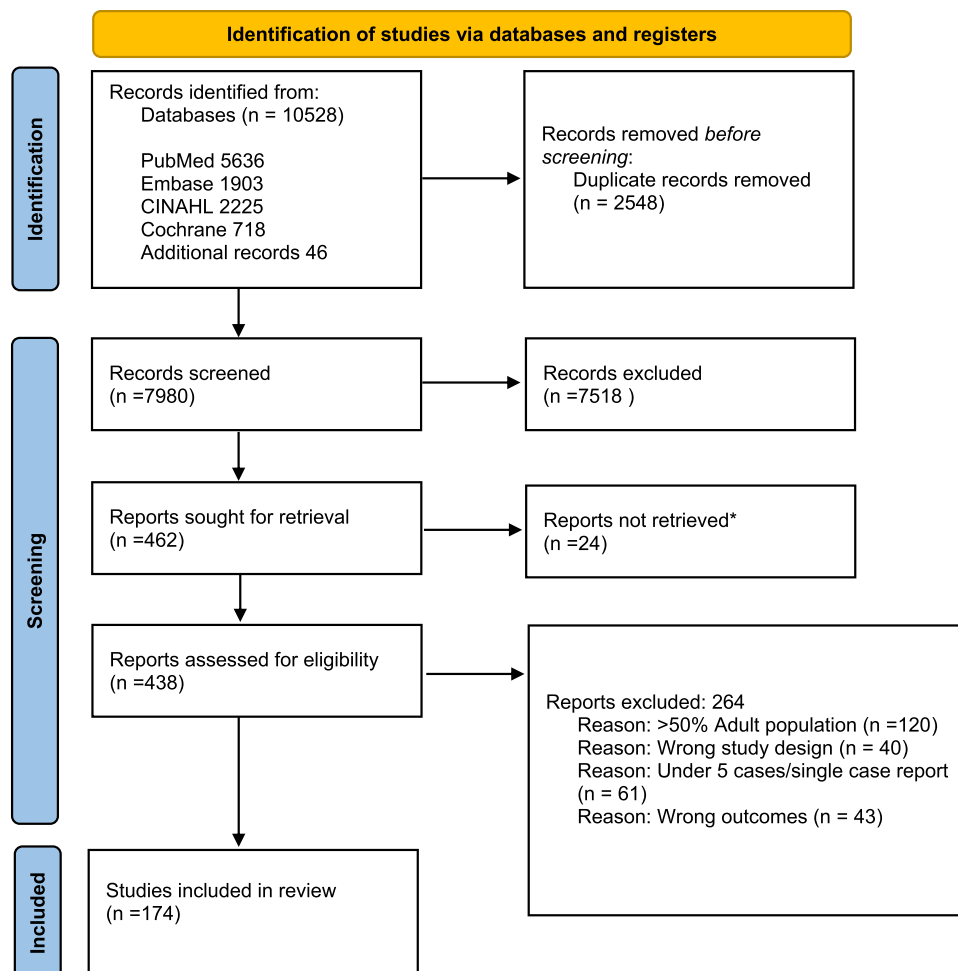


Figure 1 Prisma Protocol. (Color version of figure is available online.)

and subdural hemorrhage and hemorrhage related to cerebral venous sinus thrombosis.

Two authors (SSC, APS) independently examined titles and abstracts to identify eligible studies. Similarly, 2 authors (SSC, APS) reviewed full texts for eligible studies independently and involved a third author (VZ/MW) if needed to resolve any discrepancies. References of included publications were screened for relevant publications; thirty articles were included based on their sentinel nature.

Data extraction and analysis

The research team collectively developed a standardized charting form that included all relevant data to be extracted from studies. This included study title, year of publication, sample size, data related to diagnosis of haemorrhagic stroke, treatment modalities and outcomes reported. The charting form was piloted on a small sample of studies and iteratively updated as required. Using the charting form, each author (SSC, APS) independently abstracted the information from each article included. This information was then verified and checked for accuracy by a third author (MW).

Quality Assessment

See supplementary section

We used the Newcastle-Ottawa Quality Assessment Scale to assess risk of bias in studies. Overall, the quality of reporting is heterogenous and low for pediatric HS literature. The risk of bias is high to very high in most studies with very few scoring 9 out of 9. Most did not score for the outcomes section.

Search results

Our search identified 10528 studies prior to modification. After removing duplicates, the remaining 7980 titles and abstracts were screened (Fig. 1). 438 studies were identified for full text review. 174 studies met our inclusion criteria. Most studies are retrospective with only 2% prospective studies (Fig. 2).

Study Characteristics

Children >28 days - 18 years were included, no restrictions on time-period or location (Fig. 3). Both ruptured and unruptured aneurysms and bAVMs were included as risk of hemorrhagic stroke and stroke prevention were considered crucial questions.

Results

Definition

Definitions used were variable, most studies referred to HS as intracerebral hemorrhage (ICH), some defined ICH as evidence of hemorrhage on brain imaging study with further classification into the HS subtypes^{2,9,10,11}

Hemorrhagic stroke was referred interchangeably as intraparenchymal hemorrhage (IPH), spontaneous ICH (sICH), pediatric ICH (pICH) or cerebrovascular accident and further classified into traumatic or non-traumatic. Agreed classification and scoring systems for aneurysms and bAVMs that were uniformly used included Hunt and Hess and Spetzler-Martin grades. Demographics were dependent on etiology

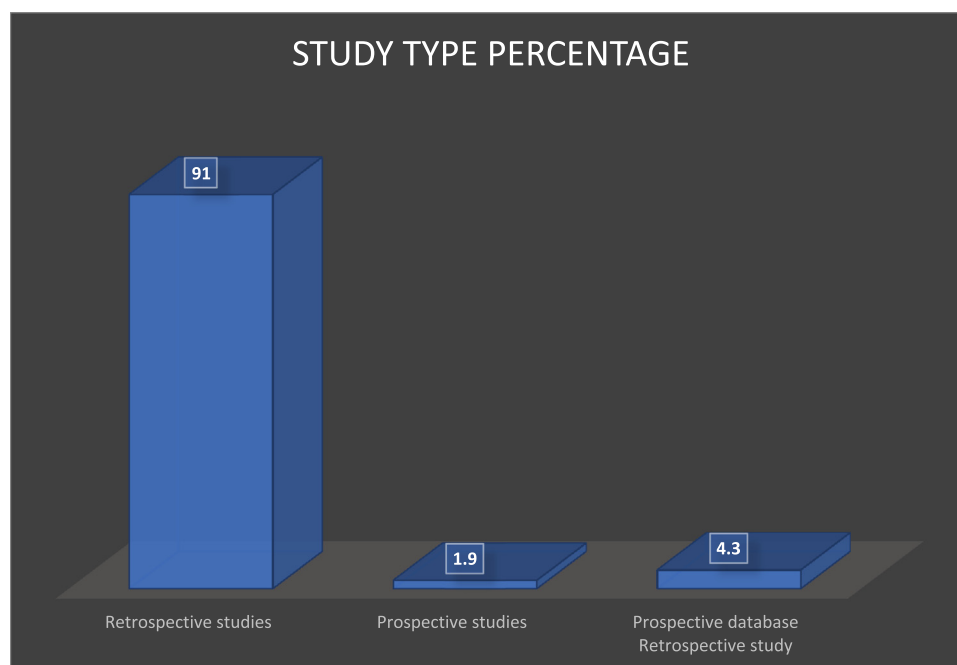


Figure 2 Percentage of type of study conducted in studies eligible for inclusion. (Color version of figure is available online.)

PEDIATRIC HEMORRHAGIC STROKE STUDIES ELIGIBLE FOR SYSTEMATIC REVIEW

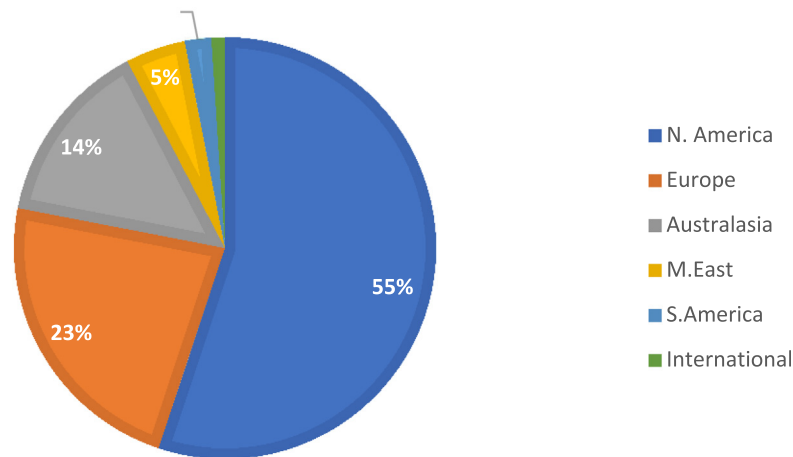


Figure 3 Global representation of studies in pediatric hemorrhagic stroke included in the systematic review. (Color version of figure is available online.)

with limited geographic patterns noticed in North America and specific countries.¹²

Etiology and risk factors

Causes of hemorrhagic stroke included bAVM, aneurysms, cavernous malformations, tumors, infection, intrinsic hematological (hemophilia A, ITP,^{13,14} Sickle cell disease, vitamin K deficiency), iatrogenic hematological (most commonly with ECMO, but also chemotherapeutics), cerebral proliferative angiopathy and rare genetic causes. Estimate of incidence in each category of etiology except tumors, was not well reported, highly variable and dependent on histopathological or genetic diagnosis.^{2,15-20}

Predisposing factors were categorized as inherited or acquired. Common comorbidities included genetic or vascular abnormalities, cardiac disease, collagen tissue disorder, hematological risk factors (lupus anticoagulant, protein C and S deficiencies) and inborn errors of metabolism.^{2,14-16,21} Although we excluded studies only reporting microhemorrhages during ECMO, we did note that children had increased risk of clinically significant ICH associated with ECMO (elevated clotting times and thrombocytopenia noted).¹⁵ Significantly, ICH as a complication of ITP was reported to have 55% mortality in a retrospective analysis of 75 children,²² mortality remained high even when treatment with steroids, intravenous immunoglobulin or splenectomy occurred.

Most studies did not address the important distinction in the difference in etiology of hemorrhage in children compared to adults, in whom associations like hypertension (3-9-fold relative-risk)^{23,24} or smoking (1.5 fold relative risk)²⁵ are more commonly found.

Risk of rupture in bAVMs

Angioarchitecture, location, size of nidus and venous drainage predict risk of early vs late rupture. In a cohort study by Garzelli et al,¹⁹ pediatric AVMs were more frequently deeply

located with a larger nidus. Deep bAVMs with exclusively deep venous drainage were associated with earlier rupture. However, studies are retrospective, and commonly critiqued as studying lesions after hemorrhage does not allow 1 to characterize the pre-hemorrhage lesion or identify structural or even pathophysiological attributes that contribute to rupture. The most robust prospective study of bAVM is in adults (ARUBA),²⁶ but remains debated and conclusions in the unruptured adult bAVM population evaluated are not generalizable to the pediatric population with ruptured bAVM.

Risk of rupture in aneurysms

Aneurysm re-rupture rate is thought to be highest in the early subarachnoid hemorrhage period. However, this data is derived from studies in adults. Re-rupture has been observed in about 6% of patients in the first 24 hours, another 1.2% between 1 and 3 days, even at centers providing early aneurysm treatment. If untreated,^{27,28} aneurysm rupture is reported as 30% during the first month, and an additional 7% between the first and third months.

Increased risk has been associated with posterior circulation location, large aneurysms, and poor presenting Fisher grade.^{28,29} The risk of provoking re-hemorrhage by treating acute hydrocephalus with an external ventricular drain is debated.²⁸

The most robust studies in treatment of ruptured aneurysms are the International Subarachnoid Aneurysm Trial (ISAT)^{30,31} and the Barrow Ruptured Aneurysm Trial (BRAT),³² which did not include patients under 18 years of age. Endovascular treatment was associated with a relatively better functional outcome based on mRS, particularly in cases involving the posterior circulation, but in BRAT this benefit diminished with time, and in both studies endovascular treatment had an increased rate of recurrence and need for retreatment. Both studies have reported 10-year outcomes.^{32,33} While BRAT suggests an increased rate of fatal hemorrhage with incompletely treated aneurysms from the

endovascular approach, ISAT found that death, and a composite of death and dependency were more likely in patients treated with surgical clipping of ruptured aneurysms.^{30,33}

Ruptured aneurysms in children usually benefit from treatment to decrease long term morbidity. In series of aneurysms treated in children, treatment techniques validated in adults appear to have similar upfront effectiveness; however, the different biology of certain brain aneurysms in children indicate a lifetime risk of further aneurysm formation and need for long term follow-up as well as large international registries and biobanks to explore risk factors and genetics^{34,35}

Presentation

Reported signs and symptoms included headache, vomiting, visual disturbances, altered consciousness, coma (all signs of raised of ICP), seizures, focal motor deficit, cerebellar signs, cranial nerve compression and encephalopathy.^{36,37} Some reports suggest that presentation patterns are associated with location distribution eg in bAVM.^{38,39} Asymptomatic patients (usually at time of radiosurgery) as well as severely symptomatic children were reported.^{40,41}

Systems/pathways used for initial clinical assessment

Most studies did not document the child's pre-morbid state or baseline neurological assessments. One study characterized 20 children at initial evaluation with baseline Glasgow coma scale (GCS) and evolution of symptoms at neurological presentation (time of acute symptom onset), pre-hospital and in hospital⁴² Cincinnati Prehospital Stroke Scale (CPSS) and Recognition of Stroke in the Emergency Room (ROSIER) were most reported. Of note, Mackay et al⁴³ showed that CPSS and ROSIER do not accurately distinguish strokes from stroke mimics. ROSIER was positive in 36% of haemorrhagic strokes and 27% of stroke mimics such as migraine. CPSS was positive in 26% of HS and 23% of stroke mimics. This study highlighted that adult stroke recognition tools are insufficient for differentiating stroke from mimics in

children, identifying an important research gap. Studies did not provide initial or follow up pediatric NIHSS.

Diagnostic work-up

Neuroimaging

Imaging studies reported CT (+/- contrast), MRI, MRA and catheter angiogram (DSA), used in various combinations at varying time points, to identify HS and evaluate for underlying cause⁴⁴ CT (+/- contrast) was often utilized as initial diagnostic neuroimaging, followed by MRI. Some studies highlighted a clear imaging pathway for both acute and follow up neuroimaging (see detailed description in the review by Mirsky et al).⁴⁴⁻⁴⁶ Follow-up imaging in 1 center⁴⁷ consisted of follow-up MRA without contrast in incidental, untreated intracranial aneurysms. Reported determinants of follow up neuroimaging were complexity of the neurovascular abnormality and treatment modality. DSA was recommended for aneurysmogenesis and CTA for clipped intracranial aneurysms.⁴⁷ Contrast MRA is recommended for endovascular coiling or following microsurgery. Catheter angiography is considered the gold standard of investigation to evaluate for underlying neurovascular lesion and describe the angioarchitecture across multiple studies.^{45,48} Imaging is determined by suspected HS etiology, acuity of symptoms, patient age and locally available resources but should include an MDT approach to support decision making.⁴⁸

Genetic workup

The expanding spectrum of genetic associations in bAVM and aneurysms provides an important step in the diagnostic work-up of hemorrhagic stroke. Genes that are commonly associated with bAVM and aneurysms have been well described.⁴⁹

Associated genes in bAVM include SMAD4, RASA1, ENG and ACVRL/ALK1 (Table 1A). The role of these genes in abnormal angiogenic remodeling of primary capillary plexus, is an important potential therapeutic target. Brain aneurysms are also associated with many genetic syndromes listed in the Table 1B adapted from Guerrero et al. There is little data or

Table 1A Associated Genetic Syndromes with Mutated Genes in Brain AVMs Adapted from Guerrero et al.⁴⁹

Genetic Syndrome Associated Mutated Gene

Hereditary hemorrhagic telangiectasia (HHT)

HHT1

HHT2

Juvenile polyposis-HHT overlap

Capillary malformation-arteriovenous Malformation

Autosomal dominant/sporadic in 30%

Parkes-Weber's syndrome

Autosomal dominant/sporadic

Wyburn-Mason's syndrome

ENG Autosomal dominant

ACVRL/ALK1

SMAD4

RASA1 RAS p21 protein activator

RASA1 RAS p21 protein activator

Table 1B Genetics Syndromes Associated With Aneurysms. Autosomal Recessive (AR), Autosomal Dominant (AD), X-Linked Recessive (XLR)

Genetic Syndrome

- Fibromuscular dysplasia
- Klippel–Trenaunay–Weber syndrome
- a-Glucosidase deficiency autosomal recessive (AR)
- a1-Antitrypsin deficiency AR
- Alkaptonuria AR
- Anderson-Fabry disease X-linked recessive XLR
- Autosomal polycystic kidney disease AD
- Ehlers-Danlos syndrome type IV AD
- Familial idiopathic non-arteriosclerotic cerebral calcification syndrome
- Hereditary hemorrhagic telangiectasia AD
- Marfan's syndrome AD
- Neurofibromatosis type 1 AD
- Noonan's syndrome AD
- Pseudoxanthoma elasticum AD, AR
- Tuberous sclerosis AD
- Wermer's syndrome (multiple endocrine neoplasia type 1) AD
- 3M syndrome

literature to guide the timing of or agreed consensus approach to incorporating genetic investigations into the workup of a child with hemorrhagic stroke.

Management

Medical

Few studies included neurocritical care aspects of managing HS^{37,50-53} such as neuroprotection, management of vasospasm^{54,55} and seizures. Blood pressure measurement on presentation and follow up were described by Lo et al,³⁷ and designated as elevated if the BP exceeded the 90th centile. Generic principles include maintaining cerebral perfusion pressure (pre-intubation mean arterial blood pressure) in cases of suspected or confirmed raised ICP⁵⁶ which needs to be balanced with rebleeding^{56,57} risk; especially in high-risk lesions eg unsecured aneurysms.

Management approach to seizures and neuroprotection follow generic recommendations for acquired brain injury and traumatic brain injury rather than specific pathology driven recommendations. Evolving adult evidence suggests that EEG monitoring and aggressive management of clinical and electrographic-only seizures significantly impacts^{58,59} outcome in patients⁶⁰⁻⁶² with HS and SAH as randomized controlled trial evidence from the SPICH and PEACH⁶³ trials are awaited. In the interim the AHA, NCC and ESO guidelines offer guidance.^{64,65} There are few reports of use of nimodipine in children with findings similar to the adult literature reported, of no statistically significant improvement in vasospasm rate but potentially improved short-term outcomes (Table 2).^{66,67}

Gaps in knowledge

Recent adult data suggest early administration of Tranexamic acid (TXA) may reduce mortality and rebleed rate.⁶⁸ The TICH-2 study (Tranexamic acid for hyperacute primary Intracerebral haemorrhage) administered TXA within 8 hours of the acute event, concluded no effect on adult patient's functional status at 90 days after ICH, despite there being significant modest reductions in early death (by 7 days) and hematoma expansion.⁶⁸ In adults, TXA was safe, with no increase in thromboembolic events. At the time of this review, we did not find any data on the safety or use of TXA in children.

Studies of antiseizure medication (ASM) to prevent seizures were also limited. Both Levetiracetam and Fosphenytoin have shown to be well tolerated, with Levetiracetam showing an effectiveness advantage in a cohort study of 126 patients.⁶⁹

Gaps in knowledge: Prospective studies are required to determine use, choice, dosing, and duration of prophylactic ASMs⁶⁹ as well as meaningful blood pressure targets and an understanding of how to provide best practice neuroprotection. Trials in adults for correction of hematological abnormalities with use of recombinant activated factor VII (rFVIIa) have not included children.

Monitoring

No reports of transcranial doppler (TCD) or cross-sectional imaging monitoring for vasospasm⁷⁰ is available outside of small cohort studies reporting use of nimodipine.⁷¹ The use of cerebrovascular reactivity (CVR) was reported by Schaller et al.⁷² which showed that altered vasoconstriction after AVM resection affects the cortex due to patchy hypoperfusion caused by physiological phenomena. Indices included standard deviation of heart rate (HRsd), root-mean-square of successive differences in heart rate (HRmssd), low–high frequency ratio (LHF), and baroreflex sensitivity (BRS). Another cohort study reported CA indices (pressure reactivity, wavelet pressure reactivity, pulse amplitude index, and correlation coefficient between intracranial pressure pulse amplitude and cerebral perfusion pressure) and percent time of cerebral perfusion pressure below lower limits of autoregulation are associated with poorer outcomes.⁷³ EEG monitoring^{74,75} remains crucial for both seizure detection^{74,76} as well as detection and^{77,78} early management of vasospasm following SAH.^{59,79-83}

Gaps in knowledge

Incidence of acute symptomatic seizures as well as SAH and cerebral vasospasm contributing to secondary brain injury necessitating multimodal monitoring, especially EEG with potential quantitative techniques, require multicenter studies to elucidate benefit.⁸⁴

Surgical intervention for management of acute intracranial hypertension

In the absence of randomized trials for intracranial pressure monitor placement, ventricular drainage, or craniectomy in

Table 2 Summary of Papers Regarding Neurocritical Management

| First Author | Journal | Year | Reference | Neurocritical Management |
|-----------------------------|------------------------------------|------|---|--|
| Beslow ⁵³ | Stroke | 2010 | Predictors of Outcome in Childhood Intracerebral Hemorrhage; A Prospective Consecutive Cohort Study | Six (27%) received either hypertonic saline or mannitol. Three (14%) were hyperventilated. Moderate therapeutic hypothermia was instituted in 2 (9%). Six (27%) required ventriculostomy. Three (14%) underwent decompressive hemicraniectomy |
| Beslow ⁵¹ | JAMA Neurology | 2013 | Pediatric intracerebral hemorrhage: Acute symptomatic seizures and epilepsy | Anti-Seizure Medications (ASM) for raised ICP |
| Meyer ⁴² | Canadian Journal of Anesthesia | 2000 | Emergency management of deeply comatose children with acute rupture of cerebral arteriovenous malformations | ICP management: Moderate hypocapnia PaCO ₂ short term target: 30-35 mmHg Osmotherapy: In life-threatening brain herniation, rapid infusion of mannitol 20% OR 3 ml/kg– 1 hypertonic saline 7.5% solution (max plasma osmolarity 300-310 mosmol/kg) is effective in lowering raised ICP. |
| Piastra et al ⁵⁰ | Journal of Intensive Care Medicine | 2019 | Clinical Outcomes and Prognostic Factors for Spontaneous Intracerebral Hemorrhage in Pediatric ICU: A 12-Y Experience | Direct ventricular puncture ICP management Moderate hypocapnia: short-term target PaCO ₂ 34-36mm Hg; avoid longer term hypocarbia, utilize capnometry Maintain cerebral perfusion pressure (CPP): vasoactive agents, arterial BP monitoring, ICP monitoring Prevent seizures: ASMs in 68.2% of patients (iv phenobarbital, midazolam infusion) Avoid hyperglycemia: Insulin infusion, target glucose levels <150 mg/dL Avoid Hyperthermia: target temperature 36C - 37C |

children, surgical management of intracranial pressure is based on extrapolated principles from adult studies. These include intracerebral/-ventricular hemorrhage, traumatic brain injury and malignant cerebral edema ischemic stroke.^{85,86} Resourcing and local preference (eg north America with high rates (71%) of invasive ICP monitoring capability, predominately through external ventricular drains (98%) or intraparenchymal monitors (90%), and fewer than 20% tissue oxygenation probes impact on decision making either by-case basis or protocol-driven by the intensivist and neurosurgeon.⁸⁷

Lopresti et al. reported the outcomes of 35 patients from 2005-2018 who underwent decompressive craniectomy after AVM rupture.⁸⁸ After 3 years, 89% of children had an mRS of 2 or less, were considered functionally independent, and all had returned to school. However, the data confirms principles of excellent functional recovery following decompressive craniectomy for focal brain lesions even in the setting of acute life-threatening intracranial hypertension.

Gaps in knowledge: In the absence of randomized trials for intracranial pressure monitor placement, ventricular

drainage, or craniectomy in children; surgical management of intracranial pressure is typically based on extrapolated principles from adult studies, recommending ICP monitoring and consideration of early decompressive craniectomy,^{85,86} prospective multicenter registry studies in pediatrics are needed.

Surgical interventions for prevention of re-hemorrhage

Most studies revealed that management was determined by expert opinion guided by the etiology. Generalization of these results is limited by the retrospective nature of studies that prevents protocolized patient selection or surgical decision-making. The timeframe of surgical intervention varied, reflecting differing risk of recurrent hemorrhage between types of vascular lesions.⁸⁹ The re-rupture risk for aneurysms is higher in the weeks following initial rupture than later, when the rupture risk returns to a baseline level.⁹⁰ AVMs are also thought to have a higher re-rupture rate early on, although the magnitude of this increase is less dramatic and is measured on the order of a year.⁸⁹ The early re-hemorrhage rate of other lesions is less well described.

Brain aneurysms

Adult aneurysm care is guided by international studies in the natural history of unruptured and treatment outcomes of ruptured aneurysms,^{31,30} and randomized trials for specific newer endovascular devices.⁹¹ Aneurysm treatment after rupture in children has not been studied in a prospective trial. Small retrospective series and meta-analyses of various techniques were included here^{92,93} Middle cerebral artery aneurysms in children: case series and review.^{35,94}

Ruptured aneurysm treatment with microsurgical or endovascular techniques in children, including clipping, bypass, vessel occlusion, coil embolization, flow diversion, liquid embolization, or endovascular vessel sacrifice have been reported. Meta-analyses have shown good long-term outcomes (mRS ≤ 2) in >70% of children surgically treated following aneurysm rupture, but only 50% good outcome if untreated.^{94,92}

Treatment with endovascular vs microsurgical techniques achieved similar outcomes.⁹⁴ The key determinant of outcome at long term follow-up was the presenting Hunt-Hess Score (presenting score of 1-3 associated with 88% likelihood of independent mRS, compared to 44% for a poor presenting score of 4 or 5.⁹⁴

At 1 institution, there was a recurrence rate of 8%,⁹⁵ although the tools and techniques in the endovascular portion of that series would now be considered outdated.

While most studies pooled different endovascular or microsurgical techniques^{93,95} flow diversion has been studied via meta-analysis and registry reporting.⁹⁶ A meta-analysis of aneurysm treatment in 24 studies including 37 children with aneurysms⁹² showed a complication rate of 21%, including 2 (5%) deaths, 2 (5%) residual aneurysms, and 4 (11%) parent vessel occlusions. These rates were similar to data from a registry of 39 patients in 16 institutions (2 patients with ruptured aneurysms who died from re-rupture despite treatment with flow diversion). In the registry, 28 (72%) patients had an mRS ≤ 2 , 5% had parent vessel occlusion, and 6% required re-treatment with an additional flow diverter. The studies did not separately report on ruptured aneurysms. A high complication rate may be due to the inclusion of posterior circulation aneurysms, dissecting aneurysms, and fusiform aneurysms, all of which are associated with higher complexity and increased technical difficulty.

Adult data from BRAT and ISAT suggest re-rupture rates on the order of 0 - 0.5 per 1000 patient-years for clipped aneurysms, and 1.56 per 1000 patient-years for endovascularly treated aneurysms.^{33,32} A retrospective study of 32 children reported that 14% of endovascular treatments and 0% of microsurgical treatments required aneurysm re-treatment, but new aneurysms formed in 20% of these patients over 6-year follow-up.³⁵ Although this is a small retrospective study, similar results to the large scale adult studies (0.8% of microsurgical, 20% of endovascular) is reassuring.

Gaps in knowledge: Direct comparisons of endovascular vs microsurgical treatment of ruptured aneurysms in children is lacking.

Meta-analyses are subject to limited reporting details, non-standardized patient selection, technique, and mixed patient

populations. Registry reports which may pool data prospectively from more institutions to address some of these problems could be utilized. Recurrence remains poorly described. Novel devices are not being studied.

Brain AVMs

Brain AVM treatment involves multiple modalities: medical optimization, microsurgery, radiation therapy, and endovascular embolization. Although microsurgery and radiation therapy largely aim to achieve cure, endovascular approaches have a wide range of techniques and procedural goals.¹³⁹ Endovascular approaches can be used to modulate high-risk features after hemorrhage, such as AVM-associated aneurysms, as an adjunct to microsurgical or radiation treatments, and in some cases have been used as a monotherapy with the aim of cure.^{97,45}

A review and meta-analysis of ruptured AVM studies through 2020 found a pooled AVM recurrence rate of 11% after treatment, but those with surgical treatment had a lower recurrence of 7%.⁹⁸ AVM recurrence is clinically significant, with a third of recurrences presenting with hemorrhage. Ruptured AVMs may show variable recurrence rates when treated acutely at the time of bleed with elevated ICP. For example, higher rates of residual lesions were present, when AVMs were resected at the time of decompressive craniectomy. Further intervention at follow-up did achieve a final cure rate (> 95%). A mixed cohort of 2200 children and adults with AVMs followed for 7 years after gamma-knife radiosurgery⁹⁹ reported 65% of AVMs as cured, most confirmed by angiography (gold standard) with less than a fifth relying on MRI alone, 41 of the 226 cures (18% of the cures were reported by MRI). Most of the cures were angiographically confirmed.⁹⁹ Radiation dose is a factor worth consideration both in cure rate and morbidity from radiation treatment. In a similar vein, radiation dose to the AVM may be limited by risk to surrounding normal structures. In the Starke cohort, 2.7%-10% of patients had permanent deficits from unintended radiation effect.⁹⁹⁻¹⁰¹ Size of the AVM may affect likelihood of achieving a cure, for example when treated with gamma-knife, cure rates ranged from 48% - 77%.^{99,102} No hemorrhages were observed after cure. Radiation treatment may require several years to achieve a cure, with an estimated 1.6% annual risk of hemorrhage until cure is confirmed, which directly compares to and is no different from the 0.8% annual risk in the unruptured population.⁹⁹

Gaps in knowledge: The multimodal and multidisciplinary nature of AVM management introduces variability in study design and reporting, preventing comparison across studies.

Surgery and radiation form the mainstay of reported outcomes in treatment, but series do not uniformly distinguish ruptured and unruptured lesions.^{97,100,103}

Cavernous malformations

HS from cavernous malformations have a different clinical semiology compared to alternate neurovascular malformations. Mortality risk is less, but progressive morbidity from

clinically evident or subclinical recurrent hemorrhages is common (up to 11% per year).¹⁰⁴ Surgical management is based on location, size, multiplicity, etiology/mechanism, and prior trends. These features may modify the risk of further hemorrhage. Treatment may be considered for management of focal neurologic deficits,¹⁰⁵ seizure control, or in response to post-hemorrhagic intracranial hypertension. Risk of subsequent hemorrhage varies widely in children,¹⁰⁴ from 0.5% annually for incidentally discovered cavernous malformations to 11.3% for previously hemorrhaged cavernous malformations.¹⁰⁴ Although the acute re-hemorrhage risk is not as dramatic as in brain aneurysms, there is an increased 18% annual risk of re-hemorrhage in the first 3 years.¹⁰⁴ Most centers would consider treatment of a symptomatic cavernous malformation, if not at the asymptomatic stage.

Microsurgery is the typical treatment strategy, but surgical risk varies widely depending on the lesion location. A study of children with brainstem cavernous malformations found an annual recurrent hemorrhage rate greater than 30% in untreated cavernous malformations. New postoperative deficits are reported in ~30% of cases, and long-term deficits in 21%, but with reduction in annual recurrent hemorrhage to 0.5%.¹⁰⁶ Surgical risks must be weighed against the natural history of cavernous malformations, considering nuances of each lesion.

Gaps in knowledge: Radiation therapy has been reported in case reports in locations with excessive surgical risk¹⁰⁷ but little evidence is available in children or adults to weigh benefit and risk of this treatment strategy.¹⁰⁸

Epilepsy surgery for cavernous malformations is an evolving field, lesions tend to have a different pattern of location and size than those treated for hemorrhage and show an estimated 4.5%-9% surgical morbidity.^{105,109} In surgical series before 2010, post-operative seizure-free rates were 72% - 100%,^{105,109} but might be biased by reporting bias.

Post treatment recurrence rate has been reported as high as 1.2% per year per child,¹⁰⁴ higher (3% per year) in children who present with more than 1 cavernous malformation. Families with a CCM genetic mutation have high number of cavernous malformations that require nuanced considerations in surveillance, surgery, and molecular therapeutic targets under research. Multicenter prospective studies are required to formalize risks and inform family counselling.

Rehabilitation

Five studies commented on rehabilitation after stroke but were not specific to hemorrhagic stroke. Most physiotherapy reports described upper limb therapy with few interventional assessments for lower limb.¹¹⁰ The use of constraint-induced movement therapy (CIMT) is well documented and showed efficacy following neonatal stroke.¹¹⁰ Forced use therapy, repetitive transcranial magnetic stimulation, functional electrical stimulation, and robotics are also supported. There is little data that shows any beneficial effect of transcranial direct current stimulation.¹¹¹

Gaps in knowledge: Assessments and factors informing interventions during acute and ongoing rehabilitation or duration of rehabilitation are not reported.^{110,112-116}

Short-term and long-term outcomes

Short and long-term outcomes have been reported regarding cognitive, motor, and neurological outcomes. Post-operative and interventional outcomes have also been specified.¹¹⁷⁻¹¹⁹ Common scales used across studies included the Kings outcome scale for childhood head injury (KOSCHI), modified Rankin scale (mRS), Glasgow outcome score (GOS), Pediatric stroke outcome measure (PSOM), health related quality of life (HRQL), CHQ and Short form general health survey SF-36.^{4,116,120-124} A KOSCHI of $\leq 4b$ or PSOM 1 is considered to be a poor outcome describing clinically significant neurological deficit. It must be noted that not all studies consistently used the same scoring systems to describe outcome; depending on the focus and specialty of the paper, neurosurgical studies for example, may describe outcomes based on surgical complications. Some categories also included broader terms such as “favorable, mild, severe neurological deficit”. Death was another category.

There is lack of unified definitions and minimal datasets making meaningful analysis of currently published literature impossible.

Short term outcomes reported include death, re-bleed, complications associated with procedural intervention. Mid-long-term outcomes include persistent neurological deficit, epilepsy, and neurocognitive outcomes. Short term outcome reporting is more robust than meaningful mid-long term outcomes. The other signal from demographic data currently reported is that ethnicity may be a predictor of outcome,

While race and ethnicity are important predictors of outcome in adult stroke studies, there is a gap in the current literature in the reporting and robust analysis of race, ethnicity and other potential socioeconomic health determinants of hemorrhagic stroke in children. We identified a single study in a California predominantly adult cohort with bAVMS in which Hispanic race/ethnicity was associated with a shorter hemorrhage-free survival.¹²⁵ In the California study, the annualized 5-year ICH rate was 2.1% (3.7% for ruptured at presentation; 1.4% for unruptured). Initial ICH presentation (hazard ratio: 3.0, 95% CI: 1.9 - 4.9, P0.001) and Hispanic race/ethnicity (hazard ratio: 1.9, 95% CI: 1.1 - 3.3, P0.02) were independent predictors of ICH, adjusting for age, gender, cohort, and a cohort-age interaction. Data was gathered from 2 institutions where 1 cohort was predominantly of black and white race and the other Hispanic and Asian race. The ICH risk for Hispanics vs whites increased to 3.1 (95% CI: 1.3 - 7.4, P0.013) after further adjusting for arteriovenous malformation size and deep venous drainage in a subset of cases with complete data. Similar trends were observed for blacks (hazard ratio: 2.1, 95% CI: 0.9 - 4.8, P0.09) and Asians (hazard ratio: 2.4, 95% CI: 0.8 - 7.1, P0.11), although nonsignificant.¹²⁵

Independent risk factors for persistent functional neurological deficit (FND) in children who undergo surgical

treatment for cerebral AVM at long term follow up include FND at presentation, AVM size >3cm, cerebral AVMs located in eloquent cortex.^{126,125}

Predictors of outcome

We found that pediatric hemorrhagic stroke outcomes were not consistently defined nor consistently reported across the literature. Studies with a surgical focus frequently categorized outcomes based on procedural complications or surgical success. Other studies variously defined outcomes using scores from the Pediatric Stroke Outcome Measure (PSOM) or the King outcome score for childhood head injury (KOSCHI), with a PSOM of >1, KOSCHI <4b often considered a “poor outcome”. Others broadly categories disabilities as “favourable, mild or severe neurological deficit”, reported epilepsy, persistent functional neurological deficits, recurrence of bleed or death. We addressed this variation by organizing clinical, radiological and structural factors present at the time of stroke that have been reported as potential predictors associated with specific outcomes in Table 3.¹²⁴ A prospective cohort study by Beslow et al looked at the incidence and risk factors for seizures and epilepsy in children with spontaneous ICH. 13% of children with ICH had developed epilepsy at 2 years of age.⁵⁰ Arterial hypertension at presentation was not a predictor of outcome.^{37,125}

Studies that have looked at the angioarchitecture of brain AVMs, correlate angioarchitecture with risk of hemorrhagic presentation.¹²⁷ A smaller AVM is associated with a higher feeding artery pressure and therefore higher rate of hemorrhagic presentation compared to a larger AVM. Smaller AVMs are also associated with larger hematoma sizes, but this does not predict future hemorrhage. There is paucity of long-term data on motor or cognitive outcomes of ruptured small AVMs compared to larger AVMs. Deep venous drainage and exclusive deep venous drainage are risk factors for future AVM hemorrhage. The association between deep venous drainage and hemorrhage may be influenced by AVM location.¹²⁷ Infratentorial location has a high hemorrhage rate due to high frequency perforator supply and exclusive deep venous drainage.

Motor and Cognitive outcomes

Few studies reported comprehensive motor and cognitive outcomes. The main studies are found in Table 4.

Discussion

Overall, the existing literature on diagnosis, management and outcomes in pediatric hemorrhagic stroke includes only few good quality studies. Most studies are aimed at individual aspects of HS which are speciality specific. Studies which report on cognitive outcomes vary on their use of outcome scales as well as time points of assessments limiting comparability and clinical applicability. Infants and younger children (< 5-years) can be difficult to assess with existing tools and

require meaningful long-term assessments especially at times of transition (kindergarten, school, higher education).

Most studies were retrospective or single center studies where selection bias, referral bias, and small sample sizes were limitations. Most centers accessed patient data through hospital records, center databases or registries instead of prospective data collection. Only a small number of centers used ICD-9 codes. Most centers excluded hemorrhagic stroke attributable to trauma, brain tumors, intraoperative bleeding, intraventricular hemorrhage, neonatal IVH, vein of Galen malformations, AV fistulae. 1 study excluded HHT and multiple AVMs.

There is a paucity of data available on specific and targeted neurocritical management of children with hemorrhagic stroke and/or complications following initial intensive care stay. Non-invasive monitoring tools including EEG and Transcranial doppler (TCD) are crucial in both resource poor and rich settings. They offer point-of care testing for seizures and vasospasm as well as other complications contributing to secondary brain injury with easy training tools available and proven high interrater reliability. Early data and expert consensus suggest impact on patient important outcomes. Non-invasive and invasive modes of ICP and CPP monitoring including EVDs that offer intervention options are used as part of multimodal neuromonitoring and inform care. Good quality multicenter research is required to validate management pathways and produce guidance on non-invasive, invasive, and imaging signs of recognizing and responding to raised ICP.

Follow up duration and timing of cognitive and motor assessments were center-specific and variable. Data regarding intervention, referral pathway and duration of rehabilitation both in an acute and or chronic setting were lacking.

Outcome reporting and relevant tools to describe neuro-cognitive abilities acutely through to post-discharge as well as ascertain baseline function or pre-morbid state are scarce and largely unvalidated for pediatric HS. Variability in the scales used, time-points for conducting assessments and comparative trajectory from admission through to post-discharge can inform methodology for multi-center high quality studies.

There was no data available on transition process from pediatric to adult care for survivors of pediatric HS, identifying the need for international collaboration to address this.

The data in reported studies was heterogenous and granular and cannot be summarized concisely eg as a meta-analysis as most studies had specific intended focus. Commitment from national and international bodies to formulating a minimal dataset to inform future studies is required.

Hemorrhagic stroke trajectory is etiology dependent and therefore management, follow up and resource availability are not uniform. Clinicians are guided by the specific type of brain injury to inform follow up plans. Neuroprognostication at certain transition points helps inform the family as well as aids referrals to the interdisciplinary team including rehabilitation. Studies examining criteria informing neuroprognostication (eg focal deficit with no hypoxia, hypotension and good outcome vs hydrocephalus [HCP] in prolonged period

Table 3 Clinical, Radiological and Structural Predictors of Poor Outcome in Pediatric Hemorrhagic Stroke

| Clinical Predictor | Outcome |
|---|---|
| Age ³⁶ | |
| Age <3 | Death |
| Age <2 | Increase risk of seizures within 7 d and require continuous infusion of antiepileptic medication |
| GCS at presentation: ^{50,126,128} | |
| GCS 7 | Death |
| GCS 10 | Survival |
| Altered mental state within 6 h ^{53,138} | Increased mortality risk |
| -Comatose | KOSCHI \leq 4b, PSOM > 1 |
| -Obtunded | |
| -Unresponsive | |
| -Intubated on arrival | |
| Functional neurological deficit at presentation ¹²⁶ | Persistent functional neurological deficit |
| Seizures ^{69,129,130} | |
| Seizures at presentation | KOSCHI \leq 4b |
| Seizures within 1st wk of hemorrhage | Increase risk of raised ICP, increased risk of secondary brain injury. Increases probability of refractory seizures requiring >2 antiepileptics on discharge. |
| Recurrent hemorrhage | Increase risk of late seizures (after 7 d of initial event) and ongoing seizures post-discharge (data available Until 6 mo post discharge). |
| Raised ICP ^{131,132} | KOSCHI <4b |
| Neurosurgical procedure required immediately or in acute phase (24-48 h) ⁵³ | Clinically significant disability |
| AVM without intervention after 1st hemorrhage presentation ³⁹ | Increased risk of death |
| Coagulation disorder – thrombocytopenia or coagulopathy ³⁶ | High risk of recurrent bleed within 1st y of index bleed. |
| Underlying medical etiology ^{2,133} | Increased mortality risk |
| Underlying structural lesions ¹⁰ | Clinically significant disability. Increased risk of seizures within first 7 d of index event. |
| Multiple vascular anomalies ³⁶ | Increased risk of acute hemorrhagic recurrence |
| Radiological Predictor | High and prolonged risk for recurrence |
| Hemorrhage of TBV >4% ¹³⁴ | Recurrence of hemorrhage within 1 y |
| Hemorrhage of TBV >2% (>2% considered large hemorrhage) ^{53,132,134,138} | Death |
| Hydrocephalus ¹³² | KOSCHI \leq 4b |
| ICH of dominant hemisphere ¹³⁴ | PSOM \geq 1 |
| Location of AVM hemorrhage: ^{127,135} | Poor quality of life (QOL) |
| Intraventricular hemorrhage | Increased risk of mortality |
| Infratentorial hemorrhage | KOSCHI \leq 4b |
| Corpus callosum, basal ganglia, thalamus ¹³⁵ | Clinically significant disability, PSOM \geq 1 |
| Eloquent cortex ¹²⁶ | KOSCHI \leq 4b, death, clinically significant disability |
| Herniation (uncal, central, subfalcine, tonsillar, upward cerebellar) ¹³⁴ | Death, risk of initial and future hemorrhage |
| KOSCHI \leq 4b | Death |
| Structural Predictor | Increased risk of hemorrhagic presentation |
| Smaller compact AVMs, with single draining vein and deep venous drainage ¹³⁵ | Death |
| Supratentorial perforators ¹³⁰ | Increased risk of hemorrhagic presentation |
| bAVM with concurrent arterial aneurysm ^{136,137} | Clinically significant deficit |
| | Increased risk of hemorrhagic presentation |

Table 4 Summary of Motor and Cognitive Outcomes

| Reference | Motor Outcomes | Cognitive Outcome |
|---------------------------------|---|--|
| Kolk et al ¹²³ | PSOM conducted at an average of 2.7 y after Stroke | Mixed cohort of neonates and children with hemorrhagic stroke. Specific domains; <ul style="list-style-type: none"> • Executive function - good • Attention and language - compromised, Sensorimotor the most compromised, Visuospatial tasks - better in children compared to neonates • Route finding and picture finding - good, Learning and memory - impaired. |
| Lo et al ¹ | <ul style="list-style-type: none"> • Median RRQ=1, mild-moderate impairment was observed • Median KOSCHI = 5a with minimal impairment with daily function. | <ul style="list-style-type: none"> • 19 survivors in a retrospective case study including 59 children: • Parent-patient rated scores on PedsQL not normally distributed in this study, CSQ - increased internalized stress |
| Meyer-Heim et al. ³⁶ | Motor outcome not reported | In children who had survived spontaneous intracranial hemorrhage, 50% of the children in a cohort of 34 children: <ul style="list-style-type: none"> • Recovered well according to standard outcome scores. • Mild to moderate neuropsychological deficits evident in long term outcomes. |
| Murphy et al ^{140,5} | PSOM scales Improved neurological function over the first 12 mo, with mild to no sensorimotor deficits and moderate overall deficits at 1- and 2-y follow-ups (Median 2-y sensorimotor PSOM=0.5, total PSOM=1.5). | <ul style="list-style-type: none"> • Comprehension and perceptual reasoning improved over 24 mo • Low performance sustained in processing speed and working memory. • Age-normed centile scores decreased between 1- and 2-y follow-ups for working memory, suggesting emerging deficits compared with peers. |
| Morales ¹⁴¹ | Motor outcomes not reported | Children with hemophilia and a history of intracranial hemorrhage demonstrated: <ul style="list-style-type: none"> • Significant impairment on some measures of executive function compared with the hemophilia group. • Significantly • reduced executive function skills observed in the cognitive flexibility and planning domains. |
| Nerva et al ¹⁴² | Ruptured bAVMs: irrespective of treatment, the majority of surviving patients (88%) mRS scores of 0-2 at their last follow up with radiographic obliteration of bAVM. | Cognitive outcomes not reported |
| Yvon et al ¹¹⁵ | 60% of children continued to have neurological deficit at discharge and 64% had regained functional hand use. This figure was higher than for those who had suffered an AIS. 80% walked independently regardless of stroke type. The multivariate analysis showed that HS was a substantial predictor of better motor outcome and better functional hand use; this did not predict better academic outcome. | Full-Scale IQ (FSIQ) using age-adapted Wechsler intelligence scales.* Development quotient (DQ) was measured using the Brunet Lezine developmental scale for 5 children in the cohort. FSIQ tended to be higher in those with HS compared to AIS. 36% of children with HS required specialized education several y post-stroke. Some studies showed that 80% of children were attending mainstream school at their 3 y follow up. Longer term follow up (up to 6 y) showed that up to 58% were on the special education register (mixed AIS and HS sample |

* **Wechsler intelligence scales for cognitive outcomes:** verbal comprehension, perceptual reasoning, working memory, and processing speed.

time with guarded prognosis; involvement of eloquent cortex vs white matter vs basal ganglia or combinations thereof) are required to formalize these. This would also focus the interdisciplinary team on crucial prevention of secondary brain injury (eg aneurysmal SAH without parenchymal injury requiring monitoring for vasospasm and seizures) that otherwise significantly impacts on morbidity. Even patients with pure intraventricular bleed and acute hydrocephalus leading to an initial primary more global brain injury may only have mild to moderate cognitive impairment and no permanent motor deficit on follow up hence highlighting the need for excellent neurocritical care to prevent secondary problems.

A particular challenge for clinicians, is the scarcity of data and consensus opinion/protocols for recognition and management of hemorrhage stroke. This includes the lack of prospective cohort studies to elucidate diagnosis, management, prognostication and outcomes, long-term and cognitive outcomes. The local and global variability in management highlights the complexity of managing pediatric hemorrhagic stroke. Whilst individual disciplines eg Neurosurgery and Neurointervention have studied their area of expertise and interest in some detail, the majority of studies are in adults with few children enrolled, and are therefore underpowered for children. Findings are often extrapolated to the pediatric population, but limitations based on fundamental differences in pathophysiology and outcome between adults and children are acknowledged.

Studying disease in the pediatric population not only brings unique challenges, but also provides an opportunity for growth and better understanding of serious and devastating illnesses like HS. Global demographic data is difficult to capture but is needed to characterize disease outcome. A data-driven approach to clinical decision may improve the outcome for both survivors of pediatric HS and their families.

Future recommendations

1. International guidelines and society statements that commission:
 - a. Meaningful acute and follow up models inclusive of the multidisciplinary team (MDT – Neurosurgeon, [interventional] Neuroradiologist, Neurointensivist, Neurologist, Rehabilitation specialist, Neuropsychologist, and other allied health professionals) to support decision making when determining etiology, acute management and planning rehabilitation needs as well as longer term follow up requirements.
 - b. Robust systems to inform acute and follow up neuroimaging.
 - c. Evidence as well as expert driven systems to support meaningful follow up stating specific time points of transition. Recommended transition points may include i) Bayley's for <3 year old's; ii) Assessments required at times of: Pre-school,

Grade 1, Middle to high school and High school to college transition

- d. A field guide for clinicians inclusive of acute and long-term management strategies (eg a toolbox of accepted tests to inform follow up, rehabilitation and other supports required at different life stages).
- e. Informed precision neuroprognostication based on unified terminology and MDT involvement from acute through to follow up stages.

Assessing and differentiating outcomes in a meaningful way (eg motor outcome and cognitive outcome) must improve to reflect and characterize scenarios where a child who makes a full motor recovery is currently categorized as having a good outcome, even though their cognitive abilities have significant impairments. Risk factors are very different between adults and children; for example, hypercholesterolemia, hypertension, lifestyle factors such as smoking and alcohol intake are specific risk factors in the adult population with impact on both short- and long-term outcome, whereas congenital heart disease is a known risk factor in children. Primary prevention and monitoring strategies therefore differ in children to adults. The impacts of HS over and above the underlying disease is crucial to report in a robust way as this will inform not only clinicians counselling families but also support advocacy.

Author contributions

The study concept and design were conceived by SC and MW. SC and MW created the Prospero protocol with contributions from AS, LE, VZ. Data collection, extraction and maintenance of the databank occurred by SC and AS, risk of bias assessment by SC and MW. SC and AS drafted the main manuscript, which was reviewed by LE, GB, LL, DH, CF, ND and MW. Revision of manuscript following review completed by SC, CF and MW.

Acknowledgments

Dr. Naba J Borah (MBBS., MS [General Surgery]., MCh [Neurosurgery]), Consultant Neurosurgeon (Guwahati Neurological Research Centre, India) for clinical, scientific and editorial contribution to section "Predictors of outcome".

Mr. Samrat Deb (B.Eng., Dip AC), Software Engineer (Deloitte consulting India, Pvt ltd) for data analysis, technical and graphical assistance.

Supplementary materials

Supplementary material associated with this article can be found in the online version at doi:[10.1016/j.spn.2022.101001](https://doi.org/10.1016/j.spn.2022.101001).

References

- Lo WD, Hajek C, Pappa C, et al: Outcomes in children with hemorrhagic stroke. *Arch Neurol* 70(1):66-71, 2013
- Fullerton HJ, Achrol AS, Johnston SC, et al: Long-term hemorrhage risk in children versus adults with brain arteriovenous malformations. *Stroke* 36:2099-2104, 2005. Available from: <https://www.ahajournals.org/doi/pdf/10.1161/01.STR.0000181746.77149.2b?download=true>
- Agrawal N, Johnston SC, Wu YW, et al: Imaging data reveal a higher pediatric stroke incidence than prior US estimates. *Stroke* 40(11):3415-3421, 2009
- Greenham M, Gordon A, Anderson V, et al: Outcome in childhood stroke. *Stroke* 47:1159-1164, 2016
- Gardner MA, Hills NK, Sidney S, et al: The 5-year direct medical cost of neonatal and childhood stroke in a population-based cohort. *Neurology* 74(5):372-378, 2010
- Medley TL, Miteff C, Andrews I, et al: Australian clinical consensus guideline: The diagnosis and acute management of childhood stroke. *Int J Stroke* 14(1):94-106, 2019
- Ferriero DM, Fullerton HJ, Bernard TJ, et al: Management of stroke in neonates and children: A scientific statement from the American heart association/American stroke association. *Stroke* 50(3):e51-e96, 2019
- McKinney SM, Magruder JT, Abramo TJ: An update on pediatric stroke protocol. *Pediatr Emerg Care* 34(11):810-815, 2018
- Guo R, Chen R, Yu Z, et al: Primary intraventricular hemorrhage in pediatric patients: Causes, characteristics, and outcomes. *World Neurosurg* 133:e121-e128, 2020
- Fullerton HJ, Wu YW, Sidney S, et al: Recurrent hemorrhagic stroke in children: A population-based cohort study. *Stroke* 38(10):2658-2662, 2007
- Jordan LC, Johnston SC, Wu YW, et al: The importance of cerebral aneurysms in childhood hemorrhagic stroke a population-based study. *Stroke* 40(2):400-405, 2009
- Laugesaar R, Kolk A, Uustalu U, et al: Epidemiology of childhood stroke in Estonia. *Pediatr Neurol* 42(2):93-100, 2010
- Neuner C, Noroozi N, Norman G, et al: Severe bleeding events in adults and children with primary immune thrombocytopenia: A systematic review. *J Thromb Haemost* 13(3):457-464, 2015
- Schiavotto C, Ruggeri M, Rodeghiero F: Adverse reactions after high-dose intravenous immunoglobulin: Incidence in 83 patients treated for idiopathic thrombocytopenic purpura (ITP) and review of the literature. *Haematologica* 78(6 Suppl 2):35-40, 1993
- v dela Cruz T, DL Stewart, Winston SJ, et al: Risk factors for intracranial hemorrhage in the extracorporeal membrane oxygenation patient. *J Perinatol* 17(1):18-23, 1997
- Yang W, Anderson-Keightly H, Westbroek EM, et al: Long-term hemorrhagic risk in pediatric patients with arteriovenous malformations. *J Neurosurg Pediatr* 18(3):329-338, 2016
- Giang KW, Mandalenakis Z, Dellborg M, et al: Long-term risk of hemorrhagic stroke in young patients with congenital heart disease. *Stroke* 49:1155-1162, 2018. Available from: <https://www.ahajournals.org/doi/pdf/10.1161/STROKEAHA.117.020032?download=true>
- Chiang KL, Cheng CY: Epidemiology, risk factors and characteristics of pediatric stroke: A nationwide population-based study. *Qjm* 111:445-454, 2018
- Garzelli L, Shotar E, Blauwblomme T, et al: Risk factors for early brain avm rupture: Cohort study of pediatric and adult patients. *AJNR Am J Neuroradiol* 41(12):2358-2363, 2020
- Hetts SW, Narvid J, Sanai N, et al: Intracranial aneurysms in childhood: 27-Year single-institution experience. *Am J Neuroradiol* 30(7):1315-1324, 2009
- del Balzo F, Spalice A, Ruggieri M, et al: Stroke in children: inherited and acquired factors and age-related variations in the presentation of 48 paediatric patients. *Acta Paediatr* 98(7):1130-1136, 2009
- Butros LJ, Bussel JB: Intracranial hemorrhage in immune thrombocytopenic purpura: A retrospective analysis. *J Pediatr Hematol Oncol* 25(8):660-664, 2003
- O'Donnell MJ, Xavier D, Liu L, et al: Risk factors for ischaemic and intracerebral haemorrhagic stroke in 22 countries (the INTERSTROKE study): A case-control study. *Lancet* 376(9735):112-123, 2010
- Krishnamurthi R v, Feigin VL, Forouzanfar MH, et al: Global and regional burden of first-ever ischaemic and haemorrhagic stroke during 1990-2010: Findings from the global burden of disease study 2010. *Lancet Glob Health* 1(5):e259-e281, 2013
- Zhang Y, Tuomilehto J, Jousilahti P, et al: Lifestyle factors on the risks of ischemic and hemorrhagic stroke. *Arch Intern Med* 171(20):1811-1818, 2011
- Mohr JP, Parides MK, Stapf C, et al: Medical management with or without interventional therapy for unruptured brain arteriovenous malformations (ARUBA): a multicentre, non-blinded, randomised trial. *Lancet* 383(9917):614-621, 2014
- Henderson WG, Torner JC, Nibbelink DW: Intracranial aneurysms and subarachnoid hemorrhage — report on a randomized treatment study. IV-B. Regulated bed rest — statistical evaluation. *Stroke* 8(5):579-589, 1977
- van Donkelaar CE, Bakker NA, Veeger NJGM, et al: Predictive factors for rebleeding after aneurysmal subarachnoid hemorrhage: Rebleeding aneurysmal subarachnoid hemorrhage study. *Stroke* 46(8):2100-2106, 2015
- Darkwah Oppong M, Gümüs M, Pierscianek D, et al: Aneurysm rebleeding before therapy: a predictable disaster? *J Neurosurg*: 1-8, 2018
- Molyneux A, Kerr R, Stratton I, et al: International subarachnoid aneurysm trial (ISAT) of neurosurgical clipping versus endovascular coiling in 2143 patients with ruptured intracranial aneurysms: A randomised trial. *Lancet* 360(9342):1267-1274, 2002
- Spetzler RF, McDougall CG, Albuquerque FC, et al: The barrow ruptured aneurysm trial: 3-year results. *J Neurosurg* 119(1):146-157, 2013
- Spetzler RF, McDougall CG, Zabramski JM, et al: Ten-year analysis of saccular aneurysms in the barrow ruptured aneurysm trial. *J Neurosurg* 132(3):771-776, 2019
- Molyneux AJ, Birks J, Clarke A, et al: The durability of endovascular coiling versus neurosurgical clipping of ruptured cerebral aneurysms: 18 year follow-up of the UK cohort of the international subarachnoid aneurysm trial (ISAT). *Lancet* 385(9969):691-697, 2015
- Wojtacha M, Bazowski P, Mandera M, et al: Cerebral aneurysms in childhood. *Childs Nerv Syst* 17:37-41, 2001. Available from: <https://link.springer.com/content/pdf/10.1007/s003810000378.pdf>
- Sanai N, Quinones-Hinojosa A, Gupta NM, et al: Pediatric intracranial aneurysms: Durability of treatment following microsurgical and endovascular management. *J Neurosurg* 104(2 Suppl):82-89, 2006
- Meyer-Heim AD, Boltshauser E: Spontaneous intracranial haemorrhage in children: Aetiology, presentation and outcome. *Brain Dev* 25(6):416-421, 2003
- Lo WD, Lee J, Rusin J, Perkins E, et al: Intracranial hemorrhage in children an evolving spectrum. *Arch Neurol* 65(12):1629-1633, 2008. Available from: <https://jamanetwork.com/>
- Fullerton HJ, Achrol AS, Johnston SC, et al: Long-term hemorrhage risk in children versus adults with brain arteriovenous malformations. *Stroke* 36(10):2099-2104, 2005
- Oulasvirta E, Koroknay-Pál P, Hafez A, et al: Characteristics and long-term outcome of 127 children with cerebral arteriovenous malformations. *Clin Neurosurg* 84(1):151-158, 2019
- Ding D, Starke RM, Kano H, et al: International multicenter cohort study of pediatric brain arteriovenous malformations. Part I: Predictors of hemorrhagic presentation. *J Neurosurg Pediatr* 19(2):127-135, 2017
- Singhal A, Adirim T, Cochrane D, et al: Pediatric patients with poor neurological status and arteriovenous malformation hemorrhage: An outcome analysis: Clinical article. *J Neurosurg Pediatr* 7(5):462-467, 2011
- Meyer PG, Orliaguet GA, Zerah M, et al: Emergency management of deeply comatose children with acute rupture of cerebral arteriovenous

- malformations. *Can J Anaesth* 47:758-766, 2000. Available from: <https://link.springer.com/content/pdf/10.1007/BF03019478.pdf>
43. Mackay MT, Churilov L, Donnan GA, et al: Performance of bedside stroke recognition tools in discriminating childhood stroke from mimics. *Neurology* 86(23):2154-2161, 2016
 44. Sporns PB, Psychogios MN, Fullerton HJ, et al: Neuroimaging of pediatric intracerebral hemorrhage. *J Clin Med* 9. <https://doi.org/10.3390/jcm9051518>, 2020
 45. Bal J, Milosevich E, Rennie A, et al: Management of haemorrhagic stroke secondary to arteriovenous malformations in childhood. *Childs Nerv Syst* 37:1255-1265, 2021. Available from: <https://link.springer.com/content/pdf/10.1007/s00381-020-04976-x.pdf>
 46. Mirsky DM, Beslow LA, Amlie-Lefond C, et al: Pathways for neuroimaging of childhood stroke. *Pediatr Neurol* 69:11-23, 2017
 47. Ghali MGZ, Srinivasan VM, Cherian J, et al: Pediatric intracranial aneurysms: Considerations and recommendations for follow-up imaging. *World Neurosurg* 109:418-431, 2018
 48. Howard BM, Hu R, Barrow JW, et al: Comprehensive review of imaging of intracranial aneurysms and angiographically negative subarachnoid hemorrhage. *Neurosurg Focus* 47(6):E20, 2019
 49. Guerrero WR, Dandapat S, Ortega-Gutierrez S: Hemorrhagic cerebrovascular pathology in the pediatric population. *Front Neurol* 11:1-13, 2020
 50. Piastra M, de Luca D, Genovese O, et al: Clinical outcomes and prognostic factors for spontaneous intracerebral hemorrhage in pediatric ICU: A 12-year experience. *J Intensive Care Med* 34:1003-1009, 2019. Available from: <https://journals.sagepub.com/doi/pdf/10.1177/0885066617726049>
 51. Beslow LA, Abend NS, Gindville MC, et al: Pediatric intracerebral hemorrhage: Acute symptomatic seizures and epilepsy. *JAMA Neurol* 70:448-454, 2013. Available from: https://jamanetwork.com/journals/jamaneurology/articlepdf/1566835/noc120092_448_454.pdf
 52. Jordan LC, Hillis AE: Hemorrhagic stroke in children. *Pediatr Neurol* 36(2):73-80, 2007
 53. Beslow LA, Licht DJ, Smith SE, et al: Predictors of outcome in childhood intracerebral hemorrhage: A prospective consecutive cohort study. *Stroke* 41:313-318, 2010. Available from: <https://www.ahajournals.org/doi/pdf/10.1161/STROKEAHA.109.568071?download=true>
 54. Maldonado-Soto AR, Fryer RH: Reversible cerebral vasoconstriction syndrome in children: An update. *Semin Pediatr Neurol* 40:100936, 2021
 55. Taran S, Mandell DM, McCredie VA: CT perfusion for the detection of delayed cerebral ischemia in the presence of neurologic confounders. *Neurocrit Care* 33(1):317-322, 2020
 56. Rabinstein AA: Optimal blood pressure after intracerebral hemorrhage. *Stroke* 49(2):275-276, 2018
 57. Cadena R, Shoykhet M, Ratcliff JJ: Emergency neurological life support: Intracranial hypertension and herniation. *Neurocrit Care* 27(S1):82-88, 2017
 58. Zafar SF, Postma EN, Biswal S, et al: Effect of epileptiform abnormality burden on neurologic outcome and antiepileptic drug management after subarachnoid hemorrhage. *Clin Neurophysiol* 129(11):2219-2227, 2018
 59. Claassen J, Hirsch LJ, Kreiter KT, et al: Quantitative continuous EEG for detecting delayed cerebral ischemia in patients with poor-grade subarachnoid hemorrhage. *Clin Neurophysiol* 115(12):2699-2710, 2004
 60. Gilmore EJ, Maciel CB, Hirsch LJ, Sheth KN: Review of the utility of prophylactic anticonvulsant use in critically ill patients with intracerebral hemorrhage. *Stroke* 47(10):2666, 2016. 272
 61. Jones FJS, Sanches PR, Smith JR, et al: Seizure prophylaxis after spontaneous intracerebral hemorrhage. *JAMA Neurol* 78(9):1128, 2021
 62. Derex L, Rheims S, Peter-Derex L: Seizures and epilepsy after intracerebral hemorrhage: An update. *J Neurol* 268(7):2605-2615, 2021
 63. Peter-Derex L: Prevention of epileptic seizures in acute intracerebral haemorrhage (PEACH). *ClinicalTrials.gov Identifier: NCT02631759*; 2022
 64. Connolly ES, Rabinstein AA, Carhuapoma JR, et al: Guidelines for the management of aneurysmal subarachnoid hemorrhage. *Stroke* 43(6):1711-1737, 2012
 65. Roach ES, Golomb MR, Adams R, et al: Management of stroke in infants and children. *Stroke* 39(9):2644-2691, 2008
 66. Christerson S, Strömberg B: Childhood stroke in Sweden I: Incidence, symptoms, risk factors and short-term outcome. *Acta Paediatr* 99:1641-1649, 2010. Available from: <https://onlinelibrary.wiley.com/doi/pdfdirect/10.1111/j.1651-2227.2010.01925.x?download=true>
 67. Skoch J, Tahir R, Abruzzo T, et al: Predicting symptomatic cerebral vasospasm after aneurysmal subarachnoid hemorrhage with an artificial neural network in a pediatric population. *Childs Nerv Syst* 33:2153-2157, 2017. Available from: <https://link.springer.com/content/pdf/10.1007/s00381-017-3573-0.pdf>
 68. Sprigg N, Flaherty K, Appleton JP, et al: Tranexamic acid to improve functional status in adults with spontaneous intracerebral haemorrhage: the TICH-2 RCT. *Health Technol Assess* 23(35):1-48, 2019
 69. Bansal S, Blalock D, Kebede T, et al: Levetiracetam versus (fos)phenytoin for seizure prophylaxis in pediatric patients with intracranial hemorrhage. *J Neurosurg Pediatr* 13(2):209-215, 2014
 70. LaRovere KL: Transcranial doppler ultrasound in children with stroke and cerebrovascular disorders. *Curr Opin Pediatr* 27(6):712-718, 2015
 71. Heffern J, McIntosh AM, Reiter PD: Nimodipine for the prevention of cerebral vasospasm after subarachnoid hemorrhage in 12 children. *Pediatr Neurol* 52(3):356-360, 2015
 72. Schaller C, Schramm J, Haun D, et al: Patterns of cortical oxygen saturation changes during co₂ reactivity testing in the vicinity of cerebral arteriovenous malformations. *Stroke* 34(4):938-944, 2003
 73. Appavu B, Foldes S, Burrows BT, et al: Multimodal assessment of cerebral autoregulation and autonomic function after pediatric cerebral arteriovenous malformation rupture. *Neurocrit Care* 34:537-546, 2021. Available from: <https://link.springer.com/content/pdf/10.1007/s12028-020-01058-3.pdf>
 74. Rots ML, van Putten MJAM, Hoedemaekers CWE, et al: Continuous EEG monitoring for early detection of delayed cerebral ischemia in subarachnoid hemorrhage: A pilot study. *Neurocrit Care* 24(2):207-216, 2016
 75. Gaspard N: Current clinical evidence supporting the use of continuous eeg monitoring for delayed cerebral ischemia detection. *J Clin Neurophysiol* 33(3):211-216, 2016
 76. Rosenthal ES, Biswal S, Zafar SF, et al: Continuous electroencephalography predicts delayed cerebral ischemia after subarachnoid hemorrhage: A prospective study of diagnostic accuracy. *Ann Neurol* 83(5):958-969, 2018
 77. Gollwitzer S, Groemer T, Rampp S, et al: Early prediction of delayed cerebral ischemia in subarachnoid hemorrhage based on quantitative EEG: A prospective study in adults. *Clin Neurophysiol* 126(8):1514-1523, 2015
 78. Kondziella D, Friberg CK, Wellwood I, et al: Continuous EEG monitoring in aneurysmal subarachnoid hemorrhage: A systematic review. *Neurocrit Care* 22(3):450-461, 2015
 79. Abend NS, Topjian AA, Williams S: Could EEG monitoring in critically ill children be a cost-effective neuroprotective strategy? *J Clin Neurophysiol* 32(6):486-494, 2015
 80. Etmiman N, Aguiar de Sousa D, Tiseo C, et al: European stroke organisation (ESO) Guidelines on management of unruptured intracranial aneurysms. *Eur Stroke J: LXXXI-CVI*, 2022
 81. Payne ET, Zhao XY, Frndova H, et al: Seizure burden is independently associated with short term outcome in critically ill children. *Brain* 137(5):1429-1438, 2014
 82. Guo Y, Fang S, Wang J, et al: Continuous EEG detection of DCI and seizures following aSAH: A systematic review. *Br J Neurosurg* 34(5):543-548, 2020
 83. de Marchis GM, Pugin D, Meyers E, et al: Seizure burden in subarachnoid hemorrhage associated with functional and cognitive outcome. *Neurology* 86(3):253-260, 2016
 84. Riviello JJ, Erklauer J: Neurocritical care and brain monitoring. *Neuro Crit Care* 39(3):847-866, 2021
 85. Mendelow AD, Gregson BA, Fernandes HM, et al: Early surgery versus initial conservative treatment in patients with spontaneous supratentorial intracerebral haematomas in the International Surgical Trial in Intracerebral Haemorrhage (STICH): A randomised trial. *Lancet* 365(9457):387-397, 2005

86. Fried HI, Nathan BR, Rowe AS, et al: The insertion and management of external ventricular drains: An evidence-based consensus statement : A statement for healthcare professionals from the neurocritical care society. *Neurocrit Care* 24(1):61-81, 2016
87. Kirschen MP, LaRovere K, Balakrishnan B, et al: A survey of neuromonitoring practices in North American pediatric intensive care units. *Pediatr Neurol* 126:125-130, 2022
88. LoPresti MA, Goethe EA, Lam S: Surgical strategies for management of pediatric arteriovenous malformation rupture: The role of initial decompressive craniectomy. *Childs Nerv Syst* 36(7):1445-1445, 2020
89. Ma L, Kim H, Chen XL, et al: Morbidity after hemorrhage in children with untreated brain arteriovenous malformation. *Cerebrovasc Dis* 43(5-6):231-241, 2017
90. Spetzler RF, McDougall CG, Zabramski JM, et al: The barrow ruptured aneurysm trial: 6-year results. *J Neurosurg* 123(3):609-617, 2015
91. Becske T, Kallmes DF, Saatci I, et al: Pipeline for uncoilable or failed aneurysms: Results from a multicenter clinical trial. *Radiology* 267(3):858-868, 2013
92. Scoville J, Joyce E, Baker C, et al: Analyzing the safety and efficacy of flow-diverting stents in pediatric aneurysms: A Systematic Review. *Neurosurgery* 89(2):154-163, 2021
93. Fulkerson DH, Voorhies JM, Payner TD, et al: Middle cerebral artery aneurysms in children: Case series and review. *J Neurosurg Pediatr* 8:79-89, 2011. Available from: <https://thejns.org/downloadpdf/journals/j-neurosurg-pediatr/8/1/article-p79.pdf>
94. Yasin JT, Wallace AN, Madaelil TP, et al: Treatment of pediatric intracranial aneurysms: Case series and meta-Analysis. *J NeuroInterv Surg* 11:257-264, 2019
95. Sanai N, Auguste KI, Lawton MT: Microsurgical management of pediatric intracranial aneurysms. *Childs Nerv Syst* 26:1319-1327, 2010. Available from: <https://link.springer.com/content/pdf/10.1007/s00381-010-1210-2.pdf>
96. Cherian J, Srinivasan V, Froehler MT, et al: Flow diversion for treatment of intracranial aneurysms in pediatric patients: Multicenter case series. *Neurosurgery* 87(1):53-62, 2020
97. Al-Smadi AS, Ansari SA, Shokuhfar T, et al: Safety and outcome of combined endovascular and surgical management of low grade cerebral arteriovenous malformations in children compared to surgery alone. *Eur J Radiol* 116:8-13, 2019
98. Hak JF, Boulouis G, Kerleroux B, et al: Pediatric brain arteriovenous malformation recurrence: A cohort study, systematic review and meta-analysis. *J Neurointerv Surg* 1-7, 2021
99. Starke RM, Ding D, Kano H, et al: International multicenter cohort study of pediatric brain arteriovenous malformations. Part 2: Outcomes after stereotactic radiosurgery. *J Neurosurg Pediatr* 19(2):136-148, 2017
100. Zadeh G, Andrade-Souza YM, Tsao MN, et al: Pediatric arteriovenous malformation: University of Toronto experience using stereotactic radiosurgery. *Childs Nerv Syst* 23(2):195-199, 2007
101. Chen CJ, Ding D, Kano H, et al: Stereotactic radiosurgery for pediatric versus adult brain arteriovenous malformations a multicenter study. *Stroke* 49(8):1939-1945, 2018. <https://doi.org/10.1161/STROKEAHA.118.022052>
102. Hanakita S, Koga T, Shin M, et al: The long-term outcomes of radiosurgery for arteriovenous malformations in pediatric and adolescent populations. *J Neurosurg Pediatr* 16(2):222-231, 2015
103. Dinca EB, de Lacy P, Yianni J, et al: Gamma knife surgery for pediatric arteriovenous malformations: A 25-year retrospective study. *J Neurosurg Pediatr* 10(5):445-450, 2012
104. Gross BA, Du R, Orbach DB, et al: The natural history of cerebral cavernous malformations in children. *J Neurosurg Pediatr* 17(2):123-128, 2016
105. Consales A, Piatelli G, Ravegnani M, et al: Treatment and outcome of children with cerebral cavernomas: A survey on 32 patients. *Neurol Sci* 31(2):117-123, 2010
106. Li D, Hao SY, Tang J, et al: Surgical management of pediatric brainstem cavernous malformations. *J Neurosurg Pediatr* 13:484-502, 2014. Available from: <https://thejns.org/downloadpdf/journals/j-neurosurg-pediatr/13/5/article-p484.pdf>
107. Kondziolka D, Lunsford LD, Coffey RJ, et al: Stereotactic radiosurgery of angiographically occult vascular malformations: indications and preliminary experience. *Neurosurgery* 27(6):892-900, 1990
108. Lu XY, Sun H, Xu JG, et al: Stereotactic radiosurgery of brainstem cavernous malformations: A systematic review and meta-analysis. *J Neurosurg* 120(4):982-987, 2014
109. von der Brölie C, Kuczaty S, von Lehe M: Surgical management and long-term outcome of pediatric patients with different subtypes of epilepsy associated with cerebral cavernous malformations. *J Neurosurg Pediatr* 13(6):699-705, 2014
110. Mirkowski M, McIntyre A, Faltynek P, et al: Nonpharmacological rehabilitation interventions for motor and cognitive outcomes following pediatric stroke: A systematic review. *Eur J Pediatr* 178(4):433-454, 2019
111. Russo C, Souza Carneiro MI, Bolognini N, et al: Safety review of transcranial direct current stimulation in stroke. *Neuromodulation* 20(3):215-222, 2017
112. Ganesan V: Outcome and rehabilitation after childhood stroke. *Handb Clin Neurol* 112:1079-1083, 2013
113. Ullah S, bin Ayaz S, Zaheer Qureshi A, et al: Characteristics and functional outcomes of pediatric stroke survivors at a rehabilitation unit in Saudi Arabia. *J Clin Neurosci* 81:403-408, 2020
114. Linden M, Hawley C, Blackwood B, et al: Technological aids for the rehabilitation of memory and executive functioning in children and adolescents with acquired brain injury. *Cochrane Database Syst Rev*, 7; 2016. 2016:CD011020,
115. Yvon E, Lamotte D, Tiberghien A, et al: Long-term motor, functional, and academic outcome following childhood ischemic and hemorrhagic stroke: A large rehabilitation center-based retrospective study. *Dev Neurorehabil* 21(2):83-90, 2018
116. Hurvitz E, Warschausky S, Berg M, et al: Long-term functional outcome of pediatric stroke survivors. *Top Stroke Rehabil* 11(2):51-59, 2004. <https://doi.org/10.1310/CL09-U2QA-9M5A-ANG2>
117. Shtaya A, Miller J, Sparrow O: Multimodality management and outcomes of brain arterio-venous malformations (AVMs) in children: Personal experience and review of the literature, with specific emphasis on age at first AVM bleed. *Childs Nerv Syst* 33:573-581, 2017
118. de Castro-Afonso LH, Nakiri GS, Oliveira RS, et al: Curative embolization of pediatric intracranial arteriovenous malformations using Onyx: The role of new embolization techniques on patient outcomes. *Neuroradiology* 58(6):585-594, 2016
119. Saraf R, Shrivastava M, Siddhartha W, et al: Intracranial pediatric aneurysms: Endovascular treatment and its outcome. *J Neurosurg Pediatr* 10(3):230-240, 2012
120. Schnitzler ER, Schneck MJ: Therapeutic pitfalls in the transition of neurologic patients from pediatric to adult health care providers. *Neurol Clin* 39(1):243-256, 2021
121. Adil MM, Vidal GA, Beslow LA: Clinical outcomes among transferred children with ischemic and hemorrhagic strokes in the nationwide inpatient sample. *J Stroke Cerebrovasc Dis* 25:2594-2602, 2016
122. de Montferrand C, Vassel-Hitier J, Yvon-Chaou E, et al: Language and cognitive outcomes after childhood stroke: Theoretical implications for hemispheric specialization. *Cortex* 120:509-523, 2019
123. Kolk A, Ennok M, Laugesaar R, et al: Long-term cognitive outcomes after pediatric stroke. *Pediatr Neurol* 44(2):101-109, 2011
124. Jordan LC, Kleinman JT, Hillis AE: Intracerebral hemorrhage volume predicts poor neurologic outcome in children. *Stroke* 40(5):1666-1671, 2009
125. Kim H, Sidney S, McCulloch CE, et al: Racial/Ethnic differences in longitudinal risk of intracranial hemorrhage in brain arteriovenous malformation patients. *Stroke* 38(9):2430-2437, 2007
126. Ravindra VM, Bollo RJ, Eli IM, et al: A study of pediatric cerebral arteriovenous malformations: Clinical presentation, radiological features, and long-term functional and educational outcomes with predictors of sustained neurological deficits. *J Neurosurg Pediatr* 24(1):1-8, 2019

127. Ellis MJ, Armstrong D, Vachhrajani S, et al: Angioarchitectural features associated with hemorrhagic presentation in pediatric cerebral arteriovenous malformations. *J Neurointerv Surg* 5:191-195, 2013. Available from: <https://jn.is.bmj.com/content/neurintsurg/5/3/191.full.pdf>
128. Boulouis G, Stricker S, Benichi S, et al: Mortality and functional outcome after pediatric intracerebral hemorrhage: Cohort study and meta-analysis. *J Neurosurg Pediatr* 27:661-667, 2021. Available from: <https://thejns.org/downloadpdf/journals/j-neurosurg-pediatr/27/6/article-p661.pdf>
129. Bansal S, Kebede T, Dean NP, et al: Predictors of acute symptomatic seizures after intracranial hemorrhage in infants. *Pediatr Crit Care Med* 15(8):750-755, 2014
130. Williams V, Jayashree M, Bansal A, et al: Spontaneous intracranial haemorrhage in children-intensive care needs and predictors of in-hospital mortality: A 10-year single-centre experience. *Childs Nerv Syst* 35:1371-1379, 2019. Available from: <https://link.springer.com/content/pdf/10.1007/s00381-019-04209-w.pdf>
131. Beslow LA, Jordan LC: Pediatric stroke: The importance of cerebral arteriopathy and vascular malformations. *Childs Nerv Syst* 26:1263-1273, 2010
132. Beslow LA, Ichord RN, Gindville MC, et al: Pediatric intracerebral hemorrhage score: A simple grading scale for intracerebral hemorrhage in children. *Stroke* 45:66-70, 2014. Available from: <https://www.ahajournals.org/doi/pdf/10.1161/STROKEAHA.113.003448?download=true>
133. Beez T, Steiger HJ, Hänggi D: Evolution of management of intracranial aneurysms in children: A systematic review of the modern literature. *J Child Neurol* 31(6):773-783, 2016. <https://doi.org/10.1177/0883073815609153>
134. Guédon A, Blauwblomme T, Boulouis G, et al: Predictors of outcome in patients with pediatric intracerebral hemorrhage: Development and validation of a modified score. *Radiology* 286(2):651-658, 2018
135. Ding D: Influence of angioarchitecture on management of pediatric intracranial arteriovenous malformations. *J Neurointerv Surg* 2013. <https://doi.org/10.1136/neurintsurg-2013-010861>
136. Kellner CP, McDowell MM, Phan MQ, et al: Number and location of draining veins in pediatric arteriovenous malformations: Association with hemorrhage. *J Neurosurg Pediatr* 14:538-545, 2014. Available from: <https://thejns.org/downloadpdf/journals/j-neurosurg-pediatr/14/5/article-p538.pdf>
137. Anderson RC, McDowell MM, Kellner CP, et al: Arteriovenous malformation-associated aneurysms in the pediatric population. *J Neurosurg Pediatr* 9:11-16, 2012. Available from: <https://thejns.org/downloadpdf/journals/j-neurosurg-pediatr/9/1/article-p11.pdf>
138. Beslow LA, Licht DJ, Smith SE, et al: Predictors of outcome in childhood intracerebral hemorrhage: A prospective consecutive cohort study. *Stroke* 41(2):313-318, 2010
139. Deng Z, Chen Y, Ma L, et al: Long-term outcomes and prognostic predictors of 111 pediatric hemorrhagic cerebral arteriovenous malformations after microsurgical resection: a single-center experience. *Neurosurg Rev* 44:915-923, 2021. Available from: <https://link.springer.com/content/pdf/10.1007/s10143-019-01210-4.pdf>
140. Murphy LK, Compas BE, Gindville MC, et al: Cognitive functioning over 2 years after intracerebral hemorrhage in school-aged children. *Dev Med Child Neurol* 59:1146-1151, 2017. Available from: <https://onlinelibrary.wiley.com/doi/pdfdirect/10.1111/dmcn.13547?download=true>
141. Morales G, Matute E, Murray J, et al: Is executive function intact after pediatric intracranial hemorrhage? A sample of Mexican children with hemophilia. *Clin Pediatr (Phila)* 52:950-959, 2013. Available from: <https://journals.sagepub.com/doi/pdf/10.1177/0009922813495311>
142. Nerva JD, Kim LJ, Barber J, et al: Outcomes of multimodality therapy in pediatric patients with ruptured and unruptured brain arteriovenous malformations. *Neurosurgery* 78(5):695-707, 2016



ELSEVIER



Cerebral Arteriopathies of Childhood — Current Approaches

Daniel Davila-Williams,^{*} Megan Barry,[†] Carolina Vargas,[‡] Arastoo Vossough,[§]
Timothy J. Bernard,[†] and Mubeen F. Rafay^{||}

Up to more than half of previously healthy children presenting with their first arterial ischemic stroke have a cerebral arteriopathy. Cerebral arteriopathies during childhood can be congenital, reflecting abnormal vessel development, or acquired when caused by disruption of vascular homeostasis. Distinguishing different types of cerebral arteriopathies in children can be challenging but of great clinical value as they may dictate different disease and treatment courses, and clinical and radiologic outcomes. Furthermore, children with stroke due to a specific arteriopathy exhibit distinctive features when compared to those with stroke due to other causes or a different type of arteriopathy. These features become crucial in the management of pediatric stroke by choosing appropriate diagnostic and treatment strategies. The objective of this article is to provide the reader with a comprehensive up-to-date review of the classification, symptoms, diagnosis, treatment, and outcome of cerebral arteriopathies in children.

Semin Pediatr Neurol 43:101004 © 2022 Elsevier Inc. All rights reserved.

Introduction

Although childhood arterial ischemic stroke (AIS) is often multifactorial, cerebral arteriopathies are recognized as a significant cause and predictor of stroke recurrence and short-term outcome. Up to more than half of children presenting with their first AIS may have a cerebral arteriopathy,¹ which denotes a pathologic intrinsic anomaly of an artery that can present in various forms. Cerebral arteriopathies can be congenital, reflecting abnormal vessel development, or acquired when caused by disruption of vascular homeostasis.² While distinguishing cerebral arteriopathies subtypes

can be challenging, it is an important step in aiding the clinical management and development of treatment strategies as each subtype can act differently.³ Previous efforts to aid in the identification and the classification of cerebral arteriopathies using consensus-based definitions (ie Childhood AIS Standardized Classification and Diagnostic Evaluation [CAS-CADE] criteria) have been refined over the years.^{3,4} In this article, we describe the most common childhood cerebral arteriopathies by reviewing their classification, presentation, diagnosis, treatment, and outcome.

Arteriopathy Classification

Classifications of childhood arteriopathies have evolved over the last 2 decades. In 2005, Wraige and colleagues proposed the first pediatric-specific classification for arteriopathy in AIS.⁵ They proposed three terms: moyamoya, craniocervical arterial dissection (CCAD), and steno-occlusive cerebral arteriopathy. Moyamoya and CCAD became widely utilized nomenclature, while steno-occlusive intracranial arteriopathies remained unclear with multiple overlapping terms such as transient cerebral arteriopathy (TCA), focal cerebral arteriopathy (FCA) and post-varicella arteriopathy (PVAR).⁶⁻⁸ In 2012, Bernard and colleagues proposed an updated classification, the CASCADE criteria, which suggested replacing

From the ^{*}Texas Children's Hospital, Baylor College of Medicine, Texas, TX, USA.

[†]Section of Neurology, Department of Pediatrics, Hemophilia & Thrombosis Center, University of Colorado, Aurora, Co, USA.

[‡]Hospital for Sick Children, University of Toronto, Ontario, Canada.

[§]Children's Hospital of Philadelphia, University of Pennsylvania, Philadelphia, PA, USA.

^{||}Children's Hospital Winnipeg, Department of Pediatrics and Child Health, Max Rady College of Medicine, University of Manitoba, Children's Hospital Research Institute of Manitoba, Manitoba, Canada.

Address reprint requests to Mubeen F. Rafay, Section of Pediatric Neurology, Department of Pediatric and Child Health, Children's Hospital Winnipeg, University of Manitoba, Children's Hospital Research Institute of Manitoba, AE 308, 820 Sherbrook Street, Winnipeg, Manitoba, Canada, R3A 1R9. E-mail: mubeen.rafay@alumni.utoronto.ca

Table 1 Cerebral Arteriopathy Classification

| |
|--|
| Focal cerebral Arteriopathy (FCA) |
| FCA – inflammatory subtype (FCA-i) |
| FCA – dissection subtype (FCA-d) |
| FCA – undetermined type (FCA-u) |
| Cranio-cervical Arterial Dissection |
| Anterior/Internal Carotid Artery Dissection –Traumatic/ Spontaneous |
| Posterior/Vertebral Artery Dissection - Traumatic/ Spontaneous |
| Moyamoya |
| With collaterals - Moyamoya Disease or Syndrome |
| Without collaterals - Moyamoya Disease or Syndrome |
| Genetic Arteriopathies |
| Syndromal |
| Non-Syndromal |
| Diffuse Multifocal Small Vessel Arteriopathy |
| Primary Central nervous System Vasculitis |
| Secondary Central nervous System Vasculitis |
| Other/Undetermined Arteriopathies |

steno-occlusive arteriopathy with the term FCA.⁴ The CASCADE criteria remains in use today, especially in the setting of standardized research studies. The definition of FCA has undergone several revisions. The current widely accepted definition is provided by the Vascular Infection in Pediatric Stroke (VIPS) investigators: FCA of childhood “is an acute, monophasic disease-causing unilateral stenosis of the intracranial cerebral arteries, mainly involving the anterior circulation.”⁹ In 2017, VIPS investigators created/tested a comprehensive classification scheme for childhood arteriopathies, which includes arterial dissection (internal carotid artery and vertebrobasilar), FCA (divided into subtypes described below), moyamoya, small vessel vasculitis, and others.¹⁰ They also categorized arteriopathies based on course/progression (progressive, stable, reversible, and indeterminate) and developed a scoring system to quantify severity of FCA, termed FCA severity score (FCASS).^{1,9} Currently, VIPS arteriopathy classifications and the FCASS are the most accepted classification tools to define and measure severity in childhood arteriopathies. Below sections will describe each arteriopathy subtype in detail, except secondary vasculitis and other/undetermined subtypes. (Table 1)

Arteriopathy Subtypes

Focal Cerebral Arteriopathy

Definition

FCA is one of the most common causes of pediatric AIS, accounting for approximately 1 quarter of arteriopathies causing stroke and an incidence ranging from 12% to 13% (year 2003-2014) in North America and 20%-26% (year 1984-2007) in Europe.^{2,8,11-13}

The most used definition characterizes FCA as a unifocal/unilateral stenosis or irregularity of the large intracranial anterior circulation arteries (distal ICA and/or its proximal

branches).¹⁰ The term “transient” or TCA was initially utilized by Chabrier to describe the clinical evolution of FCA in nine children presenting with acute hemiplegia and imaging evidence of stroke associated with the focal narrowing of the supraclinoid ICA, and/or proximal branching arteries, lack of collateral vessel development, in whom serial imaging showed initial worsening, and then regression or resolution of arteriopathy.¹³ Later studies of FCA have shown a similar dynamic and monophasic course and predilection for anterior circulation.^{12,14-16}

Classification

FCA can be subdivided into: FCA-inflammatory type (FCA-i) (includes PVAR occurring within 1-year of primary varicella infection, TCA, and other viral infection associated arteriopathies with similar dynamic course), FCA-dissection type (FCA-d), and FCA-undetermined type (FCA-u) that could not be further classified.¹⁰ This classification can be based on various clinical and imaging factors, for example¹⁰:

- FCA-i: characterized by presence of dysarthria, small infarcts in the lenticulostriate territory, infarct volume of <25 cm³, arterial banding, and isolated involvement of the proximal segment (M1) of the middle cerebral artery (MCA).
- FCA-d: representing dissection involving intracranial vessels and characterized by lack of vascular imaging features indicative of inflammation (banding, vessel wall irregularity, and enhancement), presence of trauma, and presence or absence of posterior circulation involvement

Risk Factors

FCA-i is presumably inflammatory in origin and can be either infectious (acute viral infection) or pos-infectious (post viral inflammation), leading to narrowing of the vessel and thrombus formation.¹¹ In the VIPS study, infection in the week prior to stroke conferred a 6.3-fold increased risk for stroke.¹⁷ Serological evidence of herpes simplex virus 1 and 2, and varicella infection have been associated with stroke.¹⁸ In a Swiss/Australian study, a history of varicella infection was seen in >1/4 of FCA cases.¹⁹ Abnormalities in inflammatory biomarkers, especially cerebrospinal fluid biomarkers, support active focal inflammation.²⁰ More studies are needed to establish whether FCA-i is caused by active viral infection or post viral inflammation.²¹ At presentation, there is often confusion regarding the course and the radiologic appearance of FCA-i which requires follow-up vascular imaging; FCA-i is typically focal, non-progressive, and self-limiting whereas a progressive course indicates either a more diffuse and progressive CNS inflammation or vasculitis that may require treatment with anti-inflammatory/immunomodulatory treatment.²²

Clinical Presentation

The most common presenting symptom in FCA-i is acute onset of hemiparesis with/without other associated findings, that can present as stuttering symptoms over days to weeks. In a study of 15 children with FCA, 6 had stuttering

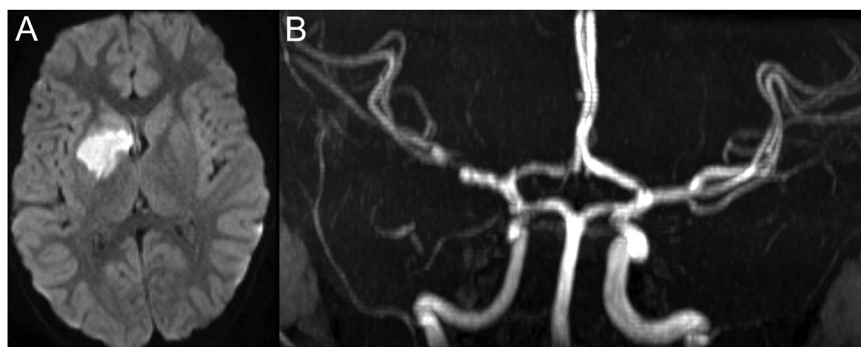


Figure 1 Focal cerebral arteriopathy (FCA). (A) Diffusion weighted imaging demonstrates an acute infarct in the region of the right basal ganglia and internal capsule. (B) Magnetic resonance angiography (MRA) demonstrates irregularity and narrowing in the proximal middle cerebral artery and anterior cerebral artery. The right middle cerebral artery demonstrates a “banded” morphology.

symptoms during 1-4 days prior to stroke.¹¹ Headache is another common symptom, reported in 7 of the 15 children.^{10,11}

Biomarker profiles have also been studied for stroke secondary to arteriopathy showing a possible link between increased inflammatory markers, progression of arteriopathy, and stroke recurrence.²³ VIPS cohort data indicates that elevated C-reactive protein levels, but no other inflammatory markers, correlated with FCASS.⁹

Imaging Features

On vascular imaging, FCA-i can be demonstrated as varying degrees of vascular stenosis and/or irregularity, with most

common areas of involvement being ICA terminus, and its proximal branches (Fig. 1). A characteristic “banded” appearance, particularly in the proximal MCA, is seen in 24% of cases (Fig. 1).^{8,10,13} These lesions may be transient, stable, or progress (Fig. 2).

Cerebral arteriopathy severity scores have been developed earlier^{14,24} considering severity and involvement of vascular segments and territories. FCASS, a 5-level grading to 5 arterial segments, was later developed based on 41 patients in the VIPS study⁹ (Fig. 3). This score did not correlate with rate of stroke recurrence, but the maximum (not baseline) score did correlate with 1-year stroke outcome. High resolution vessel wall imaging, with and without contrast, may be

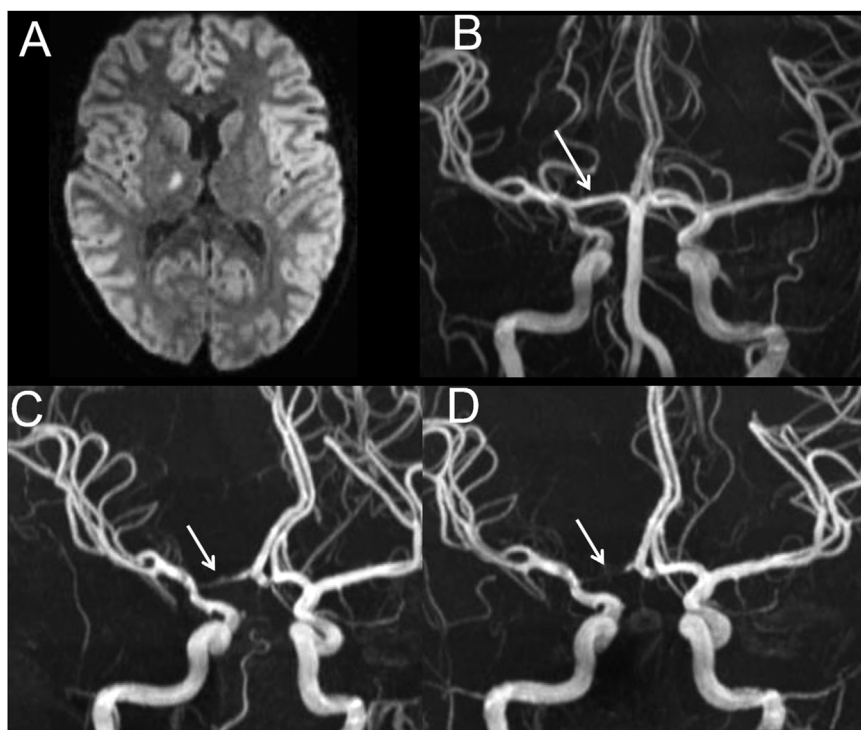


Figure 2 Vascular changes in focal cerebral arteriopathy on follow-up. (A) Diffusion weighted imaging demonstrates an acute infarct on the right. (B) Initial MRA shows a symmetric narrowing of the distal right internal carotid artery. On subsequent follow-up examinations (C and D), there is progressive narrowing of the A1 segment of the right anterior cerebral artery.

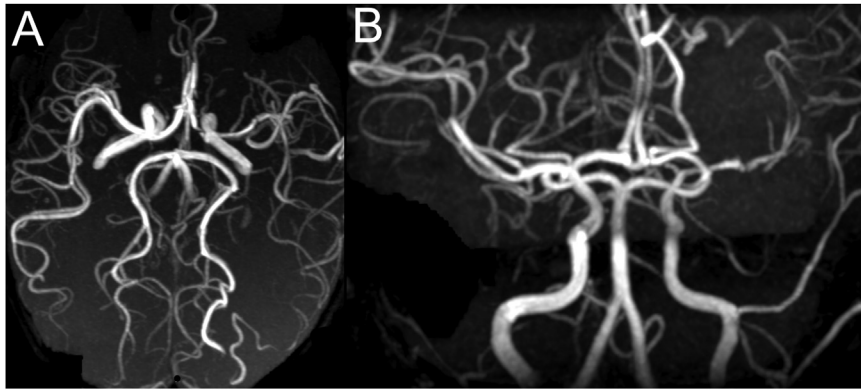


Figure 3 Focal cerebral arteriopathy severity score (FCASS). (A) axial and (B) coronal projection MRA of a patient with left sided FCA. There is less than 50% narrowing of the left internal carotid artery and left M2 segments, more than 50% narrowing of the left M1 and A1 segments, and normal caliber of the left A2 segment (FCASS = 10).

of benefit in the diagnosis of FCA-i and determination of FCA subtypes (Fig. 4). There are, however, pitfalls in the interpretation of vessel wall imaging. In a small series, strong vessel wall enhancement was associated with progressive arteriopathy.²⁵ In another small series, the FCASS did correlate with outcome, infarct progression, and recurrence.²⁶ However, vessel wall enhancement did not correlate with FCASS, infarct size/progression, risk of stroke recurrence or outcome. More importantly, these investigators reported that not all patients with FCA-i demonstrated vessel wall enhancement.

Treatment

Among childhood stroke etiologies, antithrombotic use is common, with high rates of use reported over time.³ Both antiplatelet (mainly aspirin dosed at 3-5 mg/kg once daily) and anticoagulant agents (low-molecular-weight heparin [LMWH], warfarin) are utilized.¹⁹ The choice of which agent to use often takes into consideration multiple factors including the level of clot burden, overall risk of further clotting,

activity level of the child, comfort with administration, and discussion of the risks and benefits of each.

Another controversial treatment option in FCA-i is steroid therapy. In a small retrospective study looking at consecutive children with FCA-i, 29% received corticosteroids plus antithrombotic treatment and the rest received antithrombotic treatment alone. The steroid plus antithrombotic group had better clinical outcomes, specifically cognitive and behavior outcomes. However, no difference was seen in stroke recurrence rates.¹⁹ Through expert survey, the most common indication for steroid use was progression of arteriopathy severity.²⁷ Further studies on this treatment option are ongoing.

If there is recurrence of stroke, consideration of escalation of antithrombotic therapy is recommended. This may include addition of an antiplatelet drug to the original antithrombotic agent (eg adding clopidogrel to aspirin or aspirin to LMWH). If recurrence seems to be associated with hypotension, blood pressure elevating medications, like fludrocortisone, could be considered.

The duration of antithrombotic use is uncertain in FCA-i and often highly debated. Many pediatric stroke physicians

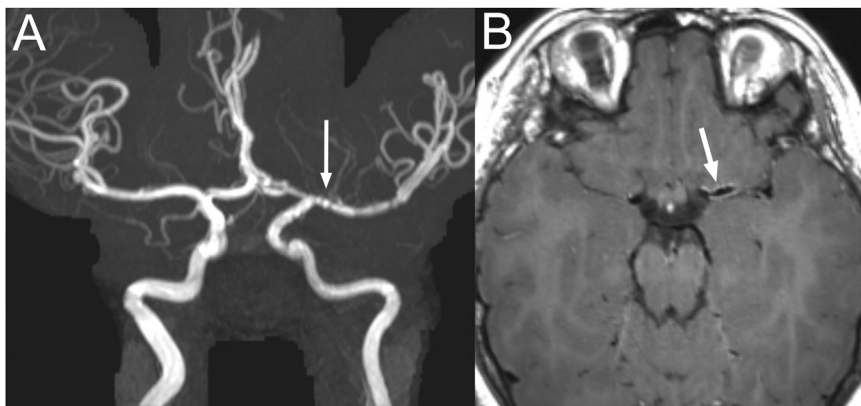


Figure 4 Vessel wall imaging in a patient with focal cerebral arteriopathy, inflammatory type (FCA-i). (A) Magnetic resonance imaging demonstrates irregularity and narrowing of the distal internal carotid artery, proximal anterior cerebral artery, and proximal middle cerebral artery, with banding of the proximal middle cerebral artery (arrow). (B) High resolution black blood arterial wall imaging demonstrates contrast enhancement in the slightly irregular left middle cerebral artery wall (arrow).

use follow-up imaging to guide treatment duration as the evolution of FCA-i can vary. If there is resolution of vasculopathy, one may consider discontinuing antithrombotic therapy. However, many children could remain on antithrombotic therapy for many years.

Outcome

FCA-i is a monophasic disorder but has a dynamic course that is associated with an increased risk for recurrent vascular events, up to 25% within 1-year.^{12,13,23} Clinical outcomes are variable and have been associated with poor FCASS score.²³ In a report of 79 patients, approximately 40% recovered completely or had mild deficits, especially in those with normalizing arteriopathy.¹² Similarly, in a report of 15 patients with FCA-i, about half had none or mild long-term deficits.¹¹

Craniocervical Arterial Dissection

Definition

CCAD is the result of a tear in the tunica intima of an artery allowing blood to accumulate within the vessel wall layers. A hematoma could form between the intima and the media layers, occluding the vessel lumen and impairing blood flow, or collect between the media and the adventitia layers, which may result in pseudoaneurysm formation and vessel rupture with the risk for subarachnoid hemorrhage.^{28,29} Approximately 1/4 of children diagnosed with an arteriopathy are diagnosed with CCAD.^{3,8} Furthermore, a unilateral arteriopathy involving a cervical artery, or a posterior circulation stroke are highly suggestive of CCAD.¹⁰

Classification

CCAD can be further classified by location (intra- or extracranial), artery involvement (carotid or vertebrobasilar) and etiology (spontaneous or traumatic). As above, intracranial dissection involving the anterior circulation may be categorized as FCA-d.¹⁰ Reportedly, many spontaneous dissections are associated with trivial trauma.³⁰

Risk Factors

Risk factors for CCAD include head/neck trauma, cervical spine anomalies, migraine, infection, and various monogenetic conditions eg inherited connective tissue disorders (CTD), polycystic kidney disease, pseudoxanthoma elasticum, homocysteinemia, fibromuscular dysplasia, and α -1-antitrypsin deficiency.^{31,32}

Among the CTD, Ehlers-Danlos syndrome (EDS) is associated with a high risk of spontaneous carotid and vertebral artery dissection and cerebral aneurysms.³³ EDS type IV, secondary to COL3A1 gene mutation, carries the highest risk of CCAD and stroke.³³⁻³⁵ Marfan syndrome is another CTD associated with CCAD.³³

Causative monogenetic variants are not found in the majority of CCAD patients, neither do the majority meet criteria for any of the known CTD; therefore, the etiology typically remains unknown.^{36,37} However, a variety of factors suggest that CCAD may have major genetic susceptibility. These include: a positive family history of CCAD, the risk of recurrence despite anti-thrombotic treatment, and the link with genes associated with CTD.^{36,38-41}

Another relevant risk factor is male gender.^{3,10,42} This finding may be due to the increased likelihood of males sustaining trauma.²² A report on the epidemiology of traumatic brain injury, males had a 1.4-fold increased risk of having TBI compared to females in high income countries. This increased with age to 2.2 in older children and teenagers.⁴³ CCAD also tends to be present in older children compared to other arteriopathy subtypes.³

Bow hunter syndrome (BHS) refers to a constellation of symptoms associated with vertebrobasilar insufficiency usually triggered by the obliteration of a vertebral artery with head rotation. BHS must be suspected when a patient presents with typical symptoms (ie vertigo, ataxia, dizziness, diplopia, dysarthria, and hemisensorimotor deficits) and imaging shows dilatation affecting the V3 segment of a vertebral artery. As discussed below, BHS requires positional imaging for its diagnosis. In many cases, multiple ischemic events have already occurred before this diagnosis is made.⁴⁴

Clinical Presentation

Symptom onset after arterial dissection could vary from hyperacute or being delayed by several weeks, but typically in hours to 7 days.³⁰ The clinical presentation can be broad and variable in concordance with the vascular territory affected and could be non-specific as in the context of a posterior circulation stroke.⁴⁵ The most commonly described symptoms include headache, neck/facial pain, visual abnormalities, nausea, emesis, ataxia, and vertigo.^{10,42,45} Other symptoms include decreased alertness, dysarthria, tinnitus, hemisensorimotor deficits, cranial nerve palsies, and seizures.^{3,30,45}

Headache and neck/facial pain are common symptoms in CCAD, present in 39%-78% of patients.^{3,28} Horner's syndrome (HS) is another widely described symptom usually with dissections of the ICA. This is due to disruption of sympathetic fibers from the superior cervical ganglion.^{28,46}

Imaging Features

The hallmark of definitive imaging diagnosis of CCAD is a demonstration of an intimal dissection flap. However, this may not always be possible in the small craniocervical vessels, and the diagnosis may rely on several secondary imaging signs. After the formation of the intramural hematoma, there may be smooth tapered narrowing of the artery caused by vessel narrowing and occlusion (flame sign), a very small persisting arterial lumen (string sign), or transmural extension due to disruption of the vascular wall leading to the formation of a pseudoaneurysm (dissecting aneurysm). Various

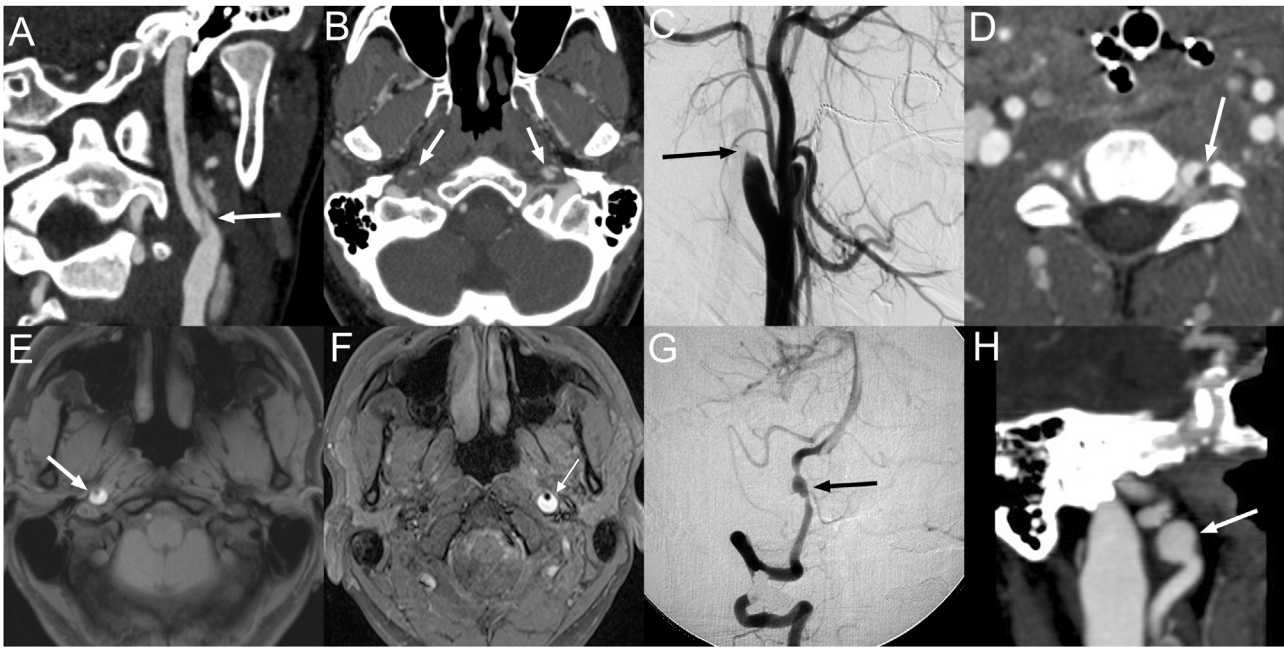


Figure 5 Various imaging manifestations of craniocervical arterial dissection. (A) Linear dissection flap in the internal carotid artery (arrow). (B) Bilateral internal carotid artery dissection showing a linear dissection flap in the left internal carotid artery and marked narrowing of the right internal carotid artery (arrows). (C) Catheter angiogram showing smooth tapered narrowing of the internal carotid artery secondary to dissection (so-called flame sign) (arrow). (D) Contour irregularity with a relatively hypodense intramural hematoma in the left vertebral artery wall secondary to vertebral artery dissection (arrow). (E) Fat-saturated T1-weighted MRI of the upper neck demonstrates a T1 hyperintense blood products and intramural hematoma in the internal carotid artery wall (arrow). (F) High resolution T1-weighted vessel wall imaging demonstrating hyperintense hematoma in the internal carotid artery wall with luminal narrowing (arrow). (G) Pseudoaneurysm formation secondary to the right vertebral artery dissection (dissecting aneurysm). (H) Pseudoaneurysm of the left internal carotid artery following carotid dissection (arrow).

imaging modalities can show the primary and secondary manifestations of arterial dissection (Fig. 5). The most common location of vertebral artery dissection is at the C1-2 level (53%).³⁰ Imaging may also demonstrate the underlying arterial anomalies that predispose patients to CCAD (eg fibromuscular dysplasia).

Conventional catheter angiography has historically been considered the gold standard for diagnosis of CCAD, but it does have some limitations. The main limitation of catheter angiography is that it only depicts the vascular lumen. Therefore, if the vessel caliber does not change and a dissection flap is not seen, conventional angiography may miss arterial dissection.⁴⁷ Small dissection flaps may be obscured by the inherent summation shadowgram nature of this technique.

Magnetic resonance imaging (MRI) and angiography (MRA), using both time-of-flight MRA and contrast enhanced MRA techniques, are often diagnostic but may not detect all cases.⁴⁸ All main imaging features of dissection can be potentially detected, depending on the MRI technique used.⁴⁸ Addition of T1-weighted images with fat suppression to look for intramural hematoma (often eccentric) can improve diagnostic ability.⁴⁷ High-resolution vessel wall imaging can also assist in detection of an intramural hematoma.^{49,50}

High resolution CT angiography can also allow similar results (Fig. 5), although this is not always easy. In many cases of posterior circulation stroke, the cause is not determined easily by CT or MR imaging. In BHS, transient

occlusion of the vertebral artery is thought to be possible with the rotation of the head and cervical spine (Fig. 6).^{44,51} This may be due to excessive vertebral motion in the upper cervical spine, vertebral developmental anomalies, and osseous/ligamentous bridges around the vertebral foramina. In cases of suspicion for BHS, assessment of the vertebral arteries in the neutral and rotated position can be performed for assessment of the anatomic narrowing. Nevertheless, the exact role of this presumably rare entity needs to be fully defined since it is not quite known how often transient narrowing of the vertebral artery can occur upon rotation in normal individuals.⁵²

Treatment

Both antiplatelet and anticoagulation therapy have been used in CCAD cases. In adults, there was no difference in stroke recurrence between antiplatelet and anticoagulation use at both 3-month and 12-month follow up.⁵³ In children, anticoagulation has been used more commonly for CCAD (mostly extracranial dissection), although current data does not show superiority of anticoagulation over antiplatelet therapy.³ The decision regarding treatment choice includes similar decision-making factors as previously noted for FCA-i. If recurrent strokes occur, one may consider escalation from antiplatelet to anticoagulation therapy, dual treatment and/or endovascular interventions.

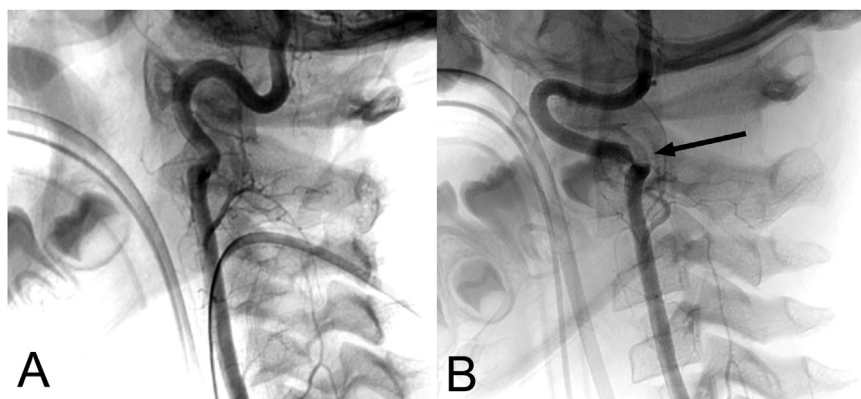


Figure 6 Narrowing of the vertebral artery on dynamic neck angiography in presumed bow hunter syndrome. (A) In the neutral position, there is normal flow in the cervical vertebral artery. (B) With lateral turning of the neck, there is induced focal narrowing of the vertebral artery (arrow).

In the 2019, the American Heart Association acute stroke management guidelines for adults, extracranial dissection is not a contraindication to intravenous alteplase. Although it has not been studied in children, it would be reasonable to consider intravenous alteplase in a child with an extracranial dissection and an ischemic stroke.⁵⁴ Similarly, endovascular treatment (mechanical thrombectomy, stenting) has been reported to be successful in adults with extracranial dissection but it has not been studied in children.⁵⁵

Pseudoaneurysm management can range from conservative with antiplatelet or anticoagulation therapy to carotid artery ligation, stenting, and other endovascular interventions.⁵⁶

Short-term treatment for pediatric BHS includes an antithrombotic agent and cervical spine activity restriction with a collar, whereas long-term options may include decompression of the affected artery or cervical spinal fusion.⁵⁷

The duration of antithrombotic therapy in children with CCAD is uncertain. Adult data recommends secondary stroke prevention with antithrombotic therapy for at least 3 months. Follow-up imaging to evaluate the injured vessel at 3-6-months may be helpful in directing the length of therapy.⁵⁸

Outcome

CCAD has been associated with significant mortality, mainly in cases with intracranial anterior circulation involvement.³² Recurrent arterial dissection has been described in 10% of cases, whereas recurrent ischemic stroke rates vary from 12% to 20%, mainly within the first year after diagnosis.^{32,59,60} Patients with vertebral artery dissecting aneurysms, as often seen in pediatric BHS, have an even high recurrence rate (>50% in first year).⁶¹ More than two thirds of patients with CCAD will have a permanent neurological deficit.³² A recent study reported a similar short and long-term outcome when compared to other arteriopathies.³

Moyamoya

Moyamoya arteriopathy accounts for 5%-10% of childhood AIS etiologies and is characterized by progressive stenosis/occlusion of the basal arteries of the circle of Willis and

abnormal small collateral vessel development, giving the typical puff of smoke appearance (moyamoya in Japanese).⁶²⁻⁶⁵ Japanese and other East Asians have the highest incidence (Japanese 1/1,000,000 and non-Japanese 0.085/1,000,000 person/year).⁶⁴ Etiology remains unclear; although, many associations are reported.⁶⁴ Ischemic strokes are common in young and hemorrhagic strokes in older patients.^{62,64} Recurrent headaches and TIA's with provocation (hyperventilation, illness) are typical presentations.⁶⁶ Asymptomatic cases are common with genetic/syndromic associations. Management is complex and requires a multidisciplinary approach (avoidance of triggers, antiplatelet therapy, and cerebral revascularization surgery considerations).⁶⁷⁻⁶⁹ Moyamoya in detail is discussed separately in another article.

Genetic/Syndromal Arteriopathies

Definition

Cerebrovascular abnormalities associated with genetic disorders and syndromes, that are not accounted by another etiology, are considered under the umbrella of genetic/syndromal cerebral arteriopathies. Their early recognition is important due to their potential for progression and risk for stroke. Typically, the large and medium cerebral arteries are involved, except in a few where small sized vessels may be involved.⁷⁰⁻⁷² Genetic cerebral arteriopathies are often accompanied by the cervical and/or other systemic vessel (eg aorta, renal, iliac, and mesenteric arteries) and non-vascular body system abnormalities (eg cardiac, ophthalmic, dermatologic, renal, and hepatic). Their coexisting involvement supports a genetic origin and requires careful investigation, particularly in cases with unidentified/unclear genetic association.

Classification

Genetic arteriopathies can be categorized into syndromal (either genetic or non-genetic) or non-syndromal genetic arteriopathies (Table 2), whereas based on their course they can be further categorized into non-progressive (static) or progressive (evolving). Non-progressive arteriopathies are

Table 2 Genetic Arteriopathies

| Syndromal | Non-syndromal |
|--|--|
| Chromosomal disorders | |
| Trisomy 21 (Down syndrome) | Moyamoya (MYMY 1-chromosome 3 locus) |
| Turner syndrome | |
| Noonan syndrome | |
| Chromosome Xq28 Deletion Syndrome | |
| Congenital Dysgenetic Embryopathies | |
| PHACES syndrome | Fibromuscular Dysplasia |
| Alagille syndrome | |
| Monogenic Disorders | |
| <i>Connective tissue disorders</i> | |
| Marfan syndrome | Pseudoxanthoma Elasticum |
| Ehler Danlos syndrome | |
| Loeys-Dietz syndrome | |
| Cutis Laxa | |
| Arterial Tortuosity syndrome | |
| Costello syndrome | |
| <i>Vasculopathies</i> | |
| Grange syndrome | ACTA2 |
| Williams-Beuren syndrome | DADA2 |
| Aicardi-Goutières syndrome | RNF213 |
| Primordial Dwarfism type II (MOPDII) | GUCY1A3 |
| Seckel syndrome | COL4A1/A2 NOTCH3 (CADASIL) HTRA1 (CARASIL) |
| <i>Neurocutaneous disorders</i> | |
| Neurofibromatosis 1 (NF1) | Hereditary Hemorrhagic Telangiectasias (HHT1, HHT2) |
| Hypomelanosis of Ito | |
| Sturge Weber syndrome | |
| <i>Hematological disorders</i> | |
| Schimke's Immuno-osseous Dysplasia | Sickle Cell Anemia Fanconi Anemia |
| <i>Metabolic disorders</i> | |
| Menkes disease | Homocystinuria |
| Pompe disease | Hyperhomocysteinemia |
| Congenital disorders of Glycosylation | Fabry's Disease |
| Mitochondrial disorders (eg Leigh's Syndrome, MELAS) | Cerebrotendinous Xanthomatosis Organic Acidemias Congenital Disorders of Glycosylation Cystinosis Mitochondrial Disorders (eg ND-5, POLG, OPA-1 and Complex III related disorders) |

typically congenital dysplastic/hypoplastic arteries recognized during early childhood as part of a genetic/syndromic association (eg Alagille syndrome) on screening investigations.²¹ Progressive genetic arteriopathies may evolve or

develop on a background of normally developed arteries (eg moyamoya with neurocutaneous disorders).⁷¹ Both types are associated with stroke, but the risk is substantially higher with progressive arteriopathies.

Incidence and Prevalence

Molecular advancements have significantly improved the identification and understanding of genetic arteriopathies, especially single gene disorders, however their exact incidence remains limited to specific conditions. In the international pediatric stroke study (IPSS), a genetic cause was estimated in 11% (77/674) of cases presenting with any AIS etiology,⁷³ whereas this risk estimation was higher [17% (126/725)] among cases associated with a congenital arteriopathy.³ Prevalence rates relating to progressive arteriopathies and specific genetic conditions have been better described, for example, 26-fold increased risk with Trisomy 21,^{68,69} arteriopathic abnormalities in 2%-8% neurofibromatosis type 1 (NF1),^{71,74-82} and 83%-91% of syndromal cases such as PHACES syndrome.^{72,83,84} This data is from several years ago and likely underestimates the prevalence of this condition due to the lack of more recent data and standard or adequate categorization of genetic arteriopathies.

Pathogenesis

Exact pathogenetic mechanisms are not well understood, except for arteriopathies associated with monogenic disorders.²¹ Even then, an exact genotype-phenotype correlation may not be available. In syndromal arteriopathies with unknown gene abnormality (eg PHACES) postulated mechanisms for defective vascular development include defects in endothelial cell maturation, differentiation, and proliferation during embryogenesis. In syndromal and non-syndromal arteriopathies with known gene abnormality (eg ACTA2, COL4A) pathogenetic mechanisms vary based on the genetic defect and may affect one or more arterial wall layers.⁸⁵ These include abnormalities of basement membrane integrity (COL4A, NF1), smooth muscle proliferation (ACTA2, NF1), collagen and proteoglycans development causing basement membrane, elastic lamina and extracellular matrix defects (Ehlers-Danlos, Marfan, NF1), and vascular remodeling in response to arterial injury or milieu (NOTCH3, JAG1, SLC2A10, ATP7A, and HBSS), abnormal metabolite accumulation (Homocystinuria, Fabry's disease) and energy substrate deficiency (MERRF, MELAS).^{21,85-87}

Clinical Presentation

Asymptomatic presentations are common with genetic arteriopathy, with at least half identified upon screening for underlying conditions. Symptomatic presentations correlate with the severity of vascular manifestations and radiologic progression.^{72,76,78,79,83,84} Due to heterogeneity among genetic arteriopathies, stroke risk is variable and difficult to quantify. In children, the approximate risk for any stroke due to a genetic cause is estimated to be 2%-11%.^{73,88} Odds of any stroke are higher with genetic arteriopathies (general population 1.2:1 vs NF1 3.4:1 AIS, and 8.1:1 hemorrhagic stroke and Marfans, 1.2:1 AIS and 1.75:1 hemorrhagic

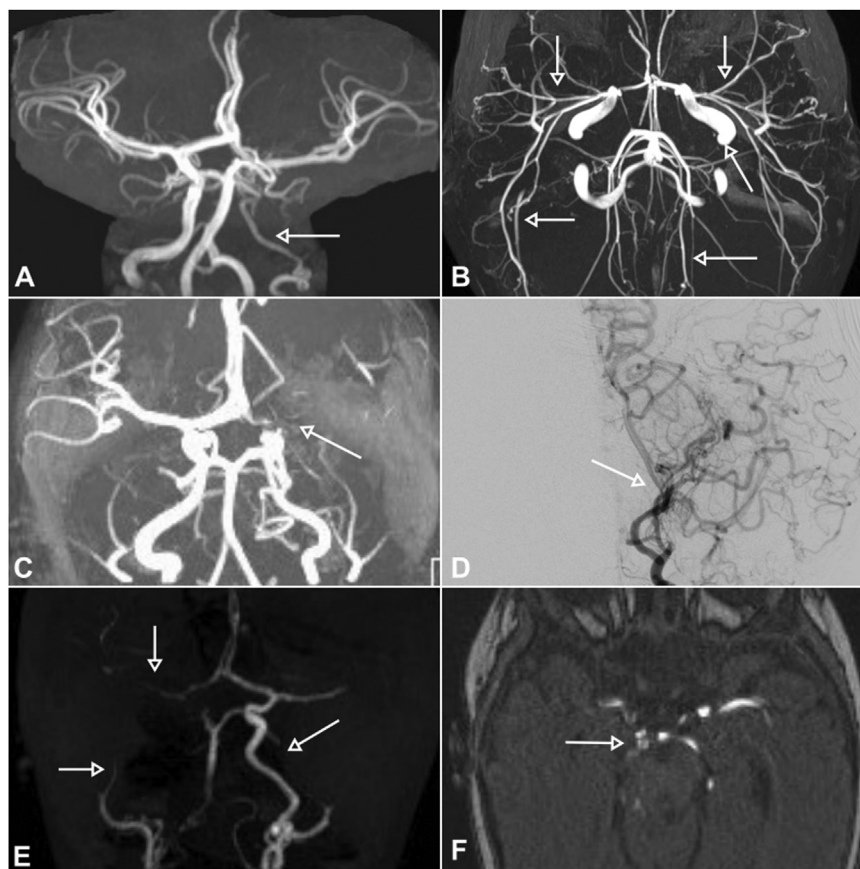


Figure 7 Neurovascular imaging findings in Genetic Arteriopathies. (A) Time of flight MR angiogram showing unilateral smooth narrowing of the entire left internal carotid artery in a 4-month-old infant with PHACE syndrome. (B) Time of flight MR angiogram showing typical dilatation of bilateral proximal internal carotid, basilar and right vertebral arteries along with severe thinning and straightening of their peripheral branches in a 3-year-old with ACTA2 disorder. (C, and D) Time-of-flight MR and cerebral catheter angiogram showing unilateral narrowing of the proximal and lack of visualization of the distal left internal carotid artery terminus and middle and anterior cerebral arteries with few surrounding collateral vessels in a 10-year-old with Neurofibromatosis Type 1. (E and F) Time of flight and contrast enhanced MR Angiogram demonstrating lack of visualization of the right internal carotid, middle cerebral and anterior cerebral (A1 segment) arteries and tortuous right posterior cerebral artery in a 6-month-old infant with PHACES syndrome.

stroke).^{33,89} However, stroke is often multifactorial due to other accompanying risk factors. Like other arteriopathies, stroke presentations are typical (hemisensorimotor deficits 80%, seizures 20%-40%, headache 50%, stuttering onset/recurrent provoked TIAs 30%-40%).^{3,68,71,73,75,78,79,84,88,6,90}

Imaging Features

Arteries of the circle of Willis, mainly ICA, MCA, ACA, are most frequently affected (75% - 85%).^{3,71} Although the radiologic appearance of genetic/syndromal arteriopathies is highly variable and dependent upon underlying condition, some are characterized by almost pathognomonic features thereby facilitating early diagnosis. The observed arteriopathic abnormalities in genetic/syndromic conditions may consist of one or more of the following: dysgenetic, hypoplastic, malformed, abnormally positioned, kinked, straight/elongated arteries (typically in ACTA 2), abnormal origin and course and smooth narrowing, stenosis, occlusion,

aneurysm formation, ectasia or tortuosity of arteries and moyamoya.^{71,72,75,82,84,91,92} (Fig. 7) Moreover, these are frequently associated with abnormal collateral vessel development. With congenital cerebral arteriopathies, collateral vessels typically develop between large or medium vessels, whereas with progressive arteriopathies collaterals consist of tiny deep intracranial perforating vessels sprouting from severely stenotic/occluded arteries. In PHACE syndrome, dysgenesis of craniocervical arteries (56%) is the commonest finding, followed by the abnormal vascular origin/course (47%), narrowing (39%), occlusion (20%) and/or primitive embryonic connections (20%),⁸⁴ along with 1 major cerebral artery involvement in 86%, 2 or more in 68%, and aortic arch abnormalities in 59%.⁷²

Treatment and Surveillance

Any treatment intervention depends upon the underlying genetic condition, coexisting risk factors and risk estimates

for stroke, stroke type, and nature of vascular abnormalities. Stroke risk is typically stratified into: low-risk (not associated with the hemodynamic changes/turbulence eg abnormal origin/course of artery, persistent embryonic artery, or anatomic variations), intermediate-risk (dysgenetic, non-visualized or narrowed/hypoplastic arteries, with/without collateral anastomosis and without hemodynamic changes) and high-risk (severe stenotic, occluded or tortuous arteries without adequate collaterals and with hemodynamic alterations or presence of other stroke risk factors).⁸³

As in other arteriopathy subtypes, stroke prophylaxis with antiplatelet therapy is the mainstay treatment for medium to high-risk, and sometimes even with low risk genetic arteriopathies.⁶⁸ Duration of therapy is unknown and often long term given the persistent nature of arteriopathies. Progressive arteriopathies are managed according to the specific cerebral arteriopathy and/or genetic condition management guidelines, for example, revascularization surgery, arterial ligation, by-pass or stenting.^{68,69,93}

Clinical and neuroimaging screening and surveillance is important, as most genetic arteriopathies are asymptomatic and progressive. Unfortunately, consensus data regarding frequency and duration of surveillance is lacking. In general, high-risk conditions are monitored radiologically at 3-6-month intervals, whereas low-risk cases may be imaged annually.

Outcome

Given the heterogeneity of genetic arteriopathies/conditions, outcomes are highly variable. In general, children with a significant parenchymal and progressive vascular abnormalities have poor outcomes, with increased risk for neurologic sequelae and stroke recurrence. Clinical outcomes are better if presence and progression of arteriopathy is identified and managed promptly.⁷¹

Declaration of interests

The authors declare that they have no known competing financial interests or personal relationships that could have appeared to influence the work reported in this paper.

Disclosures

None.

Conflict of Interests

None

Acknowledgments

None

References

1. Wintermark M, Hills NK, deVeber GA, et al: Arteriopathy diagnosis in childhood arterial ischemic stroke: results of the vascular effects of infection in pediatric stroke study. *Stroke* 45:3597-3605, 2014. <https://doi.org/10.1161/STROKEAHA.114.007404>
2. McCrea N, Fullerton HJ, Ganesan V: Genetic and environmental associations with pediatric cerebral arteriopathy. *Stroke* 50:257-265, 2019. <https://doi.org/10.1161/STROKEAHA.118.020479>
3. Rafay MF, Shapiro KA, Surmava AM, et al: Spectrum of cerebral arteriopathies in children with arterial ischemic stroke. *Neurology* 94:e2479-e2490, 2020. <https://doi.org/10.1212/WNL.00000000000009557>
4. Bernard TJ, Manco-Johnson MJ, Lo W, et al: Towards a consensus-based classification of childhood arterial ischemic stroke. *Stroke* 43:371-377, 2012. <https://doi.org/10.1161/STROKEAHA.111.624585>
5. Wraige E, Pohl KR, Ganesan V: A proposed classification for subtypes of arterial ischaemic stroke in children. *Dev Med Child Neurol* 47:252-256, 2005. <https://doi.org/10.1017/s0012162205000484>
6. Braun KP, Rafay MF, Uiterwaal CS, Pontigon AM, DeVeber G: Mode of onset predicts etiological diagnosis of arterial ischemic stroke in children. *Stroke* 38:298-302, 2007. <https://doi.org/10.1161/01.STR.0000254484.10680.c6>
7. Lanthier S, Armstrong D, Domi T, deVeber G: Post-varicella arteriopathy of childhood: natural history of vascular stenosis. *Neurology* 64:660-663, 2005. <https://doi.org/10.1212/01.WNL.0000151851.66154.27>
8. Amlie-Lefond C, Bernard TJ, Sébire G, et al: Predictors of cerebral arteriopathy in children with arterial ischemic stroke: results of the International Pediatric Stroke Study. *Circulation* 119:1417-1423, 2009. <https://doi.org/10.1161/CIRCULATIONAHA.108.806307>
9. Fullerton HJ, Stence N, Hills NK, et al: Focal cerebral arteriopathy of childhood: novel severity score and natural history. *Stroke* 49:2590-2596, 2018. <https://doi.org/10.1161/STROKEAHA.118.021556>
10. Wintermark M, Hills NK, DeVeber GA, et al: Clinical and imaging characteristics of arteriopathy subtypes in children with arterial Ischemic stroke: results of the VIPS study. *AJNR Am J Neuroradiol* 38:2172-2179, 2017. <https://doi.org/10.3174/ajnr.A5376>
11. Oesch G, Perez FA, Wainwright MS, Shaw DWW, Amlie-Lefond C: Focal cerebral arteriopathy of childhood: clinical and imaging correlates. *Stroke* 52:2258-2265, 2021. <https://doi.org/10.1161/STROKEAHA.120.031880>
12. Braun KP, Bulder MM, Chabrier S, et al: The course and outcome of unilateral intracranial arteriopathy in 79 children with ischaemic stroke. *Brain* 132:544-557, 2009. <https://doi.org/10.1093/brain/awn313>
13. Chabrier S, Rodesch G, Lasjaunias P, et al: Transient cerebral arteriopathy: a disorder recognized by serial angiograms in children with stroke. *J Child Neurol* 13:27-32, 1998. <https://doi.org/10.1177/088307389801300105>
14. Danchaivijitr N, Cox TC, Saunders DE, Ganesan V: Evolution of cerebral arteriopathies in childhood arterial ischemic stroke. *Ann Neurol* 59:620-626, 2006. <https://doi.org/10.1002/ana.20800>
15. Yeon JY, Shin HJ, Seol HJ, et al: Unilateral intracranial arteriopathy in pediatric stroke: course, outcome, and prediction of reversible arteriopathy. *Stroke* 45:1173-1176, 2014. <https://doi.org/10.1161/STROKEAHA.113.004125>
16. Fearn ND, Mackay MT: Focal cerebral arteriopathy and childhood stroke. *Curr Opin Neurol* 33:37-46, 2020. <https://doi.org/10.1097/WCO.0000000000000787>
17. Fullerton HJ, Hills NK, Elkind MS, et al: Infection, vaccination, and childhood arterial ischemic stroke: Results of the VIPS study. *Neurology* 85:1459-1466, 2015. <https://doi.org/10.1212/WNL.0000000000002065>
18. Elkind MS, Hills NK, Glaser CA, et al: Herpesvirus Infections and Childhood Arterial Ischemic Stroke: Results of the VIPS Study. *Circulation* 133:732-741, 2016. <https://doi.org/10.1161/CIRCULATIONAHA.115.018595>
19. Steinlin M, Bigi S, Stojanovski B, et al: Focal Cerebral Arteriopathy: Do Steroids Improve Outcome? *Stroke* 48:2375-2382, 2017. <https://doi.org/10.1161/STROKEAHA.117.016818>
20. Kothur K, Troedson C, Webster R, et al: Elevation of cerebrospinal fluid cytokine/chemokines involved in innate, T cell, and granulocyte inflammation in pediatric focal cerebral arteriopathy.

- Int J Stroke 14:154-158, 2019. <https://doi.org/10.1177/1747493018799975>
21. Sporns PB, Fullerton HJ, Lee S, et al: Childhood stroke. *Nat Rev Dis Primers* 8:12, 2022. <https://doi.org/10.1038/s41572-022-00337-x>. Published 2022 Feb 24
 22. Tolani AT, Yeom KW, Elbers J: Focal Cerebral Arteriopathy: The Face With Many Names. *Pediatr Neurol* 53:247-252, 2015. <https://doi.org/10.1016/j.pediatrneurol.2015.05.008>
 23. Fullerton HJ, deVeber GA, Hills NK, et al: Inflammatory biomarkers in childhood arterial ischemic stroke: correlates of stroke cause and recurrence. *Stroke* 47:2221-2228, 2016. <https://doi.org/10.1161/STROKEAHA.116.013719>
 24. Sultan SM, Beslow LA, Vossough A, et al: Predictive validity of severity grading for cerebral steno-occlusive arteriopathy in recurrent childhood ischemic stroke. *Int J Stroke* 10:213-218, 2015. <https://doi.org/10.1111/ijvs.12344>
 25. Stence NV, Pabst LL, Hollatz AL, et al: Predicting Progression of Intracranial Arteriopathies in Childhood Stroke With Vessel Wall Imaging. *Stroke* 48:2274-2277, 2017. <https://doi.org/10.1161/STROKEAHA.117.017922>
 26. Perez FA, Oesch G, Amlie-Lefond CM: MRI Vessel Wall Enhancement and Other Imaging Biomarkers in Pediatric Focal Cerebral Arteriopathy-Inflammatory Subtype. *Stroke* 51:853-859, 2020. <https://doi.org/10.1161/STROKEAHA.119.027917>
 27. Park Y, Fullerton HJ, Elm JJ: A pragmatic, adaptive clinical trial design for a rare disease: The FOCal Cerebral Arteriopathy Steroid (FOCAS) trial. *Contemp Clin Trials* 86. <https://doi.org/10.1016/j.cct.2019.105852>, 2019. 105852
 28. Schievink WI: Spontaneous dissection of the carotid and vertebral arteries. *N Engl J Med* 344:898-906, 2001. <https://doi.org/10.1056/NEJM200103223441206>
 29. Núñez DB Jr, Torres-León M, Múnera F: Vascular injuries of the neck and thoracic inlet: helical CT-angiographic correlation. *Radiographics* 24:1087-1100, 2004. <https://doi.org/10.1148/rg.244035035>
 30. Fullerton HJ, Johnston SC, Smith WS: Arterial dissection and stroke in children. *Neurology* 57:1155-1160, 2001. <https://doi.org/10.1212/wnl.57.7.1155>
 31. Bertamino M, Severino M, Grossi A, et al: ABCC6 mutations and early onset stroke: Two cases of a typical Pseudoxanthoma Elasticum. *Eur J Paediatr Neurol* 22:725-728, 2018. <https://doi.org/10.1016/j.ejpn.2018.04.002>
 32. Rafay MF, Armstrong D, Deveber G, et al: Craniocervical arterial dissection in children: clinical and radiographic presentation and outcome. *J Child Neurol* 21:8-16, 2006. <https://doi.org/10.1177/08830738060210010101>
 33. Kim ST, Cloft H, Flemming KD, et al: Increased Prevalence of Cerebrovascular Disease in Hospitalized Patients with Marfan Syndrome. *J Stroke Cerebrovasc Dis* 27:296-300, 2018. <https://doi.org/10.1016/j.jstrokecerebrovasdis.2017.08.036>
 34. North KN, Whiteman DA, Pepin MG, et al: Cerebrovascular complications in Ehlers-Danlos syndrome type IV. *Ann Neurol* 38:960-964, 1995. <https://doi.org/10.1002/ana.410380620>
 35. Chojdak-Lukasiewicz J, Dziadkowiak E, Budrewicz S: Monogenic causes of strokes. *Genes (Basel)* 12:1855, 2021. <https://doi.org/10.3390/genes12121855>. Published 2021 Nov 23
 36. Durette S, Goeggel Simonetti B, Schilling S, et al: Familial occurrence and heritable connective tissue disorders in cervical artery dissection [published correction appears in *Neurology*. 2016 Dec 6;87(23):2500] *Neurology* 83:2023-2031, 2014. <https://doi.org/10.1212/WNL.0000000000001027>
 37. Kim YK, Schulman S: Cervical artery dissection: pathology, epidemiology and management. *Thromb Res* 123:810-821, 2009. <https://doi.org/10.1016/j.thromres.2009.01.013>
 38. Grond-Ginsbach C, Brandt T, Kloss M, et al: Next generation sequencing analysis of patients with familial cervical artery dissection. *Eur Stroke J* 2:137-143, 2017. <https://doi.org/10.1177/2396987317693402>
 39. Kloss M, Grond-Ginsbach C, Ringleb P, et al: Recurrence of cervical artery dissection: An underestimated risk. *Neurology* 90:e1372-e1378, 2018. <https://doi.org/10.1212/WNL.0000000000005324>
 40. Traenka C, Kloss M, Strom T, et al: Rare genetic variants in patients with cervical artery dissection. *Eur Stroke J* 4:355-362, 2019. <https://doi.org/10.1177/2396987319861869>
 41. Wang K, Zhao S, Zhang Q, et al: Whole-exome sequencing reveals known and novel variants in a cohort of intracranial vertebral-basilar artery dissection (IVAD). *J Hum Genet* 63:1119-1128, 2018. <https://doi.org/10.1038/s10038-018-0496-x>
 42. McCrea N, Saunders D, Bagkeris E, et al: Diagnosis of vertebral artery dissection in childhood posterior circulation arterial ischaemic stroke. *Dev Med Child Neurol* 58:63-69, 2016. <https://doi.org/10.1111/dmcn.12945>
 43. Thurman DJ: The epidemiology of traumatic brain injury in children and youths: a review of research since 1990. *J Child Neurol* 31:20-27, 2016. <https://doi.org/10.1177/0883073814544363>
 44. Braga BP, Sillero R, Pereira RM, et al: Dynamic compression in vertebral artery dissection in children: apropos of a new protocol. *Childs Nerv Syst* 37:1285-1293, 2021. <https://doi.org/10.1007/s00381-020-04956-1>
 45. Stence NV, Fenton LZ, Goldenberg NA, et al: Craniocervical arterial dissection in children: diagnosis and treatment. *Curr Treat Options Neurol* 13:636-648, 2011. <https://doi.org/10.1007/s11940-011-0149-2>
 46. Chan CC, Paine M, O'Day J: Carotid dissection: a common cause of Horner's syndrome. *Clin Exp Ophthalmol* 29:411-415, 2001. <https://doi.org/10.1046/j.1442-9071.2001.d01-24.x>
 47. Lum C, Chakraborty S, Schlossmacher M, et al: Vertebral artery dissection with a normal-appearing lumen at multisection CT angiography: the importance of identifying wall hematoma. *AJNR Am J Neuroradiol* 30:787-792, 2009. <https://doi.org/10.3174/ajnr.A1455>
 48. Tan MA, DeVeber G, Kirton A, et al: Low detection rate of craniocervical arterial dissection in children using time-of-flight magnetic resonance angiography: causes and strategies to improve diagnosis. *J Child Neurol* 24:1250-1257, 2009. <https://doi.org/10.1177/0883073809333539>
 49. Swartz RH, Bhuta SS, Farb RI, et al: Intracranial arterial wall imaging using high-resolution 3-tesla contrast-enhanced MRI. *Neurology* 72:627-634, 2009. <https://doi.org/10.1212/01.wnl.0000342470.69739.b3>
 50. Dlamini N, Yau I, Mthusami P, et al: Arterial Wall Imaging in Pediatric Stroke. *Stroke* 49:891-898, 2018. <https://doi.org/10.1161/STROKEAHA.117.019827>
 51. Takekawa H, Suzuki K, Nishihira T, et al: Recurrent juvenile ischemic stroke caused by bow hunter's stroke revealed by carotid duplex ultrasonography. *J Med Ultrason* (2001) 42:437-440, 2015. <https://doi.org/10.1007/s10396-015-0611-y>
 52. Dlamini N, Freeman JL, Mackay MT, et al: Intracranial dissection mimicking transient cerebral arteriopathy in childhood arterial ischemic stroke. *J Child Neurol* 26:1203-1206, 2011. <https://doi.org/10.1177/0883073811408904>
 53. Markus HS, Levi C, King A, et al: Cervical Artery Dissection in Stroke Study (CADISS) investigators. antiplatelet therapy vs anticoagulation therapy in cervical artery dissection: the Cervical Artery Dissection in Stroke Study (CADISS) randomized clinical trial final results. *JAMA Neurol* 76:657-664, 2019. <https://doi.org/10.1001/jamaneurol.2019.0072>
 54. Powers WJ, Rabinstein AA, Ackerson T, et al: Guidelines for the Early Management of Patients With Acute Ischemic Stroke: 2019 Update to the 2018 Guidelines for the Early Management of Acute Ischemic Stroke: A Guideline for Healthcare Professionals From the American Heart Association/American Stroke Association [published correction appears in *Stroke*. 2019 Dec;50(12):e440-e441] *Stroke* 50:e344-e418, 2019. <https://doi.org/10.1161/STR.0000000000000211>
 55. Ahlhelm F, Benz RM, Ulmer S, et al: Endovascular treatment of cervical artery dissection: ten case reports and review of the literature. *Interv Neurol* 1:143-150, 2013. <https://doi.org/10.1159/000351687>
 56. Pinzón M, Lobelo NO, Rodríguez MC, et al: Endovascular management of iatrogenic cervical internal carotid artery pseudoaneurysm in a 9-year-old child: Case report and literature review. *Int J Pediatr Otorhinolaryngol* 95:29-33, 2017. <https://doi.org/10.1016/j.ijporl.2017.01.031>
 57. Fox CK, Fullerton HJ, Hetts SW, et al: Single-center series of boys with recurrent strokes and rotational vertebral arteriopathy. *Neurology* 95:e1830-e1834, 2020. <https://doi.org/10.1212/WNL.0000000000010416>

58. Kleindorfer DO, Towfighi A, Chaturvedi S, et al: 2021 guideline for the prevention of stroke in patients with stroke and transient ischemic attack: a guideline from the American Heart Association/American Stroke Association [published correction appears in *Stroke*. 2021 Jul;52(7):e483-e484] *Stroke* 52:e364-e467, 2021. <https://doi.org/10.1161/STR.0000000000000375>
59. Uohara MY, Beslow LA, Billingham L, et al: Incidence of recurrence in posterior circulation childhood arterial ischemic stroke. *JAMA Neurol* 74:316-323, 2017. <https://doi.org/10.1001/jamaneurol.2016.5166>
60. Nash M, Rafay MF: Craniocervical arterial dissection in children: pathophysiology and management. *Pediatr Neurol* 95:9-18, 2019. <https://doi.org/10.1016/j.pediatrneurol.2019.01.020>
61. Ritchey Z, Bernard TJ, Fenton LZ, et al: Stroke recurrence in children with vertebral artery dissecting aneurysm. *AJNR Am J Neuroradiol* 43:913-918, 2022. <https://doi.org/10.3174/ajnr.A7518>
62. Fukui M: Guidelines for the diagnosis and treatment of spontaneous occlusion of the circle of Willis ('moyamoya' disease). Research Committee on Spontaneous Occlusion of the Circle of Willis (Moyamoya Disease) of the Ministry of Health and Welfare, Japan. *Clin Neurol Neurosurg* 99(Suppl 2):S238-S240, 1997
63. Suzuki J, Takaku A: Cerebrovascular "moyamoya" disease. Disease showing abnormal net-like vessels in base of brain. *Arch Neurol* 20:288-299, 1969. <https://doi.org/10.1001/archneur.1969.00480090076012>
64. Kim JS: Moyamoya disease: epidemiology, clinical features, and diagnosis. *J Stroke* 18:2-11, 2016. <https://doi.org/10.5853/jos.2015.01627>
65. Natori Y, Ikezaki K, Matsushima T, et al: Angiographic moyamoya' its definition, classification, and therapy. *Clin Neurol Neurosurg* 99(Suppl 2):S168-S172, 1997. [https://doi.org/10.1016/s0303-8467\(97\)00052-8](https://doi.org/10.1016/s0303-8467(97)00052-8)
66. Zhao M, Zhang D, Wang S, et al: Transient Ischemic attack in pediatric patients with moyamoya disease: clinical features, natural history, and predictors of stroke. *Pediatr Neurol* 75:48-54, 2017. <https://doi.org/10.1016/j.pediatrneurol.2017.06.020>
67. Research committee on the pathology and treatment of spontaneous occlusion of the circle of willis; health labour sciences research grant for research on measures for intractable diseases. Guidelines for diagnosis and treatment of moyamoya disease (spontaneous occlusion of the circle of Willis). *Neurol Med Chir (Tokyo)* 52:245-266, 2012. <https://doi.org/10.2176/nmc.52.245>
68. Ferriero DM, Fullerton HJ, Bernard TJ, et al: Management of stroke in neonates and children: a scientific statement from the American Heart Association/American stroke association. *Stroke* 50:e51-e96, 2019. <https://doi.org/10.1161/STR.0000000000000183>
69. Scott RM, Smith ER: Moyamoya disease and moyamoya syndrome. *N Engl J Med* 360:1226-1237, 2009. <https://doi.org/10.1056/NEJMra0804622>
70. Choi JC: Cerebral autosomal dominant arteriopathy with subcortical infarcts and leukoencephalopathy: a genetic cause of cerebral small vessel disease. *J Clin Neurol* 6:1-9, 2010. <https://doi.org/10.3988/jcn.2010.6.1.1>
71. Barreto-Duarte B, Andrade-Gomes FH, et al: Association between neurofibromatosis type 1 and cerebrovascular diseases in children: A systematic review. *PLoS One* 16:e0241096. <https://doi.org/10.1371/journal.pone.0241096>, 2021. Published 2021 Jan 4
72. Siegel DH, Tefft KA, Kelly T, et al: Stroke in children with posterior fossa brain malformations, hemangiomas, arterial anomalies, coarctation of the aorta and cardiac defects, and eye abnormalities (PHACE) syndrome: a systematic review of the literature. *Stroke* 43:1672-1674, 2012. <https://doi.org/10.1161/STROKEAHA.112.650952>
73. Mackay MT, Wiznitzer M, Benedict SL, et al: Arterial ischemic stroke risk factors: the International Pediatric Stroke Study. *Ann Neurol* 69:130-140, 2011. <https://doi.org/10.1002/ana.22224>
74. Kim ST, Brinjikji W, Kallmes DF: Prevalence of Intracranial Aneurysms in Patients with Connective Tissue Diseases: A Retrospective Study. *AJNR Am J Neuroradiol* 37:1422-1426, 2016. <https://doi.org/10.3174/ajnr.A4718>
75. Kim ST, Brinjikji W, Lanzino G, et al: Neurovascular manifestations of connective-tissue diseases: A review. *Interv Neuroradiol* 22:624-637, 2016. <https://doi.org/10.1177/1591019916659262>
76. Duat-Rodríguez A, F Carceller Lechón, MÁ López Pino, et al: Neurofibromatosis type 1 associated with moyamoya syndrome in children. *Pediatr Neurol* 50:96-98, 2014. <https://doi.org/10.1016/j.pediatrneurol.2013.04.007>
77. Bekiesińska-Figatowska M, Brągoszewska H, Duczkowski M, et al: Circle of Willis abnormalities in children with neurofibromatosis type 1. *Neurol Neurochir Pol* 48:15-20, 2014. <https://doi.org/10.1016/j.pjnns.2013.05.002>
78. Vargiami E, Sapountzi E, Samakovitis D, et al: Moyamoya syndrome and neurofibromatosis type 1. *Ital J Pediatr* 40:59, 2014. <https://doi.org/10.1186/1824-7288-40-59>. Published 2014 Jun 21
79. Ghosh PS, Rothner AD, Emch TM, et al: Cerebral vasculopathy in children with neurofibromatosis type 1. *J Child Neurol* 28:95-101, 2013. <https://doi.org/10.1177/0883073812441059>
80. Rea D, Brandsema JF, Armstrong D, et al: Cerebral arteriopathy in children with neurofibromatosis type 1. *Pediatrics* 124:e476-e483, 2009. <https://doi.org/10.1542/peds.2009-0152>
81. Cairns AG, North KN: Cerebrovascular dysplasia in neurofibromatosis type 1. *J Neurol Neurosurg Psychiatry* 79:1165-1170, 2008. <https://doi.org/10.1136/jnnp.2007.136457>
82. Rosser TL, Vezina G, Packer RJ: Cerebrovascular abnormalities in a population of children with neurofibromatosis type 1. *Neurology* 64:553-555, 2005. <https://doi.org/10.1212/01.WNL.0000150544.00016.69>
83. Metry DW, Haggstrom AN, Drolet BA, et al: A prospective study of PHACE syndrome in infantile hemangiomas: demographic features, clinical findings, and complications. *Am J Med Genet A* 140:975-986, 2006. <https://doi.org/10.1002/ajmg.a.31189>
84. Hess CP, Fullerton HJ, Metry DW, et al: Cervical and intracranial arterial anomalies in 70 patients with PHACE syndrome. *AJNR Am J Neuroradiol* 31:1980-1986, 2010. <https://doi.org/10.3174/ajnr.A2206>
85. Munot P, Crow YJ, Ganesan V: Paediatric stroke: genetic insights into disease mechanisms and treatment targets. *Lancet Neurol* 10:264-274, 2011. [https://doi.org/10.1016/S1474-4422\(10\)70327-6](https://doi.org/10.1016/S1474-4422(10)70327-6). (91)
86. Finsterer J, Zarrouk-Mahjoub S: Mitochondrial vasculopathy. *World J Cardiol* 8:333-339, 2016. <https://doi.org/10.4330/wjc.v8.i5.333>
87. Tabarki B, Hakami W, Alkhuraish N, et al: Inherited metabolic causes of stroke in children: mechanisms, types, and management. *Front Neurol* 12. <https://doi.org/10.3389/fneur.2021.633119>, 2021. 633119Published 2021 Mar 4
88. Jordan LC, Hillis AE: Hemorrhagic stroke in children. *Pediatr Neurol* 36:73-80, 2007. <https://doi.org/10.1016/j.pediatrneurol.2006.09.017>
89. Terry AR, Jordan JT, Schwamm L, et al: Increased risk of cerebrovascular disease among patients with neurofibromatosis type 1: population-based approach. *Stroke* 47:60-65, 2016. <https://doi.org/10.1161/STROKEAHA.115.011406>
90. Seol HJ, Wang KC, Kim SK, et al: Headache in pediatric moyamoya disease: review of 204 consecutive cases. *J Neurosurg* 103(5 Suppl):439-442, 2005. <https://doi.org/10.3171/ped.2005.103.5.0439>
91. Welby JP, Kim ST, Carr CM, et al: Carotid Artery Tortuosity Is Associated with Connective Tissue Diseases. *AJNR Am J Neuroradiol* 40:1738-1743, 2019 <https://doi.org/10.3174/ajnr.A6218>
92. Morris SA: Arterial tortuosity in genetic arteriopathies. *Curr Opin Cardiol* 30:587-593, 2015. <https://doi.org/10.1097/HCO.0000000000000218>
93. Koss M, Scott RM, Irons MB, et al: Moyamoya syndrome associated with neurofibromatosis Type 1: perioperative and long-term outcome after surgical revascularization. *J Neurosurg Pediatr* 11:417-425, 2013. <https://doi.org/10.3171/2012.12.PEDS12281>

Arterial Ischemic Stroke in Children



Nevena Fileva, MD, PhD^{a,b}, Marta Bertamino, MD, PhD^c, Domenico Tortora, MD, PhD^a, Mariasavina Severino, MD^{a,*}

KEYWORDS

- Arterial ischemic stroke • Children • Neonates • Imaging • Focal cerebral arteriopathy
- Arterial dissection • Congenital heart disease • Moyamoya

KEY POINTS

- Neuroimaging has an important role in the diagnosis, treatment, and follow-up of children with arterial ischemic stroke (AIS).
- The recommended imaging modality is MRI, with a role for rapid MRI protocols in the revascularization time window.
- CT and CT angiography may be used in children with AIS if MRI is not available and in specific clinical scenarios.
- Arteriopathy is the predominant underlying mechanism in pediatric AIS and the greatest predictor of recurrence and poor outcome.
- Newborns have the highest stroke risk ratio, with high lifelong morbidity, accounting for most cases of hemiparetic cerebral palsy.

INTRODUCTION

The incidence of pediatric arterial ischemic stroke (AIS) ranges between 3 and 25 per 100,000 children/year,¹ with a mortality rate of 4% to 20%.² Depending on the patient's age at the initial event, it can be divided into perinatal stroke (between 20 gestational weeks and 1 month of age) and childhood stroke (between the second month of life and 18 years). Differences between the biological sexes and ethnicities are observed, with a higher prevalence among boys and African, Asian, and Hispanic children.¹ The majority of the survivors suffer from life-long disability with motor and cognitive deficits or epilepsy.¹ The unusual nature of pediatric AIS and consequent under-recognition, frequent nonspecific symptoms, and the wide range of differential diagnoses lead to diagnostic delays and misdiagnoses.^{3,4} The median time for diagnostic confirmation ranges from

6 to 22 hours, leading to limited possibility of access to modern treatment options.^{2,4}

Clinical presentation varies according to age, setting (inpatient vs outpatient), and stroke subtype. As for adults, the most common onset symptoms in pediatric stroke include hemiparesis (67%-90%), speech disturbance (20%-50%), vision disturbance (10%-15%), and ataxia (8%-10%).¹ However, children may also present with non-localizing and/or intermittent symptoms, such as headache (20% to 50%), altered mental status (17% to 38%), and seizures (15%-25%).¹ As a consequence, stroke recognition instruments used in the adult population, such as the FAST (Face Arm Speech Test) and ROSIER (Recognition of Stroke in the Emergency Room), have a reduced sensitivity to depict a pediatric AIS and are insufficient to discriminate between stroke and stroke mimics in the pediatric age group.⁵ Therefore, neuroimaging plays a central role in the diagnosis

^a Neuroradiology Unit, IRCCS Istituto Giannina Gaslini, Via Gaslini 5, Genova 16147, Italy; ^b Diagnostic Imaging Department, UMHAT Aleksandrovska, Bul G.Sofiiski 1, Sofia 1431, Bulgaria; ^c Physical Medicine and Rehabilitation Unit, IRCCS Istituto Giannina Gaslini, Via Gaslini 5, Genoa, Italy

* Corresponding author.

E-mail address: mariasavinaseverino@gaslini.org

of this condition in children. Of note, the presence of predisposing conditions, such as sickle cell disease, previous stroke, congenital heart disease, recent trauma, hypercoagulability, history of cerebral radiotherapy, asparaginase therapy, Down syndrome, Moyamoya arteriopathy, and recent infection, should raise the suspicion of stroke even in the absence of focal neurologic symptoms.² Finally, to quantify the stroke severity, a child-specific version of the National Institutes of Health Stroke Score (NIHSS) has been developed, that is, the pedNIHSS, that correlates with the initial infarct volume and functional outcome.^{6,7} Considering the wide range of pediatric AIS etiology, children with this diagnosis usually undergo in-depth cardiac, hematologic, rheumatologic, and genetic investigations.¹

Perinatal stroke is a likely underestimated condition with the reported incidence ranging from 1:1600 to 1:3000 live births.¹ Approximately 80% of perinatal strokes are ischemic *Fetal AIS* (20th gestational week–delivery) may be detected on prenatal imaging or in neuropathologic examination in case of stillbirth. *Neonatal AIS* is diagnosed between birth and 28 days of life, usually as a result of acute encephalopathy and seizures.⁸ *Presumed perinatal ischemic stroke* is diagnosed in older infants presenting with delayed motor milestones, epilepsy, cerebral palsy, or early handedness. In these cases, it is presumed that the ischemic event occurred within the perinatal period, with clinically cryptic presentation and/or without neuroimaging for definite diagnosis.¹ The main risk factors can be divided into maternal (first pregnancy, twins, preeclampsia, maternal smoking, fever), fetal/intrapartum (male sex, congenital heart disease, hypoglycemia, perinatal hypoxia, Apgar <7 on 5th minute, need for resuscitation) and placental (fetal vascular malperfusion, amniotic fluid inflammation, chorionic villitis).⁹ While mortality is low, most neonates with AIS experience persistent neurologic deficits including hemiparesis, and cognitive and speech impairment. The risk of epilepsy is high with rates ranging from 9% to 27.2%.⁸ Notably, the risk for epilepsy and poor outcomes can be predicted on imaging and managed with timely referral to rehabilitation services.

In this article, we discuss the neuroimaging techniques and protocols, describe the main underlying causes, and review the current treatment options for pediatric and perinatal AIS.

IMAGING PROTOCOLS

The imaging aims in pediatric AIS are manifold, including the confirmation of the diagnosis, definition of the type and mechanisms, estimation of

neurologic prognosis, detection of complications, surveillance of arteriopathies, and planning of medical and interventional treatments.^{10,11}

Brain MRI

Brain MRI has the greatest diagnostic sensitivity to AIS in the hyperacute and acute phases (up to 24 hours from the onset).¹² Furthermore, brain MRI facilitates the exclusion of other neurologic conditions with stroke-like presentations, that have a high incidence (20%–50%) in the pediatric population.^{13,14}

Abbreviated MRI protocols (AKA "quick MRI" or "fast MRI") may be useful to avoid late diagnosis and to select candidates for mechanical thrombectomy in the acute phase. These imaging studies usually last from 5 to 10 minutes (**Table 1**).¹⁵ In this phase of patient care, MR Perfusion imaging may be useful to distinguish the stroke core (ie, the irreversibly infarcted tissue) from the penumbra (ie, the critically hypoperfused tissue doomed to infarct if not reperfused). In the absence of pediatric data, the penumbra is currently defined as noninfarcted tissue (without diffusion restriction) which has a Tmax >6s on Dynamic susceptibility contrast-enhanced (DSC) T2* sequences with bolus-tracking, as it is in adults.¹⁶ However, further studies are needed to define the Tmax that best characterizes the penumbra at different ages in the pediatric population. Moreover, evidence is required to validate arterial spin labeling (ASL) MR perfusion, as a noncontrast technique for this specific purpose. More commonly, clinical-DWI mismatch as described by the DAWN trial is used to determine the role of reperfusion therapies, albeit no pediatric thresholds have been established.

When the etiology of LVO is not evident, it is indicated to complete the fast MRI study, possibly in the same session, with other MRI sequences tailored for the situation. These include any or all of a **full protocol brain MRI** study for pediatric AIS is usually used outside the emergency setting (**Table 2**).¹⁷ Regarding vessel wall imaging (VWI), adequate interpretation of the results requires the knowledge of artifacts (such as those related to slow blood flow) and false-positive cases due to dissection, peri-arterial venous plexi (ie, venous plexus of Rektorzik and peri-arterial venous plexus surrounding cervical vertebral artery), anatomic locations of extracranial and intracranial vasa vasorum and recent endovascular procedures.

In **perinatal AIS**, MRI protocols include both anatomic and vascular sequences that can be extended to the neck (**Table 3**). Notably,

Table 1
Recommended Fast MR imaging protocol for pediatric AIS

| Sequence | Plane | Key Role |
|--|-------|---|
| DWI | Axial | Detection of cytotoxic edema with distribution in vascular territories and definition of the stroke core (tissue with ADC values $< 620 \times 10^{-6} \text{ mm}^2/\text{s}$) |
| 2D T2-WI (HASTE/SSh TSE) or 2D/3D FLAIR (>2 y) | Axial | Evaluation of signal abnormalities |
| 2D T2* GE or SWI | Axial | Identification of microhemorrhages within the infarction and of asymmetric prominence of the cortical veins in the penumbra area |
| Intracranial 3D TOF Arterial MRA | Axial | Depiction of large vessel occlusion |
| MR perfusion (DSC T2* or ASL) | Axial | Qualitative and quantitative information on the brain perfusion; definition of the penumbra as the tissue with a $T_{\text{max}} > 6\text{s}$ on DSC T2* |

Abbreviations: ADC, apparent diffusion coefficient; ASL, arterial spin labeling; DSC, dynamic susceptibility contrast; DWI, diffusion-weighted imaging; GE, gradient echo; HASTE, Half-Fourier Acquisition Single-shot TSE; MRA, magnetic resonance angiography; s, seconds; SWI, susceptibility-weighted imaging; T2*, T2 star; TOF, time of flight; TSE, turbo spin echo; WI, weighted imaging.

cervicocerebral arterial injuries due to birth trauma, an important cause of neonatal AIS, may be overlooked if the vascular imaging of the neck is not obtained. Contrast injection is usually not needed.¹⁸

Computed Tomography (CT) Imaging

In the emergency setting, head CT and CT angiography should be performed to evaluate suspected **pediatric AIS** in the case of MR contraindications

Table 2
Recommended full MR imaging protocol for pediatric AIS

| Sequence | Plane | Key Role |
|----------------------------------|-------------------|---|
| DWI | Axial | Detection of cytotoxic edema with distribution in vascular territories |
| 2D T2-WI (TSE) | Axial and coronal | Evaluation of signal abnormalities |
| 2D or 3D FLAIR | Axial or sagittal | Evaluation of signal abnormalities (>2 y) |
| 2D or 3D T1-WI (TFE) | Axial or sagittal | (High-resolution) anatomic information |
| 2D T2* GE or SWI | Axial | Identification of microhemorrhages in the infarct and surrounding brain tissue |
| Intracranial 3D TOF Arterial MRA | Axial | Depiction of intracranial large vessel occlusion, stenosis, aneurysm, leptomeningeal collaterals |
| Cervical CE MRA (3D spoiled GE) | Coronal | Detection of aortic arch and/or cervical artery anomalies (occlusion, stenosis, pseudoaneurysm, relevant variant) |
| Pre- and post-contrast BBVWI | Sagittal | Identification of intramural hematomas (dissection) and pattern of vessel wall contrast enhancement |
| MR perfusion (DSC T2* or ASL) | Axial | Qualitative and quantitative information on brain perfusion in the case of cerebral arteriopathies |

Abbreviations: ADC, apparent diffusion coefficient; ASL, arterial spin labeling; BBVWI, black-blood vessel wall imaging; CE, contrast-enhanced; DSC, dynamic susceptibility contrast; DWI, diffusion-weighted imaging; GE, gradient echo; HASTE, Half-Fourier Acquisition Single-shot TSE; MRA: magnetic resonance angiography; s, seconds; SWI, susceptibility-weighted imaging; TFE, turbo field echo; TOF, time of flight; TSE, turbo spin echo; WI, weighted imaging.

Table 3
Recommended Full MR imaging protocol for neonatal AIS

| Sequence | Plane | Key Role |
|---|-----------------------|--|
| DWI | Axial | Detection of cytotoxic edema with distribution in vascular territories |
| 2D T2-WI (TSE) ^a | Axial and coronal | Evaluation of signal abnormalities |
| 2D or 3D T1-WI (TSE or TFE) ^a | Axial and/or sagittal | (High-resolution) anatomic information |
| 2D T2 ^a GE or SWI | Axial | Identification of microhemorrhages within the infarction and of asymmetric prominence of the cortical veins in the penumbra area |
| Intracranial and cervical 3D TOF Arterial MRA | Axial | Depiction of large vessel occlusion, stenosis or irregularities both at the intracranial and cervical level |
| MR perfusion (ASL) ^b | Axial | Qualitative and quantitative information on the brain perfusion |

Abbreviations: ADC, apparent diffusion coefficient; ASL, arterial spin labeling; DWI, diffusion-weighted imaging, GE, gradient echo; MRA, magnetic resonance angiography; s, seconds; SWI, susceptibility-weighted imaging, TOF, time of flight; TSE, turbo spin echo; WI, weighted imaging.

^a Adjust the sequence parameters for unmyelinated brain.

^b Optional sequence.

(eg, noncompatible medical devices or dental braces degrading the image quality), organizational delay, lack of MRI access, clinical instability, trauma, or high-risk populations in whom the pre-test probability of AIS with intracranial large vessel occlusion (LVO) is high.^{18,19} Noncontrast head CT has high sensitivity in detecting hemorrhagic stroke but fails to detect AIS in 34% to 40% of cases, especially in the hyperacute phase and with reduced radiation dose CT protocols that are used in small children.

In children, exposure to the radiation and administration of iodinated contrast via mechanical injectors are considered disadvantages. While in adults with suspect AIS CT angiography is strongly indicated after a negative brain CT, in the pediatric setting the diagnostic approach is more complex. Indeed, neurologic conditions with a possible stroke-like presentation and negative CT examination are highly frequent, especially in early childhood. Therefore, CT angiography of the head and neck after a negative noncontrast head CT may be of low yield and thus obtained more selectively. In most such instances, brain MRI is the next step in diagnostic evaluation. CT angiography of the head and neck should be obtained if time-sensitive revascularization therapies are potentially indicated, particularly in high-risk populations, such as children with cardiac disease or children with prothrombotic conditions.^{20–22} CT perfusion is rarely useful in children because of the requisite radiation exposure and lack of meaningful data from pediatric penumbral imaging studies to guide clinical decision-making.²³

In the case of **perinatal AIS**, nonenhanced head CT should be performed only if MRI is not available or in the presence of non-MRI-compatible medical devices.²⁴

Catheter-Directed Digital Subtraction Angiography

Despite being an invasive procedure with ionizing radiation exposure, catheter-directed DSA is still considered a gold standard in the diagnosis of many cerebrovascular pathologies due to higher spatial resolution compared with CTA and MRA, and unparalleled temporal resolution which facilitates the detailed characterization of discrete arterial, capillary and venous circulatory phases/compartments.^{25,26} Catheter-directed DSA may be indicated when clinical-laboratory (echocardiography), CT, and/or MRI examinations have not adequately delineated the underlying cause of AIS in a child. Moreover, catheter-directed DSA is useful in cases of posterior circulation stroke, particularly if they are recurrent, since it may reveal subtle dissections of the atlanto-axial (AA) or atlanto-occipital (AO) vertebral artery that are occult on CTA and MRI/MRA. In children with non-traumatic AA or AO vertebral artery dissections, catheter-directed DSA with rotational head maneuvers has an important role in the diagnosis of bow-hunter syndrome.^{26,27} Catheter-directed DSA also has a central role in the diagnosis of primary nervous system (CNS) angiitis because of the better delineation of stenotic and ectatic changes in the cortical branch arteries of the brain.²⁸ Finally,

in moyamoya arteriopathy, catheter-directed DSA is indicated for definitive diagnosis, staging, and surgical treatment planning.²⁹ Catheter-directed DSA is usually not indicated for the diagnosis or management of perinatal AIS.

IMAGING FINDINGS

Perinatal Arterial Ischemic Stroke

Neuroimaging in perinatal AIS has similar aims as in the pediatric age group, confirming the diagnosis, identifying a potential etiology, suggesting the timing of insult, excluding stroke mimics, assisting in treatment decisions, and providing prognostic information. In particular, early diffusion findings correlate with clinical outcomes, especially cerebral palsy.^{30,31} The majority of perinatal AIS affects the MCA territory, more often on the left side due to preferential flow direction in fetal and neonatal circulation.²⁴ Placental thrombi embolizing in the fetal circulation is considered the most probable etiology. Multiple arterial territories may be involved in neonates with meningitis, thrombophilia, and fetal vascular malperfusion.^{32,33} Perforator strokes in lenticulostriate and posterior circulation territories are more frequent in preterm neonates.³⁴

In the neonatal period, intracranial MRA is positive in 22% to 62% of cases.³⁵ MRA of the neck vessels may be useful to detect cervical vessel dissection resulting from birth trauma.³⁶ In newborn infants who undergo acute brain MRI because of clinically suspected AIS (seizures, apnea, or encephalopathy), geographic areas of restricted diffusion correspond to core infarction, and surrounding penumbral regions often fail to show signal hypointensity on ASL sequences. Paradoxically, ASL signal within the core infarction is increased, in such cases. While these changes may be related to tissue reperfusion and/or changes in cerebral blood flow linked to seizure activity, stasis within parenchymal vessels cannot be excluded as the cause.³⁷

Congenital heart disease or twin-twin transfusion syndrome may manifest in utero with acute fetal AIS (**Fig. 1**) or in the chronic phase as porencephaly, cerebral volume loss, and malformations of cortical development.³⁸

In contradistinction to the broader pediatric population, the risk of recurrence in perinatal AIS is low (around 1%).³⁹ Long-term MRI follow-up is thus not needed in the absence of specific risk factors and/or extremely rare congenital arteriopathies.⁴⁰

Pediatric Arterial Ischemic Stroke

International Pediatric Stroke Study Investigators (IPSS) developed The Childhood Arterial Ischemic

Stroke Standardized Classification and Diagnostic Evaluation (CASCADE) system to categorize childhood strokes according to the underlying cause. It divides AIS into seven subtypes: (1) small vessel arteriopathy, (2) unilateral focal cerebral arteriopathy (FCA), (3) bilateral cerebral arteriopathy, (4) aortic/cervical arteriopathy, (5) cardioembolic, (6) other, and (7) multifactorial.⁴¹ The CASCADE classification at stroke onset may help in predicting the risk of recurrent stroke, progression of arteriopathy, and treatment selection.⁴² Stroke recurrence is higher in children with arteriopathies⁴³ and in the presence of predisposing conditions such as cardiac anomalies, thrombophilia, and sickle cell disease.

Arterial dissection

Intra- and extracranial arterial dissections are among the most common arteriopathies causing AIS in childhood. Children account for 55% to 75% of all intra- and extracranial arterial dissections²⁶ (**Fig. 2**). Such dissections are often secondary manifestations of an underlying arteriopathy that alters the structural integrity of the arterial wall. In some cases, the underlying arteriopathy is a recognizable multisystem disorder with a verifiable genetic basis as in Marfan's disease and Osteogenesis imperfecta, but in other cases, the underlying arteriopathy may be uncharacterized with arterial tortuosity being the only clue to its presence.⁴⁴ In other cases, arterial dissections are complications of musculoskeletal anomalies that exert aberrant dynamic forces on the vertebral artery.⁴⁵

Frequent locations for arterial dissections in children are the atlanto-axial and atlanto-occipital segments of the vertebral artery and the cervical internal carotid artery (ICA). Brain MRI with fat-saturated T1-weighted sequences may depict intramural hematoma. Vascular imaging (CTA, MRA, or catheter-directed DSA) may reveal a double lumen, intimal flap, pseudoaneurysm, and segmental arterial stenosis or occlusion.²⁰ Catheter-directed DSA is still considered a gold standard in the diagnosis of arterial dissection due to its exquisite sensitivity to subtle luminal distortions. Nevertheless, especially in the pediatric population, brain MRI with cranio-cervical MRA is the preferred modality due to the non-invasiveness and ability to image both the affected vessels and brain parenchyma in one study.⁴⁶ In children, particularly males, presenting with posterior circulation AIS, an atlanto-axial (Power's V2) or atlanto-occipital (Power's V3) segment vertebral artery dissection should be further investigated by catheter-directed DSA with provocative head maneuvers once the arterial dissection has healed.

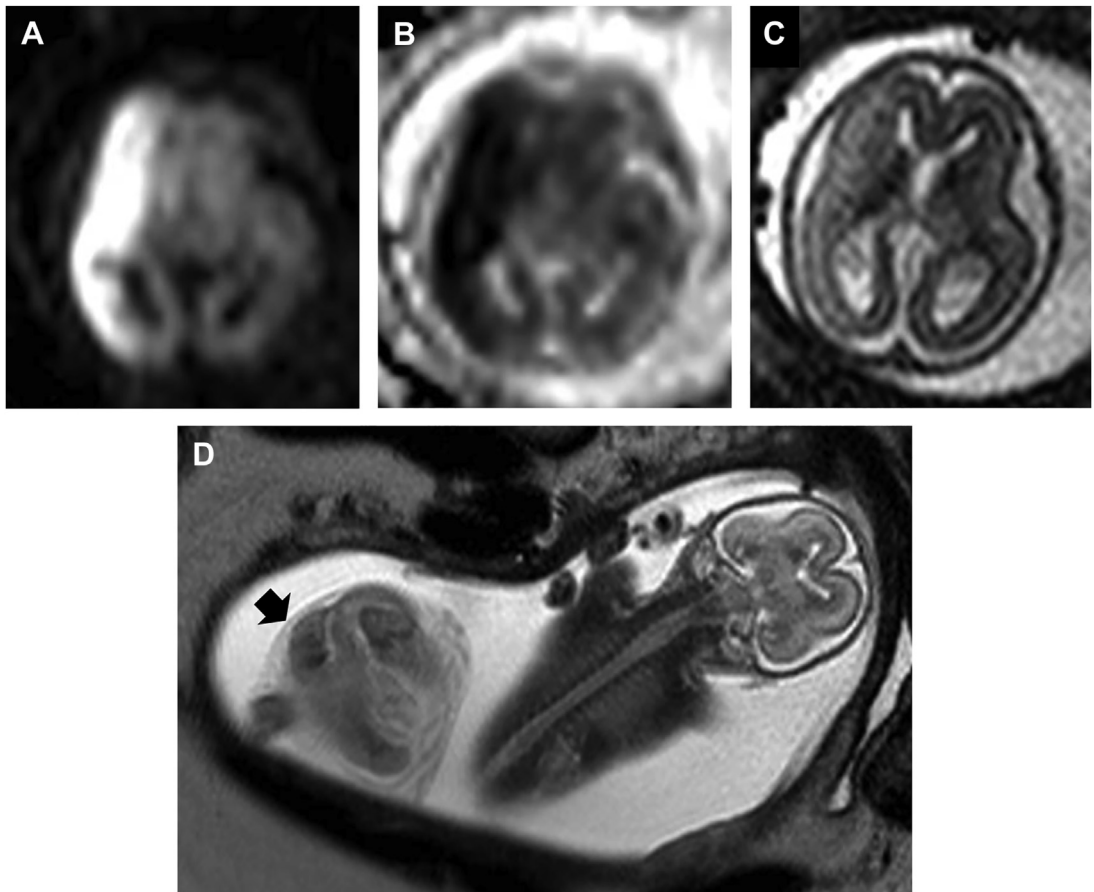


Fig. 1. Twin-to-twin transfusion syndrome complicated by fetal AIS. Fetal MRI at 20 gestational weeks with axial DWI (A), corresponding ADC map (B), and axial (C) and coronal (D) T2-weighted image reveals an AIS in the left MCA territory. Note the deceased twin fetus (thick arrow).

Dynamic and reversible vertebral artery occlusion, that colocalizes to the site of vertebral artery dissection, upon contralateral head rotation, confirms the diagnosis of bow-hunter syndrome.^{20,27}

Cardiac disorders

This group includes embolic AIS caused by congenital heart disease, procedure-related events (extracorporeal membrane oxygenation, catheterization, or surgery), or acquired heart disease.⁴⁷ According to the IPSS study, 30% of pediatric strokes can be related to cardiac disorders, with half of cases due to congenital heart disease. Patients tend to have higher mortality, poorer prognosis, and higher recurrence rate compared with other etiologies.^{47,48}

Persistent foramen ovale is the most common congenital right-to-left shunt anomaly that may lead to paradoxical embolism. The stroke risk increases corresponding to the size of the communication between the ventricles or in combination with genetic or acquired prothrombotic

abnormality. In selected cases, closure procedures and preventive therapy have proven to decrease the AIS recurrence rates.^{48,49}

A cardioembolic source should be suspected when there are signs of asynchronous AIS or multiple vascular territories are affected (particularly bilateral ICA territories or combined involvement of vertebrobasilar and ICA territories) (Fig. 3). On vascular imaging, abrupt arterial occlusion without surrounding vessel changes or stenosis is highly suspicious. A meniscus sign, in which contrast media or flow-related signal marginates the convex border of the luminal filling defect, strongly favors embolic vascular occlusion. Simultaneous cortico-subcortical and basal ganglia infarction is a worse prognostic sign. Children with AIS typically undergo cardiac evaluation via transthoracic echocardiography with intravenous with bubble contrast, as well as electrocardiographic monitoring to assess for an arrhythmia.¹ Where acute cardiac assessment is not available, transcranial Doppler can provide a first clue to the existence

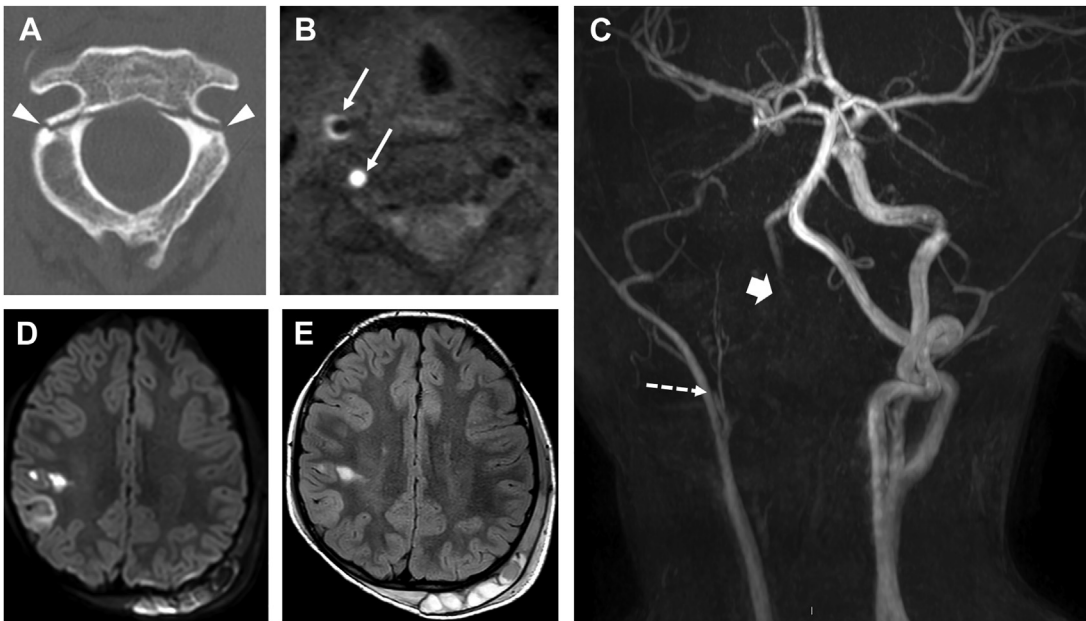


Fig. 2. Post-traumatic arterial dissections in a 7-year-old boy. (A) Axial CT scan reveals bilateral hangman fractures of C2 (*arrowheads*). (B) Axial fat-suppressed T1-weighted image of the cervical region demonstrates the hematomas in the right ICA and vertebral artery walls (*thin arrows*). (C) 3D-TOF MRA shows ICA (*dashed arrow*) and vertebral artery (*thick arrow*) occlusion. (D) Axial DWI and (E) FLAIR images depict small cortical-subcortical AIS in the right posterior frontal and parietal lobes. Note a subcutaneous hematoma in the left parietooccipital region.

of a right-to-left shunt by detecting microbubbles in the middle cerebral artery (MCA) after intravenous agitated saline injection.¹¹

Focal cerebral arteriopathy

The updated definition of focal cerebral arteriopathy (FCA) includes unifocal and unilateral stenosis/irregularity of the intradural ICA, proximal MCA, and/or proximal anterior cerebral artery.⁵⁰ It can be divided into 2 main groups: (1) inflammatory subtype (FCA-i) that can occur in cases of active and postinfectious disorders, including postvaricella cerebral arteriopathy; and (2) dissection subtype (FCA-d) affecting the intracerebral vessels.

FCA-i should be suspected in cases of subcortical lateral lenticulostriate territory infarction and/or irregular stenosis involving the intradural ICA and/or its first-order branches. The characteristic stenosis demonstrates luminal beading on vascular imaging studies and vessel wall thickening with concentric mural contrast enhancement on black blood MR vessel wall imaging (**Fig. 4**). In many affected patients, there is a clinical history of previous or ongoing infection with a range of agents that include varicella-zoster virus and SARS-CoV-19.^{48,51,52} FCA is covered in more detail in the article on arteriopathies in this book.

The 1-year stroke recurrence rate after FCA reportedly ranges from 19% to 25% and regular follow-up is recommended.⁵³ Brain MRI with MRA studies at 1.5 to 3, 6, and 12 months are fundamental to distinguish transient from persistent or progressive FCA and to exclude evolution into a moyamoya arteriopathy.⁵⁴

Although FCA-d is often associated with minor trauma, a history of trauma is absent in several cases. Since the intradural ICA and its first-order branches are characteristically involved, there is a mixed subcortical/cortical cerebral infarction. In contrast to the relatively regular beaded stenosis of FCA-i, the vascular lesion of FCA-d is much more irregular, and complete occlusions are common. Other features of dissection may also be apparent such as intimal flap, aneurysmal dilatation, pseudoaneurysm, segmental ectasia, corkscrew tortuosity, and double lumen sign or false lumen. Black blood VWI may demonstrate intramural hematoma, with or without eccentric mural contrast enhancement. Vascular imaging follow-up is required to exclude complications such as pseudoaneurysms.⁵⁴

Cerebral vasculitis

Cerebral vasculitis is classified as (i) primary CNS vasculitis, (ii) idiopathic with isolated CNS

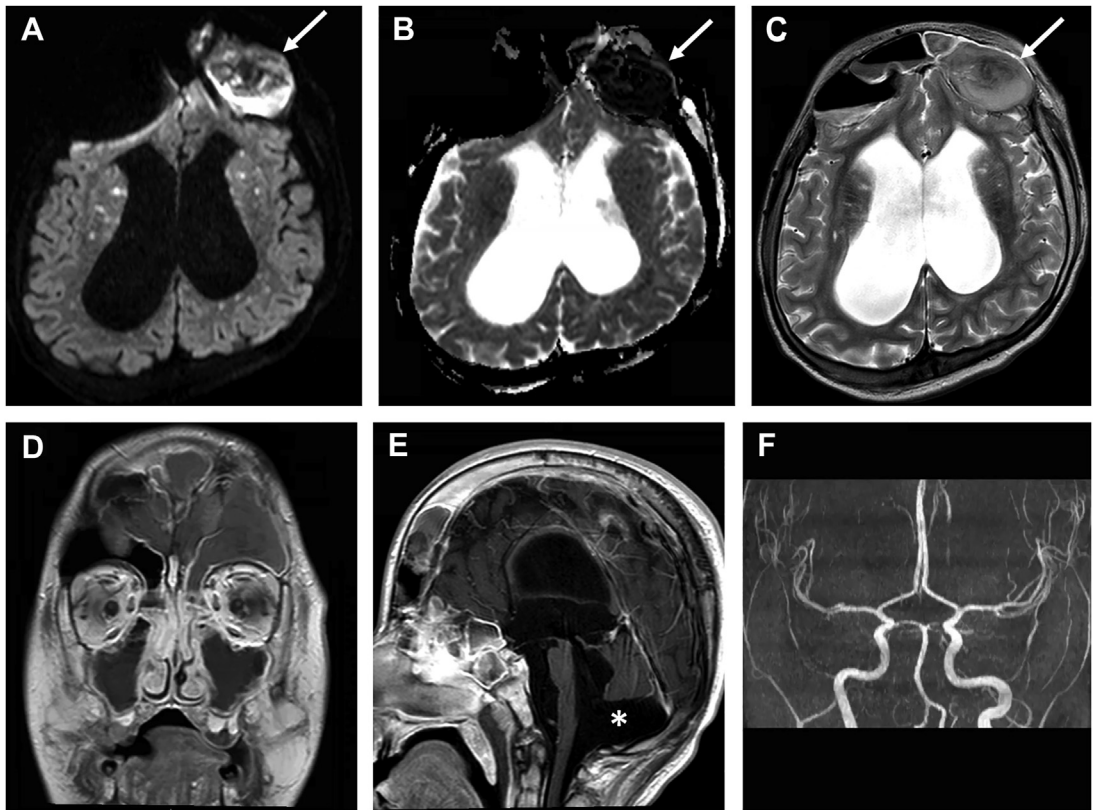


Fig. 3. Embolic AIS in a 13-year-old boy with endocarditis and acute purulent sinusitis. (A) Axial DWI with corresponding ADC maps (B) and T2-weighted images (C) show multiple bilateral small AIS in the basal ganglia and cerebral white matter. Note the mucosal thickening and fluid accumulation in the frontal sinuses with markedly reduced diffusion (thin arrows) in keeping with a purulent content. Coronal (D) and sagittal (E) postcontrast T1-weighted images reveal inflammatory mucosal enhancement in the paranasal sinuses. There is also a persistent Blake pouch cyst (asterisk) causing tetra-ventricular hydrocephalus. (F) 3D TOF MRA shows normal intracranial vessels.

involvement, and (iii) secondary CNS vasculitis in the context of systemic diseases due to rheumatological, infective, drug or treatment-related causes (Fig. 5).

Childhood primary angiitis of the central nervous system (cPACNS) is an extremely rare condition with an estimated incidence of around 2.4 cases/1000000/y⁵⁵ Two broad subtypes are recognized: (1) angiitis involving large- and medium-sized vessels (angiography-positive cPACNS) and (2) angiitis involving small vessels (angiography-negative cPACNS). CSF inflammatory biomarkers are more frequently found in secondary CNS vasculitis and angiography-negative cPACNS.⁵⁵

Brain MRI may show multiple/bilateral cerebral infarcts, cerebral microhemorrhages, and rarely subarachnoid hemorrhage, variably associated with leptomeningeal and/or parenchymal contrast enhancement. Multifocal intracranial arterial narrowing and/or irregular beading of both large and medium-sized blood vessels may be detected on

MR angiography.²⁸ MRI black blood VWI with contrast may depict arterial wall thickening and mural enhancement (see Fig. 5). Catheter-directed DSA may reveal multifocal segmental narrowing and/or irregular beading involving both medium-sized blood vessels. A negative DSA does not exclude a cPACNS and a neurosurgical biopsy might be needed.⁵⁶

Moyamoya arteriopathy

Moyamoya arteriopathy is a chronic, progressive, noninflammatory intracranial arteriopathy characterized by progressive steno-occlusive disease affecting the internal carotid termination and its branches, along with specific patterns of compensatory arterial collateral formation.^{41,57} Moyamoya arteriopathy is bilateral in the vast majority of cases, though unilateral disease has been reported. Signature collateral patterns include moyamoya collaterals (hypertrophic lateral lenticulostriates vascularizing striatocapsular structures),

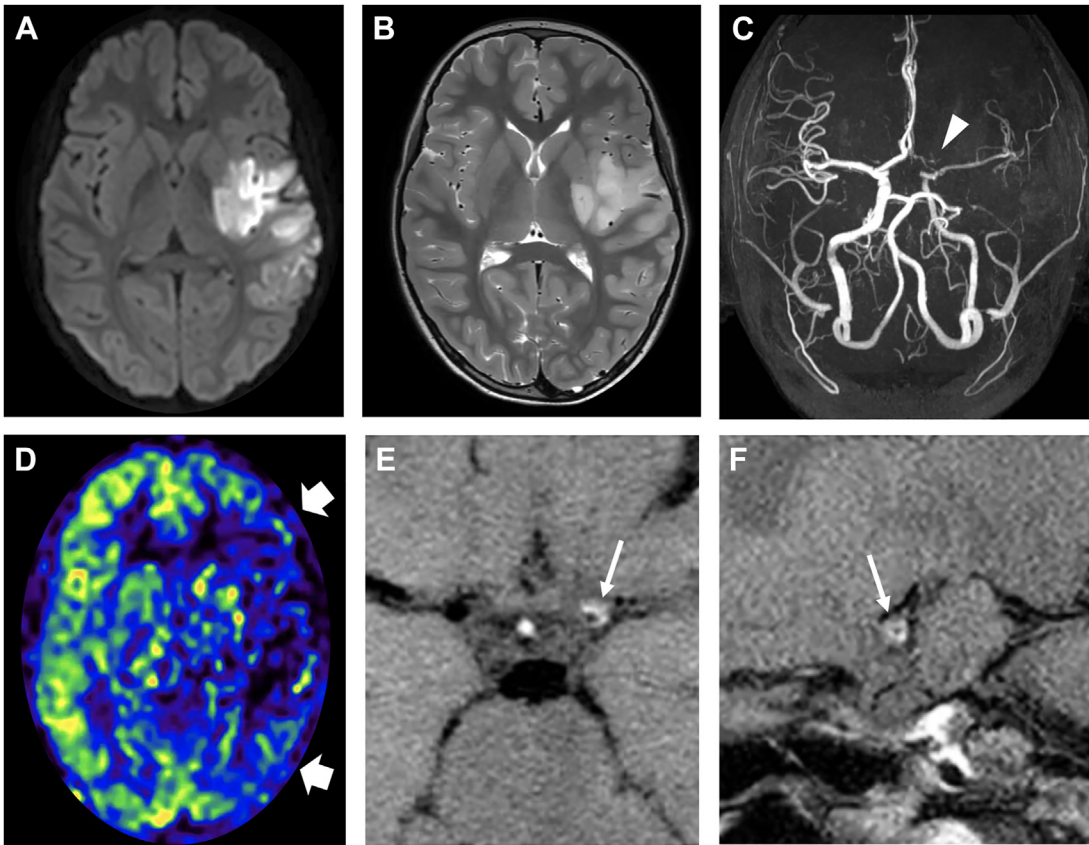


Fig. 4. Inflammatory FCA in a 12-year-old girl. Axial DWI (A) and T2-weighted (B) images demonstrate an AIS in the left fronto-insulo-temporal and nucleo-capsular region. (C) 3D-TOF MRA reveals a focal stenosis involving the left supraclinoid ICA, M1, and A1 segments (*arrowhead*) with the reduced flow in the MCA distal branches. (D) ASL flow-sensitive sequences reveal decreased blood flow in the MCA territory (*thick arrows*). (E, F) Axial and sagittal VWI demonstrates focal concentric contrast enhancement in the left ICA and M1 vessel wall (*thin arrows*).

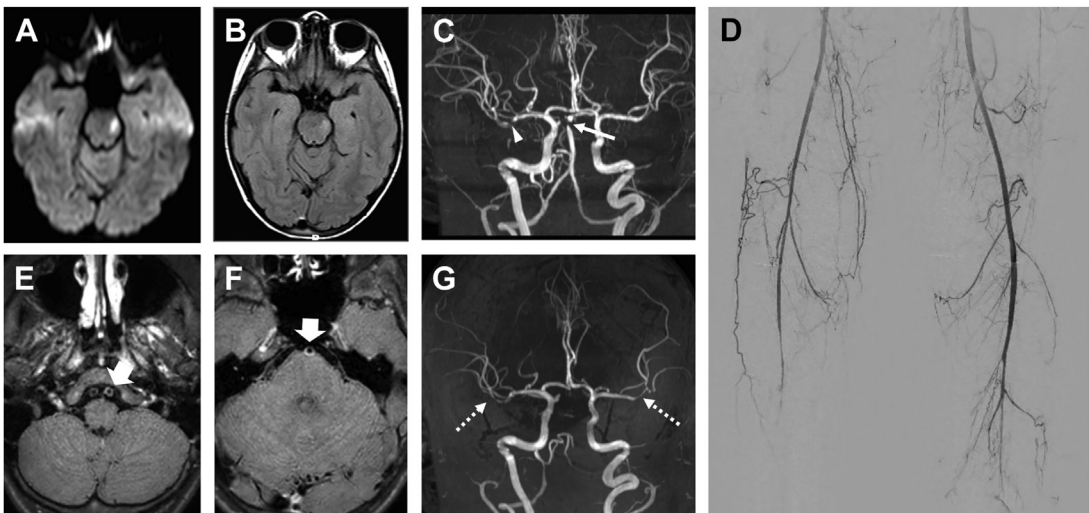


Fig. 5. Systemic autoimmune inflammatory vasculitis with CNS involvement in a 10.5-year-old girl. (A) Axial DWI and (B) FLAIR images show a left mesencephalic AIS. (C) 3D-TOF MRA demonstrates focal stenosis of the basilar artery (*thin arrow*) and right M2 segment (*arrowhead*). (D) Catheter-directed DSA reveals lower extremity vasculitis, more severe on the right side. (E, F) Black-blood vessel wall imaging reveals basilar and vertebral artery wall thickening with associated concentric mural enhancement (*thick arrows*). (G) Follow-up 3D-TOF MRA after 10 years shows the progression of the intracranial stenoses, including at the MCA level (*dashed arrows*).

leptomeningeal collaterals, transdural collaterals, and choroidal collaterals.

Moyamoya causes 6% to 10% of all childhood strokes and TIA in children.¹ This condition is described in further detail in the article on childhood arteriopathies. The natural history includes the occurrence of transient ischemic attacks, ischemic infarcts, or intracerebral hemorrhage. Since medical treatment is not effective in preventing clinical events, patients with advanced cerebral hemodynamic failure and/or neurologic symptoms benefit from surgical revascularization.⁵⁸ On imaging, as intracranial ICA stenoses become increasingly worse, there is a progressive increase in hypertrophic lateral lenticulostriate collaterals (Suzuki stages 1 through 3) followed by exhaustion (Suzuki stages 4 through 6). These collaterals have a “puff of smoke” appearance on vascular imaging (“Moyamoya” in Japanese) (Fig. 6). Brain MR perfusion studies with DSC T2* or ASL techniques are useful to depict regions of decreased cerebral perfusion. In combination with acetazolamide injection or induced hypercarbia, these studies can be used to quantify the cerebrovascular reserve and to reveal postrevascularization perfusion improvements.^{59–61}

Sickle cell disease

Sickle cell disease is the most common hemoglobinopathy worldwide. It is associated with chronic anemia and vasculopathy with multisystem involvement. The drivers of endothelial injury and dysfunction causing the arteriopathy of sickle cell disease include rheometric shear stress secondary to the sickling of erythrocytes, hypertension, hyperdynamic circulatory changes, and vascular inflammation fueled by hemolysis and iron overload. The main patterns of cerebral arteriopathy in sickle cell disease are progressive large artery intracranial occlusive disease and progressive small vessel cerebral arteriopathy which typically manifests “silent” subcortical cerebral infarctions with cognitive impairment.^{51,62} Progressive large artery intracranial occlusive disease demonstrates anatomic heterogeneity and may involve any segment of the anterior circulation or posterior circulation. A moyamoya arteriopathy pattern is not infrequent. Progressive large artery intracranial occlusive disease may present with geographic territorial infarctions or less commonly watershed zone infarctions. In contrast, small vessel arteriopathy manifests with subcortical and periventricular white matter infarctions.⁶³ This risk of stroke in the setting of progressive large artery intracranial occlusive disease drastically changed after the introduction of preventive chronic blood transfusions.⁶⁴ Stem cell transplantation and gene

therapy promise to further reduce cerebrovascular morbidity in individuals affected with sickle cell disease.⁶⁵

Infection

Systemic or cerebral infection can be associated with AIS through a variety of mechanisms with patterns that are distinct from those seen in FCA-i. According to the IPSS study, 24% of children presenting with AIS were found to have an active infection at the time of their stroke, most commonly bacterial meningitis (including tuberculous) or viral encephalitis caused by varicella, HIV, Zika, Dengue, herpes, Epstein Barr Virus, CMV, or COVID-19. The stroke mechanisms include the activation of the coagulation cascade and septic emboli.⁴⁸ Common neuroradiological findings are multifocal asynchronous AIS, striatocapsular infarction, leptomeningeal contrast enhancement, and stenoses of large and medium-sized intracranial arteries.⁴⁷

Genetic

Pediatric and perinatal stroke can be the manifestation of a genetic condition with simple Mendelian inheritance (Table 4, Fig. 7A–D).⁶⁶ In the last decade, next-generation sequencing techniques have revolutionized the diagnostic approach to monogenic stroke, improving overall patient management.⁶⁷ Specific clinical-neuroradiological phenotypes have been described that may raise the suspicion of genetic variants in genes associated with hereditary monogenic AIS forms such as CADASIL and COL4A1 mutation, even in the absence of a positive family history.^{68,69} Additionally, there are other non-hereditary syndromes associated with congenital arteriopathies and/or AIS, such as the PHACES syndrome (see Fig. 7E–H).⁷⁰

Mineralizing angiopathy

Isolated striatocapsular infarctions in infants and toddlers, without evidence of medium or large vessel abnormalities on vascular imaging should raise suspicion of mineralizing angiopathy.⁷¹ Although initially believed to be a cause of nonperinatal AIS in children less than 18 months of age, mineralizing angiopathy has now been reported as a cause of AIS in children as old as 6 years of age. If pathognomonic findings of multifocal, bilateral basal ganglia calcifications are not revealed by T1-weighted or susceptibility-weighted MRI sequences, noncontrast CT should be obtained for further evaluation. Frontal and parietal lobar calcifications in the corticomedullary junction regions, thalamic calcifications, and calcifications of the dentate nuclei may also be present though these may not be conspicuous on MRI. The

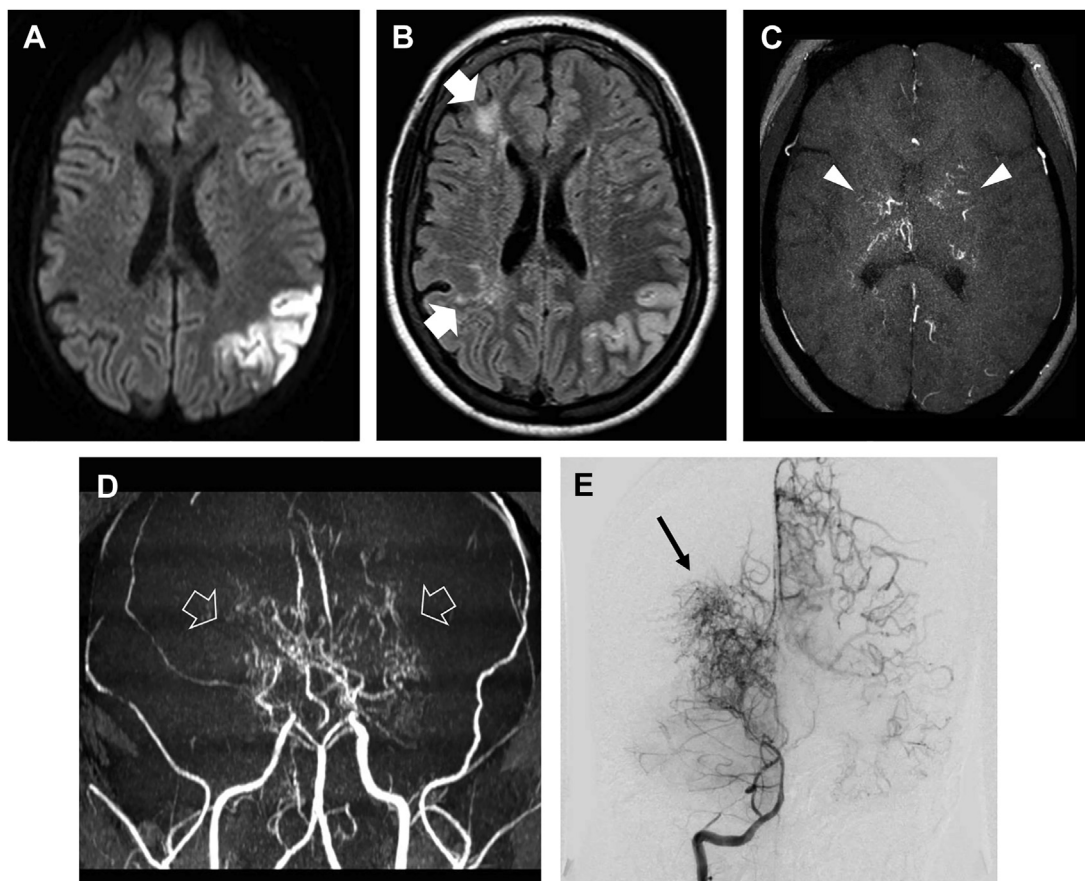


Fig. 6. Moyamoya arteriopathy in a 14-year-old girl. (A-C) Brain MRI and MRA at clinical onset. Axial DWI (A) and FLAIR (B) images show an acute cortical AIS in the left parietal MCA-PCA posterior watershed region. White matter signal changes are noted in the right fronto-parietal MCA-ACA and MCA-PCA watershed regions associated with cortical atrophy (thick arrows). (C, D) 3D-TOF MRA demonstrates moyamoya collaterals in the basal ganglia (arrowheads) and markedly reduced blood flow in bilateral MCAs, ACAs, and PCAs (empty arrows). (E) Catheter-directed DSA, right vertebral artery injection in the capillary phase, shows delayed retrograde angiographic filling of left MCA cortical branches through leptomeningeal anastomoses supplied by the left PCA, and delayed angiographic filling of moyamoya collateral networks (“puff of smoke”) in the right cerebral hemisphere by the stenotic/occluded right PCA (thin arrow).

pathophysiology of this entity is poorly understood. In the majority of cases, AIS is associated with minor head trauma (ie, fall from bed) and isolated cases have been associated with thrombophilia. Large case series indicate that minor trauma precedes the onset of stroke symptoms by an average of 60 minutes, suggesting that the trauma precipitates a cascade of events within previously diseased, calcified lenticulostriate arteries which culminates in symptomatic AIS.⁷² The literature suggests a favorable neurologic prognosis with adequate rehabilitation. Although recurrent strokes have been reported, sometimes after a period of several years, stroke recurrence is not typical.

Complications of arterial ischemic stroke in children

Regular imaging follow-up is recommended in AIS, especially in the early phases. This is useful

to evaluate therapy response and to exclude recurrent subclinical events or complications. In cases of large MCA or cerebellar infarction, secondary malignant edema may occur, and decompressive craniectomy may be indicated. Hemorrhagic transformation is another event that can lead to a change in the therapeutic strategy.¹¹

DIFFERENTIAL DIAGNOSIS/STROKE MIMICS IN CHILDREN

Migraine is the most common stroke mimic in children,⁷³ with an overall prevalence of 10.6%. Migraine headaches may be associated with vomiting and/or auras including visual or sensory disturbances.¹³ MRI findings range from normal to multiple focal white matter signal changes or cortical swelling with venous dilatation and gyriform

Table 4
Monogenic conditions associated with stroke and arteriopathies

| Disease Name | Gene Symbol | Protein name and Function | Neuroimaging Features |
|--|--------------------|---|---|
| Autosomal Dominant | | | |
| ACTA2-related vasculopathy | ACTA2 ^a | Actin Alpha 2: contractile protein of the vascular smooth muscle cells | Ischemic AIS, fusiform dilatation of ICA cavernous/clinoid segments, stenosis of terminal ICA segment, initial M1 and A1 segments, absence of "moyamoya" basal collaterals, periventricular WM signal changes, dysgyria |
| Marfan syndrome | FBN1 | Fibrillin 1: structural role for tissue integrity and regulator of cellular signaling events | Ischemic and/or hemorrhagic stroke; dissecting aortic aneurysm; neck vessel dissections; intracranial aneurysms; dural ectasias; kyphoscoliosis |
| Ehlers-Danlos Syndrome type IV (EDS-IV) | COL3A1 | Collagen type III: a major structural component of the vessel wall | Ischemic and/or hemorrhagic stroke; aneurysms and vascular ectasias; dissections |
| Cerebral autosomal dominant arteriopathy with subcortical infarcts and leukoencephalopathy (CADASIL) | NOTCH3 | NOTCH3 (Neurogenic locus notch homolog protein 3): transmembrane receptor protein, role in the survival of vascular smooth muscle cells | Confluent WM signal alterations with early anterior temporal lobe and external capsule involvement and sparing of occipital regions; focal lesions in the BG, thalamus, and pons; frequent cerebral microhemorrhages; late cerebral atrophy |
| Cathepsin A-related arteriopathy with strokes and leukoencephalopathy (CARASAL) | CTSA ^b | Cathepsin A: stabilizes the protein complex formed by β -galactosidase and neuromidase-1 thus protecting from lysosomal degradation | Confluent WM signal alterations; focal lesions in the BG and thalamus; high T2 signal connecting the middle cerebellar peduncles across the pons (arc sign); rare cerebral microhemorrhages |
| Autosomal dominant familial porencephaly | COL4A1 COL4A2 | Collagen type IV: main component of the basement membranes | Antenatal/perinatal hemorrhagic stroke; microhemorrhages; WM signal alterations; periventricular leukomalacia-like pattern; porencephaly; brain calcifications; schizencephaly; focal cortical dysplasia |

(continued on next page)

Table 4
(continued)

| Disease Name | Gene Symbol | Protein name and Function | Neuroimaging Features |
|---|---------------------------|--|--|
| Pontine autosomal dominant microangiopathy and leukoencephalopathy (PADMAL) | <i>COL4A1^c</i> | Collagen type IV: main component of the basement membranes | lacunar infarcts predominantly affecting the pons; subcortical and periventricular WM lesions; rare spinal cord involvement; uncommon micro- and macro-hemorrhages; late brainstem atrophy |
| Neurofibromatosis Type 1 (NF-1) | <i>NF1</i> | Neurofibromin 1: protein regulating Ras signaling pathway, tumor-suppressing function | Ischemic stroke, moyamoya vasculopathy, distal arterial stenoses, aneurysms, focal areas of signal intensity (FASI) typically in the cerebellar WM, brainstem, and BG; optic end extra-optic pathway gliomas, sphenoid wing dysplasia; dural calcifications; scoliosis; neurofibromas; dural ectasia; kyphoscoliosis |
| Neurofibromatosis type 2 (NF-2) | <i>NF2</i> | Neurofibromin 2: tumor suppressor gene | Ischemic stroke, cerebral arteriopathy, meningiomas, schwannomas (usually from the inferior vestibular division of the vestibulocochlear nerve); spinal ependymoma |
| Acardi-Goutieres Syndrome 1, dominant (AGS) | <i>TREX1</i> | TREX1 (Three Prime Repair Exonuclease 1): DNA-degrading enzyme | Ischemic stroke; aneurysms; WM signal alterations with frontotemporal predominance or diffuse involvement; deep WM cysts in frontal and temporal regions; cerebral calcifications (may be absent in late onset); cerebral atrophy |
| Hutchinson-Gilford Progeria Syndrome | <i>LMNA</i> | Progerin, truncated form of the lamin A precursor prelamin A: maintenance of nuclear architecture and stability, as well as genome organization and function | Ischemic stroke; progressive arterial stenoses; craniofacial disproportion with maxillary and mandibular hypoplasia |
| Alagille syndrome | <i>JAG1, NOTCH2</i> | Jagged1: Transmembrane receptor for the Notch signaling pathway; NOTCH2: Jagged 1 ligand; vascular development, and response in cases of vascular injury | Ischemic and hemorrhagic stroke; aneurysms, dolichoectasia, Moyamoya syndrome, venous anomalies; Chiari 1 anomaly, craniosynostosis, intracranial hypertension, vertebral malformations, midline malformations |

(continued on next page)

Table 4
(continued)

| Disease Name | Gene Symbol | Protein name and Function | Neuroimaging Features |
|---|-------------------------|---|--|
| Williams-Beuren syndrome | <i>ELN</i> | Elastin: architectural and mechanical role in blood vessels | Rare moyamoya arteriopathy |
| Von Hippel–Lindau disease | <i>VHL</i> | VHL (Von Hippel–Lindau): tumor suppressor role | Hemorrhagic stroke; craniospinal hemangioblastomas; endolymphatic sac tumor |
| Autosomal Recessive | | | |
| Sickle cell disease (SCD) | HBB (β^S allele) | B Hemoglobin | Ischemic and hemorrhagic strokes; WM signal alterations; cerebral atrophy; moyamoya arteriopathy; vertebral bone infarction, osteomyelitis, and altered marrow signal |
| Deficiency of adenosine deaminase 2 (DADA-2) | <i>CECR1</i> | Adenosine deaminase 2: growth and development of macrophages, important for the proper immune response and endothelial integrity | Lacunar ischemic infarcts in the nucleo-capsular, midbrain, and thalamic regions; hemorrhagic stroke, microhemorrhages, arterial stenoses with perivascular enhancing tissue in the posterior circulation, small-sized intracranial aneurysms, brain atrophy |
| Pseudoxanthoma elasticum (PXE) | <i>ABCC6</i> | <i>ABCC6</i> (ATP-binding cassette sub-family C member 6): transport and deposition of elastic fibers in the vessel wall | Ischemic stroke, intra- and extra-cranial aneurysms, arterial stenosis, tortuosity, and occlusion; segmental hypoplasia/aplasia of the petrous and/or cavernous segments of the ICA often associated with compensating arterial network supplied by external carotid artery branches (carotid rete mirabile) |
| Cerebral autosomal recessive arteriopathy with subcortical infarcts and leukoencephalopathy (CARASIL) | <i>HTRA1</i> | <i>HTRA1</i> (High-Temperature Requirement A Serine Peptidase 1): protein quality control under various stress conditions | Diffuse WM changes and multiple lacunar infarctions in the BG and thalamus; microhemorrhages |
| Ehlers-Danlos syndrome type VIA (EDS-Via) | <i>PLOD1</i> | <i>PLOD1</i> (Procollagen-Lysine,2-Oxoglutarate 5-Dioxygenase 1): catalyzes the hydroxylation of lysyl residues in collagen-like peptides | Perinatal stroke; hemorrhagic stroke; kyphoscoliosis |

(continued on next page)

Table 4
(continued)

| Disease Name | Gene Symbol | Protein name and Function | Neuroimaging Features |
|---|---|--|--|
| Grange syndrome | YY1AP1 | Yin yang 1-associated protein 1, DNA repair pathway in vascular smooth muscle cells | Hemorrhagic and ischemic stroke; subarachnoid stroke; arterial stenoses and occlusion; |
| ADAMTS13 thrombotic microangiopathy | ADAMTS13 | Extracellular matrix components, part of the coagulation cascade | Ischemic stroke (often multiple) |
| Acardi-Goutieres Syndromes | RNASEH2A RNASEH2B RNASEH2C SAMHD1 TREX1 | Ribonuclease H2 subunit A, B, and C; SAMHD1 (SAM And HD Domain Containing Deoxynucleoside Triphosphate Triphosphohydrolase 1); TREX1: regulation of the innate immune response | Ischemic stroke; aneurysms; arterial stenoses; WM signal alterations with frontotemporal predominance or diffuse involvement; delayed myelination; deep WM cysts in frontal and temporal regions; periventricular leukomalacia-like pattern; cerebral calcifications; cerebral atrophy |
| Fabry disease | GLA | α -galactosidase, part of the transportation of globotriaosylceramide | Ischemic strokes (mostly posterior circulation); lacunar infarcts; WM signal changes; basilar artery dolichoectasia; subarachnoid hemorrhage |
| Microcephalic osteodysplastic primordial dwarfism type II (MOPD II) | PCNT | Pericentrin, protein involved in centrosomes function (cell cycle progression) | Ischemic and hemorrhagic strokes, Moyamoya vasculopathy, aneurysms; microcephaly, rare malformations of cortical development |
| Arterial tortuosity syndrome | SLC2A10 | Glucose Transporter 10 (GLUT10): Facilitative glucose transporter | Elongated and tortuous large and medium-sized arteries; aneurysms; rare dissection |

Abbreviations: ACA, anterior cerebral artery; BG, basal ganglia; ICA, internal carotid artery; MCA, middle cerebral artery; WM, white matter.

^a with multiple variants at R179 position.

^b Single variant at R325 C position.

^c Variants located at 3'-UTR.

enhancement in the hemiplegic form. No diffusion restriction of the affected areas is detected. Distinct phases of parenchymal hypoperfusion, lasting for several hours, and rebound hyperfusion are often found in migraine with aura (A.K.A. complicated migraine or hemiplegic migraine) and are particularly conspicuous in ASL sequences (Fig. 8).⁷⁴ In such cases, there is often diffuse pruning of cortical branch arteries on time of flight MRA and dephasing effects on susceptibility-weighted MRI sequences.

Todd's paralysis after seizures is another AIS mimic in children. This post-ictal phenomenon can occur in 13% of seizure cases, including partial or complete hemiparesis lasting between 30 min and 36 hours. Decreased cerebral perfusion owing to cortical spreading depolarizations may be observed without restricted diffusion in the affected brain parenchyma.^{11,75}

As a mimic of pediatric stroke, symptomatic facial nerve dysfunction is common. Clinical

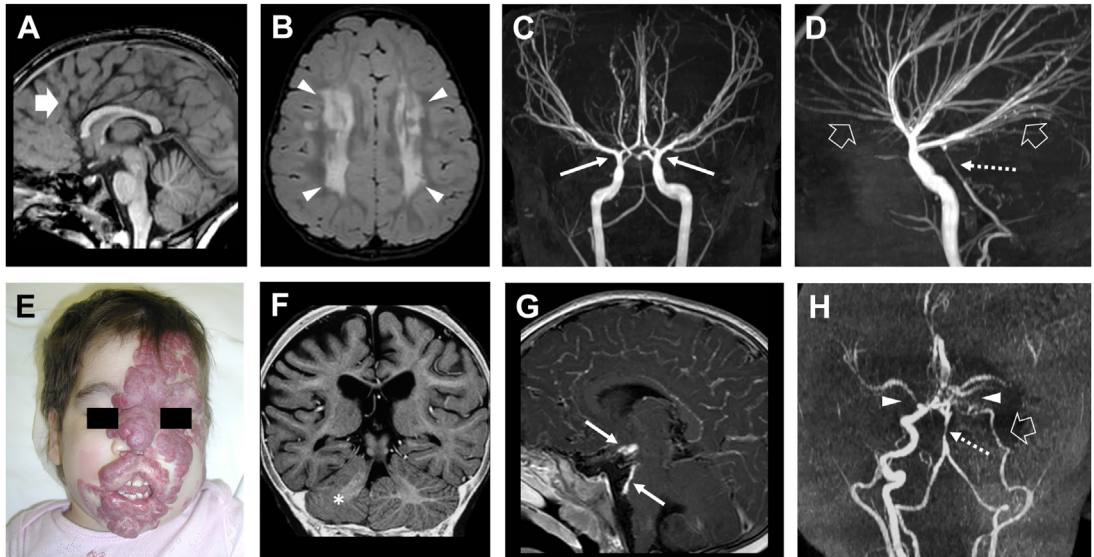


Fig. 7. Genetic and syndromic conditions related to pediatric AIS. (A–D) ACTA2-related arteriopathy in a 2-year-old girl. (A) Sagittal T1-weighted image reveals a corpus callosum dysmorphism associated with fronto-mesial dysgyria (thick arrow). (B) Axial FLAIR image reveals confluent white matter signal changes in the cerebral hemispheres (arrowheads). (C, D) 3D-TOF images show fusiform dilatation and straightening of ICA cavernous/clinoid segments associated with mild stenosis of terminal ICA (thin arrows), straightening and narrowing of MCA and ACA branches (empty arrows), and absence of moyamoya collaterals. There is severe stenosis and straightening of the basilar artery (dashed arrow). (E–H) PHACES (posterior fossa malformations, hemangioma, arterial anomalies, coarctation of the aorta/cardiac defects, eye abnormalities, and sternal cleft anomalies) syndrome in an 11-month-old girl. (E) Picture showing extended segmental facial hemangioma. (F) Coronal inversion recovery T1-weighted image demonstrates right cerebellar hypoplasia with foliar abnormalities (asterisk). (G) Post-contrast T1-weighted image reveals an intracranial hemangioma located at the brainstem level (thin arrows). (H) 3D-TOF MRA depicts hypoplasia of the left ICA (empty arrow) associated with bilateral terminal ICA stenoses (arrowheads) and reduced flow signal in the MCA distributions (moyamoya arteriopathy). There is also a focal narrowing of the basilar artery (dashed arrow). Contrast enhancement outlining the cortical and callosal sulci (G) corresponds to leptomeningeal collaterals.

neurologic deficits resulting from peripheral facial nerve dysfunction can usually be clinically differentiated from AIS, as central facial nerve palsy resulting from AIS selectively impairs the lower facial muscles and spares the upper facial muscles. In contrast, peripheral facial nerve dysfunction affects the upper and lower facial muscles. Peripheral facial nerve dysfunction is mostly the result of Bell's palsy, infection, or trauma and is frequently associated with abnormal ipsilateral contrast enhancement of the canalicular or tympanic segments of the facial nerve in the absence of brain parenchymal changes on MRI.⁷⁶

Demyelinating diseases, which include multiple sclerosis and acute disseminated encephalomyelitis, can present primarily with acute ataxia and should be included in the differential diagnosis of pediatric AIS, as should tumors. In such cases, brain MRI findings will definitively differentiate AIS from these conditions.⁷⁶ In addition, several instances of pediatric stroke are not associated

with thromboembolic large vessel occlusion, including arteriopathies, mitochondrial diseases and moyamoya arteriopathies.

TREATMENT

Medical Treatment in Perinatal Arterial Ischemic Stroke

Reperfusion therapies (fibrinolytic agents and MT) and antithrombotic treatment is generally not indicated in neonatal AIS. Secondary stroke prophylaxis with antithrombotics may occasionally be used in selected cases (ie, severe thrombophilia or cerebral embolism resulting from cardiac disease).¹

The management of neonatal AIS is currently based on supportive care measures, including the control of seizures, the optimization of oxygenation, and the correction of dehydration and anemia. Early initiation of targeted rehabilitation

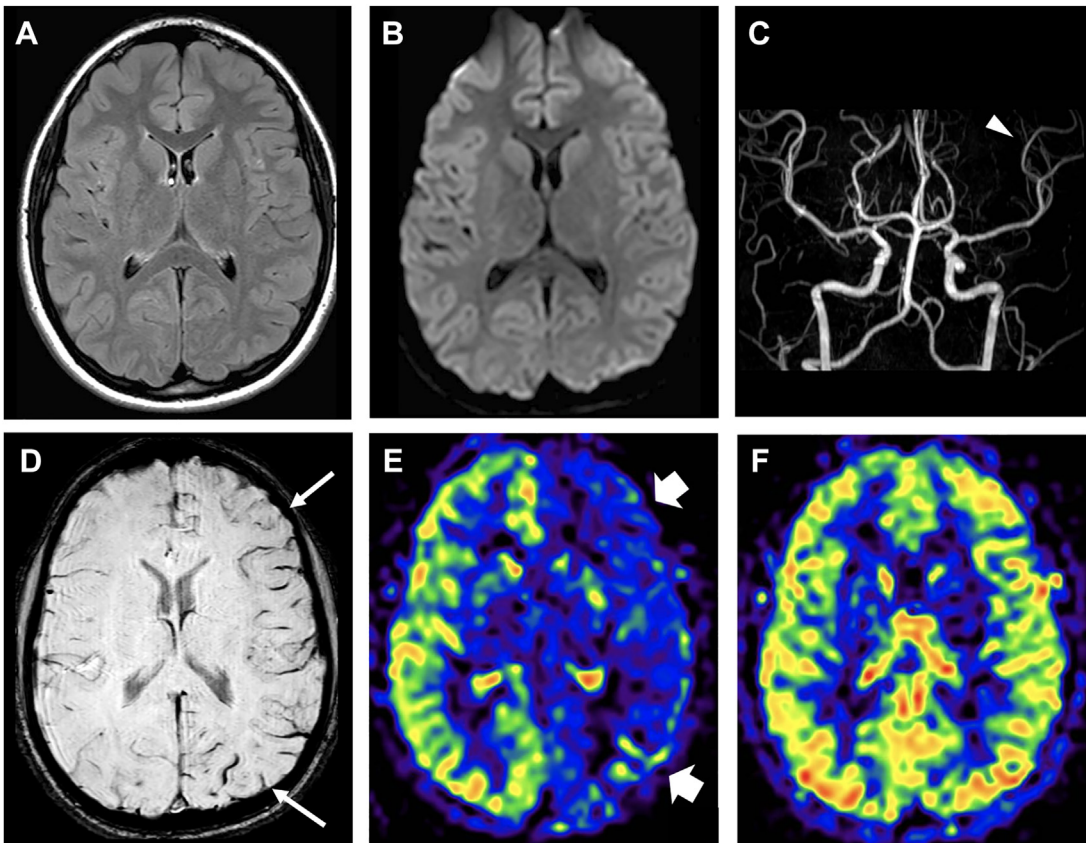


Fig. 8. Migraine attack in a 13-year-old girl presenting with headache, speech disorder and right-sided hyposthesia, and hypotonia. Axial FLAIR (A) and DWI (B) images at clinical onset show normal findings. (C) 3D-TOF reveals a very mild reduction of flow signal in the left distal MCA branches (*arrowhead*). (D) Axial SWI demonstrates increased signal in the left hemispheric cortical veins (*thin arrows*). (E) Axial ASL shows reduced cerebral blood flow in the left hemisphere (*thick arrows*). (F) Follow-up ASL study performed 3 days later reveals resolution of flow-related signal changes.

therapy has been shown to improve functional outcomes in affected patients.⁸

Reperfusion Therapies for Non-perinatal Pediatric Arterial Ischemic Stroke

Intravenous thrombolytic therapy

Despite the absence of randomized controlled data, intravenous fibrinolytic therapy with alteplase is used to treat nonperinatal AIS, with recent studies showing a more than two-fold increase in utilization across U.S. centers between 2005 and 2019.⁷⁷ At least 2 well-designed multi-center study established the safety of intravenous alteplase administered at the standard adult dose and infusion rate within 4.5 hours of AIS onset to eligible children who are 2 to 17 years of age^{77,78}. Reluctance to treat children younger than 2 years of age persists since many neuropediatricians do not believe that clinical stroke severity or timing

of stroke onset can be reliably determined in this age group. Tenecteplase is a genetically modified form of tissue plasminogen activator with a prolonged half-life that enables single bolus dosing, and which is engineered to bind to the fibrin component of thrombus such that it selectively converts thrombus-bound plasminogen to plasmin. While tenecteplase is increasingly replacing alteplase for hyperacute reperfusion therapy in adult stroke centers, providers are cautioned about its use in the pediatric population given the absence of pharmacokinetic and safety data in children with AIS.⁷⁹ Rapid hyperacute neuroimaging plays a critical role in the selection of patients for intravenous fibrinolytic therapy. Such imaging studies must reliably exclude intracranial hemorrhage and cannot delay the administration of reperfusion therapies. Notably, current American Heart Association guidelines for the early management of AIS in adults do not recommend

withholding intravenous fibrinolytic therapy in otherwise eligible patients who demonstrate cerebral microbleeds on brain MRI.⁸⁰ Moreover, delaying the administration of fibrinolytic therapy in patients who are considered eligible based on noncontrast CT is discouraged. While intravenous fibrinolytic therapy may be beneficial for patients with adult AIS with Sickle Cell Disease, the hyperacute and acute management of AIS in children with Sickle Cell Disease should be focused on emergent transfusion therapy, administration of supplemental oxygen, hydration with intravenous fluids, maintenance of normothermia and antibiotics if infection is suspected.^{80,81}

Endovascular thrombectomy

As in adults, endovascular thrombectomy (EVT) improves neurologic outcomes in pediatric patients with AIS due to acute large vessel occlusion when performed in properly selected patients.^{82–84} As a result of diagnostic delays owing to the disproportionately high frequency of stroke mimics in children with acute neurologic deficits and pediatric provider inexperience with stroke, the majority of pediatric stroke patients present with considerable delays. Recently, the Save ChildS study demonstrated that EVT in children has a similar safety profile compared with adults when performed up to 24 hours from the onset of symptoms, especially in patients 7 to 18 years of age. (Sporns PB),⁸⁵ The widening of therapeutic windows has thus encouraged the creation of pediatric stroke alert protocols in pediatric referral centers, with the definition of resource-based diagnostic algorithms based on the availability of anesthesiology support, emergency MRI, and neurointerventional expertise. to have retrospect⁸⁶

Most recently, the results of the Save Childs Pro registry, revealed at the 2024 Annual Congress of the International Pediatric Stroke Organization (Sporns PB et al), showed that EVT achieves superior neurologic outcomes relative to the best medical therapy in properly selected children with AIS due to acute intracranial medium or large vessel occlusion. Despite this, the safety and efficacy of MT in children with FCA remains uncertain with several anecdotal cases of poor response to EVT. Moreover, the risk of attempted EVT in the broader population of children with cerebral arteriopathy is considered to be substantial, particularly in patients with moyamoya arteriopathies, collagenopathies, elastinopathies, and other arteriopathies with increased fragility of the arterial wall. This underscores the importance of etiologic determination at the time of initial imaging, and the need for multidisciplinary team discussions on a case-by-case basis.

Nonetheless, there is a strong general consensus that EVT is safe and effective for children with intracranial medium or large vessel occlusions due to embolus, which is either cardiogenic or from a cervical artery dissection. Although penumbral imaging continues to play an important role in the selection of adult patients for EVT, the perfusion metrics that differentiate core infarction, from penumbra, from benign oligemia have not been established for the pediatric population and no meaningful application of penumbral imaging to pediatric patient selection for EVT is possible.⁸³

SUMMARY

Confirming the diagnosis of pediatric AIS and determining its etiology is crucial for optimizing treatment and for prognosis. Pediatric AIS should be managed in the context of a multidisciplinary team with expertise in the management of pediatric stroke. Radiologists should be familiar with the pros and cons of each imaging modality and specific findings of different stroke-related pathologies and their most common mimics, more so in the modern era of mechanical thrombectomy.

CLINICS CARE POINTS

- Neuroimaging protocols for AIS in children should be tailored based on the age and timing of presentation.
- Fast MRI protocols with arterial MR angiography and perfusion studies are useful to distinguish between AIS and other causes of acute neurologic presentation in children.
- Full MRI protocols should include additional sequences, such as black blood vessel wall imaging, that may help in the differential diagnosis of pediatric AIS.
- Repeated imaging and follow-up timing will change according to the cause of pediatric or neonatal AIS.

DISCLOSURE

The authors have nothing to disclose.

FUNDING

This work was supported by The Italian Ministry of Health, 5x1000 project n. 5M-2019-23680415.

REFERENCES

1. Ferriero DM, Fullerton HJ, Bernard TJ, et al. Management of stroke in neonates and children: a






- scientific statement from the American heart association/American stroke association. *Stroke* 2019; 50(3):e51–96.
2. Gao L, Lim M, Nguyen D, et al. The incidence of pediatric ischemic stroke: a systematic review and meta-analysis. *Int J Stroke* 2023;18(7):765–72.
 3. DeLaroche AM, Sivaswamy L, Farooqi A, et al. Pediatric stroke and its mimics: limitations of a pediatric stroke clinical pathway. *Pediatr Neurol* 2018;80: 35–41.
 4. Rafay MF, Pontigon AM, Chiang J, et al. Delay to diagnosis in acute pediatric arterial ischemic stroke. *Stroke* 2009;40(1):58–64.
 5. Neville K, Lo W. Sensitivity and specificity of an adult stroke screening tool in childhood ischemic stroke. *Pediatr Neurol* 2016;58:53–6.
 6. Ichord RN, Bastian R, Abraham L, et al. Interrater reliability of the pediatric national Institutes of Health stroke scale (PedNIHSS) in a multicenter study. *Stroke* 2011;42(3):613–7.
 7. Tam D. Calculated decisions: pediatric NIHSS stroke scale (pedNIHSS). *Pediatr Emerg Med Pract* 2023; 20(5 Suppl):CD1–2.
 8. Kirton A, Armstrong-Wells J, Chang T, et al. Symptomatic neonatal arterial ischemic stroke: the international pediatric stroke study. *Pediatrics* 2011; 128(6):e1402–10.
 9. Roy B, Webb A, Walker K, et al. Risk factors for perinatal stroke in term infants: a case-control study in Australia. *J Paediatr Child Health* 2023;59(4):673–9.
 10. Negrotto M, Muthusami P, Wasserman BA, et al. Initial diagnostic evaluation of the child with suspected arterial ischemic stroke. *Top Magn Reson Imag* 2021;30(5):211–23.
 11. Sporns PB, Fullerton HJ, Lee S, et al. Childhood stroke. *Nat Rev Dis Prim* 2022;8(1):12.
 12. Khalaf A, Iv M, Fullerton H, et al. Pediatric stroke imaging. *Pediatr Neurol* 2018;86:5–18.
 13. Mackay MT, Lee M, Yock-Corrales A, et al. Differentiating arterial ischaemic stroke from migraine in the paediatric emergency department. *Dev Med Child Neurol* 2018;60(11):1117–22.
 14. Expert Panel on Pediatric Imaging, Robertson RL, Palasis S, et al. ACR appropriateness criteria(R) cerebrovascular disease-child. *J Am Coll Radiol* 2020; 17(5S):S36–54.
 15. Christy A, Murchison C, Wilson JL. Quick brain magnetic resonance imaging with diffusion-weighted imaging as a first imaging modality in pediatric stroke. *Pediatr Neurol* 2018;78:55–60.
 16. Lee S, Mlynash M, Christensen S, et al. Hyperacute perfusion imaging before pediatric thrombectomy: analysis of the Save ChildS study. *Neurology* 2023; 100(11):e1148–58.
 17. Saunders DE, Thompson C, Gunny R, et al. Magnetic resonance imaging protocols for paediatric neuroradiology. *Pediatr Radiol* 2007;37(8):789–97.
 18. Lee S, Mirsky DM, Beslow LA, et al. Pathways for neuroimaging of neonatal stroke. *Pediatr Neurol* 2017;69:37–48.
 19. Jiang B, Mackay MT, Stence N, et al. Neuroimaging in pediatric stroke. *Semin Pediatr Neurol* 2022;43: 100989.
 20. Little SB, Sarma A, Bajaj M, et al. Imaging of vertebral artery dissection in children: an underrecognized condition with high risk of recurrent stroke. *Radiographics* 2023;43(12):e230107.
 21. Lee S, Ryan KR, Murray J, et al. Multidisciplinary stroke pathway for children supported with ventricular assist devices. *ASAIO J* 2023;69(4):402–10.
 22. Briest RC, Cheung AK, Kandula T, et al. Urgent computed tomography angiography in paediatric stroke. *Dev Med Child Neurol* 2023;65(1):126–35.
 23. Lee S, Jiang B, Heit JJ, et al. Cerebral perfusion in pediatric stroke: children are not little adults. *Top Magn Reson Imag* 2021;30(5):245–52.
 24. Goldman-Yassen AE, Dehkharghani S. Neuroimaging in perinatal stroke and cerebrovascular disease. In: Dehkharghani S, editor. *Stroke*. Brisbane (AU): Exon Publications; 2021. p. 1–24.
 25. Husson B, Lasjaunias P. Radiological approach to disorders of arterial brain vessels associated with childhood arterial stroke—a comparison between MRA and contrast angiography. *Pediatr Radiol* 2004;34(1):10–5.
 26. Nash M, Rafay MF. Craniocervical arterial dissection in children: pathophysiology and management. *Pediatr Neurol* 2019;95:9–18.
 27. Rollins N, Braga B, Hogge A, et al. Dynamic arterial compression in pediatric vertebral arterial dissection. *Stroke* 2017;48(4):1070–3.
 28. Gupta N, Hiremath SB, Aviv RI, et al. Childhood cerebral vasculitis : a multidisciplinary approach. *Clin Neuroradiol* 2023;33(1):5–20.
 29. Storey A, Michael Scott R, Robertson R, et al. Preoperative transdural collateral vessels in moyamoya as radiographic biomarkers of disease. *J Neurosurg Pediatr* 2017;19(3):289–95.
 30. Husson B, Hertz-Pannier L, Renaud C, et al. Motor outcomes after neonatal arterial ischemic stroke related to early MRI data in a prospective study. *Pediatrics* 2010;126(4):912–8.
 31. Mackay MT, Slavova N, Pastore-Wapp M, et al. Pediatric ASPECTS predicts outcomes following acute symptomatic neonatal arterial stroke. *Neurology* 2020;94(12):e1259–70.
 32. Geraldo AF, Parodi A, Bertamino M, et al. Perinatal arterial ischemic stroke in fetal vascular malperfusion: a case series and literature review. *AJNR Am J Neuroradiol* 2020;41(12):2377–83.
 33. Biswas A, Mankad K, Shroff M, et al. Neuroimaging perspectives of perinatal arterial ischemic stroke. *Pediatr Neurol* 2020;113:56–65.

34. Steggerda SJ, de Vries LS. Neonatal stroke in premature neonates. *Semin Perinatol* 2021;45(7):151471.
35. Husson B, Hertz-Pannier L, Adamsbaum C, et al. MR angiography findings in infants with neonatal arterial ischemic stroke in the middle cerebral artery territory: a prospective study using circle of Willis MR angiography. *Eur J Radiol* 2016;85(7):1329–35.
36. Baggio L, Nosadini M, Pelizza MF, et al. Neonatal arterial ischemic stroke secondary to carotid artery dissection: a case report and systematic literature review. *Pediatr Neurol* 2023;139:13–21.
37. Watson CG, Dehaes M, Gagoski BA, et al. Arterial spin labeling perfusion magnetic resonance imaging performed in acute perinatal stroke reveals hyperperfusion associated with ischemic injury. *Stroke* 2016;47(6):1514–9.
38. Kirkham FJ, Zafeiriou D, Howe D, et al. Fetal stroke and cerebrovascular disease: advances in understanding from lenticulostriate and venous imaging, alloimmune thrombocytopenia and monochorionic twins. *Eur J Paediatr Neurol* 2018;22(6):989–1005.
39. Kurnik K, Kosch A, Strater R, et al. Recurrent thromboembolism in infants and children suffering from symptomatic neonatal arterial stroke: a prospective follow-up study. *Stroke* 2003;34(12):2887–92.
40. Lehman LL, Beaute J, Kapur K, Danehy AR, Bernson-Leung ME, Malkin H, Rivkin MJ, Trenor CC 3rd. Workup for Perinatal Stroke Does Not Predict Recurrence. *Stroke*. 2017 Aug;48(8):2078-2083. doi: 10.1161/STROKEAHA.117.017356. Epub 2017 Jul 13. PMID: 28706112
41. Bernard TJ, Manco-Johnson MJ, Lo W, et al. Towards a consensus-based classification of childhood arterial ischemic stroke. *Stroke* 2012;43(2):371–7.
42. Bohmer M, Niederstadt T, Heindel W, et al. Impact of childhood arterial ischemic stroke standardized classification and diagnostic evaluation classification on further course of arteriopathy and recurrence of childhood stroke. *Stroke* 2019;50(1):83–7.
43. Fullerton HJ, Wintermark M, Hills NK, et al. Risk of recurrent arterial ischemic stroke in childhood: a prospective international study. *Stroke* 2016;47(1):53–9.
44. DeVela G, Taylor JM, Zhang B, Linscott LL, Chen AM, Karani KB, Furthmiller A, Leach JL, Vadivelu S, Abruzzo T. Quantitative Arterial Tortuosity Suggests Arteriopathy in Children With Cryptogenic Stroke. *Stroke*. 2018 Apr;49(4):1011-1014. doi: 10.1161/STROKEAHA.117.020321. Epub 2018 Mar 14. PMID: 29540605.
45. Baranoski JF, White AC, Chung CY, et al. Mechanical disorders of the cervicocerebral circulation in children and young adults. *J Neurointerventional Surg* 2023;16(9):939–46.
46. Hedjoudje A, Darcourt J, Bonneville F, et al. The use of intracranial vessel wall imaging in clinical practice. *Radiol Clin North Am* 2023;61(3):521–33.
47. Yeh HR, Kim EH, Yu JJ, et al. Arterial ischemic stroke in children with congenital heart diseases. *Pediatr Int* 2022;64(1):e15200.
48. Sun LR, Lynch JK. Advances in the diagnosis and treatment of pediatric arterial ischemic stroke. *Neurotherapeutics* 2023;20(3):633–54.
49. Elgendy AY, Saver JL, Amin Z, et al. Proposal for updated nomenclature and classification of potential causative mechanism in patent foramen ovale-associated stroke. *JAMA Neurol* 2020;77(7):878–86.
50. Wintermark M, Hills NK, DeVeber GA, et al. Clinical and imaging characteristics of arteriopathy subtypes in children with arterial ischemic stroke: results of the VIPS study. *AJNR Am J Neuroradiol* 2017;38(11):2172–9.
51. Perez FA, Oesch G, Amlie-Lefond CM. MRI vessel wall enhancement and other imaging biomarkers in pediatric focal cerebral arteriopathy-inflammatory subtype. *Stroke* 2020;51(3):853–9.
52. Bertamino M, Signa S, Veneruso M, et al. Expanding the clinical and neuroimaging features of post-varicella arteriopathy of childhood. *J Neurol* 2021;268(12):4846–65.
53. Fullerton HJ, Stence N, Hills NK, et al. Focal cerebral arteriopathy of childhood: novel severity Score and natural history. *Stroke* 2018;49(11):2590–6.
54. Fearn ND, Mackay MT. Focal cerebral arteriopathy and childhood stroke. *Curr Opin Neurol* 2020;33(1):37–46.
55. Smitka M, Bruck N, Engellandt K, et al. Clinical perspective on primary angiitis of the central nervous system in childhood (cPACNS). *Frontiers in Pediatrics* 2020;8:281.
56. Elbers J, Armstrong D, Yau I, et al. Vascular imaging outcomes of childhood primary angiitis of the central nervous system. *Pediatr Neurol* 2016;63:53–9.
57. Scott RM, Smith ER. Moyamoya disease and moyamoya syndrome. *N Engl J Med* 2009;360(12):1226–37.
58. Morello A, Scala M, Schiavetti I, et al. Surgical revascularization as a procedure to prevent neurological complications in children with moyamoya syndrome associated with neurofibromatosis I: a single institution case series. *Child's Nerv Syst* 2024;40(6):1731–41.
59. Tortora D, Scavetta C, Rebella G, et al. Spatial coefficient of variation applied to arterial spin labeling MRI may contribute to predict surgical revascularization outcomes in pediatric moyamoya vasculopathy. *Neuroradiology* 2020;62(8):1003–15.
60. Tortora D, Severino M, Pacetti M, et al. Noninvasive assessment of hemodynamic stress distribution after indirect revascularization for pediatric moyamoya vasculopathy. *AJNR Am J Neuroradiol* 2018;39(6):1157–63.
61. Dlamini N, Shah-Basak P, Leung J, et al. Breath-hold blood oxygen level-dependent MRI: a tool for the

- assessment of cerebrovascular reserve in children with moyamoya disease. *AJNR Am J Neuroradiol* 2018;39(9):1717–23.
62. Alshehri E, Dmytriw AA, Chavhan GB, et al. The role of MRA in pediatric sickle cell disease with normal transcranial Doppler imaging velocities. *J Stroke Cerebrovasc Dis* 2020;29(7):104864.
 63. Mallon D, Doig D, Dixon L, et al. Neuroimaging in sickle cell disease: a review. *J Neuroimaging* 2020;30(6):725–35.
 64. Rawanduzy CA, Earl E, Mayer G, et al. Pediatric stroke: a review of common etiologies and management strategies. *Biomedicines* 2022;11(1):2.
 65. Booth N, Ngwube A, Appavu B, et al. Reversal of cerebral arteriopathy post-hematopoietic Stem cell transplant for sickle cell disease. *Pediatrics* 2024;153(2). e2023062643.
 66. Jankovic M, Petrovic B, Novakovic I, et al. The genetic basis of strokes in pediatric populations and insight into new therapeutic options. *Int J Mol Sci* 2022;23(3):1601.
 67. Grossi A, Severino M, Rusmini M, et al. Targeted resequencing in pediatric and perinatal stroke. *Eur J Med Genet* 2020;63(11):104030.
 68. Geraldo AF, Caorsi R, Tortora D, et al. Widening the neuroimaging features of adenosine deaminase 2 deficiency. *AJNR Am J Neuroradiol* 2021;42(5):975–9.
 69. Gupta N, Miller E, Bhatia A, et al. Imaging review of pediatric monogenic CNS vasculopathy with genetic correlation. *Radiographics* 2024;44(5):e230087.
 70. Tortora D, Severino M, Accogli A, et al. Moyamoya vasculopathy in PHACE syndrome: six new cases and review of the literature. *World Neurosurgery* 2017;108:291–302.
 71. Gorodetsky C, Pulcine E, Krishnan P, et al. Childhood arterial ischemic stroke due to mineralizing angiopathy: an 18-year single-center experience. *Dev Med Child Neurol* 2021;63(9):1123–6.
 72. Bahri R, Sharma RS, Jain V. Mineralizing angiopathy with basal ganglia stroke after minor head trauma; a clinical profile and follow up study of a large series of paediatric patients from North India. *Eur J Paediatr Neurol* 2021;33:61–7.
 73. Mackay MT, Chua ZK, Lee M, et al. Stroke and non-stroke brain attacks in children. *Neurology* 2014;82(16):1434–40.
 74. Sinha R, Ramji S. Neurovascular disorders in children: an updated practical guide. *Transl Pediatr* 2021;10(4):1100–16.
 75. Brosinski CM. Implementing diagnostic reasoning to differentiate Todd's paralysis from acute ischemic stroke. *Adv Emerg Nurs J* 2014;36(1):78–86.
 76. Caffarelli M, Kimia AA, Torres AR. Acute ataxia in children: a review of the differential diagnosis and evaluation in the emergency department. *Pediatr Neurol* 2016;65:14–30.
 77. Kaur N, Patel S, Ayanbadejo MO, et al. Age-specific trends in intravenous thrombolysis and mechanical thrombectomy utilization in acute ischemic stroke in children under age 18. *Int J Stroke* 2023;18(4):469–76.
 78. Kossorotoff M, Kerleroux B, Boulouis G, Husson B, Tran Dong K, Eugene F, Damaj L, Ozanne A, Bellesme C, Rolland A, Bourcier R, Triquenot-Bagan A, Marnat G, Neau JP, Joriot S, Perez A, Guillen M, Perivier M, Audic F, Hak JF, Denier C, Naggara O; KidClot Group. Recanalization Treatments for Pediatric Acute Ischemic Stroke in France. *JAMA Netw Open*. 2022 Sep 1;5(9):e2231343. doi: 10.1001/jamanetworkopen.2022.31343. PMID: 36107427; PMCID: PMC9478769
 79. Sun LR, Wilson JL, Waak M, et al. Tenecteplase in acute stroke: what about the children? *Stroke* 2023;54(7):1950–3.
 80. Powers WJ, Rabinstein AA, Ackerson T, et al. Guidelines for the early management of patients with acute ischemic stroke: 2019 update to the 2018 guidelines for the early management of acute ischemic stroke: a guideline for healthcare professionals from the American heart association/American stroke association. *Stroke* 2019;50(12):e344–418. Epub 2019 Oct 30. Erratum in: *Stroke*. 2019 Dec;50(12):e440–e441. doi: 10.1161/STR.0000000000000215. PMID: 31662037).
 81. Kassim AA, Galadanci NA, Pruthi S, et al. How I treat and manage strokes in sickle cell disease. *Blood* 2015;125(22):3401–10.
 82. Sporns PB, Psychogios MN, Straeter R, et al. Clinical diffusion mismatch to select pediatric patients for embolectomy 6 to 24 hours after stroke: an analysis of the Save ChildS study. *Neurology* 2021;96(3):e343–51.
 83. Bhatia KD, Chowdhury S, Andrews I, et al. Association between thrombectomy and functional outcomes in pediatric patients with acute ischemic stroke from large vessel occlusion. *JAMA Neurol* 2023;80(9):910–8.
 84. Dicipinigaitis AJ, Gandhi CD, Pisapia J, et al. Endovascular thrombectomy for pediatric acute ischemic stroke. *Stroke* 2022;53(5):1530–9.
 85. Kunz WG, Sporns PB, Psychogios MN, et al. Cost-effectiveness of endovascular thrombectomy in childhood stroke: an analysis of the Save ChildS study. *J Stroke* 2022;24(1):138–47.
 86. Shack M, Andrade A, Shah-Basak PP, et al. A pediatric institutional acute stroke protocol improves timely access to stroke treatment. *Dev Med Child Neurol* 2017;59(1):31–7.

ORIGINAL RESEARCH

Evidence of Varicella Zoster Virus Reactivation in Children With Arterial Ischemic Stroke: Results of the VIPS II Study

Heather J. Fullerton , MD, MAS; Nancy K. Hills , PhD; Max Wintermark , MD, MAS; Nomazulu Dlamini , MD, MSc, PhD; Catherine Amlie-Lefond , MD; Michael M. Dowling , MD, PhD; Lori C. Jordan , MD, PhD; Neil R. Friedman, MBChB; Mitchell S. V. Elkind , MD, MS; Charles Grose , MD; the VIPS II Investigators*

BACKGROUND: Varicella zoster virus (VZV) has historically been associated with focal cerebral arteriopathy and arterial ischemic stroke (AIS) in children, and risk of AIS and myocardial infarction in adults. The VIPS (Vascular Effects of Infection in Pediatric Stroke) II study aimed to determine whether VZV remains a pediatric stroke trigger in an era of routine VZV vaccination.

METHODS: This 22-center prospective cohort study enrolled 205 patients (28 days to 18 years; median, 11.6 years) with spontaneous AIS (December 2016 to January 2022) in North America and Australia, performed parental interviews, and collected baseline (hyperacute [≤ 72 hours; $n=194$] and acute [4–6 days; $n=181$]) and convalescent (1–6 weeks; $n=74$) serum samples. A virology research laboratory measured VZV IgM and IgG titers by an in-house ELISA in patients with AIS and 95 unmatched well control children.

RESULTS: Baseline serologies indicated prior VZV exposure in 198 patients (97%). Parents recalled prior VZV vaccination in 160 (78%) and remote chickenpox in 3 (1.4%). Twenty patients (9.8%) had serologic evidence of recent VZV reactivation at the time of their stroke; all were asymptomatic. All had remote VZV exposure with VZV vaccination (median) 6.1 years prior. We observed recent VZV reactivation in patients with focal cerebral arteriopathy (4/32 [12.5%]) but not with arterial dissection or moyamoya. All 95 controls had serologic evidence of prior VZV exposure and 3 (3.1%) had recent VZV reactivation.

CONCLUSIONS: One in 10 patients with childhood AIS had recent, asymptomatic VZV reactivation. In a vaccinated population, VZV may continue to play a modest role in childhood stroke pathogenesis.

Key Words: children ■ ischemic stroke ■ varicella zoster virus (VZV) ■ VZV IgM

Childhood arterial ischemic stroke (AIS) occurs annually in at least 2.4 per 100 000 US children; the majority of affected children were previously healthy.^{1,2} The pathogenesis of childhood AIS appears multifactorial, a combination of chronic and acquired

risk factors. The VIPS (Vascular Effects of Infection in Pediatric Stroke) I study demonstrated that common, minor childhood infections, mostly upper respiratory infections, transiently increase stroke risk for a matter of days.³ The mechanisms promoting AIS likely relate

Correspondence to: Heather J. Fullerton, MD, MAS, Department of Neurology, Box 0663, University of California, San Francisco, 675 Nelson Rising Lane, Room 412A, San Francisco, CA 94143-0663. Email: heather.fullerton@ucsf.edu

*A complete list of the VIPS II Investigators can be found in the appendix at the end of the manuscript.

This manuscript was sent to Adriana B. Conforto, MD, PhD, Guest Editor, for review by expert referees, editorial decision, and final disposition.

Preprint posted on MedRxiv May 28, 2024. doi: <https://doi.org/10.1101/2024.05.26.24307958>.

Supplemental Material is available at <https://www.ahajournals.org/doi/suppl/10.1161/JAHA.124.039184>

For Sources of Funding and Disclosures, see page 9.

© 2025 The Author(s). Published on behalf of the American Heart Association, Inc., by Wiley. This is an open access article under the terms of the [Creative Commons Attribution-NonCommercial-NoDerivs](https://creativecommons.org/licenses/by-nc-nd/4.0/) License, which permits use and distribution in any medium, provided the original work is properly cited, the use is non-commercial and no modifications or adaptations are made.

JAHA is available at: www.ahajournals.org/journal/jaha

RESEARCH PERSPECTIVE

What Is New?

- The VIPS (Vascular Effects of Infection in Pediatric Stroke) II study found serological evidence of asymptomatic varicella zoster virus (VZV) reactivation at the time of arterial ischemic stroke in 10% of a new prospective childhood stroke cohort; these children had been vaccinated a median of 6 years prior.
- Although children in North America and Australia are now routinely vaccinated against VZV, the virus may still play a role in the pathogenesis of childhood arterial ischemic stroke.

What Question Should Be Addressed Next?

- Long-term studies of VZV vaccines should test whether asymptomatic VZV reactivation, particularly in the setting of waning immunity and wild-type VZV exposure, plays a role in stroke or other vascular disease in children and adults.

Nonstandard Abbreviations and Acronyms

| | |
|--------------|---|
| AIS | arterial ischemic stroke |
| FCA | focal cerebral arteriopathy |
| FOCAS | Focal Cerebral Arteriopathy Steroid |
| VIPS | Vascular Effects of Infection in Pediatric Stroke |
| VZV | varicella zoster virus |

to circulating inflammatory cytokines affecting the coagulation system and endothelium (cardiac or arterial), as well as direct effects of viruses on endothelium.⁴

While this association between infection and AIS is not specific to any one virus, varicella zoster virus (VZV) is thought to play a unique role in stroke pathogenesis. Primary VZV infection manifests as chickenpox; the virus becomes latent in neurons and can reactivate years later to cause shingles. In adults, epidemiologic evidence suggests that shingles transiently increases risk of both ischemic stroke and myocardial infarction.^{5,6} In the VIPS I case-control study (2010–2014), serologic evidence of acute VZV infection (positive VZV IgM antibodies) quadrupled the odds of childhood AIS (odds ratio, 4.43; $P=0.02$) and was present in 11% of 326 childhood AIS patients.⁷ Prior VZV vaccination, on the other hand, was protective, reducing the odds of childhood AIS by half (odds ratio, 0.51; $P=0.0003$).³

VZV has been particularly linked to childhood focal cerebral arteriopathy (FCA), an acute inflammatory arteriopathy that is unilateral, monophasic, and typically

involves the distal internal carotid artery or its proximal branches.^{8,9} FCA typically presents with acute-onset hemiparesis in a previously healthy school-aged child. Initial imaging often demonstrates basal ganglia infarction from early involvement of lenticulostriate arteries arising from the inflamed large arteries (internal carotid artery, middle and anterior cerebral artery). Large-artery stenosis progresses rapidly over days, followed by slow improvement over months. FCA occurring weeks to months after chickenpox is also known as “post-varicella arteriopathy.”¹⁰ Because VZV remains latent in the trigeminal ganglion, and the trigeminal nerve innervates the cerebral arteries affected in FCA, latent VZV is hypothesized to reactivate, travel antegrade along nerve branches to cerebral arteries, and result in this unilateral focal inflammatory arteriopathy.^{11,12}

Children in North America and Australia now routinely receive VZV vaccination in early childhood, and chickenpox is rare. In VIPS II, we aimed to study the role of VZV in childhood stroke in this modern post-vaccination era, anticipating that its importance would wane as vaccination rates increased. Based on prior knowledge of post-varicella arteriopathy, we hypothesized that VZV infection, when present, would more commonly precede arteriopathic stroke, particularly FCA, compared with cardioembolic or idiopathic stroke.

METHODS

The VIPS II data are available upon reasonable request to the corresponding author and according to the study’s formal data-sharing policy (pursuant to the National Institutes of Health Data Management and Sharing Policy).

Setting and Case Enrollment

VIPS II is a prospective cohort study that enrolled children with spontaneous arteriopathic, cardioembolic, or idiopathic AIS at 22 centers (21 North American, 1 Australian) over a 5-year enrollment period: December 2016 to January 2022. Each site obtained local institutional review board approval and informed consent/assent for each patient enrolled. Inclusion criteria were age 28 days through 18 years at stroke ictus; AIS, defined as acute-onset neurological deficits with corresponding acute infarcts in an arterial territory on brain imaging; enrolled within 72 hours of stroke ictus (or last seen normal); and stroke type classified as arteriopathic, cardioembolic, or idiopathic at the time of enrollment. VIPS II excluded strokes that were iatrogenic (eg, postsurgical or chemotherapy related) because infection was less likely to play a role in stroke pathogenesis. To reduce heterogeneity, it excluded strokes that did not fall into 1 of the primary 3 categories

(arteriopathic, cardioembolic, or idiopathic) and would have been classified as “other” stroke subtype in VIPS I (28/355 VIPS I patients).¹³ Sites interviewed parents or guardians within 1 week of enrollment using the VIPS I standardized script modified to remove time-consuming medication exposure questions; it included questions about prior chickenpox, VZV vaccination, and infectious signs/symptoms including presence of a rash, and rash characteristics (eg, blisters/vesicles).³ Sites performed detailed abstraction of medical records into case report forms in a central REDCap database.

Biological Sample Collection

The VIPS I study was limited by a broad 3-week time window for sample collection following a stroke; it could not exclude the possibility that, rather than VZV infection triggering stroke, stroke triggered VZV reactivation during the period of poststroke down-regulation of immunity.¹⁴ To address this limitation in VIPS II, sites collected blood samples at 4 time points relative to the stroke ictus: hyperacute (≤ 72 hours), acute (4–6 days), convalescent (1–6 weeks), and chronic (2–12 months).

Pathogenetic Classification

Clinically obtained brain and vascular imaging was collected for central review. A pediatric stroke neurologist (H.J.F.) and neuroradiologist (M.W.) independently reviewed all available baseline and follow-up imaging and clinical data to confirm the AIS and centrally classify the stroke type using the methods of the original VIPS study^{13,15}; disagreements were resolved through discussion. The primary classification categorized stroke pathogeneses into 4 mutually exclusive groups: definite arteriopathy, possible arteriopathy, cardioembolic, and idiopathic. The possible arteriopathy cases had abnormal vascular imaging that could represent arteriopathy versus thrombus; that subgroup therefore could include some cardioembolic or idiopathic strokes. The idiopathic category included patients with no or modest stroke risk factors, such as genetic thrombophilias or isolated patent foramen ovale. Definite arteriopathy cases were further categorized into arteriopathy subtypes; intracranial dissections involving the anterior circulation were designated as FCA-d (dissection subtype).¹³ The brain imaging was also used to measure the volume of infarcts (using ABC/2).¹⁵

Control Enrollment

While the a priori primary analyses in VIPS II were cross-sectional (eg, examining associations between infectious exposures and stroke type), we also planned to enroll stroke-free well controls to provide contextual information on subclinical infection in healthy children. Although some sites were prohibited from enrolling

controls because of pandemic-era restrictions, 17 of 22 sites enrolled unmatched stroke-free well controls (aged 28 days to 18 years) in pediatric clinics or pre-anesthesia settings (before elective imaging or minor procedures). We defined “well” as having no infection, acute hospitalization, trauma, or immunizations in the prior 2 weeks. Control exclusion criteria included history of a chronic disease and daily medication usage. After obtaining informed consent, sites collected blood samples (single time point, at enrollment) from controls and performed the same standardized parental interview used in the patients.

VZV Serologies

A varicella research laboratory at the University of Iowa used an established in-house ELISA to measure VZV IgM and IgG serologies on serum samples from each available time point.¹⁶ The antigen for the ELISA was the VZV glycoprotein E (previously called glycoprophosphatidylinositol); glycoprotein E is the most abundant VZV glycoprotein and has no cross-reactivity with any herpes simplex virus protein.^{16,17} Antihuman secondary antibodies conjugated to alkaline phosphatase were purchased from Thermo Scientific (goat antihuman IgG, Catalog No. 62-8422; and goat antihuman IgM, No. A18844). The plate was read at 405-nm wavelength. A negative titer (no antibody detected) was considered a level ≤ 0.1 absorbance units. The VZV antibody assays do not distinguish between wild-type VZV and the live, attenuated VZV in the chickenpox vaccine. All assays were carried out in at the central laboratory in Iowa with the same equipment under the direction of the same laboratory supervisor.

Definitions of VZV Infection

For “baseline serologies,” we used the hyperacute and acute blood samples, while “convalescent serologies” were based on the convalescent sample or chronic sample if no convalescent sample was available. A pediatric virologist (C.G.) interpreted the serologic results and classified the exposure to VZV on the basis of published literature.^{18–20} We defined serologic evidence of prior exposure (infection or vaccination) as baseline IgG titers >0.1 absorbance units; low-level IgG titers (>0.1 and <1.1) were consistent with prior exposure and no recent infection (reactivation). Serological evidence of recent infection (≈ 1 –6 weeks prior) at the time of stroke (or control enrollment) was defined as a baseline IgM titer ≥ 1.1 (highest titer used if 2 baseline samples). Recent infection with baseline IgG ≤ 0.1 indicated primary infection, while recent infection with baseline IgG >0.1 indicated reactivation. Baseline IgG titers ≥ 1.1 provided additional evidence of recent reactivation. Serological evidence of poststroke reactivation (ie, VZV reactivation triggered by poststroke

immunodepression) was defined as a baseline IgG >0.1 and <1.1 , baseline IgM titer <1.1 , and either a 4-fold rise in IgG titers (baseline to convalescent) or a convalescent IgM titer ≥ 1.1 .

Data Analysis

Baseline characteristics of patients with versus without recent VZV reactivation were compared using Wilcoxon rank-sum tests for continuous variables and χ^2 tests (or Fisher's exact, when appropriate) for categorical variables. All analyses were conducted using Stata version 17.0 (StataCorp, College Station, TX) with α set at 0.05. The P values are 2-sided. We completed the Strengthening the Reporting of Observational Studies in Epidemiology checklist for observational studies.

RESULTS

We enrolled 205 patients with spontaneous arteriopathic, cardioembolic, or idiopathic AIS: 188 in the United States, 15 in Canada, and 2 in Australia. Patients were 45% female and racially and ethnically diverse with a median age at stroke ictus of 11.6 (interquartile range [IQR], 5.5–15.6) years (Table 1). Upon central classification, the stroke types were 75 (37%) definite arteriopathy, 78 (38%) possible arteriopathy, 24 (12%) cardioembolic, and 38 (14%) idiopathic. The majority of infarcts were unilateral and affecting the anterior circulation (Table 1).

Past VZV Exposure (Infection or Vaccination)

Of the 205 patients, 198 (97%) had serological evidence of prior VZV exposure (IgG >0.1). Parents reported remote chickenpox in only 3 patients (8.4, 10.6, and 11.7 years before the stroke) and recalled prior VZV vaccination in 160 (78%). The median time from vaccination to stroke was 6.3 (IQR, 2.9–10.8; range, 0.12–17.1) years. Age at the most recent VZV vaccination was a median of 4.3 (IQR, 1.6–5.3) years.

Recent VZV Reactivation

Positive baseline IgM titers (≥ 1.1) were seen in 20 of 205 patients (9.8%; 95% CI, 6.1%–14.7%). All 20 patients had positive baseline IgG titers (>0.1) indicating past VZV exposure; hence, they had serological evidence of recent VZV reactivation (as opposed to primary infection). None had a recent vesicular rash to suggest cutaneous VZV infection (ie, shingles). Because IgG antibodies also rise with reactivation, elevated baseline IgG titers (≥ 1.1) provided additional evidence of recent reactivation. Among the 20 IgM-positive patients, the median baseline IgG titer was 1.87 (IQR, 0.24–3.31) absorbance units. Half of the patients had highly elevated

baseline IgG titers: IgG titers >2.0 in 10 patients (50%) and titers >3.0 in 6 patients (30%).

Among the 20 patients with recent VZV reactivation, parents recalled prior VZV vaccination in 16 and chickenpox in 1 (11.7 years prior). (The parents of 3 patients did not recall any VZV exposure.) The median time from vaccination to stroke was 6.1 (IQR, 2.9–10.7) years for these 16 patients (Figure), similar to the median of 6.3 years for the full cohort. Compared with those without recent VZV reactivation, the 20 with VZV reactivation had similar demographics, infectious histories, stroke pathogenesis, and stroke characteristics, except for smaller infarct volumes ($P=0.03$) (Table 1).

Stroke Type

Of the 32 patients with definite FCA in the VIPS II cohort, 4 (12.5%) had recent VZV reactivation, compared with none of the patients with arterial dissection ($n=10$) or moyamoya ($n=16$), and only 1 of the 13 patients with definite arteriopathy that could not be further classified. However, evidence of recent VZV reactivation was not specific to FCA, but rather observed in each of the other stroke types: cardioembolic (4/24 [16.7%]), idiopathic (3/28 [10.7%]), and possible arteriopathy (7/78 [9.0%]).

VZV Reactivation After Stroke

Of the 74 patients with convalescent serum samples, 12 (16.2% [95% CI, 9%–27%]) had serologic evidence of VZV reactivation *after* the stroke: One had convalescent IgM titers ≥ 1.1 , 9 had rising IgG titers, and 2 had both. All were asymptomatic.

Control Data

Sites enrolled 100 well controls; 95 controls with a median age of 11.8 (IQR, 6.8–15.3) years had sufficient blood samples for VZV serologies. Control age and sex were similar to that of patients with AIS, but controls were more likely to be of mixed or other race and had higher socioeconomic status (Table S1). All controls had serological evidence of prior VZV exposure (IgG >0.1). Parents reported remote chickenpox in 5 controls (5.3%) at a median of 11.8 (IQR, 8.3–14.4) years before enrollment, and prior VZV vaccination in 83 controls (87%) a median of 7.2 (2.8–10.5) years before enrollment. Positive IgM titers (≥ 1.1) were seen in 3 controls (3.1% [95% CI, 0.66%–8.9%]) aged 11.0, 13.2, and 13.8 years. All 3 had parental report of VZV vaccination (6 years prior, unknown timing, and 12 years prior, respectively); none had a history of chickenpox. None had highly elevated IgG titers (which would have supported recent reactivation); their IgG titers were 0.13, 0.43, and 1.94. In all 3, the VZV reactivation was asymptomatic (confirmed on parental interview).

Table 1. Characteristics of the 205 Cases of Childhood Arterial Ischemic Stroke Enrolled in the VIPS II Study, Stratified by Serological Evidence of Recent VZV Reactivation at the Time of the Stroke

| Characteristic | All cases (N=205) | | | Recent VZV (N=20) | | | No Recent VZV (N=185) | | | P value |
|------------------------------------|-------------------|-----|------------|-------------------|----|------------|-----------------------|-----|------------|---------|
| | n | N | (%) | n | N | (%) | n | N | (%) | |
| Demographics | | | | | | | | | | |
| Age, y, median (IQR) | 11.6 | 205 | (5.5–15.6) | 12.2 | 20 | (6.3–16.8) | 11.6 | 185 | (5.3–15.4) | 0.46 |
| Sex | | | | | | | | | | 0.15 |
| Female | 92 | 205 | (44.9) | 12 | 20 | (60.0) | 80 | 185 | (43.2) | |
| Male | 113 | 205 | (55.1) | 8 | 20 | (40.0) | 105 | 185 | (56.8) | |
| Race or ethnicity | | | | | | | | | | 0.08 |
| White, non-Hispanic | 111 | 205 | (54.1) | 6 | 20 | (30.0) | 105 | 185 | (56.8) | |
| Black, non-Hispanic | 25 | 205 | (12.2) | 2 | 20 | (10.0) | 23 | 185 | (12.4) | |
| Asian | 15 | 205 | (7.3) | 4 | 20 | (20.0) | 11 | 185 | (5.9) | |
| Hispanic | 44 | 205 | (21.5) | 7 | 20 | (35.0) | 37 | 185 | (20.0) | |
| Native American/First Nations | 1 | 205 | (0.5) | 0 | 20 | (0.0) | 1 | 185 | (0.5) | |
| Mixed or other | 8 | 205 | (3.9) | 1 | 20 | (5.0) | 7 | 185 | (3.8) | |
| Unknown | 1 | 205 | (0.5) | 0 | 20 | (0.0) | 1 | 185 | (0.5) | |
| Socioeconomic status | | | | | | | | | | |
| Residence | | | | | | | | | | 0.32 |
| Urban | 39 | 204 | (19.1) | 4 | 20 | (20.0) | 35 | 184 | (19.0) | |
| Suburban | 116 | 204 | (56.9) | 14 | 20 | (70.0) | 102 | 184 | (55.4) | |
| Rural | 49 | 204 | (24.0) | 2 | 20 | (10.0) | 47 | 184 | (25.5) | |
| Household income (in US dollars) | | | | | | | | | | 0.19 |
| <\$10000 | 13 | 205 | (6.3) | 1 | 20 | (5.0) | 12 | 185 | (6.5) | |
| \$10000–\$30000 | 24 | 205 | (11.7) | 3 | 20 | (15.0) | 21 | 185 | (11.4) | |
| \$31000–\$50000 | 26 | 205 | (12.7) | 6 | 20 | (30.0) | 20 | 185 | (10.8) | |
| \$50000–\$100000 | 45 | 205 | (22.0) | 2 | 20 | (10.0) | 43 | 185 | (23.2) | |
| >\$100000 | 59 | 205 | (28.8) | 6 | 20 | (30.0) | 53 | 185 | (28.6) | |
| Maternal education, highest level | | | | | | | | | | 0.17 |
| Less than high school | 15 | 205 | (7.3) | 2 | 20 | (10.0) | 13 | 185 | (7.0) | |
| High school graduate | 46 | 205 | (22.4) | 9 | 20 | (45.0) | 37 | 185 | (20.0) | |
| Some college education | 60 | 205 | (29.3) | 4 | 20 | (20.0) | 56 | 185 | (30.3) | |
| Bachelor's degree or equivalent | 40 | 205 | (19.5) | 4 | 20 | (20.0) | 36 | 185 | (19.5) | |
| Some graduate education | 8 | 205 | (3.9) | 0 | 20 | (0.0) | 8 | 185 | (4.3) | |
| Graduate degree | 33 | 205 | (16.1) | 1 | 20 | (5.0) | 32 | 185 | (17.3) | |
| Infectious history | | | | | | | | | | 0.46 |
| Chickenpox (ever) | 3 | 205 | (1.5) | 1 | 20 | (5.0) | 2 | 185 | (1.1) | |
| VZV vaccination (ever) | 160 | 204 | (78.4) | 16 | 20 | (80.0) | 144 | 185 | (77.8) | |
| Any clinical infection | | | | | | | | | | |
| Prior 4 wks | 49 | 205 | (23.9) | 3 | 20 | (15.0) | 46 | 185 | (24.9) | 0.42 |
| Prior 6 mo | 70 | 204 | (34.3) | 5 | 20 | (25.0) | 65 | 185 | (35.1) | 0.36 |
| Occurred during COVID-19 pandemic* | 100 | 205 | (48.8) | 10 | 20 | (50.0) | 90 | 185 | (48.6) | 0.91 |
| Stroke pathogenesis | | | | | | | | | | |
| Idiopathic | 28 | 205 | (13.7) | 3 | 20 | (15.0) | 25 | 185 | (13.5) | 0.59 |
| Cardioembolic | 24 | 205 | (11.7) | 4 | 20 | (20.0) | 20 | 185 | (10.8) | |
| Congenital heart disease | 16 | 205 | (7.8) | 3 | 20 | (15.0) | 13 | 185 | (7.0) | |
| Endocarditis | 2 | 205 | (1.0) | 0 | 20 | | 2 | 185 | (1.1) | |
| Other heart disease | 6 | 205 | (2.9) | 1 | 20 | (5.0) | 5 | 185 | (2.7) | |
| Possible arteriopathy | 78 | 205 | (38.0) | 7 | 20 | (35.0) | 71 | 185 | (38.4) | |

(Continued)

Table 1. Continued

| Characteristic | All cases (N=205) | | | Recent VZV (N=20) | | | No Recent VZV (N=185) | | | P value |
|---------------------------------|-------------------|-----|-------------|-------------------|----|-------------|-----------------------|-----|-------------|-------------------|
| | n | N | (%) | n | N | (%) | n | N | (%) | |
| Definite arteriopathy | 75 | 205 | (36.6) | 6 | 20 | (30.0) | 69 | 185 | (37.3) | 0.19 |
| FCA | 32 | 75 | (42.7) | 4 | 6 | (66.7) | 28 | 69 | (40.6) | |
| Dissection [†] | 10 | 75 | (13.3) | 0 | 6 | (0.0) | 10 | 69 | (14.5) | |
| Moyamoya | 16 | 75 | (21.3) | 0 | 6 | (0.0) | 16 | 69 | (23.2) | |
| Secondary vasculitis | 3 | 75 | (4.0) | 1 | 6 | (16.7) | 2 | 69 | (2.9) | |
| Other [‡] | 14 | 75 | (18.7) | 1 | 6 | (16.7) | 13 | 69 | (18.8) | |
| Stroke characteristics | | | | | | | | | | |
| Infarct volume, cm ³ | 15.3 | 205 | (1.72–5.32) | 4.10 | 20 | (1.72–12.2) | 17.0 | 185 | (1.72–54.7) | 0.03 [§] |
| Infarct volume/brain volume, % | 1.20 | 205 | (0.2–5.3) | 0.40 | 20 | (0.2–1.4) | 1.40 | 185 | (0.2–5.7) | 0.15 |
| Infarct location | | | | | | | | | | 0.41 |
| Anterior circulation | 141 | 205 | (68.8) | 17 | 20 | (85.0) | 124 | 185 | (67.0) | |
| Posterior circulation | 46 | 205 | (22.4) | 3 | 20 | (15.0) | 43 | 185 | (23.2) | |
| Both | 14 | 205 | (6.8) | 0 | 20 | (0.0) | 14 | 185 | (7.6) | |
| Infarct laterality | | | | | | | | | | 0.75 |
| Unilateral | 173 | 205 | (84.4) | 18 | 20 | (90.0) | 155 | 185 | (83.8) | |
| Bilateral | 32 | 205 | (15.6) | 2 | 20 | (10.0) | 30 | 185 | (16.2) | |

FCA indicates focal cerebral arteriopathy; IQR, interquartile range; VIPS, Vascular Effects of Infection in Pediatric Stroke; and VZV, varicella zoster virus.

*Strokes that occurred from January 2020 through the end of study, January 2022.

[†]Intracranial dissections involving the anterior circulation were categorized as FCA.

[‡]Includes primary vasculitis (3), vasospasm (1), other (4), unknown (6).

[§]P-value for comparison of infarct volumes calculated using Wilcoxon Rank Sum test.

DISCUSSION

In the VIPS II cohort of 205 children with spontaneous AIS, the majority were vaccinated against VZV, and a history of chickenpox was rare, yet almost 1 in 10 had evidence of recent subclinical VZV reactivation at the

time of their stroke. Also contrary to our expectations, recent VZV reactivation was *not* more common in children with arteriopathic stroke compared with cardioembolic or idiopathic stroke. However, among patients with definite arteriopathy, VZV reactivation was seen in FCA but not cervical dissection or moyamoya.

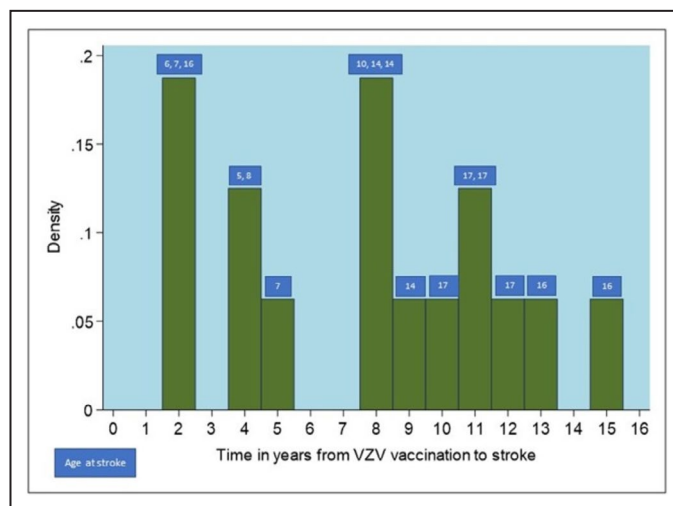


Figure. Distribution of time in years from the most recent VZV vaccination to stroke ictus among the 16 patients with stroke with serologic evidence of recent VZV reactivation at baseline and prior VZV vaccination.

Boxes above each bar show the age at stroke in years for the patients represented in that bar. VZV indicates varicella zoster virus.

Table 2. Comparison of VZV Results in the VIPS I Versus the VIPS II Study

| Study | Study years | Cases, N | VZV IgM positive, n | VZV IgM positive, % | Clinical VZV | Vaccinated, % |
|---------|-------------|----------|---------------------|---------------------|--------------|---------------|
| VIPS I | 2010–2014 | 326 | 37 | 11.3 | 0 | 58 |
| VIPS II | 2016–2022 | 205 | 20 | 9.8 | 0 | 78 |

VIPS indicates Vascular Effects of Infection in Pediatric Stroke; and VZV, varicella zoster virus.

After primary VZV infection, which includes viremia and skin involvement (the characteristic vesicular rash of chickenpox), the adaptive immune system does not succeed in eradicating the virus.²¹ Rather, the virus enters sensory nerves and travels retrograde to the sensory ganglia (dorsal root and trigeminal nerve ganglia), where it becomes latent. The latent period is dynamic: the endogenous latent virus is thought to intermittently reactivate, triggering transient asymptomatic rises in VZV IgM antibodies, and repeat exposure to exogenous virus can also lead to elevated VZV antibody titers.^{21–23} During periods of reduced immune function, latent VZV can reactivate and cause secondary infection, called zoster.²⁴ Zoster with skin involvement is called shingles.

In the prevaccination era, multiple reports described a post-varicella arteriopathy (ie, FCA) in previously healthy children with AIS following wild-type primary VZV infection (chickenpox).^{10,25,26} Rare autopsy studies revealed VZV particles and a lymphocytic infiltration in the arterial wall consistent with a focal angiitis.^{27,28} These reports and a 2001 epidemiologic study from Canada provided evidence for a delayed period of increased stroke risk occurring weeks to months after chickenpox.²⁹ The virus travels within nerves at a rate of ≈ 10 cm/day, so the time delay from varicella to stroke is not solely explained by the time for the virus to transit from the trigeminal ganglion to an artery.³⁰ Rather, these patients likely had reactivation of wild-type VZV within months of the primary infection.

We enrolled the VIPS II cohort after VZV vaccination in young children became routine in North America and Australia. The United States approved the vaccine in 1995, with early policies recommending a single dose at age 12 to 18 months,³¹ and the 2007 update calling for the current 2-dose schedule at ages 12 to 15 months and 4 to 6 years.³¹ Australia started a single-dose vaccination program in 2005, and Canadian provinces did the same between 2000 and 2007.^{32,33} In the VIPS I case–control study, VZV vaccination significantly lowered risk of childhood AIS.³ In North America and Australia, where VZV vaccination rates are high, exposure to children with chickenpox is now rare. As anticipated, the VIPS II cohort was better vaccinated than VIPS I, with rare reports of prior chickenpox (Table 2). Despite this, the prevalence of recent VZV reactivation (elevated IgM antibodies at stroke baseline) was similar in VIPS II (9.8%) and VIPS I (11.3%).

What could explain a persistent role for VZV in pediatric stroke pathogenesis in a vaccinated population? Vaccinated children can acquire a breakthrough wild-type varicella infection through exposure to adults with herpes zoster (shingles), which occurs annually in over 1 million US adults.^{34,35} We speculate that the VZV reactivation events in our stroke cohort represent asymptomatic breakthrough infections with wild-type VZV in previously vaccinated children with waning immunity. Indeed, the time interval from vaccination to stroke was generally prolonged a median of 6 years, much longer than the historic time interval (weeks to months) between chickenpox and stroke. We also identified 3 well control children with asymptomatic low-level VZV reactivation at the time of their enrollment, suggesting that asymptomatic reactivation events (possibly breakthrough wild-type infections) may be occurring at a low rate in the general vaccinated population of children. We further speculate that such events are benign in most children but act as viral triggers for stroke in others.

Based on the historical evidence of FCA after chickenpox (post-varicella arteriopathy), we hypothesized that VZV reactivation, when identified, would more commonly precede arteriopathic stroke, particularly FCA, than cardioembolic or idiopathic stroke. Among the definite arteriopathy cases in the VIPS II cohort, recent VZV reactivation was indeed seen 12.5% of FCA patients and not at all in patients with the 2 other most common childhood arteriopathies (cervical dissection and moyamoya). However, we found that recent VZV reactivation was not specific to arteriopathic stroke, with a similar prevalence in cardioembolic and idiopathic stroke. One potential explanation is misclassification of FCA cases. Early vascular imaging may be normal in FCA and many VIPS II patients lacked the serial imaging often needed to diagnose FCA; this could lead to misclassification as idiopathic. However, we observed a similar prevalence of recent VZV reactivation in the patients with cardioembolic stroke (16.7%), less likely to be misclassified patients with FCA. Other neurotrophic pathogens have been linked to FCA,^{36,37} including SARS-CoV-2.³⁸ It is possible, in a population highly vaccinated against VZV, that VZV is now an uncommon cause of FCA.

It is also plausible that VZV reactivation triggers cardioembolic and idiopathic stroke. The mechanisms by which viruses are generally postulated to trigger

thromboembolic events are likely also relevant for VZV: Circulating inflammatory cytokines affect the coagulation system (“thromboinflammation”) and cardiac and arterial endothelium, favoring the formation of intracardiac or intraluminal thrombus.^{39,40} Indeed, evidence in adults implicates shingles (VZV reactivation with cutaneous manifestations) as a trigger for both ischemic stroke and myocardial infarction, possibly through thromboinflammation or transient VZV-induced antiphospholipid antibodies.^{5,6}

Our study has a number of limitations. Because we have no prestroke serum samples, some misclassification of the timing of VZV reactivation (preceding versus following the stroke) is possible. Our assumptions regarding the timing of antibody titer elevations are based on other published studies with their own limitations.^{18–20} Our serologies could not differentiate wild-type VZV virus from vaccine-type virus, which also develops latency in sensory ganglia⁴¹; rare reports describe vaccine-virus shingles and meningitis in both immunodeficient and immunocompetent children.^{24,42,43} We did not have CSF samples available for testing; however, prior studies have shown that many patients with wild-type VZV encephalitis do not have detectable VZV DNA in the CSF.⁴⁴ The lack of serial vascular imaging, or standardized timing of imaging, likely led to underdiagnosis of FCA. Of 75 patients with definite arteriopathy, 18% could not be further classified. Almost 40% of all patients had “possible arteriopathy,” meaning that they lacked sufficient imaging and clinical data to confirm or exclude an arteriopathy. This misclassification and our intentional selection of only spontaneous arteriopathic, cardioembolic, or idiopathic strokes biased our study toward having a higher proportion of patients with arteriopathy. In the International Pediatric Stroke Study, 34% of 2127 children with AIS were reported to have an arteriopathy.⁴⁵ The ongoing FOCAS (Focal Cerebral Arteriopathy Steroid) trial will address these imaging limitations by enrolling possible patients with FCA, performing serial imaging at standardized time intervals, and measuring VZV serologies in the same research laboratory as VIPS II (ClinicalTrials.gov identifier: NCT06040255).

Despite its limitations, the VIPS II study provides evidence that VZV continues to play a role in a subset of childhood AIS cases in the modern, postvaccination era. Just as shingles may trigger ischemic stroke and myocardial infarction in adults, asymptomatic VZV reactivation (perhaps after breakthrough infection with wild-type VZV) may be a trigger for AIS in children with waning immunity. Current antivirals like acyclovir are unlikely to have a role in stroke prevention because they suppress but do not eliminate the virus. Limited evidence suggests they did not improve FCA outcomes in Swiss children, who are not routinely vaccinated against VZV.⁹ Could additional doses of

the VZV vaccine in later childhood help protect against childhood AIS? A 2013 report described the effectiveness of the VZV vaccine in 7585 children at 14-year follow-up.⁴⁶ While long-term protection against chickenpox did not appear to wane, protection against shingles (ie, *symptomatic* VZV reactivation) did wane, with no apparent protection after age 5 years. The study did not perform antibody testing and therefore could not assess the incidence of *asymptomatic* VZV reactivation. Our VZV IgM positive stroke cases could be the “canary in the coal mine,” indicating that VZV reactivation without cutaneous manifestations not only occurs but can, very rarely, have negative sequelae. Further long-term studies of childhood VZV vaccines should include antibody studies; a better understanding of the clinical significance of asymptomatic VZV reactivation is needed to guide public health decisions.

APPENDIX

VIPS II Investigators (ordered by patient enrollment numbers): Michael Dowling (Departments of Pediatrics and Neurology, University of Texas Southwestern Medical Center, Dallas, TX), Christine Fox (Departments of Neurology and Pediatrics, University of California San Francisco, San Francisco, CA), Division of Neurology, The Hospital for Sick Children, Toronto, ON, Canada: [Nomazulu Dlamini, Gabrielle DeVeber], Marcela Torres (Departments of Hematology and Oncology, Cook Children’s Hospital, Fort Worth, TX), Jenny Wilson (Department of Pediatrics, Oregon Health State University, Portland, OR), Sarah Lee (Department of Neurology, Stanford University, Palo Alto, CA), Dana Cummings (Division of Child Neurology, UPMC Children’s Hospital of Pittsburgh, Pittsburgh, PA), Department of Neurology, Nationwide Children’s Hospital, Columbus, OH: [Warren Lo, Melissa Chung], Lori Jordan (Department of Neurology, Vanderbilt University Medical Center, Nashville, TN), Departments of Pediatrics and Neurology, Children’s Hospital Colorado, Aurora, CO [Timothy Bernard, Megan Barry], Division of Neurology, Children’s Hospital of Philadelphia, Pennsylvania, PA [Rebecca Ichord, Lauren Beslow], Department of Pediatrics, Children’s Mercy Kansas City, MO [Mukta Sharma, Shannon Carpenter], Catherine Amlie-Lefond (Division of Neurology, Seattle Children’s Hospital, Seattle, WA), Neil Friedman (Department of Neurology, Phoenix Children’s Hospital, Phoenix, AZ), John Michael Taylor (Department of Pediatrics, University of Cincinnati, Cincinnati, OH), Department of Neurology, Boston Children’s Hospital, Boston, MA [Michael Rivkin, Laura Lehman], Paola Pergami (Department of Neurology, Children’s National Hospital, Washington, DC), Andrea Pardo (Department of Neurology, Lurie Children’s Hospital of Chicago, Chicago, IL), Tracee Ridley-Pryor

(Pediatric Neurology Research, Le Bonheur Children's Hospital, Memphis, TN), Department of Neurology, Johns Hopkins University, Baltimore, MD [Ryan Felling, Lisa Sun], Mark Mackay (Department of Pediatrics, Royal Children's Hospital, Melbourne, Australia), Adam Kirton (Department of Pediatrics, University of Calgary, Calgary, AB, Canada).

ARTICLE INFORMATION

Received October 15, 2024; accepted December 20, 2024.

Affiliations

Department of Neurology (H.J.F., N.K.H.), Pediatrics (H.J.F.) and Biostatistics and Epidemiology (N.K.H.), University of California San Francisco, San Francisco, CA; Department of Radiology, MD Anderson Cancer Center, Houston, TX (M.W.); Division of Neurology, Hospital for Sick Children, Toronto, Canada (N.D.); Department of Neurology, Seattle Children's Hospital, Seattle, WA (C.A.); Department of Pediatrics and Neurology, University of Texas Southwestern Medical Center, Dallas, TX (M.M.D.); Department of Pediatrics, Division of Pediatric Neurology, Vanderbilt University Medical Center, Nashville, TN (L.C.J.); Department of Neurology, Phoenix Children's, Phoenix, AZ (N.R.F.); Department of Neurology, Vagelos College of Physicians and Surgeons, and Department of Epidemiology, Mailman School of Public Health, Columbia University, New York, NY (M.S.E.); and Department of Pediatrics, Division of Infectious Diseases/Virology, University of Iowa, Iowa City, IA (C.G.).

Acknowledgments

The authors acknowledge the important contributions of the research coordinators at VIPS II sites; the VIPS II project managers, Maria Kuchherzki and Kathleen Colao; the virology laboratory manager, Wallen Jackson; and the patients and their families. Statistical analysis was performed by Nancy Hills, PhD (academic affiliation only; University of California San Francisco).

Sources of Funding

This work was supported by National Institutes of Health R01 NS104094 (Fullerton) and Marc and Lynne Benioff philanthropic gift. All authors receive National Institutes of Health funding for this project.

Disclosures

None.

Supplemental Material

Table S1

REFERENCES

- Agrawal N, Johnston SC, Wu YW, Sidney S, Fullerton HJ. Imaging data reveal a higher pediatric stroke incidence than prior US estimates. *Stroke*. 2009;40:3415–3421. doi: [10.1161/STROKEAHA.109.564633](https://doi.org/10.1161/STROKEAHA.109.564633)
- Kleindorfer D, Khoury J, Kissela B, Alwell K, Woo D, Miller R, Schneider A, Moomaw C, Broderick JP. Temporal trends in the incidence and case fatality of stroke in children and adolescents. *J Child Neurol*. 2006;21:415–418. doi: [10.1177/08830738060210050301](https://doi.org/10.1177/08830738060210050301)
- Fullerton HJ, Hills NK, Elkind MS, Dowling MM, Wintermark M, Glaser CA, Tan M, Rivkin MJ, Titomanlio L, Barkovich AJ, et al. Infection, vaccination, and childhood arterial ischemic stroke: results of the VIPS study. *Neurology*. 2015;85:1459–1466.
- Jung JM, Gruber A, Heseltine P, Rajamani K, Ameriso SF, Fisher MJ. New directions in infection-associated ischemic stroke. *J Clin Neurol*. 2024;20:140–152. doi: [10.3988/jcn.2023.0056](https://doi.org/10.3988/jcn.2023.0056)
- Wu PH, Chuang YS, Lin YT. Does herpes zoster increase the risk of stroke and myocardial infarction? A comprehensive review. *J Clin Med*. 2019;8:547. doi: [10.3390/jcm8040547](https://doi.org/10.3390/jcm8040547)
- Seo HM, Cha MJ, Han JH, Han K, Park SH, Bang CH, Lee JH, Lee JY, Choi EK, Park YM. Reciprocal relationship between herpes zoster and cardiovascular diseases: a nationwide population-based case-control study in Korea. *J Dermatol*. 2018;45:1312–1318. doi: [10.1111/1346-8138.14597](https://doi.org/10.1111/1346-8138.14597)
- Elkind MS, Hills NK, Glaser CA, Lo WD, Amlie-Lefond C, Dlamini N, Kneen R, Hod EA, Wintermark M, deVeber G, et al. Herpesvirus infections and childhood arterial ischemic stroke: results of the VIPS study. *Circulation*. 2016;133:732–741. doi: [10.1161/CIRCULATIONAHA.115.018595](https://doi.org/10.1161/CIRCULATIONAHA.115.018595)
- Fullerton HJ, Stence N, Hills NK, Jiang B, Amlie-Lefond C, Bernard TJ, Friedman NR, Ichord R, Mackay MT, Rafay MF, et al. Focal cerebral arteriopathy of childhood: novel severity score and natural history. *Stroke*. 2018;49:2590–2596. doi: [10.1161/STROKEAHA.118.021556](https://doi.org/10.1161/STROKEAHA.118.021556)
- Steinlin M, Bigi S, Stojanovski B, Gajera J, Regenyi M, El-Koussy M, Mackay MT. Focal cerebral arteriopathy: do steroids improve outcome? *Stroke*. 2017;48:2375–2382. doi: [10.1161/STROKEAHA.117.016818](https://doi.org/10.1161/STROKEAHA.117.016818)
- Lanther S, Armstrong D, Domi T, deVeber G. Post-varicella arteriopathy of childhood: natural history of vascular stenosis. *Neurology*. 2005;64:660–663. doi: [10.1212/01.WNL.0000151851.66154.27](https://doi.org/10.1212/01.WNL.0000151851.66154.27)
- Grose C, Shaban A, Fullerton HJ. Common features between stroke following varicella in children and stroke following herpes zoster in adults: varicella-zoster virus in trigeminal ganglion. *Curr Top Microbiol Immunol*. 2023;438:247–272.
- Amlie-Lefond C, Gilden D. Varicella zoster virus: a common cause of stroke in children and adults. *J Stroke Cerebrovasc Dis*. 2016;25:1561–1569. doi: [10.1016/j.jstrokecerebrovasdis.2016.03.052](https://doi.org/10.1016/j.jstrokecerebrovasdis.2016.03.052)
- Wintermark M, Hills NK, DeVeber GA, Barkovich AJ, Bernard TJ, Friedman NR, Mackay MT, Kirton A, Zhu G, Leiva-Salinas C, et al. Clinical and imaging characteristics of arteriopathy subtypes in children with arterial ischemic stroke: results of the VIPS study. *AJNR Am J Neuroradiol*. 2017;38:2172–2179.
- Faura J, Bustamante A, Miro-Mur F, Montaner J. Stroke-induced immunosuppression: implications for the prevention and prediction of post-stroke infections. *J Neuroinflammation*. 2021;18:127. doi: [10.1186/s12974-021-02177-0](https://doi.org/10.1186/s12974-021-02177-0)
- Wintermark M, Hills NK, deVeber GA, Barkovich AJ, Elkind MS, Sear K, Zhu G, Leiva-Salinas C, Hou Q, Dowling MM, et al. Arteriopathy diagnosis in childhood arterial ischemic stroke: results of the vascular effects of infection in pediatric stroke study. *Stroke*. 2014;45:3597–3605.
- Giller RH, Winistorfer S, Grose C. Cellular and humoral immunity to varicella zoster virus glycoproteins in immune and susceptible human subjects. *J Infect Dis*. 1989;160:919–928. doi: [10.1093/infdis/160.6.919](https://doi.org/10.1093/infdis/160.6.919)
- Olson JK, Grose C. Endocytosis and recycling of varicella-zoster virus fc receptor glycoprotein Gc: internalization mediated by a yxxl motif in the cytoplasmic tail. *J Virol*. 1997;71:4042–4054. doi: [10.1128/jvi.71.5.4042-4054.1997](https://doi.org/10.1128/jvi.71.5.4042-4054.1997)
- Min SW, Kim YS, Nahm FS, Yoo DH, Choi E, Lee PB, Choo H, Park ZY, Yang CS. The positive duration of varicella zoster immunoglobulin m antibody test in herpes zoster. *Medicine (Baltimore)*. 2016;95:e4616.
- Kangro HO, Ward A, Argent S, Heath RB, Cradock-Watson JE, Ridehalgh MK. Detection of specific IgM in varicella and herpes zoster by antibody-capture radioimmunoassay. *Epidemiol Infect*. 1988;101:187–195.
- Cradock-Watson JE, Ridehalgh MK, Bourne MS. Specific immunoglobulin responses after varicella and herpes zoster. *J Hyg*. 1979;82:319–336.
- Weller TH. Varicella and herpes zoster: changing concepts of the natural history, control, and importance of a not-so-benign virus. *N Engl J Med*. 1983;309:1362–1368.
- Brunell PA, Gershon AA, Uduman SA, Steinberg S. Varicella-zoster immunoglobulins during varicella, latency, and zoster. *J Infect Dis*. 1975;132:49–54. doi: [10.1093/infdis/132.1.49](https://doi.org/10.1093/infdis/132.1.49)
- Gershon A, Steinberg S, Borkowsky W, Lennette D, Lennette E. Subclinical zoster: identification by serum igm to varicella-zoster virus. *Pediatr Res*. 1981;15:610.
- Hardy I, Gershon AA, Steinberg SP, LaRussa P; Varicella vaccine collaborative study group. The incidence of zoster after immunization with live attenuated varicella vaccine: a study in children with leukemia. *N Engl J Med*. 1991;325:1545–1550.
- Alehan FK, Boyvat F, Baskin E, Derbent M, Ozbek N. Focal cerebral vasculitis and stroke after chickenpox. *Eur J Paediatr Neurol*. 2002;6:331–333. doi: [10.1053/ejpn.2002.0622](https://doi.org/10.1053/ejpn.2002.0622)
- Caekebeke JF, Peters AC, Vandvik B, Brouwer OF, de Bakker HM. Cerebral vasculopathy associated with primary varicella infection. *Arch Neurol*. 1990;47:1033–1035.

27. Hayman M, Henderson G, Poskitt KJ, Connolly MB. Postvaricella angiopathy: report of a case with pathologic correlation. *Pediatr Neurol*. 2001;24:387–389. doi: [10.1016/S0887-8994\(01\)00272-7](https://doi.org/10.1016/S0887-8994(01)00272-7)
28. Berger TM, Caduff JH, Gebbers JO. Fatal varicella-zoster virus antigen-positive giant cell arteritis of the central nervous system. *Pediatr Infect Dis J*. 2000;19:653–656. doi: [10.1097/00006454-200007000-00015](https://doi.org/10.1097/00006454-200007000-00015)
29. Askalan R, Laughlin S, Mayank S, Chan A, MacGregor D, Andrew M, Curtis R, Meaney B, deVeber G. Chickenpox and stroke in childhood: a study of frequency and causation. *Stroke*. 2001;32:1257–1262.
30. Tannous R, Grose C. Calculation of the anterograde velocity of varicella-zoster virions in a human sciatic nerve during shingles. *J Infect Dis*. 2011;203:324–326. doi: [10.1093/infdis/jiq068](https://doi.org/10.1093/infdis/jiq068)
31. Marin M, Seward JF, Gershon AA. 25 years of varicella vaccination in the United States. *J Infect Dis*. 2022;226:S375–S379. doi: [10.1093/infdis/jiac251](https://doi.org/10.1093/infdis/jiac251)
32. Shrestha AC, Field E, Rajmohan M, Lambert SB. Assessing the impact of chickenpox and shingles vaccination using intermittent enhanced surveillance in Queensland, Australia. *Vaccine*. 2023;41:7539–7547. doi: [10.1016/j.vaccine.2023.11.015](https://doi.org/10.1016/j.vaccine.2023.11.015)
33. Varicella (chickenpox) vaccines: Canadian immunization guide. 2024.
34. Viner K, Perella D, Lopez A, Bialek S, Newbern C, Pierre R, Spells N, Watson B. Transmission of varicella zoster virus from individuals with herpes zoster or varicella in school and day care settings. *J Infect Dis*. 2012;205:1336–1341. doi: [10.1093/infdis/jis207](https://doi.org/10.1093/infdis/jis207)
35. Bloch KC, Johnson JG. Varicella zoster virus transmission in the vaccine era: unmasking the role of herpes zoster. *J Infect Dis*. 2012;205:1331–1333. doi: [10.1093/infdis/jis214](https://doi.org/10.1093/infdis/jis214)
36. Ribai P, Liesnard C, Rodesch G, Giurgea S, Verheulpen D, David P, Van Bogaert P. Transient cerebral arteriopathy in infancy associated with enteroviral infection. *Eur J Paediatr Neurol*. 2003;7:73–75. doi: [10.1016/S1090-3798\(03\)00016-3](https://doi.org/10.1016/S1090-3798(03)00016-3)
37. Sasidharan S, Krishnasree KS. Transient focal cerebral arteriopathy of childhood following dengue fever. *J Postgrad Med*. 2020;66:172–173. doi: [10.4103/jpgm.JPGM_524_19](https://doi.org/10.4103/jpgm.JPGM_524_19)
38. Gulko E, Overby P, Ali S, Mehta H, Al-Mufti F, Gomes W. Vessel wall enhancement and focal cerebral arteriopathy in a pediatric patient with acute infarct and COVID-19 infection. *AJNR Am J Neuroradiol*. 2020;41:2348–2350. doi: [10.3174/ajnr.A6778](https://doi.org/10.3174/ajnr.A6778)
39. South K, McCulloch L, McColl BW, Elkind MS, Allan SM, Smith CJ. Preceding infection and risk of stroke: an old concept revived by the COVID-19 pandemic. *Int J Stroke*. 2020;15:722–732.
40. Elkind MSV, Boehme AK, Smith CJ, Meisel A, Buckwalter MS. Infection as a stroke risk factor and determinant of outcome after stroke. *Stroke*. 2020;51:3156–3168. doi: [10.1161/STROKEAHA.120.030429](https://doi.org/10.1161/STROKEAHA.120.030429)
41. Grose C. Pathogenesis of infection with varicella vaccine. *Infect Dis Clin N Am*. 1996;10:489–505. doi: [10.1016/S0891-5520\(05\)70310-X](https://doi.org/10.1016/S0891-5520(05)70310-X)
42. Detty SQ, Peebles JK, Guerrieri JM, Seroogy CM, Struck MC, Arkin LM, Henderson SL. Vaccine-strain herpes zoster ophthalmicus in a 14-month-old boy prompting an immunodeficiency workup: case report and review of vaccine-strain herpes zoster. *Pediatr Infect Dis J*. 2020;39:e25–e27. doi: [10.1097/INF.0000000000002545](https://doi.org/10.1097/INF.0000000000002545)
43. Heusel EH, Grose C. Twelve children with varicella vaccine meningitis: neuropathogenesis of reactivated live attenuated varicella vaccine virus. *Viruses*. 2020;12:1078. doi: [10.3390/v12101078](https://doi.org/10.3390/v12101078)
44. Nagel MA, Forghani B, Mahalingam R, Wellish MC, Cohrs RJ, Russman AN, Katzan I, Lin R, Gardner CJ, Gilden DH. The value of detecting anti-VZV IgG antibody in CSF to diagnose VZV vasculopathy. *Neurology*. 2007;68:1069–1073. doi: [10.1212/01.wnl.0000258549.13334.16](https://doi.org/10.1212/01.wnl.0000258549.13334.16)
45. Rafay MF, Shapiro KA, Surmava AM, deVeber GA, Kirton A, Fullerton HJ, Amlie-Lefond C, Weschke B, Dlamini N, Carpenter JL, et al. Spectrum of cerebral arteriopathies in children with arterial ischemic stroke. *Neurology*. 2020;94:e2479–e2490. doi: [10.1212/WNL.0000000000009557](https://doi.org/10.1212/WNL.0000000000009557)
46. Baxter R, Ray P, Tran TN, Black S, Shinefield HR, Coplan PM, Lewis E, Fireman B, Saddier P. Long-term effectiveness of varicella vaccine: a 14-year, prospective cohort study. *Pediatrics*. 2013;131:e1389–e1396. doi: [10.1542/peds.2012-3303](https://doi.org/10.1542/peds.2012-3303)

Infection, vaccination, and childhood arterial ischemic stroke

Results of the VIPS study



Heather J. Fullerton, MD,
MAS
Nancy K. Hills, PhD
Mitchell S.V. Elkind,
MD, MS
Michael M. Dowling,
MD, PhD
Max Wintermark, MD
Carol A. Glaser, DVM,
MD
Marilyn Tan, MD
Michael J. Rivkin, MD
Luigi Titomanlio, MD,
PhD
A. James Barkovich, MD
Gabrielle A. deVeber,
MD, MSc
On behalf of the VIPS
Investigators

ABSTRACT

Objectives: Minor infection can trigger adult arterial ischemic stroke (AIS) and is common in childhood. We tested the hypotheses that infection transiently increases risk of AIS in children, regardless of stroke subtype, while vaccination against infection is protective.

Methods: The Vascular Effects of Infection in Pediatric Stroke study is an international case-control study that prospectively enrolled 355 centrally confirmed cases of AIS (29 days–18 years old) and 354 stroke-free controls. To determine prior exposure to infections and vaccines, we conducted parental interviews and chart review.

Results: Median (interquartile range) age was 7.6 years for cases and 9.3 for controls ($p = 0.44$). Infection in the week prior to stroke, or interview date for controls, was reported in 18% of cases, vs 3% of controls, conferring a 6.3-fold increased risk of AIS ($p < 0.0001$); upper respiratory infections were most common. Prevalence of preceding infection was similar across stroke subtypes: arteriopathic, cardioembolic, and idiopathic. Use of vasoactive cold medications was similarly low in both groups. Children with some/few/no routine vaccinations were at higher stroke risk than those receiving all or most (odds ratio [OR] 7.3, $p = 0.0002$). In an age-adjusted multivariate logistic regression model, independent risk factors for AIS included infection in the prior week (OR 6.3, $p < 0.0001$), undervaccination (OR 8.2, $p = 0.0004$), black race (compared to white; OR 1.9, $p = 0.009$), and rural residence (compared to urban; OR 3.0, $p = 0.0003$).

Conclusions: Infection may act as a trigger for childhood AIS, while routine vaccinations appear protective. Hence, efforts to reduce the spread of common infections might help prevent stroke in children. **Neurology® 2015;85:1459-1466**

Correspondence to
Dr. Fullerton:
Heather.Fullerton@ucsf.edu

GLOSSARY

AIS = arterial ischemic stroke; **CI** = confidence interval; **IQR** = interquartile range; **OR** = odds ratio; **PFO** = patent foramen ovale; **SES** = socioeconomic status; **VIPS** = Vascular Effects of Infection in Pediatric Stroke.

Ischemic stroke affects at least 2.4 per 100,000 US children every year.^{1,2} Historical impressions that children recover well from stroke have been contradicted by outcome studies that document a high rate of lifelong morbidity.^{3–5} A better understanding of the causes of childhood stroke is needed to develop strategies for prevention.

Major infections—bacterial meningitis, sepsis, endocarditis—have long been associated with arterial ischemic stroke (AIS) in children. Minor infections occur more frequently, and have been linked to AIS risk in adults.^{6–14} In a retrospective case-control study set in Northern California, we found that a medical encounter for minor infection transiently increased AIS risk 15-fold ($p < 0.0001$) over a 3-day period, and that this risk factor was present in 10% of childhood AIS cases.¹⁵ This suggests a potential opportunity for primary stroke prevention

Editorial, page 1438

Supplemental data
at Neurology.org

From the Departments of Neurology (H.J.F., N.K.H., A.J.B.), Pediatrics (H.J.F., C.A.G., A.J.B.), Biostatistics and Epidemiology (N.K.H.), and Radiology (A.J.B.), University of California San Francisco; the Departments of Neurology and Epidemiology (M.S.V.E.), Columbia University College of Physicians and Surgeons and Mailman School of Public Health, New York, NY; the Departments of Pediatrics and Neurology and Neurotherapeutics (M.M.D.), UT Southwestern Medical Center, Dallas, TX; the Department of Radiology (M.W.), Stanford University, Palo Alto, CA; the Division of Communicable Disease Control (C.A.G.), Center for Infectious Diseases, California Department of Public Health, Richmond; the Departments of Pediatrics and Neurosciences (M.T.), University of the Philippines–Philippine General Hospital, Manila, Philippines; the Departments of Neurology, Psychiatry, and Radiology (M.J.R.), Boston Children’s Hospital, MA; the Pediatric Emergency Department (L.T.), Robert Debré Hospital, Paris Diderot University, Paris, France; and the Department of Neurology (G.A.d.), Hospital for Sick Children, Toronto, Canada.

Coinvestigators are listed on the *Neurology*® Web site at Neurology.org.

Go to Neurology.org for full disclosures. Funding information and disclosures deemed relevant by the authors, if any, are provided at the end of the article.

Table 1 Characteristics of patients with childhood arterial ischemic stroke and age-matched controls, based on parental interview

| Characteristics | Cases (n = 355), n (%) | Controls (n = 354), n (%) | p Value |
|-----------------------------------|------------------------|---------------------------|----------------------|
| Demographics | | | |
| Age, y, median (IQR) | 7.6 (2.8–14.3) | 9.3 (4.4–13.3) | 0.44 |
| Male | 199 (56.1) | 195 (55.1) | 0.34 |
| Race | | | 0.24 |
| White | 230 (64.8) | 223 (63.0) | |
| Black | 39 (11.0) | 26 (7.3) | |
| East Asian | 9 (2.5) | 4 (1.1) | |
| Indian/South Asian | 26 (7.3) | 23 (6.5) | |
| Middle Eastern | 3 (0.8) | 4 (1.1) | |
| First Nations/Aboriginal | 4 (1.1) | 4 (1.1) | |
| Pacific Islander | 1 (0.3) | 2 (0.6) | |
| Mixed or other | 38 (10.7) | 62 (17.5) | |
| Unknown | 5 (1.4) | 6 (1.7) | |
| Ethnicity | | | 0.17 |
| Non-Hispanic | 289 (81.4) | 276 (78.0) | |
| Hispanic | 47 (13.2) | 45 (12.7) | |
| Mixed or other | 19 (5.4) | 33 (9.3) | |
| Country | | | 0.001 ^a |
| United States | 223 (62.8) | 188 (53.1) | |
| Canada | 60 (16.9) | 121 (34.2) | |
| Australia | 16 (4.5) | 3 (0.8) | |
| Philippines | 16 (4.5) | 12 (3.4) | |
| Chile | 14 (3.9) | 13 (3.7) | |
| United Kingdom | 11 (3.1) | 6 (1.7) | |
| France | 6 (1.7) | 3 (0.8) | |
| Serbia | 5 (1.4) | 4 (1.1) | |
| China | 4 (1.1) | 4 (1.1) | |
| Socioeconomic status | | | |
| Residence | | | <0.0001 ^a |
| Urban | 118 (33.2) | 184 (52.0) | |
| Suburban | 153 (43.1) | 126 (35.6) | |
| Rural | 82 (23.1) | 44 (12.4) | |
| Household income (in US dollars) | | | 0.001 ^a |
| <\$10,000 | 55 (15.5) | 30 (8.5) | |
| \$10,000–30,000 | 68 (19.2) | 66 (18.6) | |
| \$31,000–50,000 | 47 (13.2) | 53 (15.0) | |
| \$50,000–100,000 | 90 (25.4) | 83 (23.4) | |
| >100,000 | 64 (18.0) | 105 (29.7) | |
| Missing | 31 (8.7) | 17 (4.8) | |
| Maternal education, highest level | | | <0.0001 ^a |
| Less than high school | 43 (12.1) | 16 (4.5) | |
| High school graduate | 83 (23.4) | 58 (16.4) | |
| Some college education | 109 (30.7) | 110 (31.1) | |

Continued

through improved hygiene and vaccination, and potential avenues for secondary stroke prevention by expanding our understanding of stroke pathogenesis in children. The study was limited by its narrow geographic region, retrospective data, inability to measure infections not resulting in a medical encounter (or exposure to vasoactive cold medications), and poor characterization of stroke subtypes because imaging studies were not available for review.

We sought to further assess the association between infection and AIS, and test the hypothesis that vaccinations are protective, in a large, international case-control study of childhood AIS: the Vascular Effects of Infection in Pediatric Stroke (VIPS) study. We also sought to determine whether the association with infection varies by subtype: arteriopathic, cardioembolic, or idiopathic.

METHODS Setting and case enrollment. Between January 2010 and March 2014, VIPS prospectively enrolled cases of childhood AIS, and stroke-free controls, at 37 International Pediatric Stroke Study centers in 9 countries. Our target sample size (350 cases and 350 controls) was chosen to have >80% power to detect an association between recent infection and childhood AIS subtypes, with α set at 0.05. Ethics approvals were obtained at each site. Details of case ascertainment, confirmation, imaging review, laboratory analyses, and clinical data collection are published.^{16,17} Case inclusion criteria were age 29 days through 18 years at the time of AIS, brain MRI including cerebrovascular imaging, enrollment within 3 weeks of stroke ictus (a change from 2 weeks in the published methods), and consent/assent to study participation including blood collection. Local research staff abstracted data from medical records, interviewed parents/guardians, and mailed neuroimaging studies on CD to the imaging core at the University of California San Francisco.

Case confirmation and classification of stroke subtype. Cases were confirmed centrally by 2 investigators, with adjudication by a third, using pre-established clinical and imaging criteria for AIS.¹⁶ All cases were subjected to a rigorous process for classifying the presence and type of an arteriopathy.¹⁷ Cases with no arteriopathy were further classified as cardioembolic if there was a history of congenital or acquired heart disease, excluding isolated patent foramen ovale (PFO); presumed embolic with prothrombotic condition if the child had an acquired (e.g., sepsis) or genetic prothrombotic condition; other etiology if there was another established stroke cause or risk factor; and idiopathic if no stroke risk factors were identified. Children with only PFO or migraine were considered idiopathic. Cardioembolic strokes were further classified as procedure-related, if coincident with a cardiac procedure, or spontaneous.

Control enrollment. VIPS enrolled stroke-free controls aged 29 days through 18 years. Controls were selected to minimize bias either towards or against having a recent infection. There

Table 1 Continued

| Characteristics | Cases (n = 355), n (%) | Controls (n = 354), n (%) | p Value |
|---|---------------------------|------------------------------|---------|
| Bachelor's degree, or equivalent | 68 (19.2) | 89 (25.1) | |
| Some graduate education | 8 (2.3) | 15 (4.2) | |
| Graduate degree | 30 (8.5) | 61 (17.2) | |
| Missing | 14 (3.9) | 5 (1.4) | |
| No. of routine visits to a doctor's office, past 24 months, median (IQR) ^b | 2 (2-4) | 2 (2-4) | 0.06 |
| Variables included in interview to detect recall bias | | | |
| Umbilical hernia during infancy | 15 (4.2) | 12 (3.4) | 0.56 |
| Abnormal head shape during infancy | 16 (4.5) | 11 (3.1) | 0.43 |

Abbreviation: IQR = interquartile range.

^a Significant.

^b Range 0 to 36 visits for cases, 0 to 60 for controls.

were 2 types of controls: routine visit controls enrolled at the time of a routinely scheduled clinic visit to a primary provider for an annual checkup or a neurologist for headache or developmental delay (target n = 230) and trauma visit controls enrolled at the time of an urgent visit or admission for trauma (target n = 120). Children attending a routine visit would be biased against a major infection requiring hospitalization; however, those with minor infections would likely still attend a scheduled medical appointment. The trauma controls were included because they could provide a research blood sample (at the time of clinical phlebotomy or IV insertion), and would be relatively unbiased with regards to infection except that very ill children might be less active, and hence less likely to experience trauma. (Most other children undergoing clinical venous access could be biased either towards infection, if the reason for phlebotomy is directly or indirectly related to infection, or against, if undergoing an elective procedure.) The laboratory assays will be the subject of future analyses. Sites that did not have a pediatric trauma center could not feasibly enroll trauma controls. Although controls were not pairwise matched, sites were asked to enroll roughly the same number of cases as controls. In addition, age histograms and geographic maps of cases and controls were provided to the sites throughout the enrollment period to encourage a similar demographic distribution.

Parental interview. Parents/guardians participated in a structured interview (appendix e-1 on the *Neurology*[®] Web site at Neurology.org) performed as soon as possible (maximum of 1 week after enrollment, or 3 weeks after stroke, whichever came first). The interview included questions about infections and vaccinations prior to the stroke ictus (for cases), the trauma event (for trauma visit controls), or enrollment (for routine visit controls). Because recommended vaccines vary by age and country, we asked, as a general indicator of vaccine status, whether the child had received all, most, some, few, or none of the routine vaccines expected for his or her age, and classified children as poorly vaccinated if the parent responded some/few/none. We asked about conditions that we did not expect to be associated with AIS (umbilical hernia and abnormal head shape during infancy) as a measure of recall bias. Exposure to vasoactive medications was assessed using lists of medications and locally available brand name cold remedies known to contain them. Diphenhydramine, a common nonvasoactive ingredient in cold remedies, was included to gauge recall bias.

Major infection. Major infection included diagnoses of meningitis/encephalitis and bacteremia/sepsis, as previously defined.¹⁶ These diagnoses were ascertained through chart review, and included diagnoses made after the stroke as long as the infection was thought to precede the stroke. All other infections were measured by the parental interview.

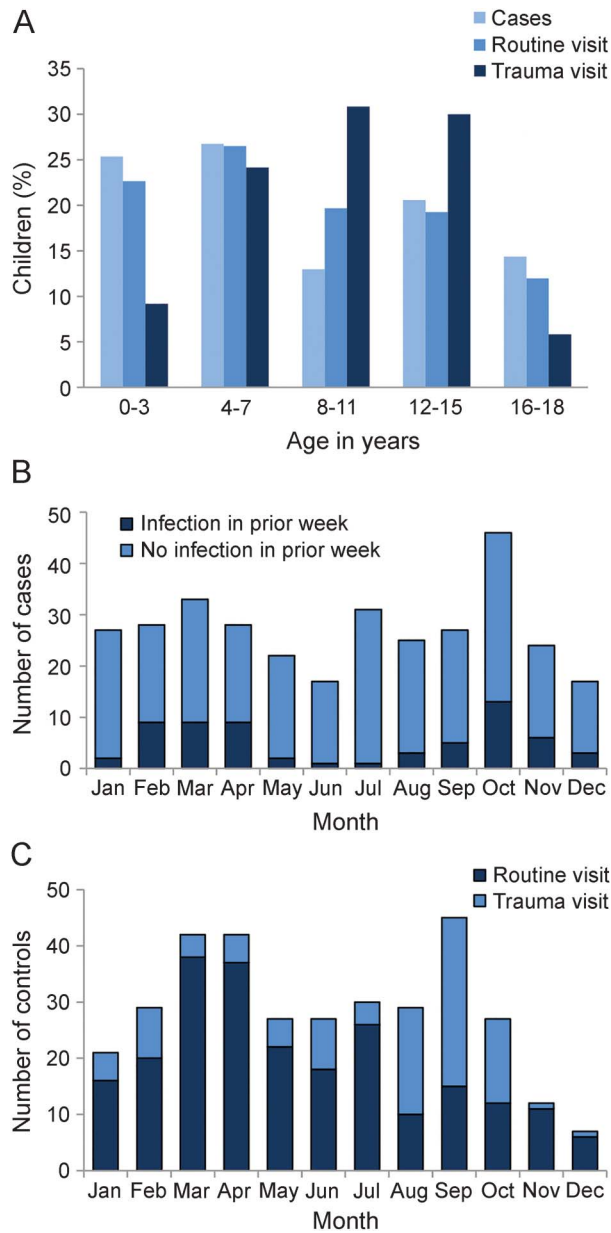
Data analysis. Interview questions that parents answered as unknown were counted as missing values. Unadjusted comparisons between cases and controls were made using χ^2 and Fisher exact tests for categorical variables and the Wilcoxon rank sum test for continuous variables.

We used logistic regression models to identify factors associated with childhood AIS. In all models, we adjusted for age (as a categorical variable given its nonlinear relationship with AIS) to account for age-related variability in rates of exposure to infection and vaccinations, and for country income level, which would likely influence vaccination rates. For this purpose, countries were categorized as either lower and middle income countries (Philippines, Serbia, and China) or high-income countries (all others), as defined by the World Bank in 2014 (<http://data.worldbank.org/country>; accessed November 25, 2014). In our final multivariable models, we also adjusted for race, because of previously reported racial differences in childhood stroke risk,¹⁸ season (because of seasonal variation in infection), and socioeconomic status (SES). Our markers of SES (urban/suburban/rural residence, household income, and highest level of maternal education) were highly correlated with one another; we alternated these indicators in multivariable models and compared results. Our primary analyses included children with major infections. To account for the fact that controls would be less likely to have been diagnosed with a major infection, we conducted sensitivity analyses excluding cases with major infection. To address potential selection bias related to our trauma visit controls (as a current infection could reduce risk of trauma), we conducted additional sensitivity analyses comparing cases to each control group separately. We used Stata v12 (Stata Corporation, College Station, TX) for all analyses.

RESULTS VIPS sites screened 650 potential cases, and enrolled 387 (160 did not meet inclusion criteria, 64 did not consent, and 39 had an inadequate blood sample); 32 were excluded upon central review. The study included 355 confirmed cases and 354 controls (234 routine visit and 120 trauma visit). Parental interviews were performed at a median (interquartile range [IQR]) of 1 (0–3) day after case enrollment (6 [4–11] days after stroke) and 0 (0–0) days after control enrollment. The trauma visit controls were similar to routine visit controls except more likely to be older, male, Canadian, and residing in a rural area (table e-1). Demographics were similar between cases and controls, except for country of enrollment and SES (table 1). Although case and control age was similar when the controls were combined, the trauma visit controls were older (figure). Cases were similar to controls in frequency of doctor's appointments and parental report of umbilical hernia or abnormal head shape.

Stroke subtype, comorbidities and risk factors, presentation, and infarct characteristics have been published.¹⁷ Of the 355 cases, 127 (36%) had a

Figure Age and seasonal distributions of childhood arterial ischemic stroke cases and controls



Histograms demonstrate (A) age distribution of cases of childhood arterial ischemic stroke ($n = 355$), routine visit controls ($n = 234$), and trauma visit controls ($n = 120$); (B) seasonal distribution of arterial ischemic strokes in northern hemisphere children, stratified by those with ($n = 63$) vs without ($n = 262$) infection in the prior week; and (C) seasonal distribution of enrollment of routine visit controls ($n = 234$) and trauma visit controls ($n = 120$). (All controls were enrolled in the northern hemisphere.)

definite arteriopathy, 34 (10%) a possible arteriopathy, and 194 (55%) no arteriopathy, including 76 (21%) cardioembolic (65 spontaneous and 11 procedure-related), 9 (3%) presumed embolic with a prothrombotic condition, 19 (5%) with another etiology (genetic syndrome, $n = 10$; meningitis/encephalitis, head trauma, and cancer, each $n = 3$), and 90 (25%) idiopathic.

Exposures based on parental interview are shown in table 2. Adjusted only for age, cases were more

likely than controls to have a reported infection in the prior week (odds ratio [OR] 6.3, 95% confidence interval [CI] 3.3–12, $p < 0.0001$), prior month (OR 2.3, 95% CI 1.6–3.2, $p < 0.0001$), and prior 6 months (OR 1.3, 95% CI 0.97–1.8, $p = 0.08$). After also adjusting for infection in the prior week, neither infection in the prior month (OR 1.4, 95% CI 0.92–2.0, $p = 0.12$) nor prior 6 months (OR 1.1, 95% CI 0.80–1.5, $p = 0.53$) remained significant. Of the 64 cases reporting recent infections (prior week), 32 (50%) had upper respiratory infections and 33 (52%) had a fever. Few cases or controls reported exposure to cold medications. In comparing routine visit to trauma visit controls, there were no differences in infection in the prior week (table e-1), or in associated signs/symptoms, or exposure to cold medications (data not shown).

Strokes occurred in all months of the year, but those preceded by infection showed seasonal variation (figure). Stroke cases with infection in the prior week had a median age of 4.0 years (IQR 1.5–8.7) compared to 9.1 (3.5–15) for those without a preceding infection ($p < 0.001$), but there were otherwise no differences between those with or without infection in demographics or stroke presentation, location, or size (data not shown). Preceding infection was common across stroke subtypes, reported in 19 of 127 (15%) with arteriopathic, 14 of 65 (22%) with spontaneous cardioembolic, and 18 of 90 (20%) with idiopathic AIS ($p = 0.17$). It was also common across subtypes of arteriopathy: 8 of 34 (24%) with moyamoya, 3 of 25 (12%) with transient cerebral arteriopathy, and 2 of 26 (8%) with arterial dissection ($p = 0.22$).

By parental report, controls were generally better vaccinated than cases (table 3). Having had a vaccination in the prior week (of any type) was associated with a reduced risk of AIS (OR 0.23, 95% CI 0.10–0.52, $p = 0.0005$). Vaccination rates varied by country income level, but controls were better vaccinated than cases in each strata (table e-2). Vaccination rates were similar between routine visit and trauma visit controls, with 97% of both groups receiving all or most routine vaccines expected for their age (table e-1).

In the multivariable logistic regression model (table 4), recent infection (prior week) and being poorly vaccinated remained independent predictors of childhood AIS, as did lower SES (rural residence shown, but findings were similar for household income and maternal education). In a sensitivity analysis excluding 34 cases with medical record documentation of major infection ($n = 13$ sepsis/bacteremia, $n = 15$ meningitis/encephalitis, $n = 7$ both), and using the same variables in the model, the strength of the association for recent infection

Table 2 Exposures to infection and cold medications among patients with childhood arterial ischemic stroke and age-matched controls, measured by parental interview

| Characteristics | Cases (n = 355), n (%) | Controls (n = 354), n (%) | p Value |
|--|------------------------|---------------------------|----------------------|
| Any infection in the: | | | |
| Prior week | 64 (18.0) | 12 (3.4) | <0.0001 ^a |
| Prior month | 137 (38.6) | 77 (21.8) | <0.0001 ^a |
| Prior 6 months | 191 (53.8) | 164 (46.3) | 0.08 |
| Recent infection (prior week) | | | |
| Type of illness | | | |
| Cold/upper respiratory infection | 32 (9.0) | 9 (2.5) | 0.0002 ^a |
| Stomach flu/gastroenteritis | 9 (2.5) | 0 (0) | 0.004 ^a |
| Ear infection/otitis media | 7 (2.0) | 1 (0.3) | 0.07 |
| Pneumonia | 5 (1.4) | 0 (0) | 0.06 |
| Flu/influenza | 3 (0.8) | 0 (0) | 0.25 |
| Bronchitis | 2 (0.6) | 0 (0) | 0.5 |
| Sinusitis | 2 (0.6) | 0 (0) | 0.5 |
| Meningitis | 2 (0.6) | 0 (0) | 0.5 |
| Strep pharyngitis | 1 (0.3) | 1 (0.3) | 1 |
| Mastoiditis | 0 (0) | 0 (0) | NA |
| Urinary tract infection | 0 (0) | 0 (0) | NA |
| Chicken pox | 0 (0) | 0 (0) | NA |
| Roseola | 0 (0) | 0 (0) | NA |
| Taken to a doctor for the illness | 45 (12.7) | 3 (0.8) | <0.0001 ^a |
| Treated with antibiotics for the illness | 31 (8.7) | 2 (0.6) | <0.0001 ^a |
| Missed school for the illness | 23 (6.5) | 2 (0.6) | <0.0001 ^a |
| Associated signs/symptoms | | | |
| Cough | 36 (10.1) | 8 (2.3) | <0.0001 ^a |
| Fever (temperature >101°F or 38.5°C) | 33 (9.3) | 4 (1.1) | <0.0001 ^a |
| Runny nose | 30 (8.5) | 6 (1.7) | <0.0001 ^a |
| Vomiting | 17 (4.8) | 0 (0) | <0.0001 ^a |
| Sore throat | 10 (2.8) | 5 (1.4) | 0.19 |
| Diarrhea | 8 (2.3) | 0 (0) | 0.008 ^a |
| Ear pain | 4 (1.1) | 1 (0.3) | 0.37 |
| Rash | 3 (0.8) | 0 (0) | 0.25 |
| Ulcers in mouth | 1 (0.3) | 0 (0) | 1 |
| Urinary frequency | 1 (0.3) | 0 (0) | 1 |
| Pain with urination | 0 (0) | 0 (0) | NA |
| Ulcers on hands/feet | 0 (0) | 0 (0) | NA |
| Cumulative infections (prior 6 months) | | | |
| Total infectious illnesses, median (range) | 1 (0–17) | 1 (0–6) | 0.18 |
| Total days of illness, median (range) | 4 (0–180) | 3 (0–100) | 0.0009 ^a |
| No. of physician visits for illness, median (range) | 0 (0–14) | 0 (0–6) | <0.0001 ^a |
| Total school/daycare days missed for illness, median (range) | 0 (0–180) | 0 (0–40) | 0.65 |

Continued

was similar (OR 6.5, $p < 0.0001$), while the OR for being poorly vaccinated lowered from 8.2 to 5.9, but remained significant ($p = 0.005$). In a second sensitivity analysis, we created models comparing cases to only routine visit controls, and only trauma visit controls; CIs widened, but the findings were similar (table e-3).

DISCUSSION In this prospective, international case-control study of childhood stroke, infection transiently increased risk of childhood AIS, regardless of stroke subtype, while routine vaccinations appeared protective. These associations persisted even after adjusting for age, sex, season, and SES. A preceding infection alone does not fully explain why AIS occurred in a child; it increases risk only 6-fold while the baseline population risk is very low. Rather, infection likely acts as a stroke trigger in a child who is otherwise predisposed, and explains why the stroke happened at a particular point in that child's life.

Major infections have long been considered etiologies of AIS in both children and adults, while a more recent body of literature suggests that minor infections can also act as a trigger for stroke in adults.^{6–14} Although utilizing different methods to ascertain infection, a handful of studies have suggested that minor infection is common prior to AIS in childhood. The International Pediatric Stroke Study registry reported infection as a stroke risk factor in 24% of 676 AIS cases enrolled in 10 countries, although infection, including a time frame for exposure, was not well-defined.¹⁹ A single-center UK study reported “clinical symptoms of infection” in 34% of 212 AIS cases.²⁰ In the only prior association study, set in the population of children receiving care from Kaiser Permanente Northern California, 33% of 126 cases (vs 13% of controls) had a medical encounter for infection in the prior 4 weeks,²¹ and 14% of cases (1.7% of controls) in the prior 7 days.¹⁵ The study reported an adjusted OR of 15 (95% CI 3.3–68) for minor infection ≤ 3 days prior to stroke, and OR 4.0 (0.9–17.9) for infection 4–7 days prior.¹⁵ This Kaiser study was geographically narrow, based purely on retrospective chart review, and unable to review imaging to either confirm or classify the AIS. VIPS improves upon the Kaiser study with its large sample size, broad geographic representation, prospective enrollment, and central imaging review for case confirmation and stroke classification. Despite these differences, the findings were similar. In VIPS, 39% of cases had parental report of infection in the prior 4 weeks, and 18% in the prior 1 week. We observed a similar association between infection and childhood AIS (adjusted OR 6.5, 95% CI 3.3–13, for infection in the prior week).

Table 2 Continued

| Characteristics | Cases (n = 355), n (%) | Controls (n = 354), n (%) | p Value |
|--|---------------------------|------------------------------|-------------------|
| Exposure to cold medications | | | |
| Cold medication taken in prior 24 hours | | | |
| Vasoactive ingredients | | | |
| Dextromethorphan | 1 (0.3) | 0 (0) | 1 |
| Pseudoephedrine | 1 (0.3) | 2 (0.6) | 0.62 |
| Phenylpropanolamine | 1 (0.3) | 0 (0) | 1 |
| Ephedra | 0 (0) | 1 (0.3) | 0.5 |
| Not vasoactive | | | |
| Diphenhydramine | 4 (1.1) | 0 (0) | 0.12 |
| Other cough syrup or cold preparation | 4 (1.1) | 1 (0.3) | 0.37 |
| Cold medication taken in prior week | | | |
| Vasoactive ingredients | | | |
| Dextromethorphan | 5 (1.4) | 1 (0.3) | 0.22 |
| Pseudoephedrine | 2 (0.6) | 2 (0.6) | 1 |
| Phenylpropanolamine | 1 (0.3) | 0 (0) | 1 |
| Ephedra | 0 (0.0) | 0 (0) | NA |
| Not vasoactive | | | |
| Diphenhydramine | 6 (1.7) | 0 (0) | 0.03 ^a |
| Other cough syrup or cold preparation | 9 (2.5) | 2 (0.6) | 0.06 |

Abbreviation: NA = not applicable.

^a Significant.

Infection could trigger stroke through several different mechanisms.^{22,23} Infection triggers systemic inflammation, which activates the coagulation system and could promote thromboembolism. Varicella-zoster virus can directly invade the internal carotid arteries,²⁴ but other infections could have an indirect pathologic effect on arteries by causing inflammatory injury to the endothelium. Inflammatory injury to cardiac endothelium might likewise promote thrombus formation in the heart, and secondary cardioembolic stroke. In VIPS, we found that infection was prevalent across stroke subtypes, arteriopathic and cardioembolic, suggesting a common mechanism. Another proposed causal pathway between infection and arteriopathic stroke is the use of cold remedies with vasoactive ingredients,²⁵ but little use of such medications was reported in our study and we found no association with AIS.

Vaccinations could conceivably reduce risk of AIS by preventing infection, or transiently increase risk by causing inflammation. In our analyses, all adjusted for age, we found only a protective effect of vaccination. It is possible that vaccinations are simply a marker for higher SES or better access to care. However, cases and controls did not differ in reported frequency of

routine visits to a doctor's office, suggesting equal access, and the protective effect of vaccination was independent of SES in our multivariable models. Because exposures to the different individual vaccines were highly correlated, we could not determine whether any one vaccine was particularly (and independently) protective against AIS. Rather, we speculate that simply being better vaccinated affords some protection against AIS by decreasing a child's exposure to infection, and thereby decreasing periods of transient systemic inflammation.

A number of observational studies have reported no increased stroke risk after routine vaccination in adults, and some have even suggested a protective effect.^{8,26-29} The only prior pediatric study to assess vaccination and stroke risk was a retrospective cohort study that examined the electronic records from 8 medical care organizations, and found no increased risk of AIS after varicella vaccination.³⁰ However, this study assessed no other pediatric vaccines, and stroke diagnoses were based purely on billing codes, which have <40% sensitivity for pediatric AIS.¹ Our study, on the other hand, assessed a broad array of pediatric vaccinations, and used rigorous methods for confirming the stroke diagnosis. Our findings provide reassurance that vaccinations do not increase stroke risk, and may even reduce risk.

The major limitation of this analysis is the potential for selection bias, as the controls were biased against current infections severe enough to require hospital admission or, in the case of the trauma visit controls, to decrease activity and thereby reduce risk of trauma. However, the association with infection remained significant in a sensitivity analysis removing cases of AIS with major infection, and another analysis comparing cases only to the routine visit controls. Other limitations are the subjective measure of infection and ascertainment of vaccination exposure through parental report, which could have led to recall bias. However, there was no difference between cases and controls in parental report of the variables included as a measure of recall bias, the total number of infections over the prior 6 months, or exposure to cold medications. Furthermore, our prior study in the Kaiser population, although retrospective, had a measure of infection (documented medical encounter) resistant to either selection or recall bias, and similarly demonstrated an association between acute infection and childhood AIS.¹⁵ Other limitations are our inability to measure subclinical infections and that our cases and controls were not matched geographically.

Infection likely acts as a trigger for AIS in children who are otherwise predisposed to stroke, while routine childhood vaccinations may be protective. Infection control through methods like handwashing and vaccinations may be a strategy for primary stroke

Table 3 Exposures to vaccinations among patients with childhood AIS and age-matched controls, measured by parental interview

| Characteristic | Cases (N = 355), n/N (%) | Controls (N = 354), n/N (%) | Risk of AIS ^a | |
|---|--------------------------|-----------------------------|--------------------------|---------------------|
| | | | OR (95% CI) | p Value |
| How many routine vaccines has your child received? | | | | 0.001 ^b |
| All expected for his or her age | 294/355 (82.8) | 320/354 (90.4) | | |
| Most | 21/355 (5.9) | 22/354 (6.2) | | |
| Some | 16/355 (4.5) | 2/354 (0.6) | | |
| Few | 2/355 (0.6) | 0/354 (0.0) | | |
| None | 9/355 (2.5) | 2/354 (0.6) | | |
| Unknown (missing data) | 13/355 (3.7) | 8/354 (2.3) | | |
| Composite variable for poorly vaccinated ^c (some/few/none) | 27/342 (7.9) | 4/346 (1.2) | 7.3 (2.5-21) | 0.0002 ^b |
| Ever received a routine vaccination against ^c | | | | |
| MMR | 298/355 (83.9) | 327/354 (92.4) | 0.40 (0.24-0.68) | 0.0007 ^b |
| Polio | 322/341 (94.4) | 338/346 (97.7) | 0.42 (0.18-0.98) | 0.004 ^b |
| DPT | 332/355 (93.5) | 344/354 (97.2) | 0.43 (0.20-0.93) | 0.03 ^b |
| Pneumococcus | 255/324 (78.7) | 285/322 (88.5) | 0.42 (0.26-0.69) | 0.0007 ^b |
| Varicella | 206/325 (63.4) | 258/337 (76.6) | 0.51 (0.36-0.74) | 0.0003 ^b |
| Meningococcus | 211/315 (67.0) | 246/323 (76.2) | 0.61 (0.42-0.91) | 0.01 ^b |
| Hepatitis A | 200/317 (63.1) | 214/322 (66.5) | 0.88 (0.62-1.25) | 0.48 |
| Hepatitis B | 266/327 (81.3) | 263/340 (77.4) | 1.3 (0.96-1.01) | 0.17 |
| Any vaccinations, prior 6 months | 109/341 (32.0) | 123/349 (35.2) | 0.82 (0.59-1.15) | 0.25 |

Abbreviations: AIS = arterial ischemic stroke; CI = confidence interval; DPT = diphtheria/pertussis/tetanus; MMR = measles/mumps/rubella; OR = odds ratio.

^aAdjusted for age and geographic region.

^bSignificant.

^cExcludes any who answered unknown; all measured vaccines are shown.

Table 4 Multivariate model showing independent predictors of childhood arterial ischemic stroke^a

| Characteristics | OR (95% CI) | p Value |
|--------------------------------|------------------|---------|
| Infection in prior week | 6.3 (3.2-12) | <0.0001 |
| Poorly vaccinated ^b | 8.2 (2.5-26) | 0.0004 |
| Residence | | |
| Urban | Ref | |
| Suburban | 2.0 (1.4-2.9) | 0.40 |
| Rural | 3.0 (1.8-4.8) | 0.001 |
| LAMI country | 0.84 (0.34-2.1) | 0.70 |
| Race | | |
| White | Ref | |
| Black | 2.0 (1.1-3.7) | 0.005 |
| Asian | 1.0 (0.49-1.8) | 0.71 |
| Other/mixed/unknown | 0.62 (0.39-0.99) | 0.007 |

Abbreviations: CI = confidence interval; LAMI = lower and middle income; OR = odds ratio; Ref = reference.

^aModel also adjusted for sex, season at enrollment, and age (as a categorical variable because nonlinear).

^bComposite variable (some/few/none routine vaccinations).

prevention. A better understanding of the association between infection and AIS in children will also inform the development of strategies for prevention of recurrent stroke in this important age group.

AUTHOR CONTRIBUTIONS

The study was conceived of and designed by H.J.F. and G.A.d., with input into study design by all the authors. H.J.F., G.A.d., and M.S.V.E. provided overall coordination of the study. M.M.D., M.T., M.J.R., L.T., G.A.d., and the VIPS investigators enrolled patients and collected data. M.W., H.J.F., and A.J.B. performed the imaging reviews. N.K.H. analyzed the data. All authors contributed to the interpretation of the data. H.J.F. drafted the manuscript, and all others critically revised it.

ACKNOWLEDGMENT

The authors thank the VIPS research coordinators, patients, and their families.

STUDY FUNDING

Funded by the NIH (R01 NS062820; PIs Fullerton, deVeber). All authors receive NIH funding for this project except for Dr. Glaser.

DISCLOSURE

The authors report no disclosures relevant to the manuscript. Go to Neurology.org for full disclosures.

REFERENCES

1. Agrawal N, Johnston SC, Wu YW, Sidney S, Fullerton HJ. Imaging data reveal a higher pediatric stroke incidence than prior US estimates. *Stroke* 2009;40:3415–3421.
2. Kleindorfer D, Khoury J, Kissela B, et al. Temporal trends in the incidence and case fatality of stroke in children and adolescents. *J Child Neurol* 2006;21:415–418.
3. deVeber GA, MacGregor D, Curtis R, Mayank S. Neurologic outcome in survivors of childhood arterial ischemic stroke and sinovenous thrombosis. *J Child Neurol* 2000;15:316–324.
4. Lanthier S, Carmant L, David M, Larbisseau A, de Veber G. Stroke in children: the coexistence of multiple risk factors predicts poor outcome. *Neurology* 2000;54:371–378.
5. De Schryver EL, Kappelle LJ, Jennekens-Schinkel A, Boudewyn Peters AC. Prognosis of ischemic stroke in childhood: a long-term follow-up study. *Dev Med Child Neurol* 2000;42:313–318.
6. Grau AJ, Bugge F, Heindl S, et al. Recent infection as a risk factor for cerebrovascular ischemia. *Stroke* 1995;26:373–379.
7. Grau AJ, Bugge F, Becher H, et al. Recent bacterial and viral infection is a risk factor for cerebrovascular ischemia: clinical and biochemical studies. *Neurology* 1998;50:196–203.
8. Smeeth L, Thomas SL, Hall AJ, Hubbard R, Farrington P, Vallance P. Risk of myocardial infarction and stroke after acute infection or vaccination. *N Engl J Med* 2004;351:2611–2618.
9. Bova IY, Bornstein NM, Korczyn AD. Acute infection as a risk factor for ischemic stroke. *Stroke* 1996;27:2204–2206.
10. Macko RF, Ameriso SF, Barndt R, Clough W, Weiner JM, Fisher M. Precipitants of brain infarction: roles of preceding infection/inflammation and recent psychological stress. *Stroke* 1996;27:1999–2004.
11. Syrjanen J, Valtonen VV, Livanainen M, Kaste M, Huttunen JK. Preceding infection as an important risk factor for ischaemic brain infarction in young and middle aged patients. *Br Med J* 1988;296:1156–1160.
12. Roquer J, Cuadrado-Godia E, Giralt-Steinthauer E, et al. Previous infection and stroke: a prospective study. *Cerebrovasc Dis* 2012;33:310–315.
13. Elkind MS, Carty CL, O'Meara ES, et al. Hospitalization for infection and risk of acute ischemic stroke: the Cardiovascular Health Study. *Stroke* 2011;42:1851–1856.
14. Elkind MS, Ramakrishnan P, Moon YP, et al. Infectious burden and risk of stroke: the northern Manhattan study. *Arch Neurol* 2010;67:33–38.
15. Hills NK, Sidney S, Fullerton HJ. Timing and number of minor infections as risk factors for childhood arterial ischemic stroke. *Neurology* 2014;83:890–897.
16. Fullerton HJ, Elkind MS, Barkovich AJ, et al. The Vascular effects of Infection in Pediatric Stroke (VIPS) study. *J Child Neurol* 2011;26:1101–1110.
17. Wintermark M, Hills NK, deVeber GA, et al. Arteriopathy diagnosis in childhood arterial ischemic stroke: results of the Vascular effects of Infection in Pediatric Stroke Study. *Stroke* 2014;45:3597–3605.
18. Fullerton HJ, Wu YW, Zhao S, Johnston SC. Risk of stroke in children: ethnic and gender disparities. *Neurology* 2003;61:189–194.
19. Mackay MT, Wiznitzer M, Benedict SL, Lee KJ, DeVeber GA, Ganesan V. Arterial ischemic stroke risk factors: the International Pediatric Stroke Study. *Ann Neurol* 2011;69:130–140.
20. Ganesan V, Prengler M, McShane MA, Wade AM, Kirkham FJ. Investigation of risk factors in children with arterial ischemic stroke. *Ann Neurol* 2003;53:167–173.
21. Hills NK, Johnston SC, Sidney S, Zielinski BA, Fullerton HJ. Recent trauma and acute infection as risk factors for childhood arterial ischemic stroke. *Ann Neurol* 2012;72:850–858.
22. Grau AJ, Urbaneck C, Palm F. Common infections and the risk of stroke. *Nat Rev Neurol* 2010;6:681–694.
23. Emsley HC, Hopkins SJ. Acute ischaemic stroke and infection: recent and emerging concepts. *Lancet Neurol* 2008;7:341–353.
24. Nagel MA, Cohrs RJ, Mahalingam R, et al. The varicella zoster virus vasculopathies: clinical, CSF, imaging, and virologic features. *Neurology* 2008;70:853–860.
25. Cantu C, Arauz A, Murillo-Bonilla LM, Lopez M, Barinagarrementeria F. Stroke associated with sympathomimetics contained in over-the-counter cough and cold drugs. *Stroke* 2003;34:1667–1672.
26. Nichol KL, Nordin J, Mullooly J, Lask R, Fillbrandt K, Iwane M. Influenza vaccination and reduction in hospitalizations for cardiac disease and stroke among the elderly. *N Engl J Med* 2003;348:1322–1332.
27. Wang CS, Wang ST, Lai CT, Lin LJ, Lee CT, Chou P. Reducing major cause-specific hospitalization rates and shortening hospital stays after influenza vaccination. *Clin Infect Dis* 2004;39:1604–1610.
28. Vila-Corcoles A, Ochoa-Gondar O, Rodriguez-Blanco T, et al. Evaluating clinical effectiveness of pneumococcal vaccination in preventing stroke: the CAPAMIS Study, 3-year follow-up. *J Stroke Cerebrovasc Dis* 2014;23:1577–1584.
29. Pinol-Ripoll G, de la Puerta I, Santos S, Purroy F, Mostacero E. Chronic bronchitis and acute infections as new risk factors for ischemic stroke and the lack of protection offered by the influenza vaccination. *Cerebrovasc Dis* 2008;26:339–347.
30. Donahue JG, Kieke BA, Yih WK, et al. Varicella vaccination and ischemic stroke in children: is there an association? *Pediatrics* 2009;123:e228–e234.



New Directions in Infection-Associated Ischemic Stroke

Jin-Man Jung^a
Andr as Gruber^b
Peter Heseltine^c
Kumar Rajamani^d
Sebasti n F. Ameriso^e
Mark J. Fisher^f

^aDepartment of Neurology,
Korea University Ansan Hospital,
Korea University College of Medicine,
Ansan, Korea;
Korea University Zebrafish,
Translational Medical Research Center,
Ansan, Korea

^bAronora, Inc., Portland, OR, USA

^cDivision of Infectious Diseases,
Department of Medicine,
University of California, Irvine, Irvine,
CA, USA

^dDepartment of Neurology,
Wayne State University-Detroit Medical
Center, Detroit, MI, USA

^eDivision of Vascular Neurology,
Department of Neurology, Fleni,
Autonomous City of Buenos Aires,
Argentina

^fDepartment of Neurology,
University of California Irvine Medical
Center, Orange, CA, USA

The relationship between infections and stroke has not been fully characterized, probably delaying the development of specific treatments. This narrative review addresses mechanisms of stroke linked to infections, including hypercoagulability, endothelial dysfunction, vasculitis, and impaired thrombolysis. SARS-CoV-2, the virus that causes COVID-19, may promote the development of stroke, which may represent its most severe neurological complication. The development of specific therapies for infection-associated stroke remains a profound challenge. Perhaps the most important remaining issue is the distinction between infections that trigger a stroke versus infections that are truly incidental. This distinction likely requires the establishment of appropriate biomarkers, candidates of which are elevated levels of fibrin D-dimer and anticardiolipin/antiphospholipid antibodies. These candidate biomarkers might have potential use in identifying pathogenic infections preceding stroke, which is a precursor to establishing specific therapies for this syndrome.

Keywords stroke; thrombosis; infections; fibrin D-dimer;
anticardiolipin/antiphospholipid antibodies.

Infections have long been suggested as precipitating factors for stroke.¹⁻³ The lack of appropriate experimental models has made it difficult to determine whether a specific infection is directly causal for the development of stroke. This review addresses the pathogenesis of stroke preceded by infections, and the therapeutic implications of infection-related stroke.

HYPERCOAGULABILITY AND THROMBOSIS

The immune system activation and inflammation occur after infection to eliminate infectious agents from the host. However, overactivation of these pathways can produce pathophysiological thrombotic and thromboembolic events.⁴ Various exogenous pathogens (i.e., infectious agents)^{5,6} can directly interact with endothelial cells, platelets, and leukocytes. Endogenous triggers (i.e., damage-associated molecular pattern molecules)⁷ and host immune responses can directly or indirectly also lead to endothelial dysfunction, alterations in the vessel wall integrity and vasomotor tone, activation of leukocytes and platelets, and decreases in antithrombotic mechanisms (e.g., fibrinolysis and inhibition of thrombin generation).⁸ Adhesion molecules such as P-selectin, E-selectin, vascular cell adhesion molecule-1, and intracellular adhesion molecule-1 can be upregulated in endothelial cells by bacterial products, viruses, and proinflammatory cytokines, resulting in an interplay of endothelial cells with platelets, neutrophils, and monocytes.⁹ Also, activated vascular endothelial cells express and synthesize molecules that are vital to intravascular coagulation, including von Willebrand factor, tissue factor, and plasminogen activator inhibitor type 1 (PAI-1).¹⁰

Thrombin and other related coagulation enzymes, and thus the development of intravascular coagulation, are also controlled by several complicated direct and indirect mechanisms.

  This is an Open Access article distributed under the terms of the Creative Commons Attribution Non-Commercial License (<https://creativecommons.org/licenses/by-nc/4.0>) which permits unrestricted non-commercial use, distribution, and reproduction in any medium, provided the original work is properly cited.

Received February 7, 2023
Revised September 6, 2023
Accepted November 12, 2023

Correspondence

Mark J. Fisher, MD
Department of Neurology,
University of California Irvine Medical
Center, 101 The City Drive South,
Orange, CA 92868, USA
Tel +1-7144566856
Fax +1-7144566573
E-mail mfisher@hs.uci.edu

These include reversible and irreversible protease inhibitors, enzymes, receptors, and proteins such as tissue-factor pathway inhibitor (TFPI), antithrombin, thrombomodulin (i.e., an endothelial integral membrane protein critical for the activation of circulating protein C),¹¹ and activated protein C (APC). Plasmin and other fibrinolytic mechanisms help to remove intravascular clots (thrombi). Some infectious agents can directly or indirectly damage the endothelium, leading to its activation/dysfunction, increased vascular permeability, and even activation of the contact complex (prekallikrein, coagulation factors XII and XI, and the proteinase inhibitor kininogen 1), causing both thrombin generation and inflammation. Numerous effects have been observed in certain infections, sepsis, and stroke patients with antecedent infection/inflammation, including decreased activity of TFPI released by endothelial cells,^{12,13} increased release of PAI-1 from activated endothelia and platelets⁹ (suppressing intrinsic thrombolysis), impaired protein C system (via the depletion of the decreased hepatic expression or gamma carboxylation of protein C and protein S), reduced thrombomodulin and endothelial protein C receptors (EPCRs) in endothelial cells,¹⁴ and a decreased level of antithrombin.¹⁵ Thrombi can thus form when there is a local or systemic procoagulant state during infection due to the presence of a pathological imbalance between hemostatic/procoagulant and antithrombotic/anticoagulant mechanisms.¹⁶

The regulation of hemostasis and thrombosis varies across different organs. The brain's unique cellular milieu has specific consequences for the regulation of these factors.¹⁷ This has led to the concept of brain-specific regulation of thrombosis and hemostasis, a likely contributor to the vulnerability of the brain to the thrombotic consequences of infections.¹⁷ One of the most-prominent elements of brain-specific regulation of thrombosis and hemostasis relates to expression of thrombomodulin. Early studies reported a surprising absence of thrombomodulin from brain capillaries.¹⁸ Later studies demonstrated particularly low abundance of thrombomodulin in regions where small deep infarcts are most common.¹⁹ Astrocyte-dependent transforming growth factor-beta-mediated transcriptional regulation resulted in restricted expression of brain capillary thrombomodulin.²⁰ Note that the activation of protein C is demonstrable during carotid artery clamping, suggesting the presence of at least some functioning brain thrombomodulin.²¹ Features similar to thrombomodulin were demonstrated for brain capillary fibrinolysis, with restricted expression of the critical endogenous fibrinolytic molecule tissue plasminogen activator and with relative overabundance of PAI-1.^{22,23}

Elevated levels of anticardiolipin antibodies (aCL) as a thrombogenic factor have been reported in patients with

stroke preceded by infection.^{24,25} Antiphospholipid antibodies (aPL) including anti- β_2 -glycoprotein I antibodies (anti- β_2 -GPIs) as well as lupus anticoagulant (LA) may be induced by various infections from viral, bacterial, parasitic, and fungal sources. Among them, antibodies against domain I of β_2 -GPIs were found to be associated with thrombosis.²⁶ However, infection-induced aPL can be transient and is not necessarily associated with thrombosis. A systematic review²⁷ of case reports of antiphospholipid syndrome (APS) following infection found that most (68.3%) of the 293 cases developed APS or transient aPL with thromboembolic events, but the others did not experience such events. Of various clinical presentation, stroke or transient ischemic attack (TIA) was observed in about 23% of cases. aCL (91.8%) were most frequently reported in cases with APS or thromboembolic events, whereas positivity for LA (92.3%) was more commonly observed in patients without clinical events.

The mechanism of aPL production in infections includes antigen-dependent processes such as molecular mimicry of infectious agents and antigen-independent mechanisms such as impairment of immune tolerance caused by inflammation.²⁸ The pathogenesis of aPL-mediated coagulopathy was proposed as the activation of endothelial cells, complement, platelets, neutrophils, and monocytes by β_2 -GPI-anti- β_2 -GPI complexes, resulting in both coagulation and inflammation.²⁹ The association between aPL and thromboembolic events is now better understood with the discovery that the EPCR as a primary target of aPL participates in anticoagulation via the activation of protein C.³⁰ Thrombosis was generated in mouse models by aPL recognition of the endosomal lysobiphosphatidic acid-EPCR complex in various cell types and the subsequent cascade of coagulation and inflammation.³¹ Moreover, a strong inverse correlation was found between the IgG aCL titer and the level of circulating APC ($r=-0.55$, $p<0.001$) in patients with acute ischemic stroke preceded by infection.¹³ In addition, elevations of fibrin D-dimer (indicating fibrin generation and lysis) and inflammatory marker C-reactive protein (CRP) have been found in patients with brain infarction preceded by infection.^{25,32} Thus, the combined presence of coagulation activation and elevated aCL can provide important clues to the diagnosis of infection-associated stroke.

VASCULITIS AND DIRECT VASCULAR INJURY BY INFECTIONS

Vasculitis attributed to direct and indirect injury to endothelial cells from infections and the host immune-inflammatory response is probably one of the important etiologies in infection-related stroke. Suspected pathophysiological mech-

anisms include direct cellular injuries from microbial antigens, proinflammatory cytokines, and recruitment of immune cells resulting in endothelial damage and dysfunction/microthrombosis.^{9,33} Animal models of vasculitis induced by bacterial (e.g., *Chlamydia pneumoniae*) and herpesvirus infections support the association of infection with vasculitis.³⁴

Multiple infectious agents can infect the arterial wall during central nervous system (CNS) infection to directly induce stroke. The size, location, and number of involved cerebral blood vessels by a specific pathogen are expected to determine the infarct pattern and stroke subtype. Neurosyphilis results from CNS infection by *Treponema pallidum*; meningovascular syphilis causes stroke and meningitis that occur between the early and late forms of the disease.³⁵ Endothelial inflammation by syphilis eventually results in stroke by small-vessel occlusion.³⁶ Systemic tuberculosis, a chronic mycobacterial granulomatous infection, is one of the most prevalent infectious diseases worldwide, and is associated with an increased risk of ischemic stroke. A more direct mechanism is at play in tuberculous meningitis, where the vessels at the base and cortical branches of the brain are at particular risk of vasculitis and resultant strokes.^{37,38} Tuberculous meningitis or neurosyphilis can appear as opportunistic infections in immunocompromised patients, such as those with human immunodeficiency virus (HIV). Infective endocarditis is characterized by infection of the endocardial surface, commonly involving the cardiac valves, by various organisms.³⁹ Ischemic lesions are typically multiple and bilateral, consistent with cardioembolic stroke.⁴⁰ Infective endocarditis often leads to septic emboli and bacterial seeding of the arterial wall, which can result in inflammation and subsequent aneurysmal formation (mycotic aneurysm).⁴¹

Varicella-zoster virus (VZV) can infect cerebral arteries by spreading in the vessel wall, thereby causing direct cerebral arteriopathy and ischemic stroke, intracerebral hemorrhage (ICH), and subarachnoid hemorrhage (Fig. 1). Nagel and colleagues^{42,43} described the presence of VZV DNA in cerebral arteries from the autopsied brain of a male who died of sus-

pected CNS vasculitis. Those authors also reported that VZV can affect both small and large vessels. Another study by Gilden et al.⁴⁴ showed the detection of VZV antigen in the temporal arteries of 74% of patients with biopsy-proven giant-cell arteritis (GCA). However, this observation has not yet replicated by any other group. VZV spreading to extracerebral arteries remains inconclusive as a culprit of GCA.

Herpes simplex virus (HSV) is the cause of acute viral encephalitis in 50%–70% of cases in which a viral etiology can be identified.⁴⁵ HSV can induce infectious cerebral vasculopathies (involving the small or large vessels, or both) and subsequent ischemic and hemorrhagic strokes as CNS complications.⁴⁶ A systematic review of published cases indicated that HSV was associated with specific stroke manifestations, with HSV type 1 related to ICH due to vascular disruption by a necrotizing process, and HSV type 2 related to multifocal cerebral infarction attributed to large-vessel vasculitis.⁴⁷ Cytomegalovirus (CMV), which also a member of the herpesvirus family, activates the immune system in atherosclerotic plaques and causes vasculopathy similar to VZV.⁴⁸ Association of CMV infection with cardiovascular disease and stroke were also demonstrated in a meta-analysis.⁴⁹ In addition, HSV, hepatitis C virus, *Chlamydia pneumoniae*, *Helicobacter pylori*, *Porphyromonas gingivalis*, and *Aggregatibacter actinomycetemcomitans* have been found in atherosclerotic carotid and coronary vessels, and may contribute to the progression of atherosclerosis lesions.^{50–54} These observations suggest that certain pathogens such as *Chlamydia pneumoniae* are associated with an increased risk of stroke due to large-artery atherosclerosis.⁵⁵

HIV increases the risk of stroke by direct infection and indirectly by increasing the effects of traditional vascular risk factors for stroke.^{56,57} HIV-related strokes may manifest as large-artery atherosclerosis, cardioembolism, small-vessel disease, coagulopathy, and HIV-associated vasculopathy.⁵⁸ A characteristic HIV vasculopathy involves arterial remodeling, with inward remodeling causing vessel stenosis and atherosclerosis, and outward remodeling leading to thinning of

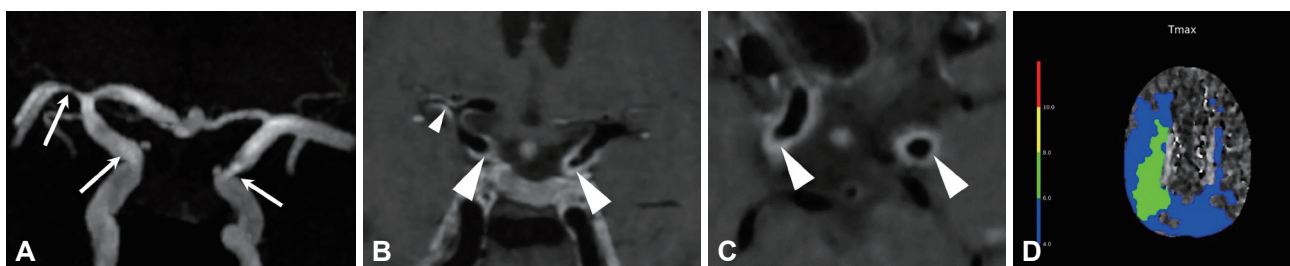


Fig. 1. Varicella-zoster virus vasculitis. A: Time-of-flight MR angiography reveals severe stenosis (indicated by arrows) in both internal carotid arteries and the proximal right middle cerebral artery. B and C: Coronal and axial contrast-enhanced vessel wall images demonstrate significant thickening and enhancement (arrowheads) in the corresponding vascular segments. D: Tmax map illustrates hypoperfusion in the vascular territories of both internal carotid arteries (blue areas), with critical hypoperfusion observed on the right side (green area). MR, magnetic resonance.

the medial layer and vessel dilation.⁵⁹ In a large sample of autopsy series from four brain banks, ischemic strokes in patients with HIV were attributed to inward remodeling and subsequent luminal narrowing,⁶⁰ and also extreme outward remodeling (dolichoectasia) of vascular walls.⁶¹

Certain fungal infections of the CNS can lead to stroke by direct infection or invasion of the vessel walls. These can occur in both immunocompetent and immunocompromised patients. Among these, yeast (e.g., *Cryptococcus* and *Candida species*) and hyphae-forming molds (e.g., *Aspergillus* and *Mucorales species*) have been implicated in stroke.⁶²

RECENT ACUTE INFECTION AS A TRIGGERING FACTOR FOR STROKE

There is extensive evidence⁶³⁻⁸² that acute infections, even if mild, can precipitate ischemic stroke (Table 1). Paganini-Hill et al.⁷² reported a case-control study showing an association between ischemic stroke and infections (and inflammatory events) during the preceding week or month; these were mostly respiratory infections that were associated with large-vessel atherothrombotic and cardioembolic strokes. Two case-control studies demonstrated links between recent infections and the risks of TIA and ischemic stroke.^{65,76} Sebastian et al.⁸⁰ used the New York State Inpatient Database to study the associations of infection with all types of stroke (ischemic stroke, ICH, and subarachnoid hemorrhage). They reported that all types of common infections, including urinary tract infections, upper respiratory infections, skin infections, and abdominal infections, were specifically associated with subsequent ischemic stroke. Moreover, they showed that the stroke risk peaked closer to the time of infection (within 1–2 weeks), but that the increased risk lasted for up to 4 months. Another study found a similar increased risk of ischemic stroke that extended up to 12 months after the incident infection, especially in younger individuals.⁷⁸ In a case-crossover study of Dutch subjects aged 18–49 years, the risk of ischemic stroke increased by more than 14-fold when fever or flu-like illness occurred within 24 hours of the event.⁸² Notably, these factors were found to potentially trigger the occurrence of all stroke subtypes other than small-vessel occlusion.

Children seem particularly prone to this increased stroke risk after even minor infections. In a population-based, case-control study of childhood arterial ischemic stroke, Hills et al.⁸³ reported that even typically minor infections were strongly associated with stroke. In children, this association occurred relatively early, typically 3 days or less from infection onset. In the Vascular Effects of Infection in Pediatric Stroke (VIPS) study, Fullerton et al.⁸⁴ reported a similar increased risk of preceding infections, especially in unvaccinated subgroups.

Data on the preventive effects of various vaccines are mixed. In population-based studies, herpes zoster vaccination in the elderly population had a protective effect for ischemic stroke,⁸⁵ whereas varicella vaccination in children showed no effect.⁸⁶ The large community-based 3-year prospective-cohort Community-Acquired Pneumonia, Acute Myocardial Infarction and Stroke (CAPAMIS) study had the primary aim of determining the effectiveness of the 23-valent pneumococcal polysaccharide vaccine (PPV23) against community-acquired pneumonia, acute myocardial infarction, and ischemic stroke in individuals aged at least 60 years. Vila-Corcoles et al.⁸⁷ found that the PPV23 was not effective in preventing cardiovascular events, and instead actually increased the thrombosis risk. Johnstone et al.⁸⁸ and Lavallée et al.⁸⁹ reported conflicting findings for the protective effect of influenza vaccination in reducing subsequent vascular events in patients with a high cardiovascular risk. However, a meta-analysis of 11 studies by Lee et al.⁹⁰ showed that vaccination against influenza did significantly lower the risk of any type of stroke, including ischemic stroke (odds ratio [OR]=0.77, 95% confidence interval [CI]=0.60–0.98). A subsequent case-control study found a modest reduction of the ischemic stroke risk with the influenza vaccine (OR=0.88, 95% CI=0.84–0.92) and no reduction of the stroke risk with the pneumococcal vaccine.⁹¹

COVID-19 AND STROKE

The COVID-19 pandemic has brought into sharp focus the multifaceted interactions between stroke risk and viral respiratory infections.⁹² SARS-CoV-2, the virus that causes COVID-19, is a single-stranded RNA virus of the *Coronaviridae* family. The host angiotensin-converting enzyme 2 (ACE2), which is abundant in alveoli, is the receptor for virus particles entering host cells. In addition to the lungs, arterial and venous endothelial cells as well as the arterial smooth-muscle cells abundantly express this molecule. Neurons, astrocytes, and oligodendrocytes with ACE2 receptors can be directly infected by the virus and activate the neuroinflammatory response.⁹³⁻⁹⁵

In addition to viral-induced endothelialitis⁹⁶ potentially leading to thrombosis and cerebral infarction, other proposed mechanisms include a hypercoagulable state induced by systemic/local inflammation, the cytokine storm, and postinfectious immune responses such as infection-induced aPL or overproduction of neutrophil extracellular traps.^{97,98} An autopsy brain study demonstrated neuroinflammation via the activation of endothelial cells, complement system, immune cells, astrocytes, and microglia, along with microthrombi in nine patients who died with COVID-19.⁹⁹ This has led to the identification of several serological biomarkers reflecting in-

Table 1. Studies of recent infections and ischemic stroke

| Study | Design and location | Population | Interval between preceding infection and stroke | Association between infection and ischemic stroke | Comments |
|------------------------------------|--|---|---|---|--|
| Syrjänen et al. ⁶⁴ | Case-control study; Finland; single center | 54 cases and 54 population controls | <1 month | RR=14.5, 95% CI=1.9–112.3 | Respiratory infections (m/c) |
| Grau et al. ⁶⁵ | Case-control study; Germany; single center | 197 cases and 197 population controls | <1 week | aOR=4.6, 95% CI=1.9–11.3 (ischemic stroke and TIA) | Recent infections, primarily of bacterial origin. Patients aged 51–60 and 61–70 years as other significant variables |
| Bova et al. ⁶⁶ | Case-control study; Germany; single center | 182 cases and 194 controls with previous stroke | <2 months | OR=2.92, 95% CI=1.64–5.26 | Respiratory and UTIs (more common) |
| Macko et al. ⁶⁷ | Case-control study; USA; single center | 37 cases, 47 community controls, and 34 hospitalized nonstroke patient controls | <1 week (infectious and inflammatory syndromes) | Prevalence of infection/inflammation was significantly higher in the case group than in either control group* | Upper respiratory tract infections (m/c) |
| Grau et al. ⁶⁸ | Case-control study; Germany; single center | 166 cases and 166 hospital controls | <1 week | OR=2.9 (95% CI=1.31–6.4) (ischemic stroke and TIA) | Respiratory tract infections (m/c). Infection increased risk of cardioembolism (OR=3.25, 95% CI=1.06–10.0) and tended to increase risk of artery-to-artery embolism (OR=7.0, 95% CI=0.86–57) |
| Nagaraja et al. ⁶⁹ | Case-control study; India; single center | 60 cases and 60 population controls | <2 weeks (mainly) | Infection in 26 cases and 6 controls (43.3% vs. 10%, <i>p</i> <0.001) | Respiratory tract infections (m/c) |
| Becher et al. ⁷⁰ | Case-control study; Germany; single center | 197 cases (ischemic stroke and TIA) and 197 population controls | <1 week | OR=4.33, 95% CI=1.78–10.51. Attributable risk of 0.15 (95% CI=0.09–0.21) | |
| Nencini et al. ⁷¹ | Case-control study; Italy; single center | 93 cases and 200 (107 hospital and 93 community) controls | <1 month (infectious and noninfectious events) | 1 month: OR=2.23, 95% CI=1.26–3.96 1 week: OR=2.45, 95% CI=1.11–5.39 | Acute infectious event significantly increased risks of atherothrombotic (OR=5.72, 95% CI=2.14–15.25) and cardioembolic stroke (OR=3.02, 95% CI=1.20–7.63) |
| Paganini-Hill et al. ⁷² | Case-crossover design; USA; single center | 233 cases and 362 outpatient controls | <1 month | No significant difference between the two groups* | Large-vessel atherothrombotic or cardioembolic stroke more common in patients with recent respiratory infection (<1 week) than in patients without infection (48% vs. 24%) |
| Zurrú et al. ⁷³ | Case-control study; Argentina; single center | 105 cases with atherothrombotic stroke and 354 outpatient controls | 1 year | aOR=4.9, 95% CI=2.3–10.2 | Respiratory tract infections were the most common type of infection at <3 months before an ischemic event, and more common in cases than control subjects (17% vs. 4%) |

Table 1. Studies of recent infections and ischemic stroke (continued)

| Study | Design and location | Population | Interval between preceding infection and stroke | Association between infection and ischemic stroke | Comments |
|---------------------------------------|--|--|--|---|--|
| Elkind et al. ⁷⁴ | Case-crossover; USA; Cardiovascular Health Study | 5,639 elderly population | <2 years as control period (hospitalization for infection) | 14 days: aHR=3.9, 95% CI=1.9-7.9 30 days: aHR=2.4, 95% CI=1.3-4.4 90 days: aHR=2.4, 95% CI=1.6-3.4 | |
| Dalager-Pedersen et al. ⁷⁵ | Cohort study; Denmark; 3 databases | 4,389 cases with community-acquired bacteremia, 43,831 population controls, and 21,893 hospitalized controls | <1 year community-acquired bacteremia | vs. population controls: 0-30 days: RR=25.82, 95% CI=16.72-39.89 31-180 days: RR=1.90, 95% CI=1.26-2.89 181-365 days: RR=0.97, 95% CI=0.58-1.59 vs. hospitalized controls: 0-30 days: RR=2.41, 95% CI=1.84-3.15 31-180 days: RR=1.25, 95% CI=0.82-1.91 181-365 days: RR=0.71, 95% CI=0.42-1.20 | |
| Consoli et al. ⁷⁶ | Prospective case-control study; Italy; multicenter | 749 cases and 253 outpatient controls | <1 month | OR=4.09, 95% CI=2.10-7.95 Early previous infection (<7 days before event) and chronic infection due to <i>Chlamydia pneumoniae</i> increased risk of acute cerebral infarction (RR=2.12, 95% CI=1.26-3.58; and RR=3.69, 95% CI=1.13-6.88; respectively) | Respiratory tract infections (m/c) |
| Cowan et al. ⁷⁷ | Case-crossover; USA; ARIC (Atherosclerosis Risk in Communities) | 1,008 ischemic stroke cases | <2 years as control period (hospitalization for infection) | 14 days: aOR=7.7, 95% CI=2.1-27.3 30 days: aOR=5.7, 95% CI=2.3-14.3 90 days: aOR=3.6, 95% CI=2.1-6.5 | Higher aOR in thrombotic strokes for the 14-day period and cardioembolic strokes for the 43-day period |
| Boehme et al. ⁷⁸ | Case-crossover; USA; California State Inpatient Database | 37,377 ischemic and 12,817 hemorrhagic stroke cases | <1 year (sepsis) | <15 days: OR=28.4, 95% CI=200-40.1 16-30 days: OR=4.0, 95% CI=2.86-5.60 31-90 days: OR=2.53, 95% CI=2.07-3.09 91-180 days: OR=2.46, 95% CI=2.03-2.99 181-365 days: OR=2.59, 95% CI=2.20-3.06 | |
| Boehme et al. ⁷⁹ | Case-crossover; USA; California State Inpatient Database | 36,975 ischemic stroke cases | <1 year (influenza-like illness) | <15 days: OR=2.83, 95% CI=1.86-4.47 16-30 days: OR=1.73, 95% CI=1.01-3.02 31-60 days: OR=1.68, 95% CI=1.13-2.51 61-90 days: OR=1.05, 95% CI=0.67-1.64 91-180 days: OR=1.23, 95% CI=0.95-1.59 | |
| Sebastian et al. ⁸⁰ | Case-crossover; USA; New York State Inpatient Databases and Emergency Department Databases | 152,356 acute ischemic stroke cases | <1 year as control period | Different infection types (skin infection, UTI, septicemia, abdominal, and respiratory) were significantly associated with ischemic stroke | Strongest association with ischemic stroke was for UTI (OR=5.32, 95% CI=3.69-7.68) within the 7-day window |

Table 1. Studies of recent infections and ischemic stroke (continued)

| Study | Design and location | Population | Interval between preceding infection and stroke | Association between infection and ischemic stroke | Comments |
|----------------------------|---|---|--|--|--|
| Pak et al. ⁸¹ | Self-controlled case series; Australia; single center | 4,557 patients with pneumonia | <2 weeks as risk interval and the control interval as 1 year before and 1 year after the risk interval | RIR=4.94, 95% CI=1.12–21.78 | |
| Ekker et al. ⁸² | Case-crossover; Netherlands; multicenter | 1,043 ischemic stroke cases and 103 young adults with ICH | <1 day (fever or flu-like disease) | Fever: RR= 15.1, 95% CI=9.0–25.5 Flu-like disease: RR=15.2, 95% CI=9.7–23.8 | Fever and flu-like illness as trigger factors for cryptogenic stroke, large-artery disease, cardioembolic stroke, and stroke of other determined cause, but not small-vessel disease |

*Noninfectious inflammatory events were included. aHR; adjusted HR; aOR; adjusted OR; CI, confidence interval; HR, hazard ratio; ICH, intracerebral hemorrhage; m/c, most common; OR, odds ratio; RIR, relative incidence rate; RR, relative risk; TIA, transient ischemic attack; UTI, urinary tract infection.

flammation and coagulation. Elevated fibrin D-dimer, lactate dehydrogenase, erythrocyte sedimentation rate, and CRP were demonstrated in COVID-19-associated ischemic stroke.^{100,101} Some authors have asserted that increased fibrin D-dimer and aPL are associated with COVID-19-related stroke.^{102,103} Fibrin D-dimer as a marker of COVID-19 coagulopathy is a notable predictor of poor outcome and mortality.¹⁰⁴

Other respiratory infections such as influenza have long been associated with an increased stroke risk. A retrospective cohort study found that 31 of 1,916 patients with COVID-19 (1.6%, 95% CI=1.1%–2.3%) at two academic hospital centers had an ischemic stroke, while only 3 of 1,486 influenza patients (0.2%, 95% CI=0.0%–0.6%) had an ischemic stroke.¹⁰⁵ The stroke risk with COVID-19 infection remained markedly higher than with influenza infection after adjusting for several confounding factors including vascular risk factors (OR=7.6, 95% CI=2.3–25.2).

Based on a systematic review of 10 studies, Fridman et al.¹⁰⁶ reported that stroke occurred in 1.8% (95% CI=0.9%–3.7%) of COVID-19 patients. They also reported that large-vessel occlusions were common across all age groups and that the in-hospital mortality rate was higher in patients with stroke related to COVID-19 (34.4%). In-hospital mortality was also more common in older patients, especially in those with multiple comorbidities and severe respiratory symptoms. Underreporting that can occur due to mild cases not being hospitalized or severe cases being wrongly attributed to non-COVID-19 causes might result in underestimation of the risk of stroke due to COVID-19. A preventive effect of the COVID-19 vaccine on thrombotic events including ischemic stroke was found in a Korean nationwide registry-based study.¹⁰⁷ Acute ischemic stroke can also occur as a rare complication of the COVID-19 vaccine via thrombotic thrombocytopenia, especially for virus vector vaccines.¹⁰⁸

THERAPEUTICS FOR INFECTION-ASSOCIATED STROKE

Infection-associated stroke may develop during or after a localized or systemic infection. However, even when the causality of a prior or current infection in the induction of acute stroke is suspected at the time of disease presentation, it is unlikely that an emergency-care provider would make special or atypical personalized diagnostic and treatment decisions. In addition, clinical trials,¹⁰⁹ observational studies,^{110,111} and meta-analyses^{112,113} have not proved the efficacy of specific treatments such as prophylactic antibiotics. At present, there are no data available from controlled clinical trials to suggest that published diagnostic and treatment protocols would improve patient outcomes in infection-associated acute

stroke. This may be attributed to the great heterogeneity of this patient population in terms of the types of infection (e.g., acute, chronic, active, previous, pathogens, local, and systemic), types of stroke, and the short window of opportunity for evaluating specific infection-related diagnostic considerations before emergency treatment is started to reduce or prevent irreversible brain injury. In addition, there are no established, high-quality data available to demonstrate the efficacy and safety of using fibrinolytic and other antithrombotic treatments in the presence of an active infection; however, there are also no high-quality data to prove the opposite. Therefore, the current treatment practice likely ignores whether an infection, past or present, has played a causal (etiological) role in the development of stroke in a particular patient. Based on review of the limited clinical trial literature in this topic, there appears to be no data to suggest that treatment of infection-associated stroke should be considered a separate category.

Some medical research over the past few decades have focused on the development of mechanistically novel and theoretically safe(r) antithrombotic and anti-inflammatory/cytoprotective agents. Examples of this new direction include enhancement or modification of the antithrombotic and/or cytoprotective protein C system or therapeutic anticoagulation by inhibiting the contact activation of blood.¹¹⁴⁻¹²⁰ Immunomodulatory drugs can be considered as a new treat-

ment option in that neuroinflammatory response plays an important role in infection-related stroke. Targeting specific components of the inflammatory cascade has shown positive results in several randomized controlled studies. Interleukin-1 (IL-1) family has been considered important mediators of the innate immune response.¹²¹ Of them, IL-1 α , IL-1 β and IL-1 receptor antagonist (IL-1Ra) have been major targets for the development of new therapies. The Canakinumab Anti-inflammatory Thrombosis Outcomes Study (CANTOS) showed that an anti-IL-1 β antibody in patients at high risk for atherosclerotic events can decrease cardiovascular events by 15%.¹²² In the VCU-ART2 and VCU-ART3 (Virginia Commonwealth University-Anakinra Remodeling Trials 2 and 3, respectively),^{123,124} anakinra, a recombinant human IL-1Ra, was reported to reduce systemic inflammation and the risk of the composite endpoint of death or heart failure in patients with acute myocardial infarction; it also reduced plasma inflammatory markers including interleukin-6 and CRP in two randomized controlled trials.^{125,126} Regarding ischemic stroke, however, the beneficial effect on clinical outcomes was observed in only one study.¹²⁵ This implies that the clinical application of these materials can be difficult due to the dual role of neuroinflammation from injury to repair after ischemic damage.¹²⁷ There have also been approaches to alleviate inflammation. In two randomized controlled trials, low-

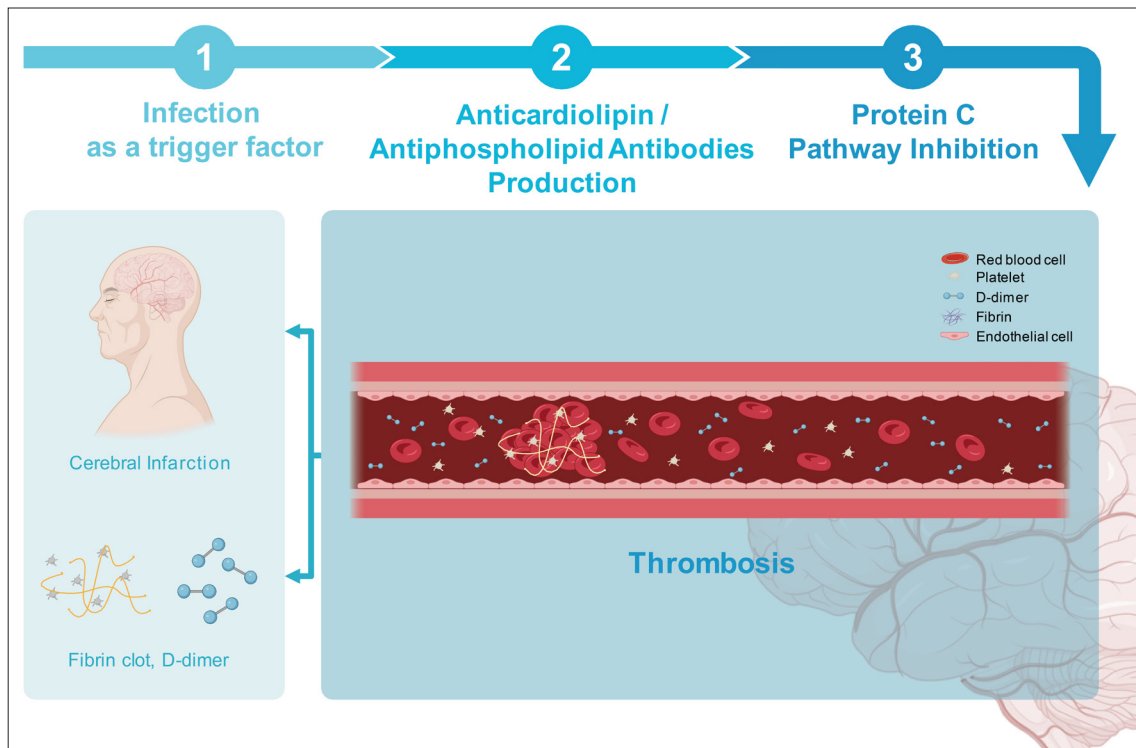


Fig. 2. Proposed pathway for ischemic stroke provoked by infection. In this mechanistic pathway, infections generate antibodies directed against cardiolipin or phospholipid, which then impair the protein C system leading to thrombosis, brain infarction, and subsequent generation of fibrin D-dimer.

dose colchicine, an old drug with new potential uses, reduced recurrent vascular events in patients with coronary artery disease.^{128,129} There is hope that these treatments can be applied to infection-related stroke.

CONCLUSION

There remains a critical question for stroke neurology regarding the nature of the relationship between infection and stroke. That question is: When is an infection that precedes a stroke acting as a trigger for the cerebrovascular event? Alternatively, when is an infection preceding a stroke simply an incidental finding and of no pathogenic significance? At the present time, there is no definitive way to make this distinction. Moreover, there are additional aspects that require analysis, such as determining associations of stroke subtypes with infection, identifying specific infectious organisms causing stroke, and delineating mechanisms of the stroke–infection relationship based on stroke subtypes.

The most likely answer to this question requires the establishment of confirmed biomarkers for infections relevant to the pathogenesis of a specific stroke. And while there are no such established biomarkers, there are some plausible candidates that have emerged from studies performed in the early 1990's to the era of COVID-19. The most-notable candidates for identifying the pathogenic infection preceding stroke are fibrin D-dimer and aCL/aPL.

Ameriso et al.²⁵ first identified elevated levels of fibrin D-dimer and aCL as biomarkers of infection-associated ischemic stroke, and some studies during the COVID-19 pandemic have tended to confirm this association.¹³⁰⁻¹³⁵ Given the demonstrable effects of aPL on the endogenous protein C system, a plausible scenario for infection-triggering stroke implicates antiphospholipid antibody-mediated inhibition of the anticoagulation effects of the protein C system. The consequence of protein C inhibition would then manifest itself as fibrin generation producing thrombo-occlusion of the brain vasculature, leading to infarction with subsequent clot lysis producing elevated levels of fibrin D-dimer (Fig. 2). At the present time, this scenario remains the most-promising conceptual framework for identifying the pathogenicity of infections related to ischemic stroke. However, the specificity of the combination of elevated fibrin D-dimer and aCL has yet to be demonstrated. More-extensive confirmation of these biomarkers will pave the way for targeted therapeutics of the challenging syndrome of infection-associated stroke.

Availability of Data and Material

Data sharing is not applicable to this article as no datasets were generated or analyzed during the study.

ORCID iDs

Jin-Man Jung <https://orcid.org/0000-0003-0557-6431>
 András Gruber <https://orcid.org/0000-0001-6212-2247>
 Peter Heseltine <https://orcid.org/0000-0001-6172-2216>
 Sebastián F. Ameriso <https://orcid.org/0000-0001-8933-0847>
 Mark J. Fisher <https://orcid.org/0000-0001-9802-8826>

Author Contributions

Conceptualization: all authors. Funding acquisition: Jin-Man Jung. Investigation: Jin-Man Jung. Supervision: Mark J. Fisher. Writing—original draft: all authors. Writing—review & editing: all authors.

Conflicts of Interest

AG is an employee and shareholder of Aronora, Inc., a company that has been developing antithrombotic agents.

JM Jung received honoraria for lectures from Pfizer, Hanmi, Otsuka, Yuhan, and Korea United Pharmaceutical Co., Ltd. All remaining authors have declared no conflicts of interest.

Funding Statement

This study was supported by the Basic Science Research Program through the National Research Foundation of Korea (NRF) funded by the Ministry of Science and ICT (NRF-2020R1C1C1009294).

Acknowledgements

The authors thank Dr. Hernan Chaves for providing Fig. 1 and Dr. Jaeeun Sim for assistance with Fig. 2.

REFERENCES

- Jillella DV, Wisco DR. Infectious causes of stroke. *Curr Opin Infect Dis* 2019;32:285-292.
- Zuber V, Cameron A, Myserlis EP, Bottolo L, Fernandez-Cadenas I, Burgess S, et al. Leveraging genetic data to elucidate the relationship between COVID-19 and ischemic stroke. *J Am Heart Assoc* 2021;10:e022433.
- Bahouth MN, Venkatesan A. Acute viral illnesses and ischemic stroke: pathophysiological considerations in the era of the COVID-19 pandemic. *Stroke* 2021;52:1885-1894.
- Gauchel N, Krauel K, Hamad MA, Bode C, Duerschmied D. Thromboinflammation as a driver of venous thromboembolism. *Hämostasologie* 2021;41:428-432.
- Fourie CMT, Schutte AE, Smith W, Kruger A, van Rooyen JM. Endothelial activation and cardiometabolic profiles of treated and never-treated HIV infected Africans. *Atherosclerosis* 2015;240:154-160.
- Marchenko V, Zelinskaya I, Toropova Y, Shmakova T, Podyacheva E, Lioznov D, et al. Influenza a virus causes histopathological changes and impairment in functional activity of blood vessels in different vascular beds. *Viruses* 2022;14:396.
- Deravi N, Poudineh M, Pirzadeh M, Yavarpour-Bali H, Mehrabi H, Erabi G, et al. The yin and yang of toll-like receptors in endothelial dysfunction. *Int Immunopharmacol* 2022;108:108768.
- Schrottmaier WC, Schmuckenschlager A, Pirabe A, Assinger A. Platelets in viral infections - brave soldiers or Trojan horses. *Front Immunol* 2022;13:856713.
- Hattori Y, Hattori K, Machida T, Matsuda N. Vascular endotheliitis associated with infections: its pathogenetic role and therapeutic implication. *Biochem Pharmacol* 2022;197:114909.
- Ince C, Mayeux PR, Nguyen T, Gomez H, Kellum JA, Ospina-Tascón GA, et al. The endothelium in sepsis. *Shock* 2016;45:259-270.
- Conway EM. Thrombomodulin and its role in inflammation. *Semin Immunopathol* 2012;34:107-125.
- Eling M, Stephens AC, Oragui EE, Rivers RP, Levin M. Tissue factor pathway inhibitor (TFPI) levels in the plasma and urine of children

- with meningococcal disease. *Thromb Haemost* 2001;85:240-244.
13. Macko RF, Ameriso SF, Gruber A, Griffin JH, Fernandez JA, Barndt R, et al. Impairments of the protein C system and fibrinolysis in infection-associated stroke. *Stroke* 1996;27:2005-2011.
 14. Levi M, van der Poll T. Inflammation and coagulation. *Crit Care Med* 2010;38(2 Suppl):S26-S34.
 15. Levi M, van der Poll T, Büller H. Bidirectional relation between inflammation and coagulation. *Circulation* 2004;109:2698-2704.
 16. Goeijenbier M, van Wissen M, van de Weg C, Jong E, Gerdes VEA, Meijers JCM, et al. Review: viral infections and mechanisms of thrombosis and bleeding. *J Med Virol* 2012;84:1680-1696.
 17. Fisher MJ. Brain regulation of thrombosis and hemostasis: from theory to practice. *Stroke* 2013;44:3275-3285.
 18. Ishii H, Salem HH, Bell CE, Laposata EA, Majerus PW. Thrombomodulin, an endothelial anticoagulant protein, is absent from the human brain. *Blood* 1986;67:362-365.
 19. Wong VL, Hofman FM, Ishii H, Fisher M. Regional distribution of thrombomodulin in human brain. *Brain Res* 1991;556:1-5.
 20. Tran ND, Correale J, Schreiber SS, Fisher M. Transforming growth factor-beta mediates astrocyte-specific regulation of brain endothelial anticoagulant factors. *Stroke* 1999;30:1671-1678.
 21. Macko RF, Killewich LA, Fernández JA, Cox DK, Gruber A, Griffin JH. Brain-specific protein C activation during carotid artery occlusion in humans. *Stroke* 1999;30:542-545.
 22. Tran ND, Schreiber SS, Fisher M. Astrocyte regulation of endothelial tissue plasminogen activator in a blood-brain barrier model. *J Cereb Blood Flow Metab* 1998;18:1316-1324.
 23. Hultman K, Björklund U, Hansson E, Jern C. Potentiating effect of endothelial cells on astrocytic plasminogen activator inhibitor type-1 gene expression in an in vitro model of the blood-brain barrier. *Neuroscience* 2010;166:408-415.
 24. Syrjänen J, Vaarala O, Iivanainen M, Palosuo T, Valtonen VV, Aho K. Anticardiolipin response and its association with infections in young and middle-aged patients with cerebral infarction. *Acta Neurol Scand* 1988;78:381-386.
 25. Ameriso SF, Wong VL, Quismorio FP Jr, Fisher M. Immunohematologic characteristics of infection-associated cerebral infarction. *Stroke* 1991;22:1004-1009.
 26. de Laat B, Pengo V, Pabinger I, Musial J, Voskuyl AE, Bultink IEM, et al. The association between circulating antibodies against domain I of beta2-glycoprotein I and thrombosis: an international multicenter study. *J Thromb Haemost* 2009;7:1767-1773.
 27. Abdel-Wahab N, Lopez-Olivo MA, Pinto-Patarroyo GP, Suarez-Almazor ME. Systematic review of case reports of antiphospholipid syndrome following infection. *Lupus* 2016;25:1520-1531.
 28. Martirosyan A, Aminov R, Manukyan G. Environmental triggers of autoreactive responses: induction of antiphospholipid antibody formation. *Front Immunol* 2019;10:1609.
 29. Garcia D, Erkan D. Diagnosis and management of the antiphospholipid syndrome. *N Engl J Med* 2018;378:2010-2021.
 30. Stearns-Kurosawa DJ, Kurosawa S, Mollica JS, Ferrell GL, Esmon CT. The endothelial cell protein C receptor augments protein C activation by the thrombin-thrombomodulin complex. *Proc Natl Acad Sci U S A* 1996;93:10212-10216.
 31. Müller-Calleja N, Hollerbach A, Royce J, Ritter S, Pedrosa D, Madhusudhan T, et al. Lipid presentation by the protein C receptor links coagulation with autoimmunity. *Science* 2021;371:eabc0956.
 32. Grau AJ, Bugge F, Steichen-Wiehn C, Heindl S, Banerjee T, Seitz R, et al. Clinical and biochemical analysis in infection-associated stroke. *Stroke* 1995;26:1520-1526.
 33. Somer T, Finegold SM. Vasculitides associated with infections, immunization, and antimicrobial drugs. *Clin Infect Dis* 1995;20:1010-1036.
 34. Dal Canto AJ, Virgin HW IV. Animal models of infection-mediated vasculitis: implications for human disease. *Int J Cardiol* 2000;75 Suppl 1:S37-S45.
 35. Gonzalez H, Koralknik IJ, Marra CM. Neurosyphilis. *Semin Neurol* 2019;39:448-455.
 36. Ferreira MG, Scavasine VC, Breda GL, de Almeida BMM, Zétola VHF, Lange MC. Small vessel occlusion and syphilis in patients with first-ever ischemic stroke. *Arq Neuropsiquiatr* 2021;79:103-106.
 37. Arshad A, Dayal S, Gadhe R, Mawley A, Shin K, Tellez D, et al. Analysis of tuberculosis meningitis pathogenesis, diagnosis, and treatment. *J Clin Med* 2020;9:2962.
 38. Tai MLS, Viswanathan S, Rahmat K, Nor HM, Kadir KAA, Goh KJ, et al. Cerebral infarction pattern in tuberculous meningitis. *Sci Rep* 2016;6:38802.
 39. Long B, Koyfman A. Infectious endocarditis: an update for emergency clinicians. *Am J Emerg Med* 2018;36:1686-1692.
 40. Mishra A, Sahu KK, Abraham BM, Sargent J, Kranis MJ, George SV, et al. Predictors, patterns and outcomes following infective endocarditis and stroke. *Acta Biomed* 2022;93:e2022203.
 41. Majeed H, Ahmad F. Mycotic Aneurysm. [Updated 2023 Jul 10]. In: StatPearls [Internet]. Treasure Island (FL): StatPearls Publishing; 2023 Jan-. [cited 2023 Aug 23]. Available from: <https://www.ncbi.nlm.nih.gov/books/NBK560736/>.
 42. Nagel MA, Traktinskiy I, Azarkh Y, Kleinschmidt-DeMasters B, Hedley-Whyte T, Russman A, et al. Varicella zoster virus vasculopathy: analysis of virus-infected arteries. *Neurology* 2011;77:364-370.
 43. Nagel MA, Gildea D. Update on varicella zoster virus vasculopathy. *Curr Infect Dis Rep* 2014;16:407.
 44. Gildea D, White T, Khmeleva N, Heintzman A, Choe A, Boyer PJ, et al. Prevalence and distribution of VZV in temporal arteries of patients with giant cell arteritis. *Neurology* 2015;84:1948-1955.
 45. Tyler KL. Acute viral encephalitis. *N Engl J Med* 2018;379:557-566.
 46. Modi S, Mahajan A, Dharaiya D, Varelas P, Mitsias P. Burden of herpes simplex virus encephalitis in the United States. *J Neurol* 2017; 264:1204-1208.
 47. Hauer L, Pikija S, Schulte EC, Sztrihai LK, Nardone R, Sellner J. Cerebrovascular manifestations of herpes simplex virus infection of the central nervous system: a systematic review. *J Neuroinflammation* 2019;16:19.
 48. Lebedeva AM, Shpektor AV, Vasilieva EY, Margolis LB. Cytomegalovirus infection in cardiovascular diseases. *Biochemistry (Mosc)* 2018; 83:1437-1447.
 49. Wang H, Peng G, Bai J, He B, Huang K, Hu X, et al. Cytomegalovirus infection and relative risk of cardiovascular disease (ischemic heart disease, stroke, and cardiovascular death): a meta-analysis of prospective studies up to 2016. *J Am Heart Assoc* 2017;6:e005025.
 50. Ameriso SF, Fridman EA, Leiguarda RC, Sevlever GE. Detection of *Helicobacter pylori* in human carotid atherosclerotic plaques. *Stroke* 2001;32:385-391.
 51. Kuo CC, Shor A, Campbell LA, Fukushi H, Patton DL, Grayston JT. Demonstration of *Chlamydia pneumoniae* in atherosclerotic lesions of coronary arteries. *J Infect Dis* 1993;167:841-849.
 52. Ishizaka Y, Ishizaka N, Takahashi E, Unuma T, Tooda E, Hashimoto H, et al. Association between hepatitis C virus core protein and carotid atherosclerosis. *Circ J* 2003;67:26-30.
 53. Nicholson AC, Hajjar DP. Herpesvirus in atherosclerosis and thrombosis: etiologic agents or ubiquitous bystanders? *Arterioscler Thromb Vasc Biol* 1998;18:339-348.
 54. Razeghian-Jahromi I, Elyaspour Z, Zibaenezhad MJ, Hassanipour S. Prevalence of microorganisms in atherosclerotic plaques of coronary arteries: a systematic review and meta-analysis. *Evid Based Complement Alternat Med* 2022;2022:8678967.
 55. Chen J, Zhu M, Ma G, Zhao Z, Sun Z. *Chlamydia pneumoniae* infection and cerebrovascular disease: a systematic review and meta-analysis. *BMC Neurol* 2013;13:183.
 56. Hsue PY, Deeks SG, Hunt PW. Immunologic basis of cardiovascular disease in HIV-infected adults. *J Infect Dis* 2012;205 Suppl 3(Suppl

- 3):S375-S382.
57. Singer EJ, Valdes-Sueiras M, Commins DL, Yong W, Carlson M. HIV stroke risk: evidence and implications. *Ther Adv Chronic Dis* 2013;4:61-70.
 58. Bogorodskaya M, Chow FC, Triant VA. Stroke in HIV. *Can J Cardiol* 2019;35:280-287.
 59. Spagnolo-Allende A, Gutierrez J. Role of brain arterial remodeling in HIV-associated cerebrovascular outcomes. *Front Neurol* 2021;12:593605.
 60. Gutierrez J, Goldman J, Dwork AJ, Elkind MSV, Marshall RS, Morgello S. Brain arterial remodeling contribution to nonembolic brain infarcts in patients with HIV. *Neurology* 2015;85:1139-1145.
 61. Montecucco F, Carbone F. Clinical relevance of adverse intracerebral artery remodeling in patients with HIV. *Neurology* 2015;85:1098-1099.
 62. George P, Ramiro JI, Gomes JA, Newey CR, Bhimraj A. Central nervous system fungal infection-related stroke: a descriptive study of mold and yeast-associated ischemic stroke. *J Stroke Cerebrovasc Dis* 2020;29:104759.
 63. Grau AJ, Urbanek C, Palm F. Common infections and the risk of stroke. *Nat Rev Neurol* 2010;6:681-694.
 64. Syrjänen J, Valtonen VV, Iivanainen M, Kaste M, Huttunen JK. Preceding infection as an important risk factor for ischaemic brain infarction in young and middle aged patients. *Br Med J (Clin Res Ed)* 1988;296:1156-1160.
 65. Grau AJ, Bugge F, Heindl S, Steichen-Wiehn C, Banerjee T, Mairwald M, et al. Recent infection as a risk factor for cerebrovascular ischemia. *Stroke* 1995;26:373-379.
 66. Bova IY, Bornstein NM, Korczyn AD. Acute infection as a risk factor for ischemic stroke. *Stroke* 1996;27:2204-2206.
 67. Macko RF, Ameriso SF, Barndt R, Clough W, Weiner JM, Fisher M. Precipitants of brain infarction. Roles of preceding infection/inflammation and recent psychological stress. *Stroke* 1996;27:1999-2004.
 68. Grau AJ, Bugge F, Becher H, Zimmermann E, Spiel M, Fent T, et al. Recent bacterial and viral infection is a risk factor for cerebrovascular ischemia: clinical and biochemical studies. *Neurology* 1998;50:196-203.
 69. Nagaraja D, Christopher R, Tripathi M, Kumar MV, Valli ER, Patil SA. Preceding infection as a risk factor of stroke in the young. *J Assoc Physicians India* 1999;47:673-675.
 70. Becher H, Grau A, Steindorf K, Bugge F, Hacke W. Previous infection and other risk factors for acute cerebrovascular ischaemia: attributable risks and the characterisation of high risk groups. *J Epidemiol Biostat* 2000;5:277-283.
 71. Nencini P, Sarti C, Innocenti R, Pracucci G, Inzitari D. Acute inflammatory events and ischemic stroke subtypes. *Cerebrovasc Dis* 2003;15:215-221.
 72. Paganini-Hill A, Lozano E, Fischberg G, Perez Barreto M, Rajamani K, Ameriso SF, et al. Infection and risk of ischemic stroke: differences among stroke subtypes. *Stroke* 2003;34:452-457.
 73. Zurrú MC, Alonzo C, Brescacián L, Romano M, Cámara LA, Waisman G, et al. Recent respiratory infection predicts atherothrombotic stroke: case-control study in a Buenos Aires healthcare system. *Stroke* 2009;40:1986-1990.
 74. Elkind MSV, Carty CL, O'Meara ES, Lumley T, Lefkowitz D, Kronmal RA, et al. Hospitalization for infection and risk of acute ischemic stroke: the Cardiovascular Health Study. *Stroke* 2011;42:1851-1856.
 75. Dalager-Pedersen M, Søgaard M, Schønheyder HC, Nielsen H, Thomsen RW. Risk for myocardial infarction and stroke after community-acquired bacteremia: a 20-year population-based cohort study. *Circulation* 2014;129:1387-1396.
 76. Consoli D, Vidale S, Aguglia U, Bassi P, Cavallini A, Galati F, et al. Previous infection and the risk of ischaemic stroke in Italy: the IN2 study. *Eur J Neurol* 2015;22:514-519.
 77. Cowan LT, Alonso A, Pankow JS, Folsom AR, Rosamond WD, Gottesman RF, et al. Hospitalized infection as a trigger for acute ischemic stroke: the Atherosclerosis Risk in Communities study. *Stroke* 2016;47:1612-1617.
 78. Boehme AK, Ranawat P, Luna J, Kamel H, Elkind MSV. Risk of acute stroke after hospitalization for sepsis: a case-crossover study. *Stroke* 2017;48:574-580.
 79. Boehme AK, Luna J, Kulick ER, Kamel H, Elkind MSV. Influenza-like illness as a trigger for ischemic stroke. *Ann Clin Transl Neurol* 2018;5:456-463.
 80. Sebastian S, Stein LK, Dharmoon MS. Infection as a stroke trigger. *Stroke* 2019;50:2216-2218.
 81. Pak A, Eisen DP, McBryde ES, Adegbeye OA. Hospitalisation for lower respiratory tract infection is associated with an increased incidence of acute myocardial infarction and stroke in tropical Northern Australia. *Sci Rep* 2021;11:6826.
 82. Ekker MS, Verhoeven JI, Rensink KML, Schellekens MMI, Boot EM, van Alebeek ME, et al. Trigger factors for stroke in young adults: a case-crossover study. *Neurology* 2023;100:e49-e61.
 83. Hills NK, Sidney S, Fullerton HJ. Timing and number of minor infections as risk factors for childhood arterial ischemic stroke. *Neurology* 2014;83:890-897.
 84. Fullerton HJ, Hills NK, Elkind MSV, Dowling MM, Wintermark M, Glaser CA, et al. Infection, vaccination, and childhood arterial ischemic stroke: results of the VIPS study. *Neurology* 2015;85:1459-1466.
 85. Yang Q, George MG, Chang A, Tong X, Merritt R, Hong Y. Effect of herpes zoster vaccine and antiviral treatment on risk of ischemic stroke. *Neurology* 2020;95:e708-e717.
 86. MacDonald SE, Dover DC, Hill MD, Kirton A, Simmonds KA, Svenson LW. Is varicella vaccination associated with pediatric arterial ischemic stroke? A population-based cohort study. *Vaccine* 2018;36:2764-2767.
 87. Vila-Corcoles A, Ochoa-Gondar O, Rodriguez-Blanco T, de Diego C, Satue E; EPIVAC Study Group. Ineffectiveness of pneumococcal vaccination in cardiovascular prevention: the CAPAMIS study. *JAMA Intern Med* 2013;173:1918-1920.
 88. Johnstone J, Loeb M, Teo KK, Gao P, Dyal L, Liu L, et al. Influenza vaccination and major adverse vascular events in high-risk patients. *Circulation* 2012;126:278-286.
 89. Lavallée PC, Labreuche J, Fox KM, Lavados P, Mattle H, Steg PG, et al. Influenza vaccination and cardiovascular risk in patients with recent TIA and stroke. *Neurology* 2014;82:1905-1913.
 90. Lee KR, Bae JH, Hwang IC, Kim KK, Suh HS, Ko KD. Effect of influenza vaccination on risk of stroke: a systematic review and meta-analysis. *Neuroepidemiology* 2017;48:103-110.
 91. Rodríguez-Martín S, Barreira-Hernández D, Gil M, García-Lledó A, Izquierdo-Esteban L, De Abajo F. Influenza vaccination and risk of ischemic stroke: a population-based case-control study. *Neurology* 2022;99:e2149-e2160.
 92. South K, McCulloch L, McColl BW, Elkind MSV, Allan SM, Smith C. Preceding infection and risk of stroke: an old concept revived by the COVID-19 pandemic. *Int J Stroke* 2020;15:722-732.
 93. Netland J, Meyerholz DK, Moore S, Cassell M, Perlman S. Severe acute respiratory syndrome coronavirus infection causes neuronal death in the absence of encephalitis in mice transgenic for human ACE2. *J Virol* 2008;82:7264-7275.
 94. Baig AM, Khaleeq A, Ali U, Syeda H. Evidence of the COVID-19 virus targeting the CNS: tissue distribution, host-virus interaction, and proposed neurotropic mechanisms. *ACS Chem Neurosci* 2020;11:995-998.
 95. Andrews MG, Mukhtar T, Eze UC, Simoneau CR, Ross J, Parikshak N, et al. Tropism of SARS-CoV-2 for human cortical astrocytes. *Proc Natl Acad Sci U S A* 2022;119:e2122236119.
 96. Varga Z, Flammer AJ, Steiger P, Haberecker M, Andermatt R, Zinkernagel AS, et al. Endothelial cell infection and endotheliitis in

- COVID-19. *Lancet* 2020;395:1417-1418.
97. Fifi JT, Mocco J. Covid-19 related stroke in young individuals. *Lancet Neurol* 2020;19:713-715.
 98. Behzadifard M, Soleimani M. NETosis and SARS-CoV-2 infection related thrombosis: a narrative review. *Thromb J* 2022;20:13.
 99. Lee MH, Perl DP, Steiner J, Pasternack N, Li W, Maric D, et al. Neurovascular injury with complement activation and inflammation in COVID-19. *Brain* 2022;145:2555-2568.
 100. Esenwa C, Cheng NT, Luna J, Willey J, Boehme AK, Kirchoff-Torres K, et al. Biomarkers of coagulation and inflammation in COVID-19-associated ischemic stroke. *Stroke* 2021;52:e706-e709.
 101. Goyal N, Sodani AK, Jain R, Ram H. Do elevated levels of inflammatory biomarkers predict the risk of occurrence of ischemic stroke in SARS-CoV2?: an observational study. *J Stroke Cerebrovasc Dis* 2021;30:106063.
 102. Beyrouiti R, Adams ME, Benjamin L, Cohen H, Farmer SF, Goh YY, et al. Characteristics of ischaemic stroke associated with COVID-19. *J Neurol Neurosurg Psychiatry* 2020;91:889-891.
 103. Zhang Y, Xiao M, Zhang S, Xia P, Cao W, Jiang W, et al. Coagulopathy and antiphospholipid antibodies in patients with Covid-19. *N Engl J Med* 2020;382:e38.
 104. Poudel A, Poudel Y, Adhikari A, Aryal BB, Dangol D, Bajracharya T, et al. D-dimer as a biomarker for assessment of COVID-19 prognosis: D-dimer levels on admission and its role in predicting disease outcome in hospitalized patients with COVID-19. *PLoS One* 2021;16:e0256744.
 105. Merkler AE, Parikh NS, Mir S, Gupta A, Kamel H, Lin E, et al. Risk of ischemic stroke in patients with coronavirus disease 2019 (COVID-19) vs patients with influenza. *JAMA Neurol* 2020;77:1-7.
 106. Fridman S, Bres Bullrich M, Jimenez-Ruiz A, Costantini P, Shah P, Just C, et al. Stroke risk, phenotypes, and death in COVID-19: systematic review and newly reported cases. *Neurology* 2020;95:e3373-e3385.
 107. Kim YE, Huh K, Park YJ, Peck KR, Jung J. Association between vaccination and acute myocardial infarction and ischemic stroke after COVID-19 infection. *JAMA* 2022;328:887-889.
 108. Kolahchi Z, Khanmirzaei M, Mowla A. Acute ischemic stroke and vaccine-induced immune thrombotic thrombocytopenia post COVID-19 vaccination; a systematic review. *J Neurol Sci* 2022;439:120327.
 109. Kalra L, Irshad S, Hodsoll J, Simpson M, Gulliford M, Smithard D, et al. Prophylactic antibiotics after acute stroke for reducing pneumonia in patients with dysphagia (STROKE-INF): a prospective, cluster-randomised, open-label, masked endpoint, controlled clinical trial. *Lancet* 2015;386:1835-1844.
 110. Kumazawa R, Jo T, Matsui H, Fushimi K, Yasunaga H. Association between angiotensin-converting enzyme inhibitors and post-stroke aspiration pneumonia. *J Stroke Cerebrovasc Dis* 2019;28:104444.
 111. Tziomalos K, Ntaios G, Miyakis S, Papanas N, Xanthis A, Agapakis D, et al. Prophylactic antibiotic treatment in severe acute ischemic stroke: the Antimicrobial chemoprophylaxis for Ischemic Stroke In MaceDonIa-Thrace Study (ARISTEIDIS). *Intern Emerg Med* 2016;11:953-958.
 112. Lin SP, Long YM, Chen XH. The effects of statins on infections after stroke or transient ischemic attack: a meta-analysis. *PLoS One* 2015;10:e0130071.
 113. Ndakotsu A, Myneni R, Iqbal A, Grewal AS, Abubacker AP, Vivekanandan G, et al. Prophylactic antibiotics, the mediator of post-stroke infections: a systematic review. *Cureus* 2021;13:e15055.
 114. Griffin JH, Zlokovic B, Fernández JA. Activated protein C: potential therapy for severe sepsis, thrombosis, and stroke. *Semin Hematol* 2002;39:197-205.
 115. Lyden P, Pryor KE, Coffey CS, Cudkowicz M, Conwit R, Jadhav A, et al. Final results of the RHAPSODY trial: a multi-center, phase 2 trial using a continual reassessment method to determine the safety and tolerability of 3K3A-APC, a recombinant variant of human activated protein C, in combination with tissue plasminogen activator, mechanical thrombectomy or both in moderate to severe acute ischemic stroke. *Ann Neurol* 2019;85:125-136.
 116. Berny-Lang MA, Hurst S, Tucker EI, Pelc LA, Wang RK, Hurn PD, et al. Thrombin mutant W215A/E217A treatment improves neurological outcome and reduces cerebral infarct size in a mouse model of ischemic stroke. *Stroke* 2011;42:1736-1741.
 117. Leung PY, Hurst S, Berny-Lang MA, Verbout NG, Gailani D, Tucker EI, et al. Inhibition of factor XII-mediated activation of factor XI provides protection against experimental acute ischemic stroke in mice. *Transl Stroke Res* 2012;3:381-389.
 118. Lorentz CU, Tucker EI, Verbout NG, Shatzel JJ, Olson SR, Markway BD, et al. The contact activation inhibitor AB023 in heparin-free hemodialysis: results of a randomized phase 2 clinical trial. *Blood* 2021;138:2173-2184.
 119. Hsu C, Hutt E, Bloomfield DM, Gailani D, Weitz JI. Factor XI inhibition to uncouple thrombosis from hemostasis: JACC review topic of the week. *J Am Coll Cardiol* 2021;78:625-631.
 120. Kleinschnitz C, Stoll G, Bendszus M, Schuh K, Pauer HU, Burfeind P, et al. Targeting coagulation factor XII provides protection from pathological thrombosis in cerebral ischemia without interfering with hemostasis. *J Exp Med* 2006;203:513-518.
 121. Rock KL, Latz E, Ontiveros F, Kono H. The sterile inflammatory response. *Annu Rev Immunol* 2010;28:321-342.
 122. Ridker PM, Everett BM, Thuren T, MacFadyen JG, Chang WH, Ballantyne C, et al. Antiinflammatory therapy with canakinumab for atherosclerotic disease. *N Engl J Med* 2017;377:1119-1131.
 123. Abbate A, Van Tassel BW, Biondi-Zoccai G, Kontos MC, Grizzard JD, Spillman DW, et al. Effects of interleukin-1 blockade with anakinra on adverse cardiac remodeling and heart failure after acute myocardial infarction [from the Virginia Commonwealth University-Anakinra Remodeling Trial (2) (VCU-ART2) pilot study]. *Am J Cardiol* 2013;111:1394-1400.
 124. Abbate A, Trankle CR, Buckley LF, Lipinski MJ, Appleton D, Kadariya D, et al. Interleukin-1 blockade inhibits the acute inflammatory response in patients with ST-segment-elevation myocardial infarction. *J Am Heart Assoc* 2020;9:e014941.
 125. Emsley HCA, Smith CJ, Georgiou RF, Vail A, Hopkins SJ, Rothwell NJ, et al. A randomised phase II study of interleukin-1 receptor antagonist in acute stroke patients. *J Neurol Neurosurg Psychiatry* 2005;76:1366-1372.
 126. Smith CJ, Hulme S, Vail A, Heal C, Parry-Jones AR, Scarth S, et al. SCIL-STROKE (Subcutaneous Interleukin-1 Receptor Antagonist in Ischemic Stroke): a randomized controlled phase 2 trial. *Stroke* 2018;49:1210-1216.
 127. Candelario-Jalil E, Dijkhuizen RM, Magnus T. Neuroinflammation, stroke, blood-brain barrier dysfunction, and imaging modalities. *Stroke* 2022;53:1473-1486.
 128. Nidorf SM, Eikelboom JW, Budgeon CA, Thompson PL. Low-dose colchicine for secondary prevention of cardiovascular disease. *J Am Coll Cardiol* 2013;61:404-410.
 129. Tardif JC, Kouz S, Waters DD, Bertrand OF, Diaz R, Maggioni AP, et al. Efficacy and safety of low-dose colchicine after myocardial infarction. *N Engl J Med* 2019;381:2497-2505.
 130. Tan YK, Goh C, Leow AST, Tambyah PA, Ang A, Yap ES, et al. COVID-19 and ischemic stroke: a systematic review and meta-summary of the literature. *J Thromb Thrombolysis* 2020;50:587-595.
 131. Qi X, Keith KA, Huang JH. COVID-19 and stroke: a review. *Brain Hemorrhages* 2021;2:76-83.
 132. Leal Rato M, Bandeira M, Romão VC, Aguiar de Sousa D. Neurologic manifestations of the antiphospholipid syndrome - an update. *Curr Neurol Neurosci Rep* 2021;21:41.
 133. Mullaguri N, Hepburn M, Gebel JM Jr, Itrat A, George P, Newey CR. COVID-19 disease and hypercoagulability leading to acute ischemic stroke. *Neurohospitalist* 2021;11:131-136.

134. Alharthy A, Faqih F, Balhamar A, Memish ZA, Karakitsos D. Life-threatening COVID-19 presenting as stroke with antiphospholipid antibodies and low ADAMTS-13 activity, and the role of therapeutic plasma exchange: a case series. *SAGE Open Med Case Rep* 2020; 8:2050313X20964089.
135. Lou M, Yuan D, Liao S, Tong L, Li J. Potential mechanisms of cerebrovascular diseases in COVID-19 patients. *J Neurovirol* 2021;27: 35-51.



Discover Generics

Cost-Effective CT & MRI Contrast Agents

 **FRESENIUS
KABI**

[VIEW CATALOG](#)

AJNR

Vessel Wall Thickening and Enhancement in High-Resolution Intracranial Vessel Wall Imaging: A Predictor of Future Ischemic Events in Moyamoya Disease

A. Kathuveetil, P.N. Sylaja, S. Senthilvelan, K. Chandrasekharan, M. Banerjee and B. Jayanand Sudhir

This information is current as of September 30, 2025.

AJNR Am J Neuroradiol 2020, 41 (1) 100-105
doi: <https://doi.org/10.3174/ajnr.A6360>
<http://www.ajnr.org/content/41/1/100>

Vessel Wall Thickening and Enhancement in High-Resolution Intracranial Vessel Wall Imaging: A Predictor of Future Ischemic Events in Moyamoya Disease

 A. Kathuveetil,  P.N. Sylaja,  S. Senthilvelan,  K. Chandrasekharan,  M. Banerjee, and  B. Jayanand Sudhir



ABSTRACT

BACKGROUND AND PURPOSE: Very few data are available with regard to high-resolution intracranial vessel wall imaging characteristics of Moyamoya disease and their relation to ischemic stroke risk. We investigated the high resolution imaging characteristics of MMD and its correlation with recent ischemic events.

MATERIALS AND METHODS: Patients with Moyamoya disease confirmed by DSA, including patients after revascularization, were enrolled. All the patients underwent high-resolution intracranial vessel wall imaging. Vessel wall thickening, enhancement, and the remodeling index of the bilateral distal ICA and proximal MCA were noted. The patients were followed up at 3 months and 6 months after high-resolution intracranial vessel wall imaging and the association of ischemic events with imaging characteristics was assessed.

RESULTS: Twenty-nine patients with Moyamoya disease were enrolled. The median age at symptom onset was 12 years (range, 1–51 years). A total of 166 steno-occlusive lesions were detected by high-resolution intracranial vessel wall imaging. Eleven lesions with concentric wall thickening (6.6%) were noted in 9 patients. Ten concentric contrast-enhancing lesions were observed in 8 patients, of which 3 patients (4 lesions) showed grade II enhancement. The presence of contrast enhancement ($P = .01$) and wall thickening ($P \leq .001$) showed a statistically significant association with ischemic events within 3 months before and after the vessel wall imaging. Grade II enhancement showed a statistically significant ($P = .02$) association with ischemic events within 4 weeks of high-resolution intracranial vessel wall imaging. The mean \pm standard deviation outer diameter of the distal ICA (right, -3.3 ± 0.68 mm; left, 3.4 ± 0.60 mm) and the remodeling index (right, 0.71 ± 0.13 ; left, 0.69 ± 0.13) were lower in Moyamoya disease.

CONCLUSIONS: High-resolution intracranial vessel wall imaging characteristics of concentric wall thickening and enhancement are relatively rare in our cohort of patients with Moyamoya disease. The presence of wall thickening and enhancement may predict future ischemic events in patients with Moyamoya disease.

ABBREVIATIONS: ACA = anterior cerebral artery; HRVWI = high-resolution intracranial vessel wall imaging; MMD = Moyamoya disease; PCA = posterior cerebral artery; SD = standard deviation

Moyamoya disease (MMD) is a rare cerebrovascular disease characterized by progressive steno-occlusive changes at the terminal portion of the ICA associated with the development of a fine basal collateral network.^{1–3} In the routine clinical practice,


particularly in the Asian population where both intracranial atherosclerotic disease and MMD are common and may present with similar angiographic features, clinicians face difficulties in differentiating them, which may delay the appropriate management. High-resolution intracranial vessel wall imaging (HRVWI) has recently been developed as a reliable tool to distinguish MMD from other intracranial vessel pathologies.^{2,4,5} There are few studies that describe concentric vessel wall enhancement that involves the distal ICA and proximal MCA in patients with symptomatic and patients with asymptomatic MMD.^{1,4} On the symptomatic side, concentric enhancement was observed in 82.1% of distal ICAs and 94.1% of proximal MCAs.¹ Also, concentric enhancement of bilateral distal ICAs was observed exclusively in MMD compared with intracranial atherosclerotic disease (53% versus 0%).¹ In addition, one recent study also observed a significant

Received September 12, 2019; accepted after revision October 27.

From the Comprehensive Stroke Care Program (A.K., P.N.S.), Department of Neurology; Departments of Radiology (S.S., K.C.) and Neurosurgery (B.J.S.), Rajiv Gandhi Centre for Biotechnology, Trivandrum, Kerala, India; and Sree Chitra Tirunal Institute for Medical Sciences and Technology (M.B.), Trivandrum, Kerala, India.

This study was funded by Wellcome Trust-Department of Biotechnology (DBT)/India Alliance as part of Research Training Fellowship.

Please address correspondence to P.N. Sylaja, MD, DM, Neurology Comprehensive Stroke, Care Program, Sree Chitra Tirunal Institute for Medical Sciences and Technology, Trivandrum, India 695011; e-mail: sylajpn@hotmail.com; @DrArunKNair

 Indicates open access to non-subscribers at www.ajnr.org

<http://dx.doi.org/10.3174/ajnr.A6360>

association of vessel wall enhancement with cerebral ischemic events in patients with MMD, which suggests the role of inflammation and neovascularization.^{3,6,7} Little is known about the characteristic HRVWI findings and the clinical significance of those findings in MMD. This study sought to investigate the high-resolution imaging characteristics of MMD and their correlation with recent ischemic events in an Indian population.

MATERIALS AND METHODS

Patient Data

Patients with MMD who satisfied the diagnostic criteria were included in the study.⁸ The inclusion criteria were the following: 1) patients with MMD, including postrevascularization cases and those medically stable enough to be in the MR scanner for 30 to 90 minutes without general anesthesia and/or sedation, and 2) good quality images. The exclusion criteria were as follows: 1) potential sources of cardioaortic embolism, 2) $\geq 50\%$ extracranial stenosis, 3) vasculopathies, such as dissection, vasculitis, or Takayasu arteritis, 4) failure of renal function (glomerular filtration rate < 60 mL/min), or 5) contraindications to MR imaging. The criteria for selecting a patient for cerebral revascularization included 1) cerebral infarction or hemorrhage based on the patient's functional disability and 2) Suzuki stage II to IV in angiographic staging. The timing of the operation was at least 4–6 weeks in patients with stroke.

Surgery for a patient who is asymptomatic or has an asymptomatic hemisphere is rarely offered. All the patients provided informed consent, and the study was approved by the institutional ethics committee. The clinical features and demographics of the patients were collected, and the images were reviewed. After HRVWI, the patients were followed up at 3 months and 6 months. They were assessed clinically for new-onset strokes, TIA, and headaches, and for syncope. The association of acute ischemic events with HRVWI characteristics was noted. HRVWI characteristics of the patients who underwent surgical revascularization were noted and the association of imaging findings with ischemic events was analyzed.

HRVWI Protocol

The included subjects underwent pre- and postcontrast HRVWI after obtaining informed consent. HRVWI was performed as per previously published protocol from Sree Chitra Tirunal Institute for Medical sciences and technology, Trivandrum, India on a 3T Discovery system (GE Healthcare, Milwaukee, Wisconsin).⁹ Acquired sequences (corresponding voxel resolution before interpolation, after interpolation) are shown as follows: sagittal Cube (GE Healthcare) T1 ($0.8 \times 0.8 \times 1.4$ mm, $0.3 \times 0.3 \times 1.4$ mm), sagittal Cube T2 ($0.6 \times 0.6 \times 1.2$ mm, $0.3 \times 0.3 \times 1.2$ mm), sagittal Cube proton density ($0.6 \times 0.5 \times 1.2$ mm, $0.3 \times 0.3 \times 1.2$ mm). Interpolation was done by using zero-filling interpolation X 512 (matrix or in-plane) zero-filling interpolation X 2 (section or through-plane). Also, SWI and DWI sequences were also acquired. These sequences eventually resulted in the following scan time for each sequence: sagittal CUBE T1 fat suppressed, 6:49 minutes; sagittal Cube T2, 6:04 minutes; sagittal Cube proton density, 4:28 minutes; and postcontrast sagittal Cube T1 fat suppressed, 6:49 minutes. Postcontrast images were acquired after

30 seconds of intravenous administration of gadoterate meglumine (Dotarem; Guerbet, Aulnay-sous-Bois, France) Guerbet LLC, headquarters located in Princeton, US at a dose of 0.1 mmol/kg body weight.

Image Review

The conventional MR imaging, DSA-Digital subtraction angiography, and HRVWI were read by 1 neuroradiologist S. Senthilvelan and 1 neurologist K. Arun with 4 years of experience and were blinded to the clinical information. All the images were read in consensus. MR images were reviewed for the presence of acute and chronic infarcts, hemorrhages, the pattern of infarcts, and the presence of small-vessel ischemic changes. All patients underwent DSA by using a biplane angiography system (Philips Healthcare, Best, the Netherlands) in an interventional radiology angiography suite. Luminal images were evaluated for the presence of stenosis and/or occlusion that involved distal ICA, proximal MCA, anterior cerebral artery (ACA), posterior cerebral artery (PCA), and basilar artery, and for the type of collaterals. Collaterals were classified as superficial meningeal (leptomeningeal, durocortical) and deep parenchymal (subependymal anastomotic, inner thalamic) networks.¹⁰ The disease was staged in all the patients by using DSA based on the Suzuki staging: 1) narrowing of carotid bifurcation, 2) dilation of the ACA and MCA with initiation of Moyamoya, 3) partial disappearance of the ACA and MCA with intensification of ICA Moyamoya, 4) advanced steno-occlusive changes in the ICA with a small amount of ICA Moyamoya, 5) absence of the ACA and MCA with further reduction of ICA Moyamoya, and 6) complete disappearance of ICA Moyamoya.¹¹

HRVWI was reviewed for wall thickening and wall enhancement that involved the distal ICA, proximal MCA, ACA, PCA, and basilar artery. The remodeling index of only the distal ICA was assessed considering the large caliber and early involvement of distal ICA in MMD:

Wall Thickening. Wall thickening was classified as concentric, eccentric, or no wall thickening by using a precontrast T1 Cube sequence by visual inspection. Concentric wall thickening was defined as a circumferential and uniform thickening, with the width of the thinnest wall segment $\geq 50\%$ of the thickest segment. Eccentric wall thickening was defined as either limited to 1 side of the vessel wall, or, where circumferential enhancement was noted, the thinnest part of the wall enhancement was estimated to be $< 50\%$ of the thickest point.¹²

Contrast Enhancement. The degree of enhancement of vessels was qualitatively graded, depending on its signal intensity on postcontrast T1 images compared with corresponding precontrast images: grade 0, no enhancement; grade I, mild enhancement, the signal intensity of vessel wall is less than that of the pituitary infundibulum; and grade II, strong enhancement, the signal intensity of contrast-enhanced vessel wall is similar to or greater than that of the infundibulum.^{3,13} Enhancement was considered concentric if it was circumferential and uniform (defined specifically as the width of the thinnest wall segment of $\geq 50\%$ of the thickest segment). Eccentric enhancement was defined as

Table 1: Demographic and clinical characteristics (N = 29)

| Patient Characteristics | Results |
|---|------------|
| Sex, n (%) | |
| Males | 17 (58.6) |
| Females | 12 (41.6) |
| Age, n (%) | |
| <18 y | 15 (51.7) |
| ≥18 y | 14 (48.3) |
| Age at first event ^a , median (IQR), y | -12 (6-36) |
| Initial clinical presentation, n (%) | |
| Ischemic stroke | 10 (34.5) |
| Intracerebral bleed | 5 (17.2) |
| TIA | 7 (24.2) |
| Syncope | 1 (3.4) |
| Seizure | 6 (20.7) |
| Recurrent events, n (%) | 22 (75.9) |
| Ischemic stroke | 10 (34.5) |
| Intracranial bleed (intraventricular hemorrhage) | 2 (6.9) |
| Positive family history of MMD, n (%) | 2 (6.9) |
| NIHSS on admission, median (IQR) | 1 (0-3) |
| mRS on admission, median (IQR) | 1 (0-3) |

Note:—IQR indicates interquartile range; mRS, modified Rankin scale.

^aThe mean ± SD interval between the first symptom and HRVWI was 64.7 ± 80.7 months.

either limited to 1 side of the vessel wall (eg, not 360° circumferential enhancement) or, where circumferential enhancement was noted, the thinnest part of the wall enhancement was estimated to be < 50% of the thickest point.^{1,12}

Remodeling Index. The outer diameter of the terminal portion of the ICA was measured by using sagittal T1 fat-suppressed images. The remodeling index was calculated as the outer diameter of a narrowed vessel (measurements between both outer diameters) divided by the caliber of the normal proximal reference vessel¹ (proximal ICA). If the ratio is > 1.05, then it was taken as positive remodeling, <0.95 was negative remodeling, and 0.95–1.05 was normal.¹⁴ The caliber of the vessel was calculated in the sagittal-oblique images perpendicular to the vessel in axial sections.

Statistical Analysis

Continuous-median (interquartile range) or mean standard deviation (SD) categorical variables-percentage (count), respectively. Data comparison of categorical variables was done by using the Fisher exact test. A *P* value of < .05 was considered statistically significant. The data were analyzed by using analytical software SPSS Statistics for Windows, version 21.0 (2012) (IBM, Armonk, New York).

Table 2: Imaging characteristics of patients with MMD

| Characteristic | n (%) (n = 58 Hemispheres) | |
|---------------------------------------|----------------------------|------------------|
| A. MRI | | |
| 1. Pattern of infarct | Acute Infarcts | Chronic Infarcts |
| Watershed | 9 (15.5) | 15 (25.9) |
| Territorial | 3 (5.2) | 5 (8.6) |
| Cortical | 2 (3.4) | 3 (5.2) |
| Isolated subcortical | 1 (1.7) | 2 (3.4) |
| B. DSA | | |
| 1. Laterality (n = 29) | | |
| Bilateral | 27 (93.1) | |
| Unilateral | 2 (6.9) | |
| 2. Vessels involved (n = 166 vessels) | Narrowed | Occluded |
| Distal ICA | 19 (11.4) | 37 (22.2) |
| Proximal MCA | 12 (7.2) | 39 (23.5) |
| Proximal ACA | 17 (10.2) | 25 (15.0) |
| PCA | 8 (4.8) | 1 (0.6) |
| Basilar artery (29 vessels) | 1 (0.6) | 0 (0) |
| 3. Suzuki stage | Right | Left |
| I | 2 (7.1) | 2 (7.1) |
| II | 0 (0) | 1 (3.6) |
| III | 5 (17.9) | 2 (7.1) |
| IV | 4 (14.3) | 10 (35.7) |
| V | 16 (57.1) | 13 (46.4) |
| VI | 1 (3.6) | 0 (0) |
| 4. Collaterals (n = 58 hemispheres) | | |
| Superficial meningeal | | |
| Leptomeningeal | | |
| Anterior | 27 (46.6) | 24 (41.4) |
| Posterior | 21 (36.2) | 20 (34.5) |
| Durocortical | | |
| Anterior | 21 (36.2) | 18 (31.1) |
| Posterior | 3 (5.2) | 5 (8.6) |
| Deep parenchymal | | |
| Subependymal anastomotic | | |
| Anterior | 6 (10.3) | 6 (10.3) |
| Posterior | 5 (8.6) | 5 (8.6) |
| Inner thalamic | | |
| Anterior | 8 (13.8) | 6 (10.3) |
| Posterior | 8 (13.8) | 7 (12.1) |

RESULTS

Twenty-nine patients with MMD, confirmed by DSA, were enrolled in the study. Of them, 15 patients had undergone surgical revascularization. Seventeen (58.6%) were males and 12 (41.4%) were females (male-to-female ratio, 1.4) and 51.7% were <18 years old. The median age at symptom onset was 12 years (range, 1–51 years), with ischemic stroke (34.5%) being the most common initial clinical presentation, followed by TIA (24.1%), seizures (20.7%), intracranial hemorrhage (17.2%), headache (6.8%), and syncope (3.4%). Seizures and hemorrhage as initial presentation occurred predominantly in children <10 years old (*P* = .03) and in adults >30 years old (*P* = .04), respectively. Recurrence of neurologic events was observed in 75.9% of the patients (Table 1). A total of 58 hemispheres, including 2 cases of unilateral MMD, were analyzed by using MR imaging, which showed 9 watershed, 3 territorial, 2 cortical, and 1 subcortical infarct in the MCA territory. DSA showed predominantly occlusive lesions that involved the distal ICA, proximal MCA, ACA, and PCA (Table 2) and collaterals, predominantly originating from the superficial meningeal network, which was reinforced by the deep parenchymal network (Table 2).

HRVWI was performed in 29 patients. A total of 166 steno-occlusive lesions were

detected (56 distal ICA, 51 proximal MCA, 49 proximal ACA, 9 PCA, and 1 basilar artery). Among them, 11 lesions (6.6%) with concentric wall thickening (Figure) were noted in 9 patients (31.03%), of which 9 lesions (81.8%) involved the distal ICAs and 2 proximal MCAs (18.2%). Ten concentric contrast-enhancing lesions (6.02%) were noted in 8 patients (27.6%), of whom 3 patients (4 lesions) showed lesions with grade II enhancement. Grade I enhancement involved 4 distal ICAs and 2 proximal MCAs. Grade II enhancement (Figure) was observed in 3 distal ICAs and 1 proximal MCA on the symptomatic side. None of the

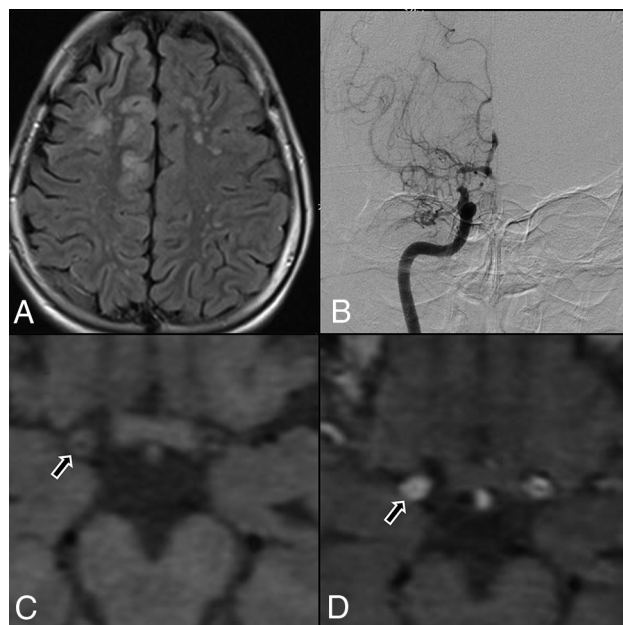


FIGURE. A, Flair axial section showing right ACA and MCA territory cortical infarct and multiple discrete MCA-ACA watershed infarct on the left side. B, DSA, showing tight stenosis of the distal ICA, with concomitant narrowing of proximal MCA and ACA, with leptomeningeal collaterals. C, Axial T1 noncontrast, HRVWI, showing circumferential wall thickening (arrow) and narrowing of the lumen of right distal ICA. D, Axial T1 contrast-enhanced, HRVWI, showing circumferential grade II enhancement (arrow) of a right distal ICA (Note:— Enhancement is graded by comparing with pituitary infundibulum).

ACA, PCA, and basilar artery MMD lesions revealed wall thickening or enhancement.

The mean age at the initial presentation of patients with wall thickening and enhancement was 22.4 and 27.3 years, respectively. The mean \pm SD interval between the first symptom and HRVWI was 64.7 ± 80.7 months, which showed a statistically insignificant inverse relationship with T1 contrast enhancement (mean \pm SD, 55.6 ± 49.6 versus 68.1 ± 90.6 , $P = .44$). The mean \pm SD follow-up period after the vessel wall imaging was 6.9 ± 3.4 months. The presence of contrast enhancement (50%, $P = .01$) and wall thickening (64.3%, $P \leq .001$) showed a statistically significant association with the ischemic events within 3 months before and after vessel wall imaging. Grade II contrast enhancement showed a statistically significant ($P = .02$) association with events within 4 weeks of HRVWI. The mean \pm SD outer diameter of the distal ICA (right, 3.3 ± 0.68 mm; left, 3.4 ± 0.60 mm) and mean \pm SD remodeling index (right, 0.71 ± 0.13 ; left, 0.69 ± 0.13) were lower in MMD (Table 3).

Among the 15 patients (51.7%) who underwent revascularization, 11 (73.3%) underwent unilateral revascularization and 4 (26.7%) underwent bilateral revascularization. HRVWI revealed contrast enhancement in only 1 patient who underwent bilateral revascularization and in 2 patients who underwent unilateral revascularization. Wall thickening was noted in 1 patient who underwent bilateral revascularization and 4 patients with unilateral revascularization. None of these patients developed ischemic events that corresponded to the arterial territory of wall thickening or enhancement during the follow-up period.

DISCUSSION

We analyzed the characteristic HRVWI findings in MMD and their possible role in predicting the risk of recent ischemic events. In our cohort of 29 patients with MMD, only 6.02% MMD lesions showed contrast enhancement and 6.6% MMD lesions showed wall thickening. Among them, wall thickening and enhancement were mostly observed in distal ICA and proximal MCA. The ACA, PCA, and basilar artery did not reveal such changes in HRVWI. A smaller outer diameter of the involved vessel with negative remodeling was also observed. Also, the

Table 3: HRVWI characteristics of MMD

| HRVWI Characteristics | Contrast Enhancement (8 Patients, 10 Lesions) | T1 Wall Thickening (9 Patients, 11 Lesions) |
|---|--|--|
| Pattern, <i>n</i> (%) | | |
| Concentric | 10 (100) | 11 (100) |
| Eccentric | 0 (0) | 0 (0) |
| Vessel involved, <i>n</i> (%) | | |
| Distal ICA | 8 (80) | 9 (81.8) |
| Proximal MCA | 2 (20) | 2 (18.2) |
| Events within 3 mo before and after the imaging, <i>n</i> (%) | 7 (87.5) ($P = .01$) | 9 (100) ($P \leq .001$) |
| Recent events (DWI positive) within 4 wk of imaging, <i>n</i> (%) | | 4 (44.4) ($P = .20$) |
| Grade I contrast enhancement | 0 (0) | |
| Grade II contrast enhancement | 3 (100) ($P = .02$) | |
| Suzuki stage | Grade 2 enhancement (4 lesions) | Wall thickening (11 lesions) |
| I | 1 (25) | 1 (9.1) |
| II | 1 (25) | 2 (18.2) |
| III | 0 | 4 (36.4) |
| IV | 2 (50) | 4 (36.4) |
| Remodeling index, mean \pm SD | Right, 0.71 ± 0.13 | Left, 0.69 ± 0.13 |

presence of wall thickening and enhancement showed a statistically significant association with ischemic events.

We observed concentric wall enhancement in 27.6% of patients with MMD. Among the 166 steno-occlusive lesions detected by HRVWI, 6.02% of lesions only showed contrast enhancement, which is lower in comparison with the previously published data, which accounted for 70%–93%.^{1,3,15,16} This may be related to the characteristics of the population under study or might be related to the small sample size. There is evidence that MMD is primarily a proliferative disease of the intima and smooth muscles that leads to vascular stenosis and that concentric enhancement may represent hyperproliferation of vessel components.¹⁷ It is well known that strong contrast enhancement of the arterial wall suggests an increase in the vascular supply and increased endothelial permeability, which promotes entry of the contrast agent into the extravascular space.¹⁸

Chmelova et al¹⁹ found a higher expression of both angiogenic factors in intima and vascular endothelial growth factor in the endothelium of Moyamoya-affected arteries than normal arteries. Nestin, a marker of newly formed endothelial cells was expressed in the Moyamoya-affected vessels.²⁰ Thus, it can be presumed that an active angiogenic milieu prevails in the enhanced vessels in patients with MMD.¹⁹ Similar to the atherosclerotic process in the extracranial vessels where concentric and circumferential wall enhancements suggest an inflammatory response due to increased macrophage infiltration and neovascularity, the enhancement in Moyamoya vessels may be considered to represent an active angiogenic process and inflammatory response.

Vessel wall thickening was observed in 31.03% of the patients with MMD. Among the 166 steno-occlusive lesions detected, 6.6% of lesions only showed vessel wall thickening, which was diffuse and concentric. Also, the outer diameter of the distal ICA was attenuated with negative remodeling in all the patients. Histopathologic studies of ICAs and MCAs in MMD demonstrated eccentric intimal fibrous thickening, which is often multilayered, with newly formed elastic lamina between the layers.²¹ The internal elastic lamina is markedly tortuous, with duplication and a decrease in the number of smooth-muscle cells in the media and these pathologic changes are seen predominantly in the distal ICA, proximal MCA, and ACA. The thinning of media and decreased flow as well as constriction of the internal elastic lamina, culminate in the decreased outer diameter of the vessels as well as the negative remodeling. It can also be postulated that diffuse wall thickening might be due to vessel wall edema and investigators have found that the wall edema has a correlation with inflammation²² associated with significantly greater plasma concentration of matrix metalloproteinase-9, monocyte chemoattractant protein-1, vascular endothelial growth factor, and other inflammatory cytokines.

Our study also observed steno-occlusive lesions, which predominantly involved the distal ICA, which supports the notion that stenosis in MMD begins first in the ICA and as the disease progress involves the MCA, followed by the ACA. The occlusive lesions in MMD predominantly involve the anterior circulation and the involvement of the vertebral and basilar arteries is relatively rare,²¹ which is also the same in our study. Our study could

not demonstrate thickening or enhancement of the ACA, PCA, and basilar artery. However, in 1 study, 19.6% of ACAs showed contrast enhancement.³

We also studied the role of HRVWI to possibly predict a future event based on its characteristic findings. It was observed that grade II enhancing lesions were significantly associated with ischemic events within 4 weeks of imaging. Besides, those lesions that showed either wall thickening or contrast enhancement were significantly associated with neurologic events within 3 months before or after vessel wall imaging. Wang et al³ reported that high-grade enhancement in the Moyamoya-affected vessel is associated with an increased risk of acute ischemic infarction. As with atherosclerotic plaque, in which higher-grade contrast enhancement represents plaque instability and identifies lesions responsible for ischemic events, higher-grade enhancement in MMD may reflect a proliferative neovascular change and activity of the lesion.³ These findings suggest that HRVWI might help to identify patients at risk of an early event and help the physician triage them for early revascularization. We also observed that the presence of wall thickening and enhancement did not correlate with subsequent events after revascularization, which suggests that these findings cannot be taken into consideration in predicting the risk of future events after revascularization.

The strength of our study is that, because all the patients underwent detailed evaluation for secondary etiology, the study population truly represents idiopathic MMD. The HRVWI was read by a neuroradiologist and a neurologist who were blinded to clinical data and, hence, the imaging data are homogeneous and unbiased. Because all these patients were on a regular follow-up schedule, the recurrent cerebral events could be carefully documented. The study was conducted in a single center and the sample size was small. Also, the HRVWI was done at varying time intervals from the symptom onset with a long interval in a few of the patients, which may explain the relatively few patients with wall enhancement compared with previous studies. A study with a large sample size that involves multiple centers is needed to validate the findings in our study.

CONCLUSIONS

The presence of concentric wall thickening and enhancement in HRVWI was relatively rare in our cohort of patients with MMD compared with the Japanese and Chinese populations. The presence of wall thickening, and enhancement may predict future ischemic events in patients with MMD.

Disclosures: K. Arun—RELATED: Grant: Wellcome Trust/DBT*; Support for travel to meetings for the study or other purposes: Wellcome Trust/DBT.* P.N. Sylaja—RELATED: Grant: Wellcome DBT project* UNRELATED: Employment: Sree Chitra Tirunal Institute for Medical Sciences and Technology. C. Kesavadas—RELATED: Grant: Wellcome DBT* UNRELATED: Employment: Grants/Grants Pending: DST India.* *Money paid to the institution.

REFERENCES

1. Ryoo S, Cha J, Kim SJ, et al. **High-resolution magnetic resonance wall imaging findings of moyamoya disease.** *Stroke* 2014;45:2457–60 [CrossRef Medline](#)
2. Han C, Li ML, Xu Y, et al. **Adult moyamoya-atherosclerosis syndrome: clinical and vessel wall imaging features.** *J Neurol Sci* 2016;369:181–84 [CrossRef Medline](#)

3. Wang M, Yang Y, Zhou F, et al. **The contrast enhancement of intracranial arterial wall on high-resolution MRI and its clinical relevance in patients with moyamoya vasculopathy.** *Sci Rep* 2017;7:44264 [CrossRef Medline](#)
4. Kim YJ, Lee DH, Kwon JY, et al. **High resolution MRI difference between moyamoya disease and intracranial atherosclerosis.** *Eur J Neurol* 2013;20:1311–18 [CrossRef Medline](#)
5. Kesav P, Krishnavadana B, Kesavadas C, et al. **Utility of intracranial high-resolution vessel wall magnetic resonance imaging in differentiating intracranial vasculopathic diseases causing ischemic stroke.** *Neuroradiology* 2019;61:389–96 [CrossRef](#)
6. Hatsukami TS, Yuan C. **MRI in the early identification and classification of high-risk atherosclerotic carotid plaques.** *Imaging Med* 2010;2:63–75 [CrossRef Medline](#)
7. Wasserman BA. **Advanced contrast-enhanced MRI for looking beyond the lumen to predict stroke: building a risk profile for carotid plaque.** *Stroke* 2010;41(Suppl):S12–S16 [CrossRef Medline](#)
8. Fukui M. **Guidelines for the diagnosis and treatment of spontaneous occlusion of the circle of Willis ('moyamoya' disease). Research Committee on Spontaneous Occlusion of the Circle of Willis (Moyamoya Disease) of the Ministry of Health and Welfare.** *Clin Neurol Neurosurg* 1997;99:S238–40 [CrossRef](#)
9. Adhithyan R, Kesav P, Thomas B, et al. **High-resolution magnetic resonance vessel wall imaging in cerebrovascular diseases.** *Neurol India* 2018;66:1124–32 [CrossRef Medline](#)
10. Baltasavias G, Khan N, Valavanis A. **The collateral circulation in pediatric moyamoya disease.** *Childs Nerv Syst* 2015;31:389–98 [CrossRef Medline](#)
11. Zhao M, Zhang D, Wang S, et al. **Posterior circulation involvement in pediatric and adult patients with moyamoya disease: a single center experience in 574 patients.** *Acta Neurol Belg* 2018;118:227–33 [CrossRef Medline](#)
12. Swartz RH, Bhuta SS, Farb RI, et al. **Intracranial arterial wall imaging using high-resolution 3-Tesla contrast-enhanced MRI.** *Neurology* 2009;72:627–34 [CrossRef Medline](#)
13. Qiao Y, Steinman DA, Qin Q, et al. **Intracranial arterial wall imaging using three-dimensional high isotropic resolution black blood MRI at 3.0 Tesla.** *J Magn Reson Imaging* 2011;34:22–30 [CrossRef Medline](#)
14. Yu LB, Zhang Q, Shi ZY, et al. **High-resolution magnetic resonance imaging of moyamoya disease.** *Chin Med J (Engl)* 2015;128:3231–37 [CrossRef Medline](#)
15. Yuan M, Liu ZQ, Wang ZQ, et al. **High-resolution MR imaging of the arterial wall in moyamoya disease.** *Neurosci Lett* 2015;584:77–82 [CrossRef Medline](#)
16. Mossa-Basha M, de Havenon A, Becker KJ, et al. **Added value of vessel wall magnetic resonance imaging in the differentiation of moyamoya vasculopathies in a non-Asian cohort.** *Stroke* 2016;47:1782–88 [CrossRef Medline](#)
17. Fukui M, Kono S, Sueishi K, et al. **Moyamoya disease.** *Neuropathology* 2000;20(Suppl):S61–64 [CrossRef Medline](#)
18. Millon A, Boussel L, Brevet M, et al. **Clinical and histological significance of gadolinium enhancement in carotid atherosclerotic plaque.** *Stroke* 2012;43:3023–28 [CrossRef Medline](#)
19. Chmelova J, Kolar Z, Prochazka V, et al. **Moyamoya disease is associated with endothelial activity detected by anti-nestin antibody.** *Biomed Pap Med Fac Univ Palacky Olomouc Czech Repub* 2010;154:159–62 [Medline](#)
20. Mokrý J, Čížková D, Filip S, et al. **Nestin expression by newly formed human blood vessels.** *Stem Cells Dev* 2004;13:658–64 [CrossRef Medline](#)
21. Kaku Y, Morioka M, Ohmori Y, et al. **Outer-diameter narrowing of the internal carotid and middle cerebral arteries in moyamoya disease detected on 3D constructive interference in steady-state MR image: is arterial constrictive remodeling a major pathogenesis?** *Acta Neurochir (Wien)* 2012;154:2151–57 [CrossRef Medline](#)
22. Chen X, Zhao H, Chen Z, et al. **Association between proximal internal carotid artery steno-occlusive disease and diffuse wall thickening in its petrous segment: a magnetic resonance vessel wall imaging study.** *Neuroradiology* 2017;59:485–90 [CrossRef Medline](#)



Steno-occlusive Intracranial Large Vessel Arteriopathies in Childhood

A Pattern Oriented Approach to Neuroimaging Diagnosis

Katherine S. Kelson^a, Timothy J. Bernard, MD^{a,b}, Nicholas V. Stence, MD^{a,c,*}

KEYWORDS

• Focal cerebral arteriopathy • Intracranial arteriopathy • Intracranial dissection • Moyamoya

KEY POINTS

- Steno-occlusive intracranial large vessel arteriopathies are a common cause of arterial ischemic stroke (AIS) in children, particularly within the anterior cerebral circulation. The wide range of disorders that belongs to this category expresses a limited number of discrete phenotypes whose recognition facilitates diagnosis and treatment.
- Focal cerebral arteriopathy (FCA) is most common of these disorders expressed in childhood with characteristic acute clinical presentation and imaging features involving the intradural internal carotid artery (ICA) distribution unilaterally. It is notable for a significant risk of transient arteriopathy progression complicated by recurrent stroke.
- The moyamoya arteriopathies are a group of disorders characterized by chronic progressive occlusion of the intradural ICA terminus accompanied by specific unique types of collateral vessel formation. It is bilateral in most cases, is a common cause of AIS in children and often requires microneurosurgical revascularization for definitive therapy.
- Multi-focal arteriopathy (MFA) is the least common pattern of steno-occlusive intracranial large vessel disease in children. It is characterized by involvement of the anterior circulation bilaterally, and/or the posterior circulation and is often accompanied by involvement of small to medium size intracranial arteries.
- Intracranial arterial dissection is a specific mural injury process that may occur as a result of major mechanical damage to otherwise normal arteries or may be a manifestation of minor hemodynamic trauma (spontaneous) in the setting of underlying arteriopathy that compromises mural integrity. It may involve the intracranial posterior circulation in children and can frequently result in recurrent stroke.

INTRODUCTION

Steno-occlusive intracranial large vessel arteriopathy is an important cause of arterial ischemic

stroke (AIS) in pediatric patients, representing up to 50% of cases.¹ Among the different phenotypic patterns encountered, the focal cerebral arteriopathy (FCA) pattern is most common. The

^a University of Colorado Anschutz School of Medicine, Aurora, CO, USA; ^b Department of Pediatrics, Section of Child Neurology, University of Colorado Anschutz School of Medicine, Aurora, CO, USA; ^c Department of Radiology, Section of Pediatric Radiology, University of Colorado Anschutz School of Medicine, Aurora, CO, USA

* Corresponding author. 13123 East 16th Avenue, Aurora, CO 80045.

E-mail address: nicholas.stence@cuanschutz.edu

moyamoya arteriopathy phenotype accounts for most remaining cases of childhood AIS due to steno-occlusive intracranial large vessel arteriopathy, with MFA phenotypes being relatively uncommon.² Moyamoya arteriopathies (MMA) result from the interaction of vascular injury factors (radiation, mycobacterial infection, and rheometric shear stress caused by sickled erythrocytes) with genetically-programmed segmental vulnerability traits in arteries. Consequently, the moyamoya phenotype can be expressed in many different clinical settings and is variably associated with a variety of syndromic conditions. The congenital cerebrovascular dysplasias expressed in the PHACE syndrome are worth noting here. These may be symptomatic with AIS, are usually monofocal and usually involve the internal carotid artery (ICA). Although any ICA segment may be involved, a moyamoya phenotype is sometimes encountered. These cases are typically recognized by clinical and imaging stigmata of the well-described neurocristopathy. MFA patterns are expressed by a variety of genetic arteriopathies, infectious and autoimmune forms of vasculitis, and in the reversible cerebral vasoconstriction syndrome (RCVS).

Given the high rate of recurrent stroke and varied options for stroke prevention, which may depend on the specific type of arteriopathy diagnosis, early and accurate diagnosis of steno-occlusive intracranial large vessel arteriopathy subtypes is important. We will discuss the subtypes of childhood steno-occlusive intracranial large vessel arteriopathies and important imaging findings to help guide clinical diagnosis.

1. FCA

a. Definition and Epidemiology

FCA is an acutely presenting, acquired, monophasic, unilateral monofocal steno-occlusion of the large intracranial arteries of the anterior cerebral circulation, most commonly involving the intradural ICA and its terminal branches.² The acute presentation initially expresses signs and symptoms of striatocapsular ischemia, followed by signs and symptoms of cortical ischemia as the primary vascular lesion progresses and collateral failure ensues. The brain imaging findings closely reflect the characteristic clinical course with striatocapsular infarction being the earliest and most consistent brain imaging manifestation. FCA has previously been referred to as transient cerebral arteriopathy, as it often stabilizes or improves months to

years after onset.² FCA has been further differentiated by subtype based on the dominant underlying mechanism of vessel wall injury (arterial dissection vs mural inflammation). The most widely recognized primary subtypes recently defined by the vascular effects of infection in pediatric stroke (VIPS) trial include FCA-inflammatory (FCA-i), FCA-dissection (FCA-d), and FCA-undetermined.² A classification system described by Bernard and colleagues applies the CASCADE criteria to aid in the diagnosis of FCA based on the presence of characteristic lenticulostriate collateral vessels, which are distinct from those encountered in the MMA.³ Specifically, the lenticulostriate collateral vessels encountered in FCA are bridging collaterals, which do not vascularize the striatum and internal capsule but instead form horizontally-oriented anastomotic bridges with each other in the subarachnoid space to reconstitute distal flow across a severe stenosis within the circle of Willis. In contrast, true moyamoya collaterals are hypertrophied lenticulostriate arteries, which directly vascularize the striatum and internal capsule in an attempt to reach the cortical territory. Notably, the CASCADE criteria recognize a posterior circulation form of FCA, which may be caused by dissection of the intradural vertebral arteries, basilar artery, and/or posterior cerebral arteries. Given the unique pathogenesis of anterior circulation FCA, it stands to reason that dissections of the posterior arterial circulation should be distinctly classified, particularly since these usually occur in the setting of a generalized or diffuse arteriopathy. Additionally, although the strictly pattern-based CASCADE criteria also recognize congenital anomalies as a potential form of FCA, neurocristopathies expressing a monofocal anterior circulation dysplasia rarely mimic the vascular imaging findings of FCA and can usually be differentiated on the basis of clinical presentation and ancillary neuroimaging findings.

The incidence of AIS has been reported to be 2.4 per 100,000 person-years.⁴⁻⁶ On a population basis, FCA accounts for up to 25% of childhood stroke—^{1,2}most commonly in patients aged 5 to 9 y old.⁷

Although AIS typically has a male predominance across all types, there is a 50/50 male to female distribution in FCA.⁸

b. Pathophysiology

The underlying etiology of many cases of FCA remains uncertain, but most cases of FCA are thought to be inflammatory in nature, termed FCA-i. In FCA-i, it is postulated that an episode of arterial inflammation leads to narrowing of vessels with secondary thrombus formation within the arterial lumen surrounded by inflamed or damaged endothelium.⁹ Wintermark and colleagues note that FCA-i tends to be restricted to the territory of the distal intradural ICA and its terminal branches.² There is increasing evidence that many cases of FCA, specifically FCA-i, are secondary to previous infection.² Black blood vessel wall imaging (VWI) has shown promise in directly imaging mural inflammation in FCA through detection of vessel wall thickening and enhancement, discussed further in the following section.¹⁰ Black blood VWI may also reveal intramural blood products that cause T1 shortening in the case of arterial dissection.

Post-varicella arteriopathy (PVA) is an important subtype of FCA-i occurring following primary varicella zoster virus (VZV) infection, with an average latency interval of 2 mo from infection to stroke.^{2,11,12} PVA occurs when varicella virus infection involving the cutaneous distribution of the ophthalmic division of the trigeminal nerve results in retrograde transport of virus through dendritic processes to cell bodies in the trigeminal ganglion where virus remains latent. Subsequent reactivation of virus enables viral spread through trigeminal axons to the adventitia of the intradural ICA and its terminal branches.¹³ Vascular imaging features of PVA are indistinguishable from other etiologies of FCA-i.¹⁴ PVA may present in patients who are positive for VZV without cutaneous stigmata, or many months after known VZV infection, which can cloud the clinical picture.¹⁵ If PVA is suspected as a potential cause of FCA, there should be a low threshold to obtain cerebrospinal fluid (CSF) to test for VZV-DNA, especially

in unvaccinated patients.¹⁶ In general, increasing rates of vaccination against VZV have been associated with a decreasing incidence of PVA.^{17,18} Although PVA is a well-described cause of FCA-i in pediatric populations, other potential infectious etiologies are increasingly recognized. Other common infections, including Parvovirus-B19, cytomegalovirus and herpes viruses specifically have also been found to be potential triggers of AIS, even if initial infectious symptoms are subclinical.^{2,12,19} Recent case studies also suggest the novel virus COVID-19 as a potential infectious trigger of FCA-i.²⁰

Isolated intracranial arterial dissections involving the intradural ICA and/or M1-middle cerebral artery (MCA) are regarded as FCA-d subtype in the most recent VIPS classification (see **Fig. 5**).² Most reported cases are associated with head and neck trauma, most commonly due to mechanical forces resulting from rapid acceleration-deceleration injuries (whiplash), or from the shock wave effects of intracranial penetrating injuries. The forces of such injuries may produce tears in the tunica intima of intracranial arteries that are subjected to traction forces near fixation points (ie, petrolingual ligament, petroclival ligament, and paraclinoid dural rings encircling ICA).^{2,21} Nonetheless, many cases of intracranial arterial dissection are often spontaneous or follow minor trauma. While generalized or diffuse arteriopathies (ie, Ehlers Danlos type 4, Marfan's Syndrome, Loeys Dietz Syndrome, and Arterial Tortuosity Syndrome) may be associated with intracranial arterial dissections, FCA-d, which is a monofocal process, is by definition distinct from these entities. Intracranial stenoses involving the intradural ICA are frequently difficult to diagnose and distinguish as purely inflammatory or dissecting processes. Moreover, overlap between arterial wall inflammation and arterial dissection likely exists. Inflammation, as a form of vessel wall injury can lead to arterial dissection, and arterial dissection as a distinct form of vessel wall injury can lead to vessel wall inflammation. When dissections form, exposure of the thrombogenic

subendothelial tissue to circulating blood can lead to in-situ thrombosis, false lumen expansion with reciprocal collapse of the true lumen, and downstream embolization of thrombus. Any or all of these processes can serve as a mechanism of AIS. Notably, intracranial arterial dissection can be complicated by dissecting aneurysm formation when the false lumen of the dissection undergoes intramural expansion or by subarachnoid hemorrhage when the false lumen extends completely across the arterial wall from the adluminal side to the abluminal side. Consequently, close monitoring by vascular imaging is recommended.²¹

c. Presentation, symptoms, diagnosis

The typical presentation of FCA is in a previously healthy school age child with an acute onset of neurologic symptoms, most commonly acute hemiplegia, headache, and variable sensorimotor findings.^{22–24} Symptoms may progress over hours to days, with faster progression of symptoms associated with an increased risk of recurrent ischemic stroke.^{23–25} In pediatric AIS patients found to have arteriopathy, the risk of recurrent stroke within 1 y is up to 21%, a much higher rate of recurrence than for cardioembolic or cryptogenic stroke.²⁶ The mortality rate from AIS in FCA is 2.6%.^{27,28} Survivors have high rates of permanent neurologic morbidity, up to 50% having disabling sensorimotor deficits and/or cognitive deficits at 1 y.^{29,30}

Accurate diagnostic evaluation of FCA relies on prompt recognition of neurologic symptoms, demonstration of characteristic neuroimaging findings and the results of laboratory testing. Relevant laboratory results include C-reactive protein, erythrocyte sedimentation rate, D-dimer, and CSF indices. CSF studies should include polymerase chain reaction to look for underlying infectious etiologies.^{9,26,31} Inflammatory markers commonly used to diagnose adult stroke can also be collected to help clarify the diagnosis, including interleukin (IL)-6, IL-10, IL-1Ra, and granulocyte macrophage colony-stimulating factor.^{9,26,31} D-dimer may also be used as a biomarker of prognosis since elevated levels have been associated with poor outcomes.³²

As discussed, vascular imaging manifestations of FCA include steno-occlusion and/or luminal irregularity of the distal intradural ICA and contiguous proximal anterior cerebral artery and MCA segments.^{2,33,34} A banded pattern of luminal irregularity involving the intradural ICA and M1 on catheter-directed cerebral angiography has long been considered pathognomonic for FCA-i (**Fig. 1B**), although the finding can also be suggested on computed tomography (CT) angiography and MR angiography (MRA) (with or without contrast).² Imaging features strongly suggestive of the FCA-d subtype include intimal flap, intramural hematoma, segmental corkscrew tortuosity (caused by dissections with a spiral intramural trajectory), segmental ectasia, aneurysm, and pseudoaneurysm.^{35–37} Segmental ectasias, aneurysms, pseudoaneurysms, and some intimal flaps are adequately shown by MRI, MRA, and computed tomography angiography (CTA) techniques. MRA has been shown to be concordant with CTA in up to 100% of cases when localizing vascular lesions in large to medium size intracranial arteries.³⁸ MRA is also as reliable as CTA in detecting stenotic or occlusive disease of the ICA and MCA, and so can help in determination of the many causes of AIS, including cardioembolic disease, MMA, FCA-d, and FCA-i.³⁸ Some pediatric patients with an isolated striatocapsular infarction and no detectable arterial narrowing at presentation will go on to develop arterial stenosis typical of FCA-i. Thus, early repeat vascular imaging should be undertaken in such cases if initial angiography is negative (**Fig. 2**). Rapid MRA protocols that reduce the need for sedation can also be employed by decreasing coverage and spatial resolution, and by leveraging modern acceleration techniques such as compressed SENSE (**Fig. 3**).³⁹

Isolated striatocapsular infarction is an early and specific brain imaging finding in patients presenting with FCA (regardless of subtype). It is most likely to be demonstrated by MRI, highlighting the importance of obtaining MRI acutely whenever possible.^{40–42} In contrast to

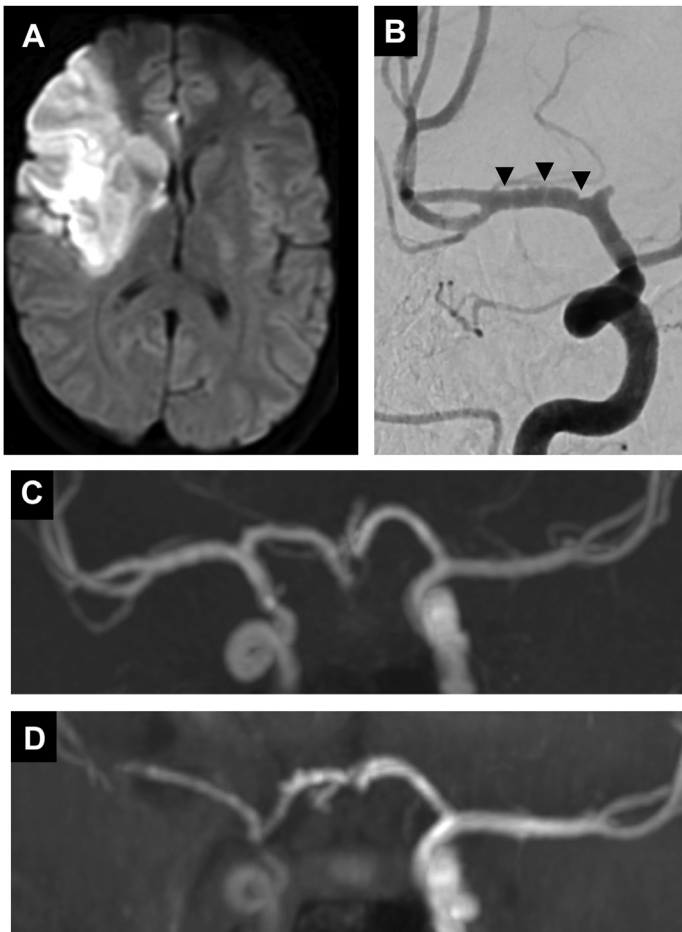


Fig. 1. Focal cerebral arteriopathy. 17-year-old boy presenting with acute onset left sided weakness and headache. (A) Axial diffusion weighted MRI h after presentation showing acute infarct within right basal ganglia, insula and anterior cortical MCA territory. (B) Frontal projection of catheter-directed angiogram in the right internal carotid artery (ICA) performed immediately after MRI showing banded pattern of luminal irregularity primarily involving proximal MCA (*arrowheads*) typical of FCA-i. (C) Coronal MIP image of TOF MRA performed at the same time as (A) shows narrowing and irregularity of proximal right MCA and intradural ICA, although it is less apparent than on catheter-directed angiogram. (D) Follow-up MRA performed 2 months later shows marked progression of stenosis.

other vascular imaging techniques, which exclusively depict the vascular lumen, black blood VWI highlights the vessel wall, and is uniquely able to show vessel wall thickening and enhancement. Black Blood VWI without contrast will reveal intramural hematomas in cases of FCA-d. Multiple studies have noted the utility of MRI intracranial Black Blood VWI in the evaluation of steno-occlusive intracranial large vessel arteriopathies, as this modality directly images the arterial wall where the pathology is found, in contrast to luminal techniques like CTA, MRA, and catheter angiography

(CA).⁴³ Recommendations for how to acquire Black Blood VWI have been outlined elsewhere.⁴⁴ Research into pediatric populations is still limited to small case series and case reports. Stence and colleagues demonstrated strong vessel wall enhancement at stroke onset was associated with arteriopathy progression over time in both FCA and MMA (see **Fig. 2**; **Fig. 4**).⁴⁵ Dlamini and colleagues showed that mural enhancement of intracranial vessels on Black Blood VWI in pediatric populations is more concentric than seen in adults, and is associated with a range of diagnoses including FCA-i,

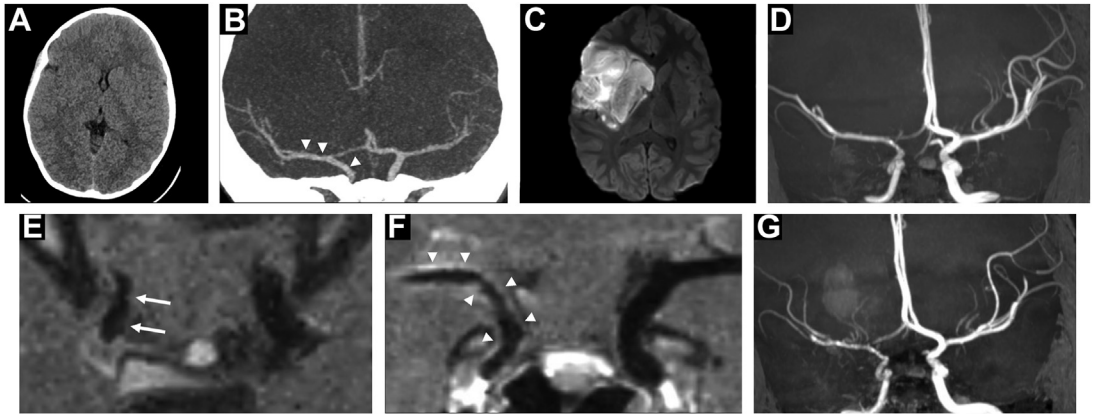


Fig. 2. Focal cerebral arteriopathy. 7-year-old girl presenting with acute left sided weakness and confusion. (A) Initial axial non-contrast head CT without evidence of infarction. (B) Coronal CTA demonstrating subtle decrease in caliber of intradural right ICA and M1 segment (*arrowheads*). (C) Axial DWI obtained 12 h later demonstrating a large infarction involving right basal ganglia, internal capsule, insula and opercular cortex with parenchymal edema. (D) Coronal MIP MRA showing more obvious decreased caliber of right intradural ICA, A1 and M1 segments, with mild irregularity of the intradural ICA. *E & F* Small field of view, post-contrast axial (*E*) and coronal (*F*) black-blood vessel wall imaging of internal carotid arteries demonstrates stenosis and luminal irregularity involving the intradural right ICA (*arrows*), with a banded pattern of vessel wall thickening and enhancement involving the intradural right ICA and M1 segment (*arrowheads*). (*G*) Repeat coronal MIP MRA obtained 2 days after (*D*) demonstrates worsened stenosis and luminal irregularity involving the intradural right ICA and M1 segment in the region of vessel wall thickening and enhancement.

vasculitis, vasospasm, and cryptogenic AIS.⁴⁶ It is important to note that mural enhancement on Black Blood VWI is not present in all cases of FCA-i.⁴⁷

Catheter-directed angiography, although less utilized than in the past for diagnostic evaluation of childhood AIS, remains an important diagnostic modality for the assessment of intracranial large vessel occlusion (LVO) of indeterminate etiology. Very small intimal flaps or other findings associated with subtle

dissections (ie, prolonged retention of contrast media within the false lumen) may only be detected by catheter-directed angiography.

In addition to initial diagnostic imaging, repeat vascular imaging is important to document early worsening and eventual improvement or resolution of many cases of FCA (see **Figs. 1** and **2**).³³

d. Management and treatment

Early diagnosis of FCA is important to guide treatment and avoid complications. In

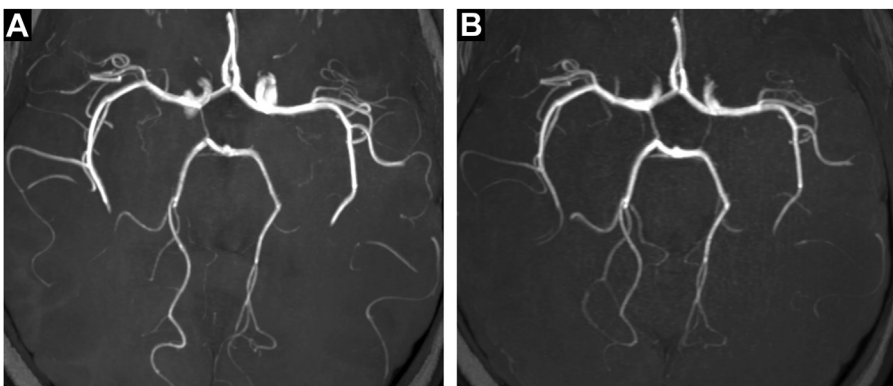


Fig. 3. (A) Axial MIP from a routine, non-contrast TOF MRA with voxel size of 0.5 mm and compressed SENSE factor of 4, acquisition time 3.5 minutes. (B) Axial MIP from a fast, non-contrast TOF MRA with voxel size of 0.8 mm and compressed SENSE factor of 7, acquisition time 30 seconds. The central arteries are equally conspicuous on both acquisitions, although detail of peripheral arteries is superior on the routine acquisition.

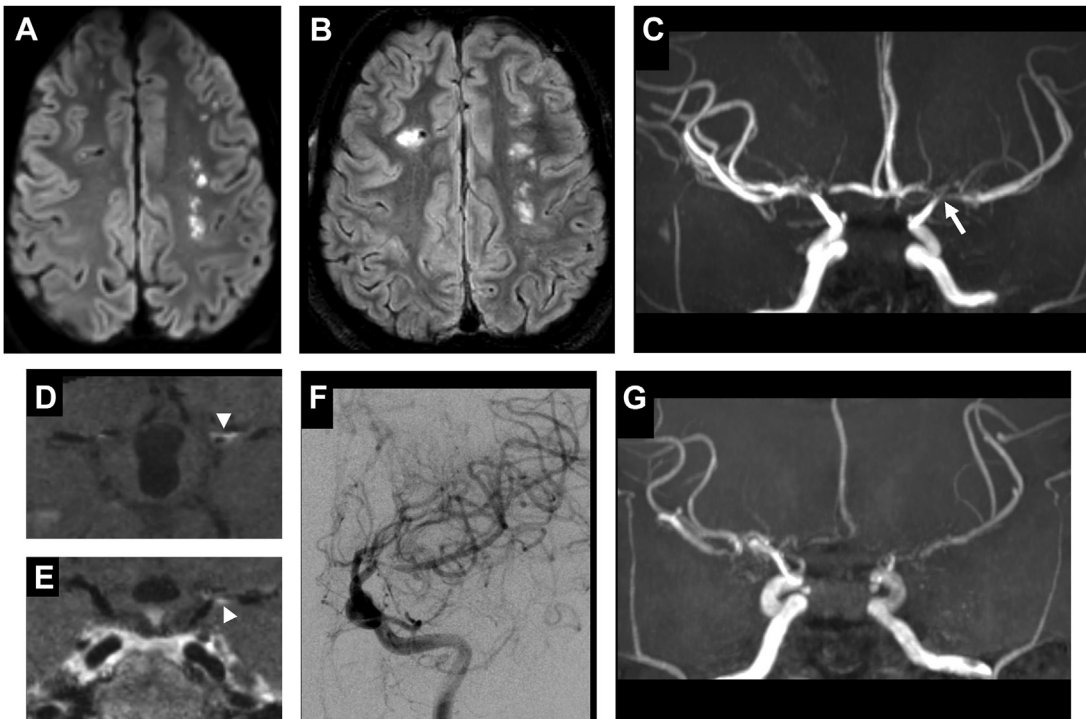


Fig. 4. Moyamoya arteriopathy. 12-year-old girl with a history of a posterior fossa juvenile pilocytic astrocytoma treated with surgery several years prior, presenting acutely with right arm weakness. (A) Axial DWI demonstrating several small foci of acute infarction in the left periventricular white matter watershed territory, while an axial FLAIR at the same level (B) demonstrates additional foci of more chronic infarction. (C) Coronal MIP of a TOF MRA demonstrates moderate to marked narrowing of the left ICA terminus, proximal M1 and A1 (arrow), as well as moderate narrowing of the right A1 and M1. Axial (D) and coronal (E) post-contrast small field of view black-blood VWI over the terminal ICAs shows asymmetric wall thickening and mural enhancement involving the distal left ICA and proximal A1 and M1 (arrowheads). Frontal projection of left ICA injection from catheter-directed angiogram (F) confirms narrowing of the left carotid terminus, proximal A1 and M1, and prominent moyamoya collaterals. TOF MRA performed 2 years later (G) shows marked progression of bilateral ICA termini, M1 and A1 narrowing, worse on the left.

general, FCA is acutely treated with antiplatelet therapy, avoiding hypotension, and bed-rest with 15° Trendelenberg position to reduce risk of recurrent stroke.⁴⁸ Although data are limited, one study demonstrated that the addition of corticosteroid treatment in FCA-i may be associated with better clinical outcomes for behavior and cognitive domains.⁴⁹ As such, corticosteroids and acyclovir are increasingly utilized in cases of FCA-i, especially those with early progressive arterial stenosis or recurrent stroke events. To better determine the best use of steroids in FCA-i, the FOCAS trial has begun enrollment in North America and will compare the use of immediate treatment of all patients with FCA-i to delayed steroid administration in children with progressive FCA or recurrent

stroke within the first week.⁵⁰ Other options for treatment of recurrent or progressive disease include escalation of antithrombotic management, blood pressure augmentation, and/or more prolonged bed-rest in a supine position. The use of intravenous thrombolytic drugs and catheter-directed revascularization techniques in selected children with AIS is an area of active research and was examined in both the TIPS-ER study and Save ChildS study, respectively.^{51–53} Preliminary results from the Save ChildS study indicate that mechanical thrombectomy performed for intracranial LVO (intracranial ICA, M1, vertebral artery, basilar artery, and posterior cerebral artery) within 6 to 24 h of symptom onset in a small cohort of children (N = 20) with a variety of LVO

mechanisms (only 5% FCA) had comparable or better functional outcomes compared to adult patients who received the same treatment, and had a similar safety profile.⁵⁴ Whether thrombectomy should have a role in the management of FCA patients with intracranial LVO is, however, not yet settled. Several concerns remain regarding the use of endovascular thrombectomy techniques in pediatric AIS patients with FCA, including a lack of high-level evidence, and a theoretically higher risk of procedure related vessel trauma (de novo dissection, acute mural perforation, acute or delayed mural rupture, and delayed traumatic aneurysm formation). These concerns are centered around the increased fragility of the acutely inflamed or dissected arterial wall, the increased frailty, smaller vessel diameters, and propensity to severe vasospasm that characterizes the developing cerebral arteries of children.^{55,56} Although the numbers are small, TIPS-ER suggests that the use of intravenous tPA in children with FCA may be safe.⁵³ Confirmation with larger numbers is needed to be certain.

2. MMA

a. Definition, epidemiology, and pathophysiology

MMA are chronic and progressively occlusive vascular diseases that affect terminal intracranial ICA bifurcation unilaterally or bilaterally, resulting in the sequential development and eventual exhaustion of specific unique collateral arteries, thus expressing a distinct clinical and neuroimaging phenotype.⁵⁷ The patterns of collateral vessel development that are unique to MMA include: (1) moyamoya collaterals (hypertrophied lenticulostriate collateral vessels that vascularize striatum and internal capsule), (2) choroidal collaterals involving anastomoses between the anterior choroidal artery and perforating arteries, (3) transdural collaterals from the external carotid artery, which extend across intact dura matter and provide cerebral vascularization. Although leptomeningeal collaterals involving anastomoses between arterial tributaries in the cortical watershed zones are also a prominent feature of MMA, this pattern of collateral vessel development is not unique to MMA. All the collateral

patterns that form in MMA reflect the distribution of steno-occlusive disease at the intracranial ICA terminus and within the anterior circle of Willis, which precludes collateral flow through the circle of Willis and forces collateral networks to form distal to the circle of Willis. In most cases, MMA begins with progressive occlusion of the intracranial ICA terminus, and initiation of true moyamoya collaterals (Suzuki stages 1 and 2). As the occlusion becomes complete, moyamoya collaterals intensify (Suzuki stage 3). As the lumen of the M1 and A1 segments become obliterated, inflow to moyamoya collaterals is eliminated causing a gradual involution of moyamoya collaterals that is accompanied by a proliferation of other collateral networks (Suzuki stages 4 through 6). Notably, this proliferation can lead to the formation of fragile vessels with angiomatous features.

The MMA phenotype results from the interaction of vascular injury factors (radiation, mycobacterial/viral infection, and rheometric shear stress caused by sickled erythrocytes) with genetically programmed permissivity traits (mutations in neurofibromin, JAG1, and RNF213) expressed by arteries that are segmentally vulnerable because of their positional identity in the cerebrovascular tree (terminal carotid artery bifurcation and anterior circle of Willis). Segmental vulnerability is conferred by variable exposure to hemodynamic stimuli driving vascular remodeling processes, and by genetic programs that are differentially executed by vascular cells according to metameric location. Consequently, the moyamoya phenotype can be expressed in many different clinical settings and is variably associated with a variety of syndromic conditions. In contrast to FCA, which has been defined in part by the monophasic clinical course and sometimes resolving nature of the index vascular lesion, MMAs are progressive and chronic with no expectation of resolution of symptoms and with more frequent episodes of stroke recurrence over time.^{2,58} Notably, the initial early-stage presentation of bilateral MMA, may occasionally be mild and inapparent on one side, resulting in the misdiagnosis

of FCA. Progression from unilateral to bilateral disease will usually differentiate the patient with MMA from FCA.⁵⁹ In contrast to FCA, truly unilateral or early-stage bilateral MMA does not typically present with focal striato-capsular infarction as an early initial manifestation. Moreover, true moyamoya collaterals found in MMA directly vascularize the striatum and internal capsule, in contrast to the lenticulostriate collaterals of FCA, which form anastomotic networks that bridge an M1 or A1 occlusion. In MMA, the involvement of the anterior circulation is predominant, with basilar terminus and posterior circle of Willis affected in about 20% of cases later in the disease and less often associated with symptomatic presentation.²

When MMA is associated with recognizable systemic pathologic traits, the condition is referred to as a Moyamoya syndrome (MMS). Examples of MMS include Down syndrome, neurofibromatosis, and sickle cell disease.⁶⁰ When not associated with any recognizable physical or pathologic traits affecting tissues beyond the circle of Willis vessels, it is referred to as Moyamoya disease (MMD). In general, there is a much higher incidence of MMD in Asian countries, but MMD is increasingly prevalent in the United States.^{57,61} It is unclear if the higher incidence of MMD in Asian countries is accounted for by genetic factors, environmentally based injury factors (ie, endemic mycobacterial infection), or some combination of these.

Although MMD was originally described as idiopathic, MMD has long been known to harbor an inherited predisposition. Recently, mutations in the *RNF213* gene have been shown to cause susceptibility to the isolated development of MMA in otherwise normal individuals.⁶² Although it was once believed that MMD represents a single disease process, it is likely that the genetic factors contributing to the development of MMD are a diverse and heterogeneous group with population dependent variability, and future studies will reveal additional susceptibility genes.

b. Presentation, symptoms, and diagnosis

In the pediatric population, the first onset of MMA is most often seen between

ages 5 to 9 y old (school age children).⁵⁸ MMA most often presents acutely with ischemic events, seen in 51% of pediatric patients.⁵⁸ However, prior to an acute onset of AIS, patients often report a long history of mild to severe headaches.⁶³

Diagnosis of MMA relies on neuroimaging with brain MRI, CT, CTA, MRA, and/or CA (see Fig. 4). In acutely symptomatic pediatric patients, brain imaging studies most often show infarcts in cerebral watershed zones and deep white matter watershed zones, often varying in age from acute to chronic. Brain MRI studies obtained in children with MMA will frequently reveal prominent moyamoya collaterals on T2 weighted imaging sequences, and angiomatous leptomeningeal collaterals in the form of sulcal hyperintensity ('ivy sign') on FLAIR images. Vascular imaging studies reveal the presence of stenosis or occlusion involving the terminal ICA, M1 or A1 with moyamoya collaterals depicted as abnormal vascular networks in the basal subarachnoid cisterns, corpus striatum, and internal capsule.^{59,64} The changes are most often bilateral, though asymmetry is often present. CA is often performed for surgical treatment planning because the uniquely superior spatial and temporal resolution of CA enables detailed characterization of collateral circulation patterns and external carotid branch anatomy. In MMA patients undergoing cerebral revascularization surgery, preservation of transdural collaterals is particularly important for prevention of ischemic surgical complications, and CA provides neurosurgeons with the vascular roadmap that is necessary to avoid interruption of such collaterals during craniotomy.⁶² Many grading systems for MMA have been proposed, the most well-known of which is the Suzuki system, which is based on CA (see above).⁶⁵ Black Blood VWI has also been studied as an imaging modality in MMA. Black Blood VWI can depict the constrictive remodeling that typifies MMD,⁶² and some series have associated strong concentric mural enhancement on Black Blood VWI with a poor prognosis.⁶⁶

c. Management and treatment

In MMA, revascularization surgery reduces recurrent stroke risk, and is therefore

indicated for clinical symptoms of transient ischaemic attack, cognitive decline, or neuroimaging showing evidence of progression.⁵⁸ Surgical treatment in asymptomatic patients is controversial, although revascularization is reportedly associated with decreased progression of symptoms including headaches, and ischemic strokes.^{61,67} The FLAIR 'ivy sign' has been used as surrogate for slow flow in angiomatous leptomeningeal collaterals indicating a need for revascularization, although it is subject to variation from differences in imaging and sedation techniques.⁶⁸ Other modalities of treatment include anti-platelet therapy, salt, blood pressure augmentation, and rehydration to improve cerebral blood flow.^{69–78} Intravenous thrombolysis, while used in other types of pediatric AIS, is relatively contraindicated in MMA due to the high risk of hemorrhage from the fragile collateral vasculature.⁶⁷ In

MMA due to sickle cell disease, exchange transfusion plays a critical role in AIS treatment and stroke prevention. Reversal of the MMA phenotype by hematopoietic stem cell transplant in pediatric Sickle cell disease has been reported.⁷⁹

3. Multi-focal arteriopathy (MFA)

Multi-focal cerebral arteriopathy is the least common pattern of steno-occlusive intracranial large vessel arteriopathy phenotype encountered in children. It is characterized by involvement of the anterior circulation bilaterally, and/or the posterior circulation and is often accompanied by involvement of small to medium size intracranial arteries. In contrast to MMA, multi-focal cerebral arteriopathy often involves the posterior circulation and may be driven by immunoinflammatory processes (infectious and autoimmune forms of CNS vasculitis, including the cerebral arteriopathy expressed by bacterial meningitis

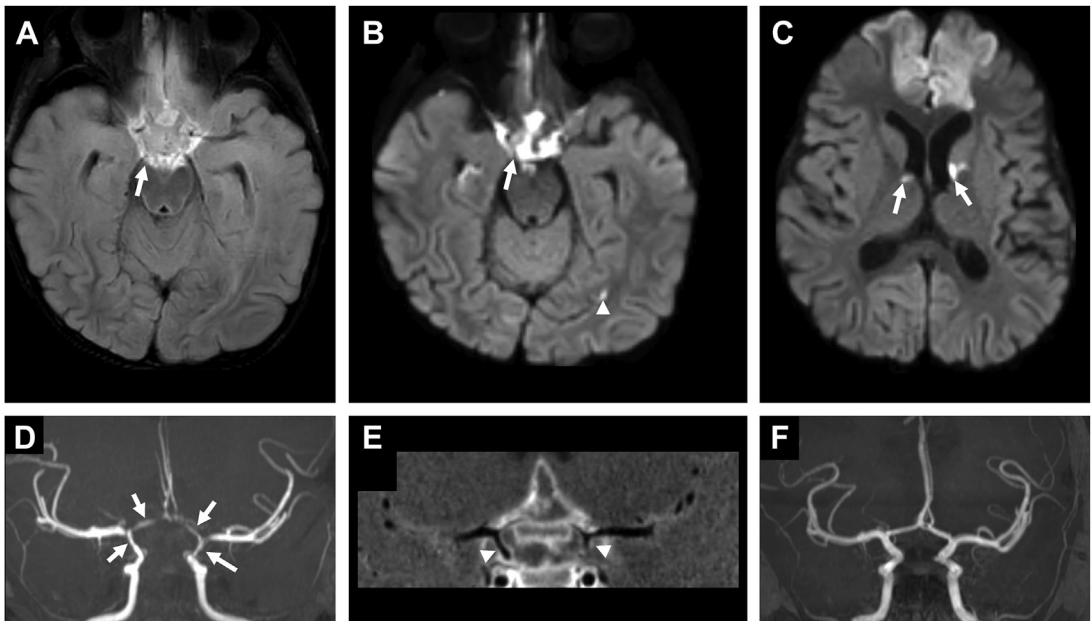


Fig. 5. Intracranial arteriopathy secondary to bacterial meningitis. 18-month-old male presenting with fever of unknown origin, malaise and altered mental status. (A) Axial FLAIR image showing hyperintense material in the suprasellar cisterns surrounding the distal ICAs and optic chiasm (arrow). (B) Axial DWI showing this material is diffusion restricting (arrow), suggestive of purulence. Small amount of intraventricular purulence is also seen (arrowhead). (C) More superior axial DWI image demonstrating restricted diffusion in the bilateral anterior medial frontal lobes corresponding to ACA territory infarctions, as well as small foci of infarction in the right anterior thalamus and left caudate head (arrows). (D) Coronal MIP from TOF MRA showing marked narrowing of the bilateral intradural ICAs and A1 segments (arrows). (E) Coronal post-contrast vessel wall image showing wall enhancement involving these vessels (arrowheads), as well as leptomeningeal enhancement surrounding the optic chiasm and suprasellar cistern. (F) Coronal MRA MIP 1-year later after treatment showing complete resolution of arterial narrowing.

[Figure 5]), maladaptive responses to endothelial injury (reversible cerebral vasoconstriction syndrome) or genetic defects that corrupt mechanical integrity of the arterial wall in diffuse or mosaic fashion (Arterial Tortuosity Syndrome, Ehlers Danlos Syndrome, Loeys Dietz Syndrome, Marfan's Syndrome, Menke's Syndrome, Neurocristopathies). A diverse and heterogeneous group of conditions with varied mechanisms express this phenotype, and thus a comprehensive discussion of pathophysiology, diagnosis, management and treatment is beyond the scope of this review. This steno-occlusive intracranial large vessel arteriopathy phenotype is primarily included to differentiate it from the more common patterns covered in detail above. **Fig. 5**

SUMMARY

a. Neuroimaging points

- i. FCA-i characteristically presents acutely with isolated striatocapsular infarction, but often variably associated with geographic infarctions of cerebral cortex and subcortical white matter in the distribution of the MCA and anterior cerebral artery. The associated stenosis of the intradural ICA ranges from very subtle to severe on initial vascular imaging. Early repeat vascular imaging is indicated, particularly if no stenosis is detected at the time of initial vascular imaging. Collaterals are typically horizontally-oriented bridging lenticulostriate arteries.
- ii. Fast MRI and MRA brain sequences can increase the chances of obtaining images in young children without sedation.
- iii. Intracranial arterial dissection is an important cause of AIS in children. Monofocal intracranial dissection with isolated involvement of the intradural ICA and/or M1 is sometimes referred to as FCA-d and it may or may not be preceded by significant trauma.

MMA are caused by the interaction of vascular injury factors with genetically determined susceptibilities in segmentally vulnerable vessels. Progressive stenosis and occlusion of the intracranial ICA terminus accompanied by formation of moyamoya, transdural, choroidal, and leptomeningeal collaterals is characteristic. The process is bilateral in most cases. Revascularization procedures are a vital treatment modality for patients with MMA.

DISCLOSURE

The authors have nothing to disclose.

REFERENCES

1. Fullerton HJ, Wu YW, Sidney S, et al. Risk of recurrent childhood arterial ischemic stroke in a population-based cohort: the importance of cerebrovascular imaging. *Pediatrics* 2007;119(3):495–501.
2. Wintermark M, Hills NK, DeVeber GA, et al. Clinical and imaging characteristics of arteriopathy subtypes in children with arterial ischemic stroke: results of the VIPS study. *Am J Neuroradiol* 2017;38(11):2172–9.
3. Bernard TJ, Manco-Johnson MJ, Lo W, et al. Towards a consensus-based classification of childhood arterial ischemic stroke. *Stroke* 2012;43(2):371–7.
4. Agrawal N, Johnston SC, Wu YW, et al. Imaging data reveal a higher pediatric stroke incidence than prior US estimates. *Stroke* 2009;40(11):3415–21.
5. Giroud M, Lemesle M, Gouyon JB, et al. Cerebrovascular disease in children under 16 years of age in the city of Dijon, France: a study of incidence and clinical features from 1985 to 1993. *J Clin Epidemiol* 1995;48(11):1343–8.
6. Beslow LA, Agner SC, Santoro JD, et al. International prevalence and mechanisms of SARS-CoV-2 in childhood arterial ischemic stroke during the COVID-19 pandemic. *Stroke* 2022;53(8):2497–503.
7. Mackay MT, Wiznitzer M, Benedict SL, et al. Arterial ischemic stroke risk factors: the international pediatric stroke study. *Ann Neurol* 2011;69(1):130–40.
8. Golomb MR, Fullerton HJ, Nowak-Gottl U, et al. Male predominance in childhood ischemic stroke. *Stroke* 2009;40(1):52–7.
9. Buerki SE, Grandgirard D, Datta AN, et al. Inflammatory markers in pediatric stroke: an attempt to better understanding the pathophysiology. *Eur J Paediatr Neurol* 2016;20(2):252–60.
10. Arnett N, Pavlou A, Burke MP, et al. Vessel wall MR imaging of central nervous system vasculitis: a systematic review. *Neuroradiology* 2022;64(1):43–58.
11. Amlie-Lefond C, Bernard TJ, Sébire G, et al. Predictors of cerebral arteriopathy in children with arterial ischemic stroke. *Circulation* 2009;119(10):1417–23.
12. Sébire G, Meyer L, Chabrier S. Varicella as a risk factor for cerebral infarction in childhood: a case-control study. *Ann Neurol* 1999;45(5):679–80.
13. Nagel MA, Cohrs RJ, Mahalingam R, et al. The varicella zoster virus vasculopathies: clinical, CSF, imaging, and virologic features. *Neurology* 2008;70(11):853–60.
14. Chabrier S, Sébire G, Fluss J. Transient cerebral arteriopathy, postvaricella arteriopathy, and focal

- cerebral arteriopathy or the unique susceptibility of the M1 segment in children with stroke. *Stroke* 2016;47(10):2439–41.
15. Nagel MA, Traktinskiy I, Azarkh Y, et al. Varicella zoster virus vasculopathy. Analysis of virus-infected arteries 2011;77(4):364–70.
 16. Persa L, Shaw DW, Amlie-Lefond C. Why would a child have a stroke? *J Child Neurol* 2022;37(12–14):907–15.
 17. Fullerton HJ, Hills NK, Elkind MSV, et al. Infection, vaccination, and childhood arterial ischemic stroke. Results of the VIPS study 2015;85(17):1459–66.
 18. Vora SB, Amlie-Lefond Catherine, Perez Francisco A, et al. Varicella-associated stroke. *J Pediatr* 2018;199.
 19. Elkind MSV, Hills NK, Glaser CA, et al. Herpesvirus infections and childhood arterial ischemic stroke. *Circulation* 2016;133(8):732–41.
 20. Mirzaee SMM, Gonçalves FG, Mohammadifard M, et al. Focal cerebral arteriopathy in a pediatric patient with COVID-19. *Radiology* 2020;297(2):E274–5.
 21. Nash M, Rafay MF. Craniocervical arterial dissection in children: pathophysiology and management. *Pediatr Neurol* 2019;95:9–18.
 22. Chabrier S, Rodesch G, Lasjaunias P, et al. Transient cerebral arteriopathy: a disorder recognized by serial angiograms in children with stroke. *J Child Neurol* 1998;13(1):27–32.
 23. Oesch G, Perez FA, Wainwright MS, et al. Focal cerebral arteriopathy of childhood. *Stroke* 2021;52(7):2258–65.
 24. Bulder MMM, Braun KPJ, Leeuwis JW, et al. The course of unilateral intracranial arteriopathy in young adults with arterial ischemic stroke. *Stroke* 2012;43(7):1890–6.
 25. Braun KPJ, Bulder MMM, Chabrier S, et al. The course and outcome of unilateral intracranial arteriopathy in 79 children with ischaemic stroke. *Brain* 2008;132(2):544–57.
 26. Fullerton HJ, deVeber GA, Hills NK, et al. Inflammatory biomarkers in childhood arterial ischemic stroke. *Stroke* 2016;47(9):2221–8.
 27. Steinlin M, O'callaghan F, Mackay MT. Planning interventional trials in childhood arterial ischaemic stroke using a Delphi consensus process. *Dev Med Child Neurol* 2017;59(7):713–8.
 28. Beslow LA, Dowling MM, Hassanein SMA, et al. Mortality after pediatric arterial ischemic stroke. *Pediatrics* 2018;141(5).
 29. Fullerton HJ, Stence N, Hills NK, et al. Focal cerebral arteriopathy of childhood. *Stroke* 2018;49(11):2590–6.
 30. Kitchen L, Westmacott R, Friefeld S, et al. The pediatric stroke outcome measure. *Stroke* 2012;43(6):1602–8.
 31. Mineyko A, Narendran A, Fritzier ML, et al. Inflammatory biomarkers of pediatric focal cerebral arteriopathy. *Neurology* 2012;79(13):1406–8.
 32. Goldenberg NA, Jenkins S, Jack J, et al. Arteriopathy, D-dimer, and risk of poor neurologic outcome in childhood-onset arterial ischemic stroke. *J Pediatr* 2013;162(5):1041–6.e1.
 33. Danchaivijitr N, Cox TC, Saunders DE, et al. Evolution of cerebral arteriopathies in childhood arterial ischemic stroke. *Ann Neurol* 2006;59(4):620–6.
 34. Twilt M, Benseler SM. Childhood inflammatory brain diseases: pathogenesis, diagnosis and therapy. *Rheumatology* 2013;53(8):1359–68.
 35. Wintermark M, Hills NK, deVeber GA, et al. Arteriopathy diagnosis in childhood arterial ischemic stroke. *Stroke* 2014;45(12):3597–605.
 36. Mackay MT, Chua ZK, Lee M, et al. Stroke and non-stroke brain attacks in children. *Neurology* 2014;82(16):1434–40.
 37. Lehman LL, Beslow LA, Steinlin M, et al. What will improve pediatric acute stroke care? *Stroke* 2019;50(2):249–56.
 38. Husson B, Rodesch G, Lasjaunias P, et al. Magnetic resonance angiography in childhood arterial brain infarcts. *Stroke* 2002;33(5):1280–5.
 39. Ding J, Duan Y, Zhuo Z, et al. Acceleration of brain TOF-MRA with compressed sensitivity encoding: a multicenter clinical study. *AJNR Am J Neuroradiol* 2021;42(7):1208–15.
 40. Christy A, Murchison C, Wilson JL. Quick brain magnetic resonance imaging with diffusion-weighted imaging as a first imaging modality in pediatric stroke. *Pediatr Neurol* 2018;78:55–60.
 41. De Jong G, Kannikeswaran N, DeLaroche A, et al. Rapid sequence MRI protocol in the evaluation of pediatric brain attacks. *Pediatr Neurol* 2020;107:77–83.
 42. Hernandez-Garcia L, Lahiri A, Schollenberger J. Recent progress in ASL. *Neuroimage* 2019;187:3–16.
 43. Vranic JE, Hartman JB, Mossa-Basha M. High-resolution magnetic resonance vessel wall imaging for the evaluation of intracranial vascular pathology. *Neuroimaging Clin N Am* 2021;31(2):223–33.
 44. Mandell DM, Mossa-Basha M, Qiao Y, et al. Intracranial vessel wall MRI: principles and expert consensus recommendations of the american society of neuroradiology. *AJNR Am J Neuroradiol* 2017;38(2):218–29.
 45. Stence NV, Pabst LL, Hollatz AL, et al. Predicting progression of intracranial arteriopathies in childhood stroke with vessel wall imaging. *Stroke* 2017;48(8):2274–7.
 46. Dlamini N, Yau I, Muthusami P, et al. Arterial wall imaging in pediatric stroke. *Stroke* 2018;49(4):891–8.
 47. Perez FA, Oesch G, Amlie-Lefond CM. MRI vessel wall enhancement and other imaging biomarkers in pediatric focal cerebral arteriopathy-inflammatory subtype. *Stroke* 2020;51(3):853–9.
 48. Tolani AT, Yeom KW, Elbers J. Focal cerebral arteriopathy: the face with many names. *Pediatr Neurol* 2015;53(3):247–52.
 49. Steinlin M, Bigi S, Stojanovski B, et al. Focal cerebral arteriopathy: do steroids improve outcome? *Stroke* 2017;48(9):2375–82.

50. Park Y, Fullerton HJ, Elm JJ. A pragmatic, adaptive clinical trial design for a rare disease: the FOcal Cerebral Arteriopathy Steroid (FOCAS) trial. *Contemp Clin Trials* 2019;86:105852.
51. Braun KP, van der Worp HB. Thrombolysis in childhood ischaemic stroke: still a bridge too far. *Lancet Neurol* 2009;8(6):503–5.
52. Sporns PB, Sträter R, Minnerup J, et al. Feasibility, safety, and outcome of endovascular recanalization in childhood stroke: the save childs study. *JAMA Neurol* 2020;77(1):25–34.
53. Amlie-Lefond C, Shaw DWW, Cooper A, et al. Risk of intracranial hemorrhage following intravenous tPA (tissue-type plasminogen activator) for acute stroke is low in children. *Stroke* 2020;51(2):542–8.
54. Sporns PB, Psychogios MN, Straeter R, et al. Clinical diffusion mismatch to select pediatric patients for embolectomy 6 to 24 hours after stroke: an analysis of the save childs Study. *Neurology* 2021;96(3):e343–51.
55. Chabrier S, Ozanne A, Naggara O, et al. Hyperacute recanalization strategies and childhood stroke in the evidence age. *Stroke* 2021;52(1):381–4.
56. Sun LR, Harrar D, Drocton G, et al. Mechanical thrombectomy for acute ischemic stroke. *Stroke* 2020;51(10):3174–81.
57. Ghaffari-Rafi A, Ghaffari-Rafi S, Leon-Rojas J. Socioeconomic and demographic disparities of moyamoya disease in the United States. *Clin Neurol Neurosurg* 2020;192:105719.
58. Lee S, Rivkin MJ, Kirton A, et al. Moyamoya disease in children: results from the international pediatric stroke study. *J Child Neurol* 2017;32(11):924–9.
59. Elbers J, Armstrong D, Benseler SM, et al. The utility of collaterals as a biomarker in pediatric unilateral intracranial arteriopathy. *Pediatr Neurol* 2018;78:27–34.
60. Kim JE, Jeon JS. An update on the diagnosis and treatment of adult Moyamoya disease taking into consideration controversial issues. *Neurol Res* 2014;36(5):407–16.
61. Guzman R, Lee M, Achrol A, et al. Clinical outcome after 450 revascularization procedures for moyamoya disease. *Clinical article. J Neurosurg* 2009;111(5):927–35.
62. Ihara M, Yamamoto Y, Hattori Y, et al. Moyamoya disease: diagnosis and interventions. *Lancet Neurol* 2022;21(8):747–58.
63. Ibrahim DM, Tamargo RJ, Ahn ES. Moyamoya disease in children. *Childs Nerv Syst* 2010;26(10):1297–308.
64. Kuroda S, Fujimura M, Takahashi J, et al. Diagnostic criteria for moyamoya disease - 2021 revised version. *Neurol Med -Chir* 2022;62(7):307–12.
65. Liu ZW, Han C, Zhao F, et al. Collateral circulation in moyamoya disease: a new grading system. *Stroke* 2019;50(10):2708–15.
66. Hao F, Han C, Lu M, et al. High-resolution MRI vessel wall enhancement in moyamoya disease: risk factors and clinical outcomes. *Eur Radiol* 2024;34(8):5179–89.
67. Sun LR, Lynch JK. Advances in the diagnosis and treatment of pediatric arterial ischemic stroke. *Neurotherapeutics* 2023;20(3):633–54.
68. Scott RM, Smith ER. Moyamoya disease and moyamoya syndrome. *N Engl J Med* 2009;360(12):1226–37.
69. Sporns PB, Fullerton HJ, Lee S, et al. Childhood stroke. *Nat Rev Dis Primers* 2022;8(1):12.
70. Sébire G, Fullerton H, Riou E, et al. Toward the definition of cerebral arteriopathies of childhood. *Curr Opin Pediatr* 2004;16(6).
71. Rawanduzy CA, Earl E, Mayer G, et al. Pediatric stroke: a review of common etiologies and management strategies. *Biomedicines* 2022;11(1).
72. Baltensperger A, Mirsky D, Maloney J, et al. Cost and utility of routine contrast-enhanced neck MRA in a pediatric MRI stroke evaluation protocol. *AJNR Am J Neuroradiol* 2019;40(12):2143–5.
73. Stence NV, Fenton LZ, Goldenberg NA, et al. Cranio-cervical arterial dissection in children: diagnosis and treatment. *Curr Treat Options Neurol* 2011;13(6):636–48.
74. Uohara MY, Beslow LA, Billingham L, et al. Incidence of recurrence in posterior circulation childhood arterial ischemic stroke. *JAMA Neurol* 2017;74(3):316–23.
75. Debette S, Compter A, Labeyrie MA, et al. Epidemiology, pathophysiology, diagnosis, and management of intracranial artery dissection. *Lancet Neurol* 2015;14(6):640–54.
76. Lucas MJ, Brouwer MC, van de Beek D. Neurological sequelae of bacterial meningitis. *J Infect* 2016;73(1):18–27.
77. Zainel A, Mitchell H, Sadarangani M. Bacterial meningitis in children: neurological complications, associated risk factors, and prevention. *Microorganisms* 2021;9(3).
78. Sun LR, Cooper S. Neurological complications of the treatment of pediatric neoplastic disorders. *Pediatr Neurol* 2018;85:33–42.
79. Booth N, Ngwube A, Appavu B, et al. Reversal of cerebral arteriopathy post-hematopoietic stem cell transplant for sickle cell disease. *Pediatrics* 2024;153(2). e2023062643.