

European Course on Pediatric Neuroradiology in Latin America (ECPNA-LATAM)
3rd Cycle - Module 1

Pediatric Intracranial Vascular Malformations



Idealização:   Organização: 

1




European Course on Pediatric Neuroradiology in Latin America (ECPNA-LATAM)
3rd Cycle - Module 1





Bernardo Corrêa de Almeida Teixeira
MD PhD

Neuroradiologist at Curitiba, Paraná, Brazil, working at:

Pequeno Príncipe Childrens Hospital
Neurological Institute of Curitiba
Quanta Diagnostic Imaging

Adjunt Professor of Radiology at
Federal University of Paraná

Idealização:   Organização: 

2

Intracranial Vascular Malformations

European Course on Pediatric Neuroradiology in Latin America (ECPNA-LATAM)
3rd Cycle - Module 1

There is no conflict of interest in this presentation

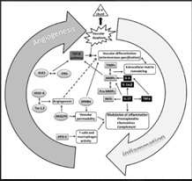
3

Topic for Today

European Course on Pediatric Neuroradiology in Latin America (ECPNA-LATAM)
3rd Cycle - Module 1

1. Vein of Galen Malformations
2. Dural Sinus Malformations
3. Arteriovenous Malformations
4. Pial Arteriovenous Fistula
5. Aneurysms
6. Vascular and Metameric Syndromes

ETIOLOGY
Vasculogenesis and Angiogenesis 4-10weeks
Arrest of early angiogenesis = AVM
Mutations in RAS-MAPK and PI3K/AKT/mTOR



4

Vein of Galen Malformation

European Course on Pediatric Neuroradiology in Latin America (ECPNA-LATAM)
3rd Cycle - Module 1

- <1% intracranial vascular malformations → 1:58.1000 (1/3 vascular anomalies in children)
- Pathological fistula connections w/ venous hipertension → Choroidal arteries and Median prosencephalic vein (Choroidal and Mural Types) / Venous drainage mainly through persistent falcine sinus
- Outcomes → >35% without deficits (3 subgroups → extensive brain damage (10-18%), hemodynamic instability (60%), no brain damage/hemodynamic instability)
- Risk Stratification (chance of decompensation → mediolateral diameter falcine sinus (2-3 mm X 9-10 mm) → Treatment → Partial occlusion of the fistula (20%)

Jaimex, Camilo, Suelly Fazio Ferracoli, and Darren B. Orbach. "Cerebrovascular Anomalies in the Fetus." American Journal of Neurology 46.2 (2025): 231-239


5

Vein of Galen Malformation

European Course on Pediatric Neuroradiology in Latin America (ECPNA-LATAM)
3rd Cycle - Module 1

F. Ido, asymptomatic, diagnosed in the second-trimester ultrasound

Mural Type



THIRD GROUP
(No Brain Damage / Hemodynamic Instability) → Embolization at 6 mo

6

Vein of Galen Malformation

European Course on Pediatric Neurology in Latin America (ECPNR-LATAM) 3rd Cycle - Module 1

F, 1do, Apgar 3/8 with unstable respiratory distress

Follow-up 2 mo after embolization

Choroidal Type

SECOND GROUP (60%)
(Hemodynamic Instability) → Immediate Embolization

7

Vein of Galen Malformation

European Course on Pediatric Neurology in Latin America (ECPNR-LATAM) 3rd Cycle - Module 1

F, 2mo, respiratory distress, cough and excessive crying after birth, ICU aggressive cardiac stabilization

F, 2yo, clinical deterioration after embolization 2 months ago

FIRST GROUP - EXTENSIVE BRAIN DAMAGE "MELTING BRAIN" SYNDROME
High flow → Venous Hypertension/Ischemia → +CSF drainage → Diffuse Brain Destruction
If hydrocephalus <5mo → Embolization (Do NOT shunt!)

Hoang Stanley, et al. "Vein of Galen malformation." *Neurosurgical Focus* 27:5 (2009): E8

8

Dural Sinus Malformation

European Course on Pediatric Neurology in Latin America (ECPNR-LATAM) 3rd Cycle - Module 1

F, 6do, vomiting and hypoactivity

Follow-up after 10 months

SPONTANEOUS REGRESSION

9

Dural Sinus Malformation

European Course on Pediatric Neurology in Latin America (ECPNR-LATAM) 3rd Cycle - Module 1

F, 3mo, palpable left retroauricular pulsatile mass

- Very rare → 80 cases reported in the literature
- Two subtypes → Torcular (low-flow) and Lateral (high-flow)
- Outcomes discordant → 88% no sequela / 46% severe morbidity / death (probably reported cases are more severe)
- Distention of venous dural structures with or w/o intraluminal thrombus → slow flow (1/3 with arterial flow)
- 97% decrease in size spontaneously

James, Camilo, Suley Fazio Ferracoli, and Darren B. Orbach. "Cerebrovascular Anomalies in the Fetus." *American Journal of Neurology* 44:2 (2005): 230-239

Dermarini JI, Zafarino, et al. "Perioperative management of dural sinus malformation and high-flow arteriovenous fistula in an infant." *Acta Neurologica Belgica* 124:2 (2024): 675-677.

10

Arteriovenous Malformation (AVMs)

European Course on Pediatric Neurology in Latin America (ECPNR-LATAM) 3rd Cycle - Module 1

M, 13yo, headache and seizure

- Lower incidence in Children → Rupture more than adults!
- 3-20% of Vascular Malformations → Most common cause brain hemorrhage in children
- Nidus → Immature arteries connected to veins
- Annual risk bleeding → 2-4% (25% mortality)
- Usually Treated → Surgery (67-100%), Endovascular (21%)
- Endovascular followed by surgery 24-48h → + "normal perfusion breakthrough syndrome"

Spetzler-Martin Grade 2

Embolization

Guerrero, Waldo R, Subepta Dardas, and Santiago Ortega-Gutierrez. "Hemorrhagic cerebrovascular pathology in the pediatric population." *Frontiers in Neurology* 11 (2020): 1055

11

Arteriovenous Malformation (AVMs)

European Course on Pediatric Neurology in Latin America (ECPNR-LATAM) 3rd Cycle - Module 1

M, 17yo, headache and seizure

SPETZLER-MARTIN GRADE 5
Size (3-; 4-6; >6) → 1/2/3
Location (Eloquent, Non-Eloquent) → 1/0
Venous Drainage (Deep, Superficial) → 1/0

Spetzler-Martin Grade 5

TABLE 1 | Most common etiologies of spontaneous intracerebral hemorrhage in children.

- Vascular malformations (55%)
- Arteriovenous malformations (59%)
- Cavernous malformations (11%)
- Bleeding diathesis (21%)
- Coagulopathy: liver failure, DIC, congenital
- Thrombocytopenias: malignant ALL, AML, congenital aplastic anemia, bone marrow failure, immune-mediated, substance
- Aneurysm (9%)
- Hemorrhagic primary intracranial tumor (8%)
- Other (10%)
- Hemorrhagic CNS infection
- Cerebral vasculitis
- Meningitis disease
- Med drug abuse

Guerrero, Waldo R, Subepta Dardas, and Santiago Ortega-Gutierrez. "Hemorrhagic cerebrovascular pathology in the pediatric population." *Frontiers in Neurology* 11 (2020): 1055

12

Pial Arteriovenous Fistula (AVFs)

European Course on Pediatric Neuroorology in Latin America (ECPNR-LATAM) 3rd Cycle - Module 1

F, 10yo, minor trauma and headache

Arterial Venous

Embolization

- Non-Galenic Fistulas → anomalous arterio-venous communications in the brain surface
- Superficial single enlarged draining vein w/o nidus
- Cardiac failure and brain damage may occur

James, Camilo, Susly Fabio Ferracioli, and Damien B. Orbach. "Cerebrovascular Anomalies in the Fetus." American Journal of Neurology 46:2 (2009): 231-239

13

Pial Arteriovenous Fistula (AVFs)

European Course on Pediatric Neuroorology in Latin America (ECPNR-LATAM) 3rd Cycle - Module 1

1 day after embolization loss of consciousness

Baseline

1 day after embolization

1 year after embolization

14

Pial Arteriovenous Fistula (AVFs)

European Course on Pediatric Neuroorology in Latin America (ECPNR-LATAM) 3rd Cycle - Module 1

M, 7yo, headache and seizure

1 Pial AVF Multiple Feeders

M, 8yo, headache with vomiting

2 Pial AVFs

After Embolization

Demartini, Zeferino, et al. "Matas test revisited: carotid compression for embolization of high-flow pediatric pial arteriovenous fistulas." Journal of Neurosurgery: Pediatrics 27:3 (2023): 364-367

15

Giant Sacular Aneurysm (>25mm)

European Course on Pediatric Neuroorology in Latin America (ECPNR-LATAM) 3rd Cycle - Module 1

F, 3yo, headache, vomiting and altered mental status

After Embolization

Demartini, Zeferino, et al. "Giant Aneurysm of Posterior Fossa in Childhood." Pediatric Neurosurgery 56:5 (2021): 497-500

16

Giant Sacular Aneurysm (>25mm)

European Course on Pediatric Neuroorology in Latin America (ECPNR-LATAM) 3rd Cycle - Module 1

After 10 days of embolization sudden bilateral hemiparesis

Vasospasm → Balloon

Baseline

After Embolization

5 year Follow-up

Demartini, Zeferino, et al. "Giant Aneurysm of Posterior Fossa in Childhood." Pediatric Neurosurgery 56:5 (2021): 497-500

17

Donut Shape Aneurysm

European Course on Pediatric Neuroorology in Latin America (ECPNR-LATAM) 3rd Cycle - Module 1

M, 7yo, seizures, vomiting left motor deficit, small SAH on CT

ANEURYSMS IN CHILDREN

- Male predominance
- Internal and middle cerebral arteries
- Higher traumatic, thrombosed, dissecting, infectious and fusiform
- Giant in 19% (vertebro-basilar)

DONUT SHAPE ANEURYSM

- 2012 Takeuchi
- Circunferential laminar flow → central thrombosis
- Diferent from giant thrombosed aneurysms → repetitive dissecting leads to trombose

After Embolization

After Embolization

After Embolization

Demartini Z, Zeferino, Renato Fedatto Berardo, and Bernardo CA Teixeira. "Pediatric Donut-Shaped Basilar Artery Aneurysm." World Neurosurgery 185 (2024): 221-223

18

Multiple Giant Aneurysms

European Course on Pediatric Neuroradiology in Latin America (ECPNA-LATAM) 3rd Cycle - Module 1

F, 7yo, headache for 3 weeks, Parry-Romberg Syndrome

LOCALIZED SCLERODERMA
Progressive Soft tissue atrophy → Hemifacial WM abnormalities, calcifications → Rarely aneurysms
Vessel Wall Imaging → Supports vasculitis-related etiology

Vaz, André, and Bernardo Cordeiro de Almeida Teixeira. "Vessel wall MRI in the dissecting pseudoaneurysm related to Parry-Romberg syndrome." *Arquivos de Neuro-Psiquiatria* (2022).

19

PHACES Syndrome

European Course on Pediatric Neuroradiology in Latin America (ECPNA-LATAM) 3rd Cycle - Module 1

M, 8yo, follow-up of ventriculomegaly, facial small hemangiomas

PHACES SYNDROME
9x more in female
P (posterior fossa)
H (hemangioma)
A (arterial)
C (coarctation)
E (eye)
S (sternus)

Diagnosis → Hemangioma + 1 major criteria or 2 minor criteria

20

Cerebrofacial Metameric Syndrome

European Course on Pediatric Neuroradiology in Latin America (ECPNA-LATAM) 3rd Cycle - Module 1

M, 18mo, facial venous malformation

Arrows: DVA
Arrowheads: Venous Ectasia
Short Arrows: Venous Aneurysms
Asterisk: Venous Malformation

No Arterial supply to Venous Aneurysm → DDX Vein of Galen Malformation

Domenici D, Zeffeno D, de Brito G, de Souza D, de Almeida CA, Teixeira B. "Cerebrofacial Venous Metameric Syndrome Mimicking Vein of Galen Aneurysmal Malformation." *World Neurosurgery* 90 (2020): 13-17.
Bingth, Waleed, et al. "Cerebrofacial venous malformations are associated with intracranial developmental venous anomalies and dual venous sinus abnormalities." *American Journal of Neuroradiology* 47 (2020): 1209-1214.

21

Cerebrofacial Metameric Syndrome

European Course on Pediatric Neuroradiology in Latin America (ECPNA-LATAM) 3rd Cycle - Module 1

M, 8yo, suspected Sturge Weber Syndrome, but no Pial angiomatosis

CAMS, SAMS AND CVMS

- Can involve Arteries (Cerebrofacial AMS / Spine AMS) and Veins (CVMS)
- Wide spectrum disorders (venous absence to venous proliferation) → Sturge Weber most common
- 34 metameres (3 in face)
 - Type 1: Medial prosencephalic (olfactory)
 - Type 2: Lateral prosencephalic (optic)
 - Type 3: Rhombencephalic (otic)
- CVMS → Slow-flow lesions (cutaneous, soft tissue and intracranial), DVA and cavernomas

Port-wine Stain **Venous Ectasia**

No arteriovenous shunts

Sinus Agenesis (Sagittal, Straight, Sigmoid)

All Activate MAPK1 → Upregulation of Growth Factors

Domenici D, Zeffeno D, de Brito G, de Souza D, de Almeida CA, Teixeira B. "Cerebrofacial Venous Metameric Syndrome Mimicking Vein of Galen Aneurysmal Malformation." *World Neurosurgery* 90 (2020): 13-17.
Bingth, Waleed, et al. "Cerebrofacial venous malformations are associated with intracranial developmental venous anomalies and dual venous sinus abnormalities." *American Journal of Neuroradiology* 47 (2020): 1209-1214.

22

Take Home Points

European Course on Pediatric Neuroradiology in Latin America (ECPNA-LATAM) 3rd Cycle - Module 1

- Vein of Galen Malformations → Most common fetal/neonatal malformations (Imaging to diagnosis and risk stratification)
- Dural Sinus Malformations → Rare and spontaneously regress in most cases
- Arteriovenous Malformations → Nidus with multiple feeders
- Pial Arteriovenous Fistula → No Nidus with one or more feeders
- Aneurysms → Giant, Dissecting, Donuts
- Vascular and Metameric Syndromes → When see one vascular anomaly look for others and get it all together

23

European Course on Pediatric Neuroradiology in Latin America (ECPNA-LATAM) 3rd Cycle - Module 1

Contact
bernardo.teixeira@ufpr.br

Thank you for your attention!

Idealização: Organização:

24