

Head and Neck Vascular Anomalies in Children



Jeremy S. Ruthberg, MD^{a,*}, Srinivas M. Susarla, DMD, MD, MPH^b, Randall A. Bly, MD^{a,c}

KEYWORDS

- Vascular anomaly • Vascular tumor • Vascular malformation • Hemangioma
- Lymphatic malformation • Propranolol • Sclerotherapy • Facial nerve mapping

KEY POINTS

- Vascular lesions are subdivided into 2 categories: vascular tumors and vascular malformations under the current classification system of the International Society for the Study of Vascular Anomalies.
- Due to complexity and potential for high morbidity and functional impairment, vascular anomaly management requires a multidisciplinary approach, with a combination of medical, laser, chemical, orthognathic, and surgical therapies available.
- Ultrasound can be used as an in-clinic screening tool to evaluate the flow characteristics of vascular anomalies in pediatric patients while limiting ionizing radiation or sedation.
- The standard imaging technique for studying vascular anomalies is magnetic resonance imaging with gadolinium enhancement.

INTRODUCTION

Vascular anomalies represent a diverse and complex set of conditions that can significantly impact the health and well-being of patients. Oral and maxillofacial surgeons are commonly consulted for evaluation of patients with vascular anomalies; vascular anomalies may affect the head and neck in nearly 60% of cases.¹ Vascular anomalies can have significant functional and esthetic concerns for patients. Depending on growth patterns, size, and location, a patient's symptoms may include dysphagia, airway compromise, obstructive sleep apnea, dysfunctional mastication, abnormal speech, and others.

Our understanding of the pathogenesis of vascular lesions has dramatically shifted over the past 40 years. However, the management of facial vascular anomalies remains a challenge,

demanding a multidisciplinary approach. Part of the confusion around management is due to persistence of inconsistent, sometimes inaccurate, largely descriptive nomenclature used by clinicians and researchers. Historically, vascular lesions were classified by descriptors and associations with foods (eg, "cherry", "strawberry," and "port-wine stain"). Others have used the word hemangioma to describe both acquired and congenital lesions.

Mulliken and Glowacki comprised a biologic classification system after analyzing the clinical behavior and endothelial cell characteristics of vascular anomalies in 1982, subdividing vascular lesions into 2 primary categories: hemangiomas and malformations.² Hemangiomas were defined as tumors with abnormal endothelial cell cycles and vascular malformations as structural abnormalities of blood vessels with normal endothelial cells.³

^a Department of Otolaryngology-Head and Neck Surgery, University of Washington Medical Center, 1959 Northeast Pacific Street, UW Box 356515, Seattle, WA 98195, USA; ^b Division of Craniofacial Plastic Surgery, Seattle Children's Hospital, 4800 Sand Point Way NE, OB.9.520, Seattle, WA 98105, USA; ^c Division of Pediatric Otolaryngology-Head and Neck Surgery, University of Washington Medical Center, 1959 Northeast Pacific Street, UW Box 356515, Seattle, WA 98195, USA

* Corresponding author. UW Department of Otolaryngology-HNS, University of Washington Medical Center, 1959 Northeast Pacific Street, UW Box 356515, Seattle, WA 98195.

E-mail address: jruthb@uw.edu

CURRENT CLASSIFICATION

In 2018, the International Society for the Study of Vascular Anomalies updated the classification system for vascular anomalies with 2 primary vascular lesions: vascular tumors (which are then characterized by biologic behavior: benign, locally-aggressive, or malignant) and vascular malformations (which are classified by originating vessel) (Table 1).⁴

VASCULAR TUMORS

Benign Vascular Tumors

Benign vascular tumors include hemangiomas, tufted angiomas, pyogenic granulomas, and others (Table 2).⁴ Classification is based upon growth pattern: focal, multifocal, segmental, or indeterminate and tissue layers involved: superficial, deep, mixed. Hemangiomas are also frequently reported as part of syndromes such as PHACE (posterior fossa malformation, hemangioma, arterial anomalies, cardiovascular anomalies, eye anomalies). Patients with PHACE syndrome may present with central nervous system impairments such as developmental delay or seizures. Such patients should undergo further imaging of the head, ophthalmologic examination, and cardiac evaluation. Finding a hemangioma should alert the clinician about the potential for other concordant findings.

Infantile hemangiomas (IHs) are the most common vascular tumors, occurring in as many as 10% of children, with a female preponderance

ranging from 2:1 to 3:1.^{3,5-7} They also occur more commonly in Caucasian children and premature infants.⁸ These lesions present in the following stages: proliferation, plateau, and involution. They are absent at birth, appearing by about 2 weeks of age as a pale macula with telangiectasias. They then grow rapidly and involute, regressing slowly and predictably over the next few years. The lesion's bright red color fades and dulls over time, becoming softer to palpation (Fig. 1).

Involution can occur gradually and may last until the child is approximately 3 years of age. After complete regression, the child's normal skin is restored in about half of cases, while in the other half, increased skin laxity, discoloration, scarring, telangiectasis, or a residual mass may persist.^{3,9,10}

IHs can manifest either superficially or deeply, penetrating through all skin skills and occasionally extending into muscle. About 20% are multifocal and, in these instances, tumors can grow in the brain, liver, lung, spleen, or gastrointestinal tract, a phenomenon called **disseminated hemangiomatosis**.¹¹ The presence of extensive cutaneous hemangiomas or multiple intrahepatic hemangiomas can result in severe, life-threatening conditions such as congestive heart failure and symptomatic anemia.¹⁰⁻¹² Additionally, when a hemangioma undergoes skin or mucosal breakdown, ulceration and secondary infection may occur.

The proliferating phase of IHs is characterized by elevated endothelial cell turnover.¹³ Capillary endothelial cells exhibit robust growth in tissue culture, forming tubules.^{13,14} During this phase, hemangiomas express endothelial markers such as CD31, CD133, and factor VIII-related antigen (von Willebrand factor).^{9,14-18} Additionally, angiogenic peptides are upregulated during proliferation, including vascular endothelial growth factor (VEGF), basic fibroblast growth factor, proliferating cell nuclear antigen, and type IV collagenase.^{13,16,17}

As IHs enter involution, certain cell types such as mast cells, other monocytes, and fibroblasts propagate and deposit fibrous tissue around vessels and interstices.¹⁹ Apoptosis starts and peaks by about 2 years. Tissue inhibitor of metalloproteinase 1, which suppresses nascent blood vessel formation, is produced and regulated by an auto-crine induction loop.¹³ After complete regression, only a few vessels remain in the hemangioma, and a lining of mature endothelial cells surrounded by fibrofatty tissue pad remains.^{3,9,15,19}

IH diagnoses can be confirmed with molecular staining for glucose transporter 1 (GLUT-1), a protein found in erythrocytes, which facilitates differentiation from other vascular anomalies.^{20,21}

Table 1
Classification of vascular anomalies

Vascular tumors	Benign Locally aggressive/ borderline Malignant
Vascular malformations	<i>Simple:</i> Single distinct vascular malformation <i>Combined:</i> 2 or more distinct vascular malformations found in the same lesion <i>Of major name vessels:</i> anomalies involving origin, course, number, length, diameter, valve, and communication <i>Associated with other anomalies:</i> Vascular malformations in the context of associated syndromes

Table 2
A list of the most common vascular tumors and subcategories

	<i>Behavior</i>	<i>Examples</i>
Vascular tumors	Benign	Congenital hemangioma Tufted angioma Spindle-cell hemangioma Epithelioid hemangioma Pyogenic granuloma Others
	Locally aggressive/borderline	Kaposiform hemangioendothelioma Retiform hemangioendothelioma Papillary intralymphatic angioendothelioma Composite hemangioendothelioma Others
	Malignant	Kaposi sarcoma Angiosarcoma Epithelioid hemangioendothelioma Others

Local tissue hypoxia leads to upregulation of GLUT-1, VEGF, and insulinlike growth factor 2 directly, and indirectly through the renin-angiotensin system. Elevation of these proteins, coupled with the embolization of placental mesenchymal cells, is believed to play a role in promoting endothelial cell proliferation and the progression of IHs. Maternal or infant hypoxic exposure, with pre-eclampsia and preterm birth, has been theorized to lead to IHs.²²

Although the term **intraosseous hemangioma** has been used in the literature to describe what can be slow-flow capillary, venous, or mixed capillary-venous-lymphatic vascular malformations,

IHs typically do not involve the bone.^{9,15,23,24} Skeletal abnormalities, including outer cortex depression, nasal deviation, orbital enlargement, and hypertrophy of the maxilla or mandible, are sporadically observed in association with or following the involution of a sizable cutaneous facial hemangioma. The mechanism underlying this skeletal overgrowth is not well understood but could potentially be linked to heightened blood flow during the tumor's proliferative phase.^{9,24}

Congenital hemangiomas may be detected in utero and manifest as fully developed, soft, discolored masses at birth. Often the mass has overlying telangiectasias. These lesions fall into distinct

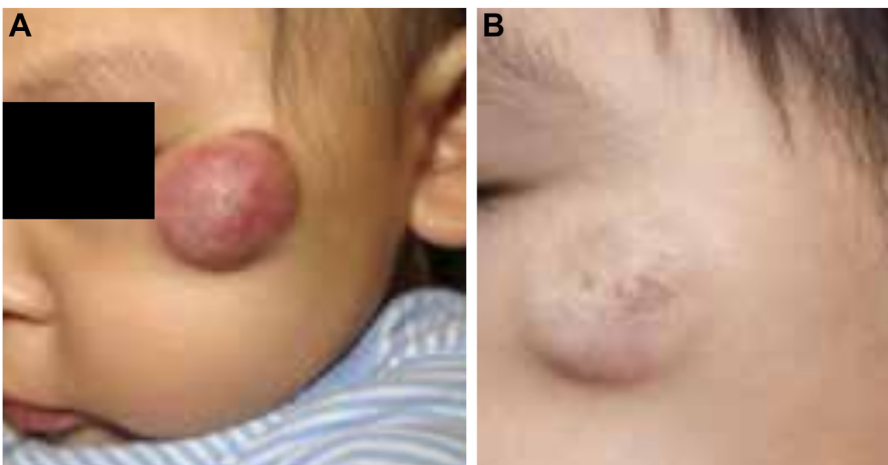

Fig. 1. Infantile hemangioma. (A) A male infant is presenting with a sizable lesion on his left cheek. The parents noticed the lesion shortly after birth, concerned over the rapid growth over the subsequent few months. (B) This patient was treated with propranolol, which led to significant reduction in size and redness of the mass. By year 3, a residual fibrofatty mass remained. (Susarla, S., Bly, R., Mulliken, J., & Kaban, L. (2023). Maxillofacial Vascular Anomalies. In L. Kaban (Ed.), *Oral and Maxillofacial Surgery in Children* (1st ed.). Quintessence Publishing Company, Ltd.).

categories: noninvoluting congenital hemangiomas (NICHs), rapidly involuting congenital hemangiomas (RICHs), and partially involuting congenital hemangiomas (PICHs).^{25,26} NICH lesions exhibit gradual, proportionate growth over time without spontaneous regression. In contrast, RICH lesions do not undergo proliferation postnatally and do undergo rapid involution, typically resolving completely by 2 years of age (Fig. 2).

PICH lesions are generally singular occurrences located in the head or extremities near joints. Surgical excision is frequently necessary during the preschool years for NICHs, while the management of RICH lesions is usually nonsurgical unless complications such as ulceration or bleeding arise. After involution of RICHs, residual atrophic skin may be present, but not residual fibrofatty tissue. In terms of molecular staining, congenital hemangiomas do not express GLUT-1, while IHs do.

Locally Aggressive/Borderline Vascular Tumors

Locally aggressive vascular tumors and those with borderline behavior primarily include hemangioendotheliomas, the most well-known of which is a kaposiform hemangioendothelioma (KHE). Clinically, KHE appear as cutaneous, violaceous lesions that often present in the head and neck. In 1940, the phrase Kasabach-Merritt syndrome was coined to describe a patient presenting with thrombocytopenia, petechiae, and bleeding with a giant hemangioma.²⁷ This, however, is not a syndrome, but instead a constellation of coagulopathic phenomena. It may be associated with KHEs and less frequently with tufted angiomas, but not IHs.^{17,28,29} Kasabach-Merritt phenomenon includes

profound thrombocytopenia ($<10,000 \text{ mm}^3$), low fibrinogen levels, and increased fibrin split products. The prothrombin time and activated partial thromboplastin time can be slightly elevated. Notably, this coagulopathy should **not** be treated with heparin, which may accelerate the growth of the lesion.³⁰ KHE may also be associated with bone resorption, and can lead to localized osteopenia, or disappearing bone disease.³¹

Kaposi sarcoma (KS) is a low-grade, locally aggressive vascular tumor associated with immunosuppressed states, most commonly as an acquired immunodeficiency syndrome-defining malignancy. KS starts as a macule and grows into plaques, and later into nodules.³² It typically involves the skin, mucosa, and viscera. There is currently no cure for KS and surgical excision is restricted for severe issues of cosmesis or to alleviate significant discomfort.

Malignant Vascular Tumors

Malignant vascular tumors include angiosarcomas and epithelioid hemangioendotheliomas. Angiosarcoma does not commonly occur in pediatric patients. In adults, these tumors can be appreciated in sun-damaged areas of the head and neck, breast, or the liver.³³ Cutaneous angiosarcoma has been putatively linked to ultraviolet light exposure or prior radiation exposure.³⁴ Epithelioid hemangioendothelioma has a higher metastatic rate and more aggressive behavior than other hemangioendotheliomas. They typically appear as nonspecific cutaneous nodules, and a vascular tumor may not be suspected at the time of the diagnosis.³⁵

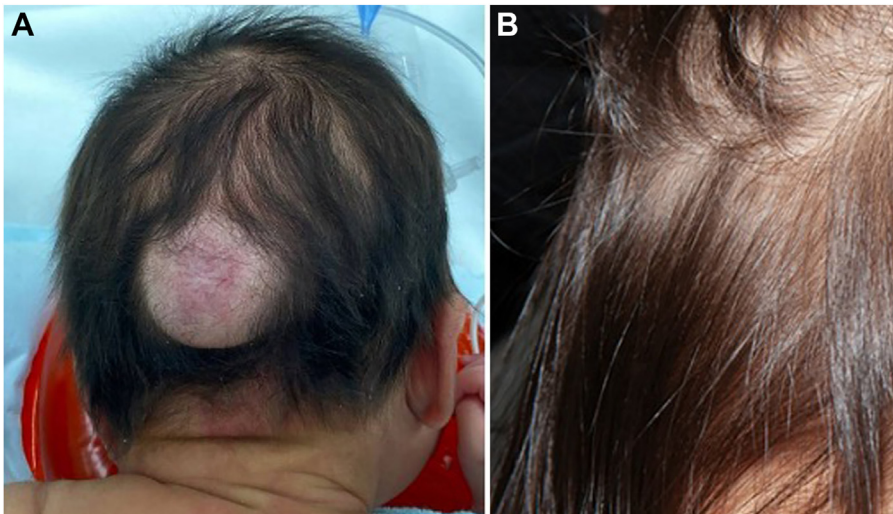


Fig. 2. Congenital hemangioma. (A) An infant born with a rapidly involuting congenital hemangioma (RICH) in the posterior scalp. (B) Involution was nearly complete by 12 months.

VASCULAR MALFORMATIONS

Vascular malformations arise from dysfunctional morphogenesis of blood and lymphatic vessels (Table 3).³⁶ Although present at birth, many may not manifest clinically until late infancy or childhood.^{2,9,15} Malformations typically exhibit proportional growth with the individual, persist throughout life, and may fluctuate due to various inciting factors such as trauma, infection, or endocrine changes (eg, pregnancy and puberty).^{9,23} While most vascular malformations were historically characterized as sporadic, some follow an autosomal dominant pattern. Over the past 2 decades, there has been significant progress in understanding the molecular basis of inherited vascular anomalies.^{37,38}

Approximately one-third of patients with vascular malformations have corresponding skeletal changes.²⁴ This may involve primary intraosseous vascular malformations or associated changes in size, shape, or density of bone adjacent to the malformation.^{22,24} For example, the most common abnormality occurs when the bone beneath a slow-flow cutaneous vascular malformation grows and expands. On a cellular level, these anomalies exhibit a normal endothelial cell cycle, unless affected by thrombosis, trauma, and endovascular or surgical intervention.

Anatomically, vascular malformations are classified based on the vessels involved and their association with other anomalies. They are also categorized by flow characteristics, with differentiation between slow-flow and fast-flow lesions. Simple lesions involve a single malformation and include capillary, venous, lymphatic, arteriovenous (AV) malformations (AVMs), and AV fistulae. Capillary, venous, and lymphatic malformations are characterized as slow-flow lesions, while AVMs are fast-flow lesions.

Although most vascular malformations are simple, combined malformations involving 2 or more malformations within the same lesion can occur. Vascular malformations are described based on the predominant type(s) of vessel(s) involved. For instance, the port-wine stain, once mistakenly referred to as a capillary hemangioma, should be termed a capillary malformation. Similarly, the terms lymphangioma and cystic hygroma are more accurately described as lymphatic malformations. The old term cavernous hemangioma corresponds to a venous malformation, and hemangiolymphangioma indicates a combined lymphaticovenous malformation. Arterial malformations include aneurysms, ectasias, or stenoses, and AV fistulas and malformations are also observed in the maxillofacial region. Most combined malformations demonstrate slow-flow dynamics.

For pediatric patients, lymphatic malformations are the most common vascular malformation found in the head and neck.³⁹ They may appear as ballotable masses that range from blue to dark red depending on whether intralesional bleeding is present.³⁹

Vascular malformations associated with major named vessels comprise a further subdivision. These lesions, also known as “channel type” or “truncal” malformations, can affect veins, arteries, or lymphatics. Anomalies of major named vessels can have a wide variety of presentations, including alterations in vessel origin or course, number of vessels, or persistence of embryonic vessels. Vascular malformations associated with syndromes are categorized separately.

DIAGNOSIS OF VASCULAR ANOMALIES AND MALFORMATIONS

Clinical Examination

IHs. The diagnosis of IHs is primarily clinical. They may be clinically confounded with capillary

Table 3
Vascular malformations

Simple (Single vascular malformation within lesion)	Capillary malformations (low-flow) Lymphatic malformations (low-flow) Venous malformations (low-flow) Arteriovenous malformations (high-flow) Arteriovenous fistula (high-flow)
Combined (2 or more vascular malformations within lesion)	Capillary-venous malformation (CVM) Capillary-lymphatic malformation (CLM) Capillary-arteriovenous malformation (CAVM) Lymphatic-venous malformation (LVM) Capillary-lymphatic-venous malformation (CLVM) Capillary-lymphatic-arteriovenous malformation (CLAVM) Capillary-venous-arteriovenous malformation (CVAVM) Capillary-lymphatic-arteriovenous malformation (CLAVM)

malformations such as port-wine stains, AVMs, dermoid cysts, and pyogenic granulomas.²² In early stages, superficial IHs appear bright red, while deep lesions may have an absence of cutaneous or mucosal discoloration. There is typically firmness to palpation, and although pulsations are absent, a notable Doppler signal is often observed. These lesions exhibit fast-flow characteristics during the proliferation phase and transition to slow-flow during regression. Frequently, dilated cutaneous veins are visible adjacent to the tumor. As IHs involute, the bright red colorization of superficial lesions deepens, small central areas on the surface turn gray, and the mass softens to palpation. Deep hemangiomas, with intact overlying skin, soften and gradually involute, similarly to bright red superficial lesions.⁶ The skin color typically fades to a normal hue, but often there is minor telangiectasia and lost elasticity. After involution, a fibrofatty residual pad may remain in the submucosa.

Vascular malformations. The appearance and structure of vascular malformations vary according to involved vessels. Capillary malformations exhibit a pink hue in infancy, darken during childhood, and take on a deep purple color in older patients. In children, they have a smooth texture resembling normal skin, while in adults, the surface often develops a "pebbly" appearance and becomes slightly raised. Venous malformations appear bluish and are soft, easily compressible, with palpable phleboliths. Venous abnormalities can expand during the Valsalva maneuver or when in a dependent position. Enlargement may occur after injury, partial resection, or be associated with puberty, pregnancy, or the use of medications to suppress ovulation. Lymphatic lesions typically lack color (Fig. 3), while combined lymphatic-venous malformations (previously hemolymphangiomas) have a deep purple-blue hue. They may fluctuate in association with upper respiratory tract infections.

Macrocytic lesions of the head and neck (referred to previously as cystic hygromas) can be transilluminated in the clinic and are often identified prenatally due to increased nuchal translucency.⁴⁰ Within the oral cavity, pure lymphatic malformations or combined capillary-lymphatic malformations frequently display highly irregular surfaces, featuring clear or dark hemorrhagic bullae and vesicles, with resemblance to salmon eggs. AV lesions (AVMs) are warm, sometimes tender, and may exhibit pulsations and a bruit if macroshunting occurs. Schobinger introduced a clinical staging system for AVMs that is helpful in predicting the natural history.^{10,41} Stage I lesions are quiescent; stage II are expansile and

exhibit enlargement, pulsations, and a bruit; stage III are destructive; and stage IV lesions are associated with decompensatory cardiac failure (Table 4).

Intraorally, the mucosa is stained with concurrent gingival hypertrophy. Bleeding may occur around the necks of teeth adjacent to the malformation, and the teeth may be loose and depressible into the alveolus (Fig. 4).

Imaging Studies

Ultrasonography is a useful adjunct for the evaluation of flow characteristics of vascular malformations. It is typically employed as a screening tool, especially for pediatric patients as to avoid utilizing ionizing radiation or sedation.

The standard imaging technique for studying vascular anomalies is MRI with gadolinium enhancement.⁴² On T1-weighted images, IHs appear as a soft tissue mass with intermediate intensity, while on T2-weighted images, they exhibit hyperintensity. Flow voids appear around and within the tumor mass indicating high flow and shunting between arteries and veins.⁹ Involuting hemangiomas demonstrate less flow and increased lobularity and fatty tissue. MRI is useful in differentiating a deep hemangioma from a lymphatic or venous malformation.¹⁰ Short tau inversion recovery sequencing, which is based on T2 but nullifies fat signaling, is particularly useful in evaluating vascular anomalies (Fig. 5). Angiography is not indicated for the diagnosis of hemangiomas, but may be performed prior to endovascular treatment of a vascular malformation.

Plain radiography and computed tomography (CT) detect skeletal changes adjacent to vascular lesions. For example, a large IH may create bony changes due to mass effect or hypertrophy secondary to increased perfusion during the proliferating phase. In contrast, one-third of vascular malformations of the head and neck area show skeletal aberrations.^{24,43} Skeletal changes may include underlying bony hypertrophy (or cartilage when lesions involve the external ear), distortion in shape (seen with venous, lymphatic, or combined lesions), or osteopenia and bony destruction (seen with AV lesions).^{24,43}

Molecular Studies

Comprehensive management of the patient with a vascular anomaly should include genetic testing as a key component. Identification of genetic variants, when present, can not only establish a conclusive diagnosis but also provide valuable guidance for clinical management. Furthermore, it aids in the screening for additional anomalies

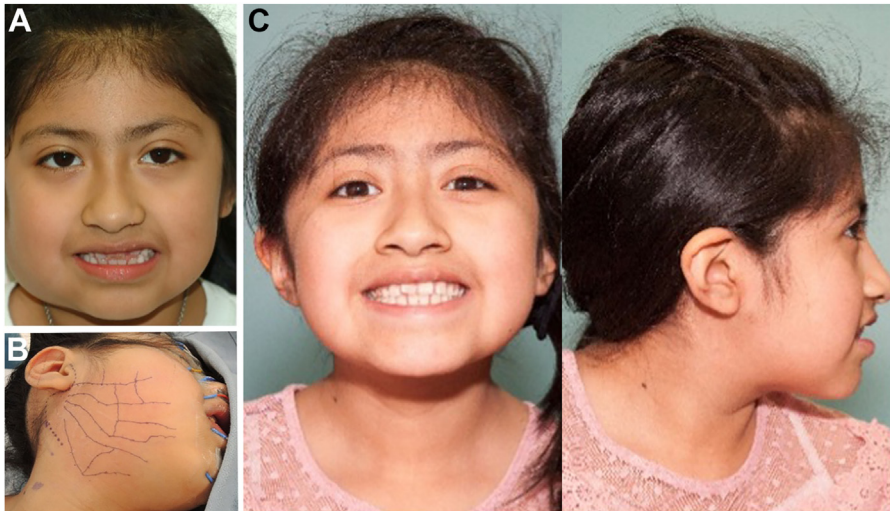

Fig. 3. A female patient with a history of right-sided parotid microcystic lymphatic malformation. (A) At 8 years of age with 2 to 3 months of progressive right facial swelling. (B) Intraoperative facial nerve monitoring during surgical resection. (C) She returned to clinic at 9 years of age after undergoing a right total parotidectomy with lymphatic malformation removal, including a right suprahyoid neck dissection, left upper lip lesion excision, and nasal alar rim lesion excision.

and informs treatment strategy. Notable syndromes with vascular anomalies are listed in [Table 5](#).

The predominance of mutations detected in individuals with vascular anomalies affect 2 key intracellular signaling pathways: phosphoinositide

3 kinase/AKT/mammalian (or mechanistic) target of rapamycin (PI3K/AKT/mTOR) and RAS/mitogen activated protein kinase (RAS/MAPK).³⁸ Each pathway is integral to cell cycle regulation and activating mutations are associated with vascular anomalies and syndromes.

Recent advancements have enabled targeted therapeutic approaches. Patients with overgrowth secondary to vascular anomalies often exhibit somatic activating mutations in PI3K/AKT/mTOR. In such cases, the use of sirolimus, an mTOR inhibitor, has proven effective in curtailing uncontrolled proliferation.⁴⁴ Similarly, recent clinical studies highlight the efficacy of MEK1/2 inhibitors, such as selumetinib, in managing AVMs by targeting the RAS/MAPK signaling pathway.⁴⁵

Table 4 Schobinger clinical staging system for arteriovenous malformations	
Stage	Description
I (Quiescence)	Pink-bluish stain, warmth, and arteriovascular shunting by continuous Doppler scanning or 20-MHz color Doppler scanning
II (Expansion)	Stage I + enlargement, pulsations, thrill, bruit, and tortuous, tense veins
III (Destruction)	Stage II + either dystrophic skin changes, ulceration, bleeding, persistent pain, or necrosis
IV (Decompensation)	Stage III + cardiovascular collapse

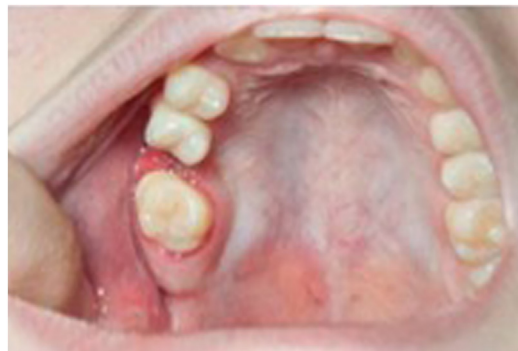

Fig. 4. A patient with a maxillary arteriovenous malformation with localized changes consisting of mucosal staining and gingival hypertrophy.

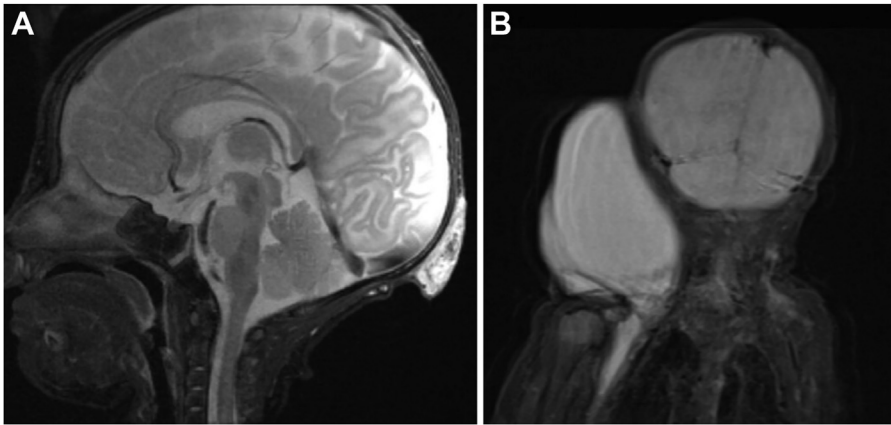


Fig. 5. Use of MRI in various vascular anomalies. (A) MRI with short tau inversion recovery (STIR) sequencing of a patient with a rapidly involuting congenital hemangioma (RICH) along the occipital scalp. The lesion is hyperintense, well circumscribed, with no underlying bony changes or intracranial extension. There is early arterial enhancement with multiple prominent occipital vascular flow voids adjacent to the mass in surrounding soft tissue. (B) MRI with STIR sequencing demonstrating a hyperintense lesion with a major cystic component (10 × 7 × 9.2 cm) indicative of a large lymphatic malformation.

MANAGEMENT AND TREATMENT OF VASCULAR MALFORMATIONS

IHs are typically managed conservatively being allowed to involute and regress spontaneously. While many lesions in the palate, gum, and lips should be observed, some larger head and neck lesions may require more aggressive management due to concerns of disfigurement or functional compromise. Large lesions may lead to adjacent bony or soft tissue hypertrophy. Management requires a multidisciplinary approach, with a combination of medical, laser, and surgical therapy available.

Systemic corticosteroids were previously employed; however, due to their side effect profile, there is a growing shift toward the use of alternative agents, with propranolol emerging as first-line therapy.⁴⁶ Propranolol is a non-selective B1 and B2 adrenergic receptor antagonist and is effective for treating IHs. Potential mechanisms of action include vasoconstriction, inhibition of angiogenesis, or induction of apoptosis. Propranolol dosing is set at 2 to 3 mg/kg/d and divided over 2 to 3 doses. Patient should be monitored continuously for adverse effects such as bronchial hyperactivity, symptomatic bradycardia, hypotension, and hypoglycemia.

Table 5
Notable syndromes associated with vascular anomalies

Syndrome	Clinical Features	Gene
Klippel-Trenaunay	CM + VM ± LM + limb overgrowth	PIK3CA
Parkes Weber	CM + AVF + limb overgrowth	RASA1
Sturge-Weber	Facial + leptomeningeal CM + eye anomalies ± bone and/or soft tissue overgrowth	GNAQ
Maffucci	VM ± spindle-cell hemangioma + enchondroma	IDH1/IDH2
CLOVES	LM + VM + CM ± AVM + lipomatous overgrowth	PIK3CA
Proteus	CM, VM, and/or LM + asymmetrical somatic overgrowth	AKT1
Bannayan-Riley-Ruvalcaba	AVM + VM + macrocephaly, lipomatous overgrowth	PTEN
CLAPO	Lower lip CM + face and neck LM + asymmetry and partial/generalized overgrowth	PIK3CA

Abbreviations: AVF, arteriovenous fistula; AVM, arteriovenous malformation; CLAPO, capillary malformation of the lower lip, lymphatic malformation of the face and neck, asymmetry and partial/generalized overgrowth; CLOVES, congenital lipomatous overgrowth, vascular malformations, epidermal nevi, spinal/skeletal anomalies/scoliosis; CM, capillary malformation; LM, lymphatic malformation; VM, venous malformation.

For IHs that exhibit ulceration, frequent cleansing and topical antibiotics are recommended. When IHs do not respond to propranolol and when there is associated bleeding, significant functional compromise, airway obstruction, or vision loss, surgical management is recommended, and ideally before a child starts school.

Congenital hemangiomas are ineffectively managed by medical therapy. RICHs are typically observed while NICHs may be managed with laser therapy or surgical intervention.

Venous malformations vary in size, from small, well-localized lesions to diffuse lesions that may involve adjacent bone. Adjacent bone can become distorted in shape and size. In rare cases, the venous malformation may exist within craniofacial bones; the mandible is most frequently involved while the maxilla is less commonly affected.

When venous or combined lymphatic-venous malformations cause secondary bony distortion, without direct intraosseous involvement, orthodontic treatment and orthognathic procedures are recommended and can be performed safely, without fear of excessive bleeding. Patients with intraosseous venous malformations that display microshunting may exhibit major hemorrhage spontaneously or intraoperatively. Any hemorrhage must be differentiated between bleeding from the intraosseous vascular lesion or from coagulopathies.

Venous malformations may induce localized coagulation and, at times, disseminated intravascular coagulopathy due to stagnation and turbulence in blood flow. Hematologic studies demonstrate a normal prothrombin time and partial thromboplastin time while fibrin split products and fibrinopeptide may be elevated, with decreased fibrinogen and platelet levels. Heparin treatment should be considered if indicated. Only after correction of the coagulopathy are surgical procedures feasible. Another approach is to begin giving heparin, followed by antifibrinolytic therapy with ϵ -aminocaproic acid. Failure to address the chronic consumptive coagulopathy may lead to issues with hemostasis intraoperatively.

In the past, the mainstay of treatment was surgery. However, resection of venous malformations, particularly large lesions, may be associated with significant morbidity or even disfigurement, especially if lesions are diffuse.⁴⁷ In this context, resection is recommended for the smaller, well-localized lesions, persistently symptomatic lesions despite sclerotherapy, or those in proximity to critical anatomic structures (ie, sensory or motor nerves) where scarring from sclerosing treatment may complicate surgical excision in the future (Fig. 6).

Sclerosing therapy is now recommended for large superficial venous malformations, which requires general anesthesia with concurrent fluoroscopic guidance. Whichever sclerosing agent is utilized (eg, sodium tetradecyl sulfate, ethanol, ethanolamine oleate, bleomycin, or polidocanol) is then injected into the malformation, resulting in an inflammatory reaction and subsequent fibrosis. Usually, several sessions (6–8 weeks apart) are required to reduce large venous malformations. Recanalization is a known phenomenon in venous malformations.⁴⁸ Sclerotherapy can be dangerous and should be performed only by experienced interventional radiologists. Complications include local blistering, prolonged pain or swelling at injection site, full-thickness skin necrosis, and nerve damage.⁴⁹ Systemic complications include hemolysis, transient hemoglobinuria, and potential for renal toxicity and cardiac arrest.^{49,50} Small oral mucosal venous malformations may be treated by injection of 1% sodium tetradecyl sulfate. Notably, malformations are not removed from sclerosing therapy and patients should be counseled that deformities may persist following sclerosing treatment; further treatment may require resection. As more knowledge is gained about genetic etiology, targeted medical therapy is beginning to be an option for these patients.

Commonly, venous and combined lymphatic-venous lesions are associated with intermittent swelling, pain, and fever. For patients with these symptoms, it may be difficult to differentiate between cellulitis, intralesional abscesses, thrombophlebitis, and phlebothrombosis. Upon examination, a local source may be identified (eg, dental caries or a periapical abscess). Management will require appropriate antibiotics (typically penicillin or clindamycin) and subsequent surgical drainage if an abscess is present. Aspirin may be considered in reducing pain if thrombosis is present.⁵¹ In patients who respond to aspirin, the administration of this antiplatelet drug is typically continued indefinitely (325 mg per day).

Lymphatic malformations commonly involve the tongue, floor of mouth, mandible, submandibular, and neck soft tissues. Lymphatic malformations are benign and treatment may be observational unless functional compromise or severe esthetic concerns are present.⁵² Common sequelae such as intralesional bleeding are typically managed nonoperatively. However, lymphatic malformations engender a higher risk of developing superinfections. More than 3 infections annually merit consideration for prophylactic antibiotic therapy. For larger lymphatic malformations, macrocystic lesions, or those that are symptomatic, sclerotherapy should be considered.

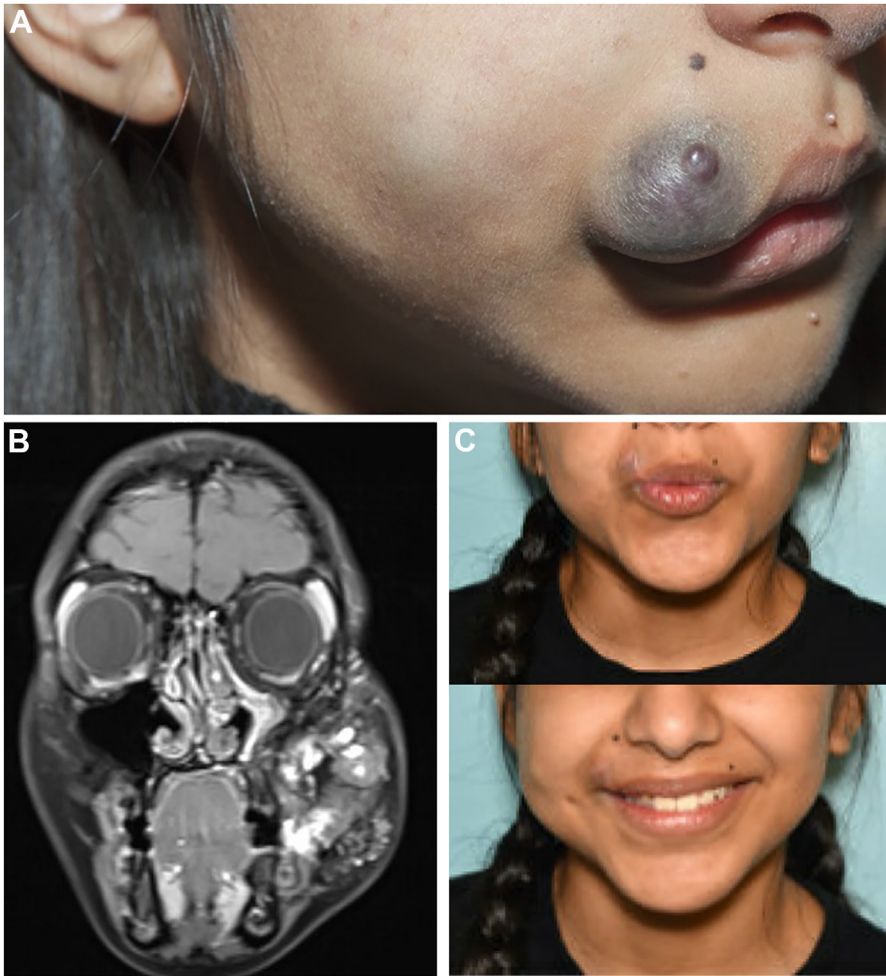


Fig. 6. Venous malformation. (A) A patient with right malar venous malformation previously glue embolized by an interventional radiologist. The lesion was subsequently resected transorally through a buccal incision. (B) MRI demonstrated hyperintense T2 lesion and hypointense T1 in right subcutaneous tissue and masticator space deeply investing temporalis and masseter. No intraosseous component. Lesion was measured at $11.4 \times 9.2 \times 4.5$ cm. (C) Postop photographs at 2 months.

Sclerosing treatment involves evacuation of the malformation cavity by aspiration, followed by injection of chemical agents (eg, sodium tetradecyl sulfate, doxycycline, ethanol, bleomycin, and picibanil—OK432) that induce scarring between the walls of the lesion. Sclerotherapy is minimally invasive and has a lower morbidity when compared to surgical resection. Serial treatments, 6 to 8 weeks apart, may be required. Ulceration of the overlying soft tissue is the most common adverse event and most observed when ethanol is used as a sclerosing agent or when lesions are superficial. Due to size, sclerosing agents are less effective with microcystic malformations. Recent advances in targeted molecular therapies have facilitated the introduction of oral medications (eg, sirolimus) for

managing severe microcystic lymphatic malformations. Based upon similar pathophysiologic characteristics, sirolimus has also emerged as a potential treatment for Gorham-Stout disease (“vanishing bone disease”).⁵²

In some cases, large lymphatic malformations can lead to highly morbid, functional impairments such as airway obstruction and feeding difficulties (Fig. 7).

In older children, bony hypertrophy and malocclusion develop adjacent to the lesion.⁵³ Patients with macroglossia may be prone to developing mandibular prognathism and open bite secondary to the progressive mandibular distortion. Patients with these complications usually undergo multiple surgical procedures, which may consist of cervical

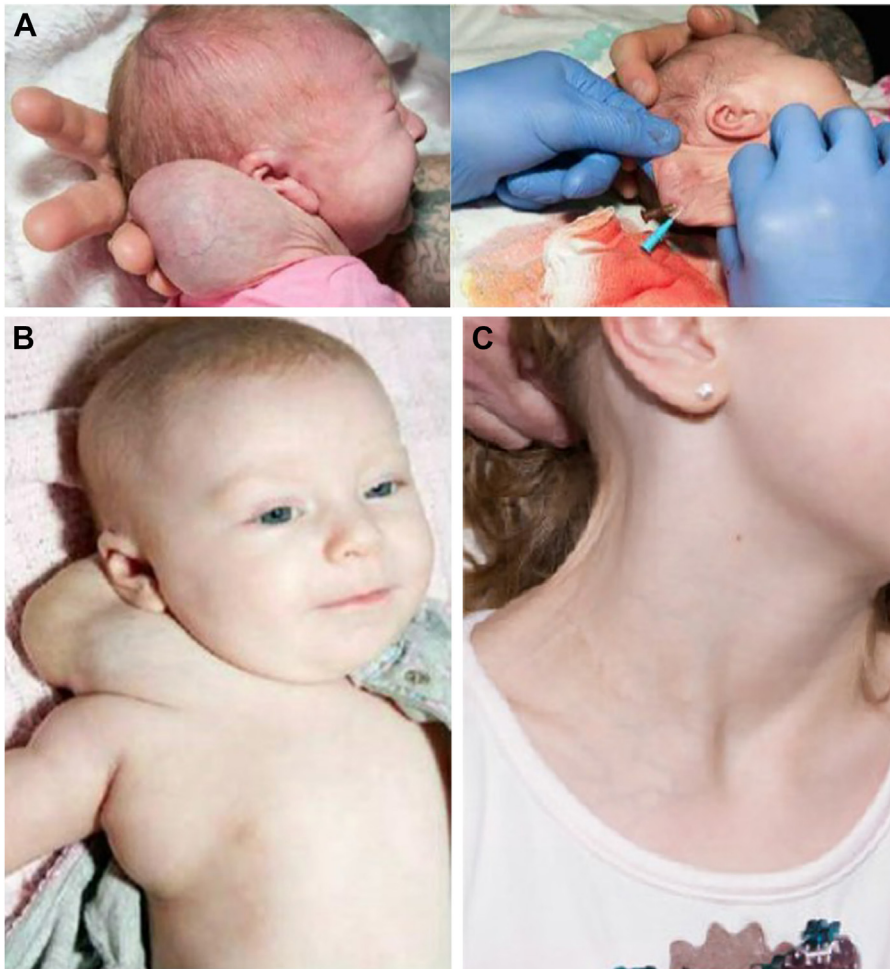

Fig. 7. A female patient with history of a complex cystic lymphatic malformation in the right supraclavicular neck that extended between the sternocleidomastoid and trapezius and inferiorly below her clavicle into her right axilla. She underwent multiple aspirations prior to definitive resection at 18 months. (A) At 2 weeks, initial aspiration. (B) At 3 months of age, seen in clinic to discuss surgical interventions. (C) Age 6 years, presenting for interval follow-up, demonstrating full recovery. She reported no functional deficits, without any breathing or swallowing concerns.

excision, lingual reduction, and various orthognathic surgical procedures. Orthognathic correction is typically performed after the completion of growth, and only if the lingual size and position allow for it, such as in the case of mandibular setback.

Capillary malformations also occur in isolation or in association with lymphatic, venous, or arterial malformations. In such combined vascular anomalies, management is based on the characteristics of the predominant, deeper malformation. Cutaneous capillary malformations may be seen in the mid and upper face and can be associated with Sturge-Weber syndrome (SWS), which can involve capillary malformations in eyes and leptomeninges.⁵⁴ High suspicion for SWS warrants a

brain MRI and ophthalmology consultation. Laser therapy has proved to be highly effective for the management of superficial component of capillary malformations. Typically, the use of pulsed dye laser ($\lambda=595$ nm) treatment is employed to brighten the lesion. This is performed serially, with treatments spaced 6 weeks apart, until there is a treatment response plateau. As lesions progress to thicker and darker states, pulsed-dye laser treatment becomes less effective. Notable advantages of early treatment (infancy or early childhood) include superior lightning, reduced risk of hyperpigmentation, and the potential for decreased psychological impact.

A rare, hereditary form of vascular malformation occurring intraorally is hereditary hemorrhagic

telangiectasia (HHT). It follows an autosomal dominant inheritance pattern.¹⁵ Patients with HHT typically present with difficult-to-control epistaxis, but other organs can be involved in leading to gastrointestinal bleeding, stroke, cardiac failure, among others, with management options varying depending on organs involved.⁵⁵ Intraoral manifestations also occur exhibiting characteristic ectasia from extremely thin endothelial walls.

AVMs represent high-flow lesions where shunting occurs between arterial and venous circulations. In the maxillofacial region, they predominately involve the dentoalveolar segment. Sequelae may include loose teeth, gingival bleeding, and potential massive hemorrhage, either spontaneously or intraoperatively. AVMs are slightly more prevalent in females (male to female ratio of 1:1.5), occurring in the head and neck more frequently than in the extremities or trunk. While often noticed at birth, AVMs may be overlooked due to their seemingly innocuous nature, with symptoms becoming evident later in childhood. Patients typically seek evaluation and treatment when AVMs expand and cause symptoms, commonly triggered by trauma, puberty, or pregnancy.

Diagnostic tools include ultrasonography, color Doppler examination, MRI, magnetic resonance angiography, and CT scans.⁵⁶ Super-selective arterial embolization reserved for treatment represents a significant advance in managing inflow. Although not curative, it can be lifesaving in acute bleeding situations. AVM management has evolved, emphasizing intervention for symptomatic relief, bleeding control, preservation of function, and improving associated deformities. Cure is rarely achieved due to the extensive involvement of multiple tissue planes.

Asymptomatic AVMs may be observed longitudinally or excised, particularly in anatomically safe regions. Caution must be exercised during surgery to prevent enlargement or collateral flow

development. Interventions for higher Schobinger stage lesions (III and IV) aim at palliating pain, bleeding, or congestive heart failure. Ligation or proximal embolization is contraindicated due to rapid collateral flow development.

The current management strategy involves arterial embolization followed by surgical excision 24 to 72 hours after embolization. The timing is crucial to prevent recanalization. Surgical goals include complete resection of the AVM nidus and involved tissue, with soft tissue defects managed through adjacent tissue transfers. In tooth-bearing areas, long-term bleeding control may be challenging. A strategy involving tooth removal, socket packing, and oversewing has been successful. Unfortunately, AVMs often recur, with a reported overall success rate of 60%, varying by Schobinger stage. For stage III lesions, embolization is palliative, and reoperation may not be feasible.

Vascular Lesions Adjacent to the Facial Nerve

Depending on the location, some craniofacial vascular lesions put the facial nerve at significant risk. The risk of facial nerve injury is higher when managing vascular lesions compared to traditional parotid surgeries, likely due to significant alteration in the facial nerve course.⁵⁷ The course of the facial nerve is conventionally evaluated during surgery with intraoperative nerve integrity monitoring (NIM) (standard NIM), which performs continuous electromyography at 2 to 4 locations.⁵⁸ In 2018, Bly and colleagues performed a retrospective cohort analysis comparing surgical patients receiving NIM or preoperative facial nerve mapping (FNM) and reported significantly less facial nerve injuries in the group with preoperative mapping.^{59,60} FNM may also provide the surgeon with a more targeted approach, reducing intraoperative times, and decreasing the need for anterograde approach with main trunk identification (Fig. 8).

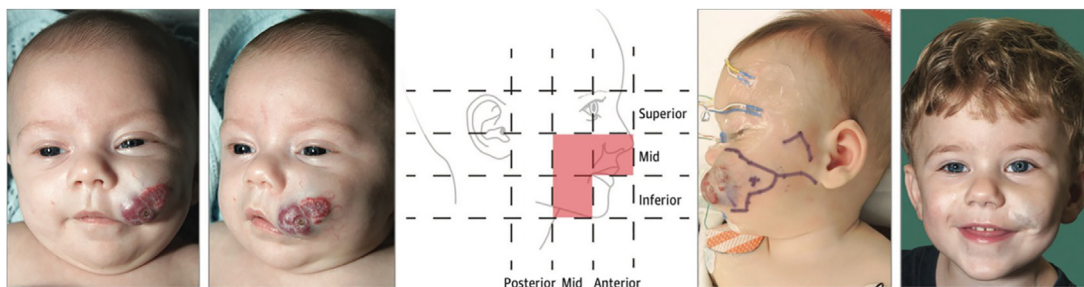


Fig. 8. Preoperative nerve mapping. Preoperative images with a schematic identifying the segments of the facial nerve that is impacted. This infant had an infantile hemangioma that did not respond to propranolol therapy. The lesion was excised directly with peripheral nerve identification and preservation. (From: Bly RA, Holdefer RN, Slimp J, et al. Preoperative Facial Nerve Mapping to Plan and Guide Pediatric Facial Vascular Anomaly Resection. *JAMA Otolaryngol Head Neck Surg.* 2018;144(5):418-426. <https://doi.org/10.1001/jamaoto.2018.0054>)

CLINICS CARE POINTS

- Propranolol has emerged as first-line therapy for managing IHs.
- A combination of sclerotherapy and surgical excision may be necessary in managing large vascular lesions with significant functional impairment.
- Vascular lesions adjacent to the facial nerve may benefit from preoperative FNM.

DISCLOSURE

The authors have nothing to disclose.

REFERENCES

1. Huoh KC, Rosbe KW. Infantile hemangiomas of the head and neck. *Pediatr Clin North Am* 2013;60(4):937–49.
2. Mulliken JB, Glowacki J. Hemangiomas and vascular malformations in infants and children: a classification based on endothelial characteristics. *Plast Reconstr Surg* 1982;69(3):412–22.
3. Mulliken J, Young A. *Vascular Birthmarks: hemangiomas and malformations*. Philadelphia, PA: Saunders; 1988.
4. 2018 International Society for the Study of Vascular Anomalies. ISSVA Classification of Vascular Anomalies. Available at: issva.org/classification. [Accessed 30 April 2024].
5. Jacobs AH, Walton RG. The incidence of birthmarks in the neonate. *Pediatrics* 1976;58(2):218–22.
6. Hand JL, Frieden IJ. Vascular birthmarks of infancy: resolving nosologic confusion. *Am J Med Genet* 2002;108(4):257–64.
7. Enjolras O, Mulliken JB. Vascular tumors and vascular malformations (new issues). *Adv Dermatol* 1997;13:375–423.
8. Amir J, Metzker A, Krikler R, et al. Strawberry hemangioma in preterm infants. *Pediatr Dermatol* 1986;3(4):331–2.
9. Mulliken JB, Fishman SJ, Burrows PE. Vascular anomalies. *Curr Probl Surg* 2000;37(8):517–84.
10. Finn MC, Glowacki J, Mulliken JB. Congenital vascular lesions: clinical application of a new classification. *J Pediatr Surg* 1983;18(6):894–900.
11. Burke EC, Winkelmann RK, Strickland MK. Disseminated hemangiomatosis. the newborn with central nervous system involvement. *Am J Dis Child* 1964;108:418–24.
12. Cooper AG, Bolande RP. Multiple hemangiomas in an infant with cardiac hypertrophy. postmortem angiographic demonstration of the arteriovenous fistulae. *Pediatrics* 1965;35:27–35.
13. Takahashi K, Mulliken JB, Kozakewich HP, et al. Cellular markers that distinguish the phases of hemangioma during infancy and childhood. *J Clin Invest* 1994;93(6):2357–64.
14. Mulliken JB, Zetter BR, Folkman J. In vitro characteristics of endothelium from hemangiomas and vascular malformations. *Surgery* 1982;92(2):348–53.
15. Cohen MM. Vasculogenesis, angiogenesis, hemangiomas, and vascular malformations. *Am J Med Genet* 2002;108(4):265–74.
16. Vikkula M, Boon LM, Mulliken JB. Molecular genetics of vascular malformations. *Matrix Biol* 2001;20(5–6):327–35.
17. Vikkula M, Boon LM, Mulliken JB, et al. Molecular basis of vascular anomalies. *Trends Cardiovasc Med* 1998;8(7):281–92.
18. Yu Y, Flint AF, Mulliken JB, et al. Endothelial progenitor cells in infantile hemangioma. *Blood* 2004;103(4):1373–5.
19. Glowacki J, Mulliken JB. Mast cells in hemangiomas and vascular malformations. *Pediatrics* 1982;70(1):48–51.
20. North PE, Waner M, Mizeracki A, et al. A unique microvascular phenotype shared by juvenile hemangiomas and human placenta. *Arch Dermatol* 2001;137(5):559–70.
21. North PE, Waner M, Mizeracki A, et al. GLUT1: a newly discovered immunohistochemical marker for juvenile hemangiomas. *Hum Pathol* 2000;31(1):11–22.
22. Smith C, Friedlander SF, Guma M, et al. Infantile Hemangiomas: An Updated Review on Risk Factors, Pathogenesis, and Treatment. *Birth Defects Res* 2017;109(11):809–15.
23. Kaban LB, Mulliken JB. Vascular anomalies of the maxillofacial region. *J Oral Maxillofac Surg* 1986;44(3):203–13.
24. Boyd JB, Mulliken JB, Kaban LB, et al. Skeletal changes associated with vascular malformations. *Plast Reconstr Surg* 1984;74(6):789–97.
25. Enjolras O, Mulliken JB, Boon LM, et al. Noninvoluting congenital hemangioma: a rare cutaneous vascular anomaly. *Plast Reconstr Surg* 2001;107(7):1647–54.
26. Boon LM, Enjolras O, Mulliken JB. Congenital hemangioma: evidence of accelerated involution. *J Pediatr* 1996;128(3):329–35.
27. Kasabach HH, Merritt KK. CAPILLARY HEMANGIOMA WITH EXTENSIVE PURPURA: REPORT OF A CASE. *JAMA Pediatr* 1940;59:1063–70. Available at: <https://api.semanticscholar.org/CorpusID:71603949>.
28. Enjolras O, Wassef M, Mazoyer E, et al. Infants with Kasabach-Merritt syndrome do not have “true” hemangiomas. *J Pediatr* 1997;130(4):631–40.
29. Enjolras O, Mulliken JB, Wassef M, et al. Residual lesions after Kasabach-Merritt phenomenon in 41 patients. *J Am Acad Dermatol* 2000;42(2 Pt 1):225–35.

30. Sarkar M, Mulliken JB, Kozakewich HP, et al. Thrombocytopenic coagulopathy (Kasabach-Merritt phenomenon) is associated with Kaposiform hemangioendothelioma and not with common infantile hemangioma. *Plast Reconstr Surg* 1997;100(6):1377–86.
31. Lee S, Finn L, Sze RW, et al. Gorham Stout syndrome (disappearing bone disease): two additional case reports and a review of the literature. *Arch Otolaryngol Head Neck Surg* 2003;129(12):1340–3.
32. Radu O, Pantanowitz L. Kaposi sarcoma. *Arch Pathol Lab Med* 2013;137(2):289–94.
33. Painter CA, Jain E, Tomson BN, et al. The Angiosarcoma Project: enabling genomic and clinical discoveries in a rare cancer through patient-partnered research. *Nat Med* 2020;26(2):181–7.
34. Shon W, Billings SD. Cutaneous Malignant Vascular Neoplasms. *Clin Lab Med* 2017;37(3):633–46.
35. Ko JS, Billings SD. Diagnostically Challenging Epithelioid Vascular Tumors. *Surg Pathol Clin* 2015;8(3):331–51.
36. Kunimoto K, Yamamoto Y, Jinnin M. ISSVA Classification of Vascular Anomalies and Molecular Biology. *Int J Mol Sci* 2022;23(4). <https://doi.org/10.3390/ijms23042358>.
37. Greene AK, Goss JA. Vascular Anomalies: From a Clinicohistologic to a Genetic Framework. *Plast Reconstr Surg* 2018;141(5):709e–17e.
38. Borst AJ, Nakano TA, Blei F, et al. A Primer on a Comprehensive Genetic Approach to Vascular Anomalies. *Front Pediatr* 2020;8:579591.
39. Fevurly RD, Fishman SJ. Vascular anomalies in pediatrics. *Surg Clin North Am* 2012;92(3):769–800, x.
40. Defnet AM, Bagrodia N, Hernandez SL, et al. Pediatric lymphatic malformations: evolving understanding and therapeutic options. *Pediatr Surg Int* 2016;32(5):425–33.
41. Gilbert P, Dubois J, Giroux MF, et al. New Treatment Approaches to Arteriovenous Malformations. *Semin Intervent Radiol* 2017;34(3):258–71.
42. Samadi K, Salazar GM. Role of imaging in the diagnosis of vascular malformations vascular malformations. *Cardiovasc Diagn Ther* 2019;9(Suppl 1):S143–51.
43. Williams HB. Facial bone changes with vascular tumors in children. *Plast Reconstr Surg* 1979;63(3):309–16.
44. Adams DM. Practical Genetic and Biologic Therapeutic Considerations in Vascular Anomalies. *Tech Vasc Interv Radiol* 2019;22(4):100629.
45. Nikolaev SI, Fish JE, Radovanovic I. Somatic Activating KRAS Mutations in Arteriovenous Malformations of the Brain. *N Engl J Med* 2018;378(16):1561–2.
46. Drolet BA, Frommelt PC, Chamlin SL, et al. Initiation and use of propranolol for infantile hemangioma: report of a consensus conference. *Pediatrics* 2013;131(1):128–40.
47. Gurgacz S, Zamora L, Scott NA. Percutaneous Sclerotherapy for Vascular Malformations: A Systematic Review. *Ann Vasc Surg* 2014;28(5):1335–49.
48. Ali S, Mitchell S. Outcomes of Venous Malformation Sclerotherapy: A Review of Study Methodology and Long-Term Results. *Semin Intervent Radiol* 2017;34(03):288–93.
49. Aronniemi J, Castrén E, Lappalainen K, et al. Sclerotherapy complications of peripheral venous malformations. *Phlebology* 2016;31(10):712–22.
50. Cavezzi A, Parsi K. Complications of foam sclerotherapy. *Phlebology* 2012;27(Suppl 1):46–51.
51. Nguyen JT, Koerper MA, Hess CP, et al. Aspirin therapy in venous malformation: a retrospective cohort study of benefits, side effects, and patient experiences. *Pediatr Dermatol* 2014;31(5):556–60.
52. Perkins JA, Manning SC, Tempero RM, et al. Lymphatic malformations: review of current treatment. *Otolaryngol Head Neck Surg* 2010;142(6):795–803, 803.e1.
53. Padwa BL, Hayward PG, Ferraro NF, et al. Cervicofacial lymphatic malformation: clinical course, surgical intervention, and pathogenesis of skeletal hypertrophy. *Plast Reconstr Surg* 1995;95(6):951–60.
54. Comi AM. Update on Sturge-Weber syndrome: diagnosis, treatment, quantitative measures, and controversies. *Lymphat Res Biol* 2007;5(4):257–64.
55. Kühnel T, Wirsching K, Wohlgemuth W, et al. Hereditary Hemorrhagic Telangiectasia. *Otolaryngol Clin North Am* 2018;51(1):237–54.
56. Tanoue S, Tanaka N, Koganemaru M, et al. Head and Neck Arteriovenous Malformations: Clinical Manifestations and Endovascular Treatments. *Interventional radiology (Higashimatsuyama-shi (Japan))* 2023;8(2):23–35.
57. Lee GS, Perkins JA, Oliaei S, et al. Facial nerve anatomy, dissection and preservation in lymphatic malformation management. *Int J Pediatr Otorhinolaryngol* 2008;72(6):759–66.
58. Lowry TR, Gal TJ, Brennan JA. Patterns of use of facial nerve monitoring during parotid gland surgery. *Otolaryngol Head Neck Surg* 2005;133(3):313–8.
59. Bly RA, Holdefer RN, Slimp J, et al. Preoperative Facial Nerve Mapping to Plan and Guide Pediatric Facial Vascular Anomaly Resection. *JAMA Otolaryngol Head Neck Surg* 2018;144(5):418–26.
60. Susarla S, Bly R, Mulliken J, Kaban L. Chapter 14: Maxillofacial Vascular Anomalies. In: Kaban L, editor. *Oral and Maxillofacial Surgery in Children*. 1st edition. Batavia, IL: Quintessence Publishing Co; 2023. p. 246–52.



Role of imaging in the diagnosis of vascular malformations

vascular malformations

Katayoun Samadi, Gloria Maria Salazar

Division of Interventional Radiology, Department of Radiology, Massachusetts General Hospital, Boston, MA, USA

Contributions: (I) Conception and design: All authors; (II) Administrative support: All authors; (III) Provision of study materials or patients: All authors; (IV) Collection and assembly of data: All authors; (V) Data analysis and interpretation: All authors; (VI) Manuscript writing: All authors; (VII) Final approval of manuscript: All authors.

Correspondence to: Gloria Maria Salazar. Division of Interventional Radiology, Department of Radiology, Massachusetts General Hospital, Boston, MA, USA. Email: gmsalazar@mgh.harvard.edu.

Abstract: Imaging evaluation of vascular malformations (VM) is paramount for proper diagnosis and treatment planning. These lesions often present as complex vascular masses with arterial, venous and lymphatic components, requiring the use of advanced imaging modalities for full anatomical characterization. Symptoms also depend of the location and flow characteristic of such lesions and range from: asymptomatic to severe forms of cardiac arteriovenous shunting. We present an overview of the diagnostic work-up of VM per most recent classification systems and describe imaging characteristics of such lesions at ultrasonography (US) and magnetic resonance imaging (MRI) as a diagnostic tool for work-up of such patients.

Keywords: Magnetic resonance imaging (MRI); ultrasound; vascular malformation (VM)

Submitted Jun 01, 2018. Accepted for publication Aug 13, 2018.

doi: 10.21037/cdt.2018.08.06

View this article at: <http://dx.doi.org/10.21037/cdt.2018.08.06>

Introduction

Vascular malformations (VM) are vascular spaces lined by flat epithelium with an estimated prevalence of 4.5% in the population (1). It is usually present at birth, with enlargement proportional to child's growth, but sudden expansion may be seen in infection, hormonal changes or trauma (2). They are the most common childhood soft tissue masses (3). VM occurs due to errors in morphogenesis however they exhibit normal cell turnover unlike vascular tumors (4-6). These lesions can be diffuse or focal, simple or combined based on subtype of vessels involved (7). Appropriate distinction between different VM lead to improved management of lesions, therefore VM can be classified by the type of vessel component (capillary, venous, lymphatic, arterial and hybrid subtype) and according to blood flow dynamics (high and slow flow lesions) (8). Moreover, this classification system combined with detailed physical exam and imaging can have up to 90% accuracy of diagnosis (9). Doppler ultrasonography (US) has been

the first diagnostic modality utilized in the management of patients with VM, due to low-cost, non-ionizing technology and the ability to provide lesions' flow characteristics (10), however magnetic resonance imaging (MRI) has proven advantageous to define extent of the lesions and guide appropriate treatment (11).

In this article, we review the classification of VM, their clinical presentation and role of imaging in their diagnosis.

Current classifications and terminology review

In the last decade, there has been increased knowledge to different aspect of vascular anomalies including histopathology, etiology, and their treatment. Due to its low incidence and heterogenous presentation of clinical and imaging findings, misdiagnosis is common and therefore, correct classification and terminology is paramount for proper clinical management.

The first classification system was proposed by Malan and Puglionisi in 1964 (12), categorizing vascular anomalies

Table 1 Classification of vascular malformations

Slow flow
Lymphatic malformation
Macrocytic
Microcytic
Mixed
Venous malformations
Distensible
Non-distensible
Capillary malformations
Cutis marmorata telangiectasias
Congenital telangiectasias
Fast flow
Arterial malformation
Aneurysm
Atresia
Ectasia
Stenosis
Arteriovenous malformation
Arteriovenous fistula

based on involvement of main trunks or peripheral vessels and then each group into three entities of arterial, venous, and other associated malformations.

In 1988, the Hamburg classification introduced embryological aspects, further subdividing them into either an extra truncular or truncular based on time of developmental arrest during embryonic life (13,14).

A binary approach initially proposed by Mulliken and Glowacki (15) with further revisions in 1996 based on pathologic features by the International Society for the Study of Vascular Anomalies (ISSVA), is now widely accepted by various subspecialists. Correlation of this system with clinical history and treatment options make this approach clinically useful.

The ISSVA divides vascular anomalies into two categories: (I) vascular neoplasm and (II) VM (*Table 1*) (16). While vascular neoplasms have increased rate of endothelial cell turnover, VM are structural abnormalities without cell turnover of capillary, venous, lymphatic and arterial vessels; which may have these elements alone or in combination (7).

This classification also reflects hemodynamic aspect of VM and categorizes them into high flow and low flow lesions (17,18). High-flow lesions should have an arterial component and including arteriovenous malformations (AVM) and fistulas, while low-flow lesions are divided into venous malformation, lymphatic malformation and combined form. The combined form depending on the dominant component is divided further into venous dominant and lymphatic dominant.

Due to the vascular endothelial origin of these lesions, every organ in the body can be affected therefore a multi-specialty approach is required for the management of these conditions. Given the rarity of these malformations correct use of terminology will improve communication among different specialists of multidisciplinary teams.

Diagnostic imaging in VM

A detailed history and clinical examination are paramount for initial evaluation of VM, however, when imaging is required, it is important to choose the appropriate modality for the specific type of malformation. Ultrasound (US) is widely used for initial screening, and can help planning for further imaging assessment (19,20). US should be able to evaluate vascularity if it includes grayscale, color Doppler, and spectral Doppler tracings (19). Given the lack of ionizing radiation, no need for sedation for children and easy accessibility, makes it an appropriate modality for primary classification of these lesions. Another advantage of US is that it can evaluate response to treatment by detecting changes in size and flow characteristic (21,22). However, the limited field of view for large lesions and operator-dependent examination are major limitations as a primary diagnostic modality (23). Multidetector computed tomography (CT) or CT angiography is helpful because of its fast speed and wide availability, especially useful when urgent imaging is required, however, its radiation exposure limits its usage, particularly in the pediatric population (11,22).

MRI features can provide further characterization of sonographic findings and help determine the appropriate management of VM (24). Moreover, it allows to define extent of the vascular lesion and anatomic relationship to adjacent structures (10). High soft tissue resolution and fat suppression characteristics allows to discern the location of vascular anomalies in relation to surrounding soft tissues (23). MRI is also able to differentiate high flow from low flow lesions using dynamic post-contrast sequences (25). The distinction between these two types of lesions depends on rapid filling on

high flow lesions and late filling on low flow lesions (26).

Different MR imaging protocol depends on type of vascularity and location of the lesion (11). To be able to classify and characterize VM, we should initially acquire non-contrast multiplanar T2-weighted fast spin echo and T1-weighted spin echo. Next, contrast in administered and dynamic sequencing images are obtained from arterial and venous phases. After that, post contrast T1 weighted spin echo images are acquired to complete the imaging acquisition (26). On contrast-enhanced MRI, the parenchymal component of VM seems so bright in T2-weighted imaged, and extent of adjacent tissue involvement is well depicted on T1, T2 or short-tau inversion recovery type images (27). Low flow malformations generally homogenous intraluminal signal on T2-weighted imaging, whereas high flow lesions contain voids (10).

Calcification and phleboliths may appear as flow-void and lead to misdiagnosis of low flow and high flow lesion (28) since these lesions are better visualized on CT, obtaining a non-contrast CT would help to better identify the lesion (29).

Since proper classification of VM is paramount for management, below we present imaging characteristic of various VM per different features.

Slow flow malformations

Slow flow VM depending on being local or diffuse have different clinical presentation. Their incidence is 1 in 10,000 in the United States (30). Typically, a detailed physical examination can separate high flow from low flow malformations. In slow flow category, typically one can differentiate them to lymphatic (LM) and venous (VM) subtype by physical exam. To define the extent of the lesions and plan for further management, US and MRI are useful modalities.

US is best primary modality for initial evaluation of patients. Slow flow vascular lesions appear heterogenous defined lesion which can be unilocular or multilocular. Cystic areas are compressible in lymphatic lesions whereas venous malformations are not compressible (31). On the other hand, MRI also can give prognostic information and includes description of extent and tissue involvement. With use of T1 weighted imaging, we can define the anatomy and with fat suppression techniques, we can increase lesion detection by suppressing the bright fat. T1 imaging is useful in differentiating LMs from VMs, LMs enhance peripherally while VMs enhance homogeneously and the chambers within a VM appear heterogenous hyperintense,

whereas, LM remain hypointense and the septa appear hyperintense. In other words, the contrast medium penetrates a VM but not LM. Below is an overview of LMs and VMs in term of description of the lesions.

Venous malformation

Venous malformation is the most prevalent VM with a prevalence of 1% in general population (32). Venous malformation can be found anywhere in the body however, they are more prevalent in head and neck (40%), extremities (40%), and trunk (20%) (33). The Birmingham peripheral limb classification (34) tried to separate venous malformation as to whether they are localized or diffuses, bone joint involvement, fascia or muscle involvement whole limb involvement with or without skin involvement (35). The severity of symptoms depends on size of the lesions and adjacent structure. Lesions may progress during adolescence (75%) and childhood (25%) (36).

US is used as the first line modality to diagnose venous malformations and they appear as slow flow with multiple chambers (*Figure 1A*). Doppler sonography helps the physicians to distinguish high flow from slow flow VM and to differentiate lymphatic from venous malformations (37). VMs typically composed of small chambers on US and phleboliths are detected as a mass with acoustic shadowing and are so typical of venous malformations. CT venography is recommended for to identify underlying pathology, obstructed veins and anatomical variation and extent of venous thrombosis (38). In MRI, venous malformations look hypo- to isointense on T1 weighted images and hyperintense on T2 weighted images (*Figure 1B*). These features allow differentiation of VMs from AVM. On angiographic evaluation, these masses can present with a fistulous component to an adjacent artery (*Figure 1C*). Invasive tests may be required for when non/less invasive tests were not diagnostic. Obstructive truncular VM along iliac vein needs phlebography combined with intravenous ultrasound for proper management (39).

Lymphatic malformation

LMs account for 2.8/100,000 of hospital admissions (37,40). LMs are composed of vessels or large chambers lined by a single layer of endothelial cells. Most commonly, LMs affect head and neck (78%), and an additional 20% occurring in pelvis, axilla, and mesentery (41). Fifty percent of cases are present at birth and more than 90% are diagnosed before

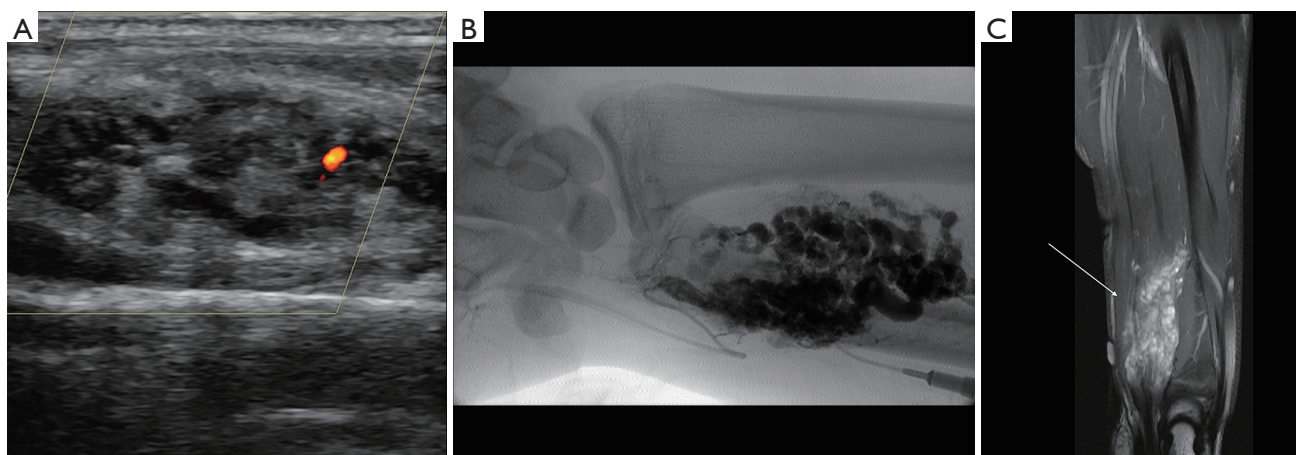


Figure 1 A 23-year-old male with venous malformation in his right distal forearm. (A) Heterogenous structure in the forearm with serpentine appearance with evidence of slow flow in power Doppler. (B) High signal lesion which demonstrates venous malformation. (C) The arrow indicates direct contrast injection of this lesion on angiography demonstrated a large tangle of vessels without clear arterial feeder.

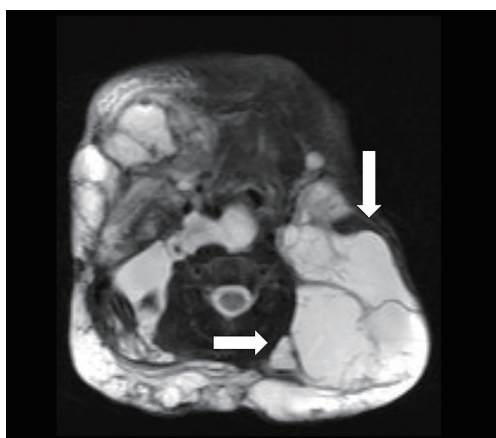


Figure 2 A 5-year-old male with cystic hygroma. Arrows indicates macrocystic, multilocular, rim enhancing, multi-spatial lesion, most consistent with a lymphatic malformation.

age 2 (42). Evaluation of LMs is highly dependent on imaging to define the size and characteristic of the lesions. They are categorized at either macrocytic lesion and microcytic lesions:

- (I) Macrocytic: these lesions have cyst spaces of 2 cm or more and appear as soft masses with trans-illumination and don't exhibit dependency. On US macrocytic lymphatic lesions are characterizes by fewer major anechoic chambers compared to VMs (43);
- (II) Microcytic: these lesions can infiltrate tissues. The affected area has an overlying layer of small

vesicles and present with swollen limb and can be complicated by lymphatic fluid leakage and episode of infection. Staging system based on site and extent of LM has been proposed and correlate well with surgical outcome (44).

Like other VM US is the first line examination and LM appear as small (microcytic) or large (macrocytic) chambers with no detectable flow. Whether chylous or not, the lesions are usually anechoic by US. US may demonstrate hypoechoic compressible channels with absent blood flow on Doppler (45). Macrocytic LMs can be misdiagnosed with VMs but they can be distinguished from VMs based on the size of the chambers and lack of phlebolith, whereas, microcytic lesions are more easily differentiated from VMs as venous malformations show slow flow in 85% of cases (19). MRI is the modality of choice for determine the extent of LMs. LM cavities appear iso to hypointense in T1 imaging and hyperintense in T2 weighted images (*Figure 2*) and as they lack the flow void effect they can be differentiated from high flow lesions. Use of gadolinium facilitate differentiate venous malformation and lymphatic malformations as gadolinium only accumulate in venous malformations. As in VM, CT is never indicated for evaluation of LMs.

Fast flow malformations

Symptoms of high flow lesions depends on the degree of arteriovenous shunting and involved area. They are

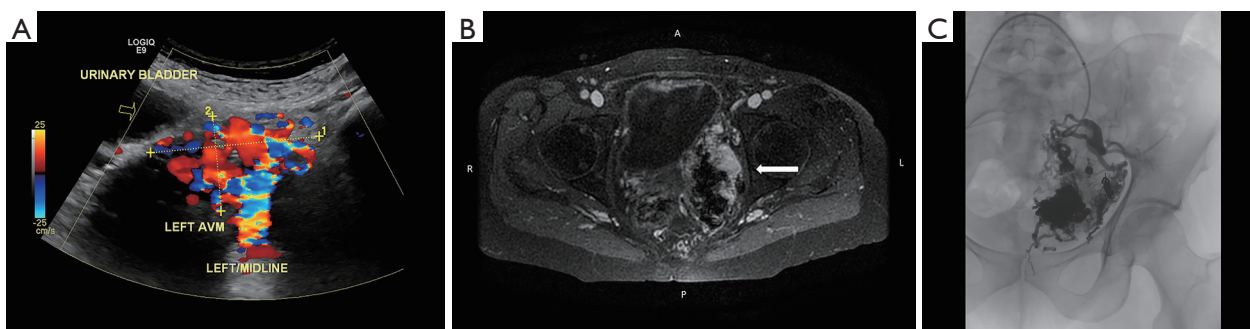


Figure 3 A 67-year-old male with arteriovenous malformation which resulted in hypertension. (A) Axial view in a routine CT angiography of abdomen demonstrates arteriovenous malformation in left hemi-pelvic with arterial feeders from internal iliac artery (yellow arrow). (B) In sagittal view white arrow indicates the arteriovenous malformation. Next to left internal iliac artery there is a cluster of vessels that appear to have arterial supply. (C) Digital subtraction angiography from the left internal iliac artery demonstrates feeder vessels arising from this artery.

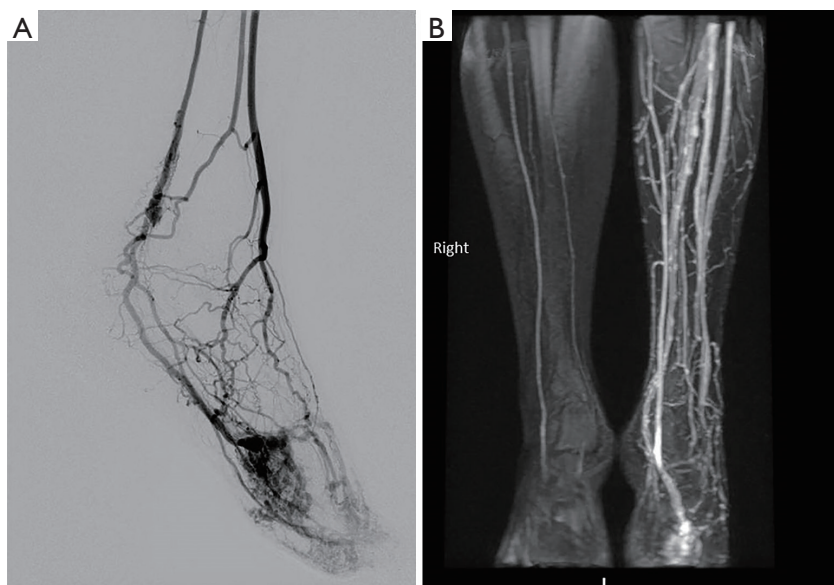

Figure 4 A 36-year-old male with arteriovenous malformation. (A) The arteriovenous malformation results in pitting edema in left lower extremity. (B) MR angiogram of feet: left foot arteriovenous shunting with early draining venous structures suggestive of high-flow AVM. AVM, arteriovenous malformations.

pulsatile lesions without capillary transition between artery and vein, they may present during childhood and grow with child's growth, with periods of rapid growth at puberty at times of trauma, surgery and pregnancy, they may also be due to an iatrogenic cause (11). Venous congestions can lead to pain, hemorrhage, ulceration and high output cardiac failure (19). Like other vascular lesions, US is the first diagnostic modality to both differentiate these lesions from slow flow lesions and plan for further imaging. Cross

sectional can show the key feature of the high flow lesions including a mass like cluster of an arterial and venous structures (*Figure 3*).

Arteriovenous malformation

They are congenital lesion which are compose of dysplastic arteries connected to veins without capillary bed in between. They contain a nidus between venous and arterial bed.

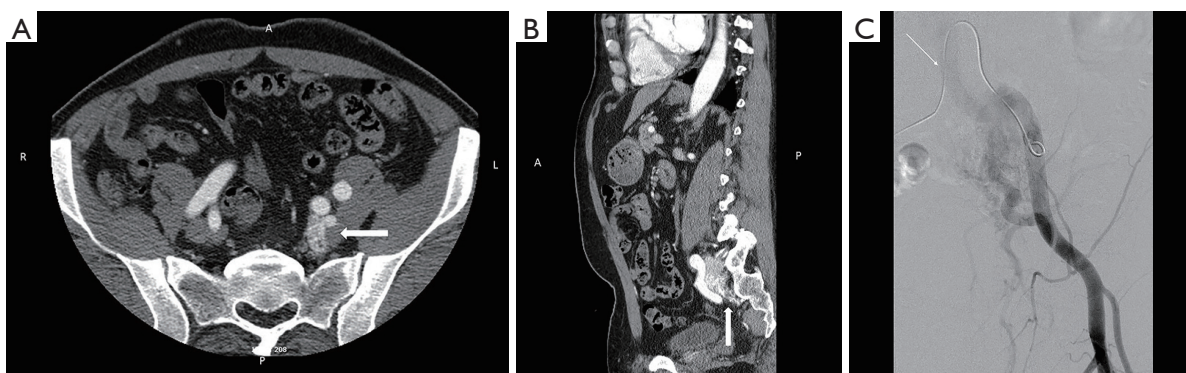


Figure 5 A 75-year-old woman with large left pelvic AVM who initially presented with symptoms related to cardiovascular overload due to the large AV shunt. (A) Doppler ultrasound demonstrates high flow AVM within the pelvis. (B) Large AVM in left pelvic side wall with mass effect (white arrow). (C) Digital subtraction angiography demonstrates a large arteriovenous malformation with extensive arterial supply. Arrow indicated early venous drainage through left internal iliac vein. AVM, arteriovenous malformations.

They are mainly found in the muscles, subcutaneous fat, bone and cranium (11). These lesions are most commonly found in central nervous system and less frequently on limbs (Figure 4) and trunk (Figures 3 and 4) (46). Major complications include: varicose vein bleeding, cardiac failure and aneurysm formation (45). Venous congestions can lead to pain, hemorrhage, ulceration and high output cardiac failure (47).

On US and Doppler sonography, AVM appear as vessels with high systolic and diastolic flow, prominent arteriovenous shunting and pulsatile venous structure (19) on contrast to other VM, CT can also provide useful information regarding adjacent organ involvement and extent of the mass (Figure 4). Contrast enhanced CT allow structural assessment of these lesions (48). On MRI they present as network of arteries and veins connected by a shunt. They demonstrate flow void in T1 an T2 weighted spin echo imaging and are hyperintense on T2 weighted gradient echo imaging indicating rapid flow (Figure 4B) (49). Unlike other VM AVM don't present enhancement of adjacent structures on T2 weighted imaging (49). In conventional MRI findings are vascular flow voids without associated T2 hyperintensity, enhancement or mass on surrounding tissue, however, Patel *et al.* (50) showed 50% of lesions presented with these characteristics and these are more common in lesions that consisting of multiple tissue compartment. Awareness of this atypical features help radiologist not to misdiagnose these lesions. AVMs also require diagnostic angiography (Figures 3C) (51) and they present as dilated arteries with early opacification of dilated veins and in cases that embolization is performed

during the angiography we see that additional arteries become apparent after original vessels are embolized (22,52) (Figure 5).

Arteriovenous fistula

They are usually acquired lesions and most commonly found in the brain (53) and lack the nidus present in VMs in imaging (11). Long standing fistulas may result in limb edema, high output cardiac failure and aneurysmal degeneration of the artery (54,55). Most commonly masses with AV fistula component are iatrogenic lesions from prior surgery and/or trauma and usually there is communication between large vessels. Risk factors for iatrogenic fistula include: female gender, hypertension, left femoral puncture and anticoagulation therapy (56,57).

Like other vascular anomalies, first diagnostic test of choice for diagnosis of arteriovenous fistulas is ultrasound. Arteriovenous fistulas appear as high frequency, low resistance continuous flow with elevated diastolic velocities through pulse cycle.

MRI shows arterial and venous component as high signal intensity without well-defined mass (3). T1W and T2W sequences show serpiginous signal voids without focal mass (3) which are diagnostic for fistula. Intrauterine AVFs are usually secondary to trauma and may present with mild discomfort to feeling of pressure and vaginal and rectal bleeding (58). Most asymptomatic women are diagnosed with US which present as high velocity, low resistance flow and on MRI imaging they appear as high-flow

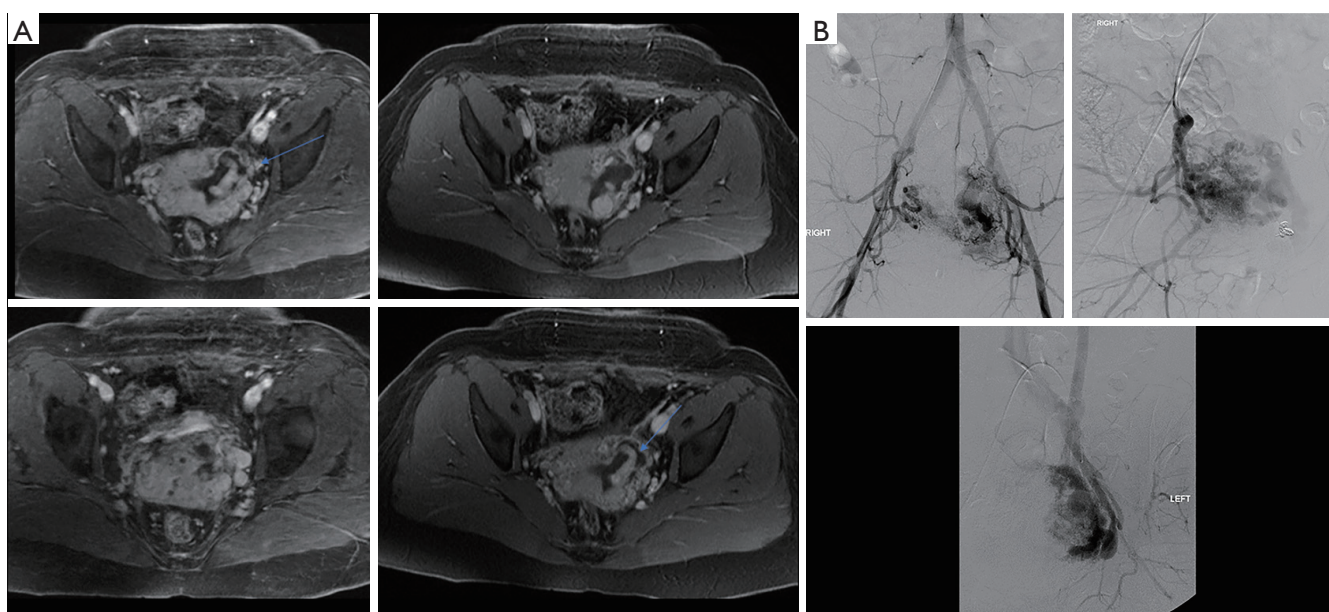


Figure 6 A 32-year-old female post dilation and curettage presenting with vaginal bleeding. (A) MRI demonstrates multiple enlarged vessels with a large draining vein (arrow) and arteriovenous shunting. (B) DSA demonstrates AVM with early venous drainage. AVM, arteriovenous malformations.

serpentine and large arteries and draining veins *Figure 6A*. Areas of high signal on T1 weighted images may be due to hemorrhage or flow related enhancement (58). On angiography, there are enlarged vessels with early venous drainage (*Figure 6B*).

Conclusions

The evaluation of vascular masses is complex and treatment is highly dependent on the imaging work-up and its characteristics. While US evaluation is the first modality for diagnosis of VM, MRI can provide significant information for treatment planning and improvement of symptoms.

Acknowledgments

None.

Footnote

Conflicts of Interest: The authors have no conflicts of interest to declare.

References

1. Greene AK, Kim S, Rogers GF, et al. Risk of vascular anomalies with Down syndrome. *Pediatrics* 2008;121:e135-40.
2. Fishman SJ, Mulliken JB: Hemangiomas and vascular malformations of infancy and childhood. *Pediatr. Clin North Am* 1993;40:1177-1200.
3. Navarro OM, Laffan EE, Ngan BY. Pediatric soft tissue tumors and pseudotumors: MR imaging features with pathologic correlation. Imaging approach, pseudotumors, vascular lesions, and adipocytic tumors. *Radiographics* 2009;29:887-906.
4. Brouillard P, Vikkula M. Vascular malformations: localized defects in vascular morphogenesis. *Clin Genet* 2003;63:340-51.
5. Woollard HH. The development of the principal arterial stems in the forelimb of the pig. In: *Contributions to Embryology*. Washington, DC: Carnegie Institution of Washington, 1922;14:139-54.
6. Lasjaunias P. A revised concept of the congenital nature of cerebral arteriovenous malformations. *Interv Neuroradiol* 1997;3:275-81.
7. Available online: <http://www.issva.org/classification>
8. Lee BB, Bergan JJ. Advanced management of congenital vascular malformations: a multidisciplinary approach. *Cardiovasc Surg* 2002;10:523-33.
9. Foley LS, Ann M. Vascular Anomalies in Pediatrics. *Adv Pediatr* 2015;62:227-55.

10. Dubois J, Kulungowski AM. Vascular anomalies: what a radiologist needs to know. *Pediatr Radiol* 2010;40:895-905.
11. Kollipara R, Odhav A, Rentas KE, et al. Vascular Anomalies in Pediatric Patients Updated Classification, Imaging, and Therapy. *Radiol Clin N Am* 2013;51:659-72.
12. Malan E, Puglionisi A. Congenital angiodysplasia of the extremities: generalities and classification; venous dysplasias. *J Cardiovasc Surg (Torino)* 1964;5:87-130.
13. Belov S. Classification of congenital vascular defects. *Int Angiol* 1990;9:141-6.
14. Belov S. Anatomopathological classification of congenital vascular defects. *Semin Vasc Surg* 1993;6:219-24.
15. Mulliken JB, Glowacki J. Hemangiomas and vascular malformations in infants and children: a classification based on endothelial characteristics. *Plast Reconstr Surg* 1982;69:412-22.
16. Enjolras O. Classification and management of the various superficial vascular anomalies: hemangiomas and vascular malformations. *J Dermatol* 1997;24:701-10.
17. Elluru RG, Azizkhan RG. Cervicofacial vascular anomalies. Vascular malformations. *Semin Pediatr Surg* 2006;15:133-39.
18. Chang MW. Updated classification of hemangiomas and other vascular anomalies. *Lymphat Res Biol* 2003;1:259-65.
19. Dubois J, Garel L. Imaging and therapeutic approach of hemangiomas and vascular malformations in the pediatric age group. *Pediatr Radiol* 1999;29:879-93.
20. Dubois J, Patriquin HB, Garel L, et al. Soft-tissue hemangiomas in infants and children: Diagnosis using Doppler sonography. *AJR Am J Roentgenol* 1998;171:247-52.
21. Flors L, Leiva-Salinas C, Maged IM, et al. MR imaging of soft-tissue vascular malformations: diagnosis, classification, and therapy follow up. *RadioGraphics* 2011;31:1321-40.
22. Legiehn GM, Heran MK. Classification, diagnosis, and interventional radiologic management of vascular malformations. *Orthop Clin North Am* 2006;37:435-74.
23. Tekes A, Koshy J, Kalayci TO, et al. Mitchell Vascular Anomalies Flow Chart (SEMVAFC): A visual pathway combining clinical and imaging findings for classification of soft-tissue vascular anomalies. *Clin Radiol* 2014;69:443-57.
24. Hyodoh H, Hori M, Akiba H, et al. Peripheral vascular malformations: imaging, treatment approaches, and therapeutic issues. *Radiographics* 2005;25 Suppl 1:S159-71.
25. Bashir U, Shah S, Jeph S, et al. Magnetic Resonance (MR) Imaging of Vascular Malformations. *Pol J Radiol* 2017;82:731-41.
26. Lidsky ME, Spritzer CE, Shortell CK. The role of dynamic contrast-enhanced magnetic resonance imaging in the diagnosis and management of patients with vascular malformations. *J Vasc Surg* 2012;56:757-64.e1.
27. Konez O, Burrows PE. An appropriate diagnostic workup for suspected vascular birthmarks. *Cleve Clin J Med* 2004;71:505-10.
28. Abernethy LJ. Classification and imaging of vascular malformations in children. *Eur Radiol*, 2003;13:2483-97.
29. Vilgrain V, Boulos L, Vullierme MP, et al. Imaging of atypical hemangiomas of the liver with pathologic correlation. *Radiographics*, 2000;20:379-97.
30. Cavezzi A, Parsi K. Complications of foam sclerotherapy. *Phlebology* 2012;27:46-51.
31. Lo K, Mihm M, Fay A. Current theories on the pathogenesis of infantile hemangioma. *Semin Ophthalmol* 2009;24:172-7.
32. Eifert S, Villavicencio JL, Kao TC, et al. Prevalence of deep venous anomalies in congenital vascular malformations of venous predominance. *J Vasc Surg* 2000;31:462-71.
33. McCafferty I. Management of Low-Flow Vascular Malformations: Clinical Presentation, Classification, Patient Selection, Imaging and Treatment. *Cardiovasc Intervent Radiol* 2015;38:1082-104.
34. Mendonca DA, McCafferty I, Nishikawa H, et al. Venous malformations of the limbs: the Birmingham experience, comparisons and classification in children. *J Plast Reconstr Aesthet Surg* 2010;63:383-9.
35. Hassanein AH, Mulliken J, Fishman S, et al. Venous malformations: risk of progression during childhood and adolescence. *Ann Plast Surg* 2012;68:198-201.
36. Colletti G, Valassina D, Bertossi D, et al. Contemporary Management of Vascular malformations. *J Oral Maxillofac Surg* 2014;72:510-28.
37. Smith RJ. Lymphatic malformations. *Lymphat Res Biol* 2004;2:25-31.
38. Gloviczki P, editor. Summary of Guideline of American Venous Forum: Handbook of Venous Disorders, 3rd edn. London, UK: A Hodder Arnold, 2008:706-22.
39. Lee BB. Venous malformation and haemangioma: differential diagnosis, diagnosis, natural history and consequences. *Phlebology* 2013;28:176-87.
40. Emery PJ, Bailey CM, Evans JN. Cystic hygroma of the head and neck. A review of 37 cases. *J Laryngol Otol* 1984;98:613-9.
41. Puig S, Casati B, Staudenherz A, et al. Vascular low-flow malformations in children: current concepts for classification, diagnosis and therapy. *Eur J Radiol* 2005;53:35-45.

42. Zadvinskis DP, Benson MT, Kerr HH, et al. Congenital malformations of the cervicothoracic lymphatic system: embryology and pathogenesis. *Radiographics* 1992;12:1175-89.
43. Legiehn GM, Heran MK. A step-by-step practical approach to imaging diagnosis and interventional radiologic therapy in vascular malformations. *Semin Intervent Radiol* 2010;27:209-31.
44. de Serres LM, Sie KC, Richardson MA. Lymphatic malformations of the head and neck. A proposal for staging. *Arch Otolaryngol Head Neck Surg* 1995;121:577.
45. Trenor CC 3rd, Chaudry G. Complex lymphatic anomalies. *Semin Pediatr Surg* 2014;23:186-90.
46. Stapf C, Mohr JP, Pile-Spellman J, et al. Epidemiology and natural history of arteriovenous malformations. *Neurosurg Focus* 2001;11:e1.
47. Mulliken JB, Fishman SJ, Burrows PE. Vascular Anomalies. *Curr Probl Surg* 2000;37:517-84.
48. Wójcicki P, Wójcicka K. Epidemiology, Diagnostics and Treatment of Vascular Tumours and Malformations. *Adv Clin Exp Med* 2014;23:475-84.
49. Gulati MS, Paul SB, Batra A, et al. Uterine arteriovenous malformations: the role of intravenous 'dual-phase' CT angiography. *Clin Imaging* 2000;24:10-4.
50. Patel AS, Schulman JM, Ruben BS, et al. Atypical MRI features in soft-tissue arteriovenous malformation: a novel imaging appearance with radiologic-pathologic correlation. *Pediatr Radiol* 2015;45:1515-21.
51. Siegel MJ. Magnetic resonance imaging of musculoskeletal soft tissue masses. *Radiol Clin North Am* 2001;39:701-20.
52. Yakes WF, Krauth L, Ecklund J, et al. Ethanol endovascular management of brain arteriovenous malformations: initial results. *Neurosurgery* 1997;40:1145-52.
53. Lee HJ, Kwon BS, Kwon JH, et al. Arteriovenous malformation incidentally found by ultrasonography in a thigh hematoma after contusion. *Ann Rehabil Med* 2012;36:287-90.
54. Kron J, Sutherland D, Rosch J, et al. Arteriovenous fistula: a rare complication of arterial puncture for cardiac catheterization. *Am J Cardiol* 1985;55:1445-6.
55. Glaser RL, McKellar D, Scher KS. Arteriovenous fistulas after cardiac catheterization. *Arch Surg* 1989;124:1313-5.
56. Kim D, Orron DE, Skillman JJ, et al. Role of superficial femoral artery puncture in the development of pseudoaneurysm and arteriovenous fistula complicating percutaneous transfemoral cardiac catheterization. *Cathet Cardiovasc Diagn* 1992;25:91-7.
57. Oweida SW, Roubin GS, Smith RB, et al. Postcatheterization vascular complications associated with percutaneous transluminal coronary angioplasty. *J Vasc Surg* 1990;12:310-5.
58. Christenson BM, Gipson MG, Smith MT. Pelvic Vascular Malformations. *Semin Intervent Radiol* 2013;30:364-71.


Cite this article as: Samadi K, Salazar GM. Role of imaging in the diagnosis of vascular malformations vascular malformations. *Cardiovasc Diagn Ther* 2019;9(Suppl 1):S143-S151. doi: 10.21037/cdt.2018.08.06

REVIEW

Open Access

Infantile haemangioma: 5-year experience at the vascular anomaly clinic



Amr Abdelhamid AbouZeid^{1*} , Iman A. Ragab², Shaimaa Abdelsattar Mohammad³, Wael Ahmed Ghanem¹, Haytham Mohamed Nasser⁴ and Osama El-Naggar¹

Abstract

Background: Infantile haemangiomas (IH) represent a common benign vascular tumour affecting the paediatric population. Infantile haemangiomas are characterised by a natural history differentiating it from other vascular anomalies. After a transient proliferative phase in early infancy, the tumour passes through a plateau phase before going into spontaneous involution. In this report, we tried to share our experience over the last 5 years in managing cases presenting with IH at a specialised vascular anomaly clinic.

Main body of abstract: This report included cases of IH who were attending the vascular anomaly clinic during the period 2015 through 2019. Data of all patients attending the clinic were retrospectively examined. Files of 103 cases with IH were available for review. The diagnosis of IH was usually straight forward owing to the typical history and characteristic findings at clinical examination. A significant female predominance was noticed. Generally, IH were more common in the head and neck region (70%). Active intervention was necessary in specific situations (eye occlusion, airway involvement, large lesions with skin ulcerations). Whenever intervention proved to be necessary, propranolol was chosen as the first line of treatment with a favourable response detected in about 90% of cases. Surgery was still a valid option (6%) for lesions amenable to resection; however, we must put in consideration that most lesions will spontaneously regress.

Conclusion: Infantile haemangiomas are common benign vascular tumours of infancy with relatively few complications. Cosmesis is a major concern especially for lesions affecting the face. Propranolol can induce tumour regression in most cases, and generally, a favourable outcome can be anticipated.

Keywords: Haemangioma, Multidisciplinary team, Vascular anomalies, Propranolol, Magnetic resonance imaging

Background

Infantile haemangiomas (IH) constitute the majority of vascular tumours [1], besides being the most common soft tissue tumour in children [2]. Infantile haemangiomas (IH) are characterised by significant heterogeneity with variable presentations affecting different parts of the body [2, 3]. A female predilection has been reported [1–3]; also, IH have been shown to be more common with prematurity and among fair-skinned people [2, 3].

Typically, IH are not present (or very small) at birth; then, the tumour follows a characteristic natural history: rapid proliferative phase (1st year of life), plateau phase, and then goes into spontaneous involution [2].

In 1982, Mulliken and Glowacki proposed their famous classification differentiating between haemangiomas (vascular tumours) and other vascular malformations (hamartomas) [4]. Their classification gained widespread acceptance and succeeded in removing many of the misunderstandings that have accumulated over years from confusing terminology [3]. The classification has been adopted and modified by the International Society for the Study of Vascular Anomalies (ISSVA) in 1996 with further update in 2014 [5]. Another milestone in the

* Correspondence: amrabelhamid@hotmail.com

¹Pediatric Surgery Department, Faculty of Medicine, Ain Shams University, Cairo, Egypt

Full list of author information is available at the end of the article

history of vascular anomalies was the introduction of propranolol to induce regression of IH [6]; several centres reported a high success rate with propranolol in treating IH with strong level of evidence [2].

In this report, we present our experience over the last 5 years in managing cases of IH at a multidisciplinary vascular anomaly clinic.

Main text

This report included cases of IH who were attending the vascular anomaly clinic during the period 2015 through 2019. Other vascular tumours (congenital haemangioma, haemangioendotheliomas) were excluded for having a different management protocol. Also, cases of hepatic haemangiomas were excluded to be discussed in a separate report. Owing to the retrospective nature of the study, an IRB number was not required, and the study was approved through expedited review by the scientific/ethical committee of the Pediatric Surgery department.

Multidisciplinary approach

The idea of a multidisciplinary vascular anomaly clinic was first introduced at our institution by late professor Alaa Hamza in 2008. Currently, the vascular anomaly clinic is held once every 2 weeks (twice per month). The clinic is regularly attended by paediatric surgeons and paediatricians (haematology/oncology) who manage cases together in an integrated manner (interdisciplinary approach) [7]. Paediatric radiologists review all available imaging studies to be discussed with the clinical team highlighting the differential diagnoses and important anatomical findings. Colleagues from other specialties (interventional radiology, ENT, plastic surgery, neurosurgery, ophthalmology, etc.) are consulted independently in specific situations as required (multidisciplinary approach) [7]. At his first visit to the clinic, each patient receives a follow-up card carrying his diagnosis, while follow-up notes can be added successively with further visits. Data including patients' photographs and investigations are stored in an electronic form on a personal computer. Only regular staff members who are running the vascular anomaly clinic are allowed to access the patients' data with special attention to hide the patients' identity in any presentation or publication. The parents are informed about the importance of saving medical data of their children to be available for future studies and interpretations that will serve to improve medical service supplied for children with similar disease.

Digital archiving of 103 cases with IH was available for review. Most of these were cases that had an indication for active intervention (either medical or surgical treatment). A significant female predominance was noticed (female to male ratio = 3:1). Infantile haemangiomas

presented either as segmental (18 %) or more commonly a localised lesion (82%) (Fig. 1). Diffuse (segmental) lesions were noticed to affect the head and neck, trunk, or limbs. Four cases presented with multiple cutaneous haemangiomas (more than three); two of them had associated visceral lesions (liver). Generally, IH were more common in the head and neck region (about 70% in this case series). Table 1 demonstrates the distribution of IH through different parts of the body among cases included in the study. Skin ulcerations were noticed during the rapid proliferative phase of IH in certain regions: genitalia, upper limbs, breast, and periauricular (Fig. 2).

Diagnosis

In most cases, the diagnosis was made on a clinical background (typical history and characteristic appearance; Fig. 1). Investigations (Doppler ultrasound, MRI) were only required for atypical cases, to search for associated anomalies, and before intervention (surgery/injection) if it turned to be necessary [3, 8]. Doppler ultrasound can confirm the presence of 'high' arterial flow differentiating IH from other low flow vascular anomalies. MRI proved to be superior in demonstrating anatomical details of lesions with deeper extensions (e.g. the parotid gland). Typical MRI findings (Figs. 3 and 4) included a well-defined 'mass lesion' with characteristic 'flow voids' (in T1 and T2WI) that showed avid enhancement after IV contrast injection [8, 9].

Medical treatment

Cases with IH can be managed expectantly by waiting for spontaneous involution [1, 10]. This often requires repeated reassurance for the parents as complete regression may be delayed up to the age of 7–9 years [1]. Digital photography of cases successfully managed conservatively can be of great help in reassuring anxious family members (Fig. 5). Active intervention is necessary in specific situations (eye occlusion, Fig. 6; airway involvement; large lesions with skin ulcerations) [1]. IH affecting the face raise major parental concerns urging for early intervention to avoid social stress on the child and his family [2].

Whenever intervention proved to be necessary, propranolol was chosen as the first line of treatment. An oral dose of 2mg/kg/day in three divided doses was generally well tolerated (no complications detected in this case series) with a favourable response in about 90% of cases. The favourable response was in the form of either inducing partial/complete regression (Figs. 2 and 7) or at least interruption of the proliferative phase of the tumour. Before we start oral propranolol treatment, we have to exclude history of congenital heart disease and bronchial asthma. We can start as early as during the neonatal period (usually, IH do not present at birth, but

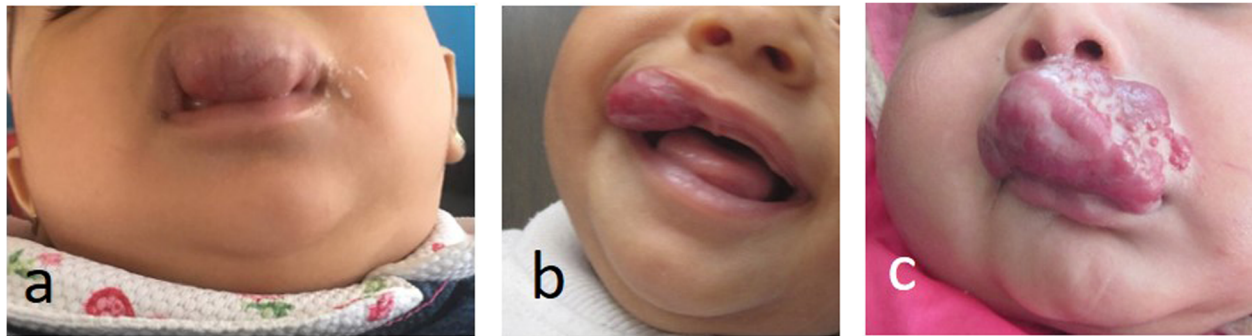


Fig. 1 Infantile haemangioma of the upper lip in three different cases showing the characteristic appearance of red, compressible papules

rather few weeks later). We may start at a lower oral dose (1 mg/kg/day) for 2 weeks; then, we shift to 2 mg/kg/day; in severe cases (airway affection), we may reach 3 mg/kg/day [1, 2]. Early, when we first started to use propranolol in treatment of IH, we used to hospitalise these cases to monitor for any significant changes in their heart rate; later, we have found that to be unnecessary [11]. Alternatively, small superficial lesions can be managed by topical application of timolol maleate solution/gel [12]. Guided by the clinical response (tumour regression) and tumour site-related complications, oral propranolol may be discontinued after reaching the age of 1–2 years (usually gradual tapering of dose over 2–3 months). Very occasionally, a relapse (re-increase in tumour size) after drug discontinuation may be an indication to prolong propranolol treatment for further 6 months.

Although propranolol has greatly replaced corticosteroids in the nonsurgical therapy of IH, systemic corticosteroids (prednisolone 2–5mg/kg/day) may still have a role as an adjuvant treatment with propranolol in critical

situations (airway involvement) [11, 13]. In this series, we had two cases of IH affecting the airway presenting with the characteristic segmental cutaneous lesions in the face ‘beard distribution’ [13]. The first showed good response to propranolol, while the second case presented at the age of 3 months with severe stridor that required tracheostomy before being referred to our clinic. The latter received a combination of oral propranolol and prednisolone to control breathing difficulties. After some time, corticosteroids were discontinued because of systemic side effects and were replaced by the newly introduced drug ‘sirolimus’ [14]. The patient is now stable (2 years old) with shrinkage of subglottic lesions and has been referred to an ENT facility to arrange for weaning her from the tracheostomy tube.

Intralesional steroid injection (triamcinolone 2 mg/kg) can be used to accelerate tumour regression in small, localised lesions [1, 2] with less predictable outcomes (50% response). This is usually applied only once or twice to avoid possible complications of repeated subcutaneous injections (skin atrophy/depigmentation).

Table 1 The distribution of infantile haemangioma through different parts of the body among cases included in the study

Head and neck		Other parts of the body	
Periorbital	12	Limbs	12
Parotid	12	Trunk	9
Scalp	9	Breast	4
Lip	8	Genitalia	4
Cheek	6	Sacrum	1
Nose	5		
Forehead	4		
Periauricular	3		
Submandibular	2		
Temporal	1		
Other	11		
Total	73	Total	30

Surgical treatment

Surgery is still a valid option for lesions amenable to resection [1, 2]; however, we must put in consideration that most lesions will spontaneously regress. Surgery was considered a last resort for IH in this case series where only six cases (6%) underwent surgical excision. Two of these cases (one in the parotid and the other in the scalp) failed to show any signs of regression with time or with medical treatment (propranolol + several trials of local injection steroids/bleomycin) (Figs. 3 and 8). In a third case, the lesion was located at the nasal tip. Although the lesion showed partial response to medical treatment, yet it was still causing a significant cosmetic problem for the child and her family. The indication for surgery in the other three cases was mainly guided by parents’ preference, when the lesion was excised through

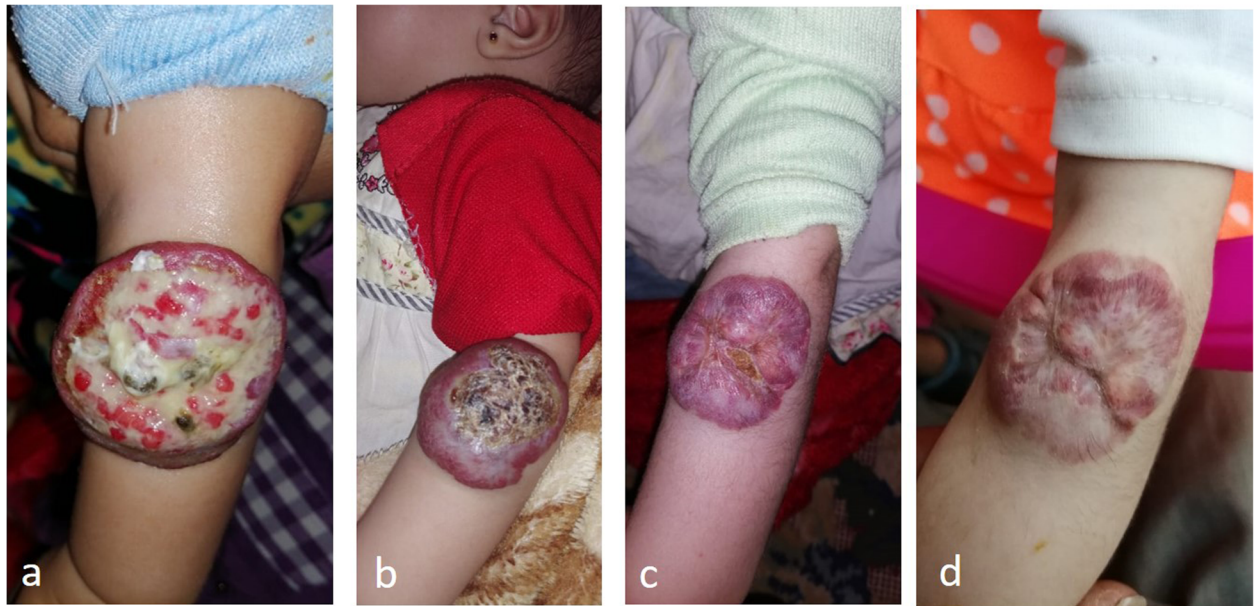

Fig. 2 Infantile haemangioma of the upper limb in the same patient at different stages. **a** The lesion at the age of 3 months showing marked overlying skin ulcerations during rapid proliferative phase. **b, c** Progress showing gradual healing by daily dressing and oral propranolol therapy. **d** Regression of the haemangioma at the age of 18 months

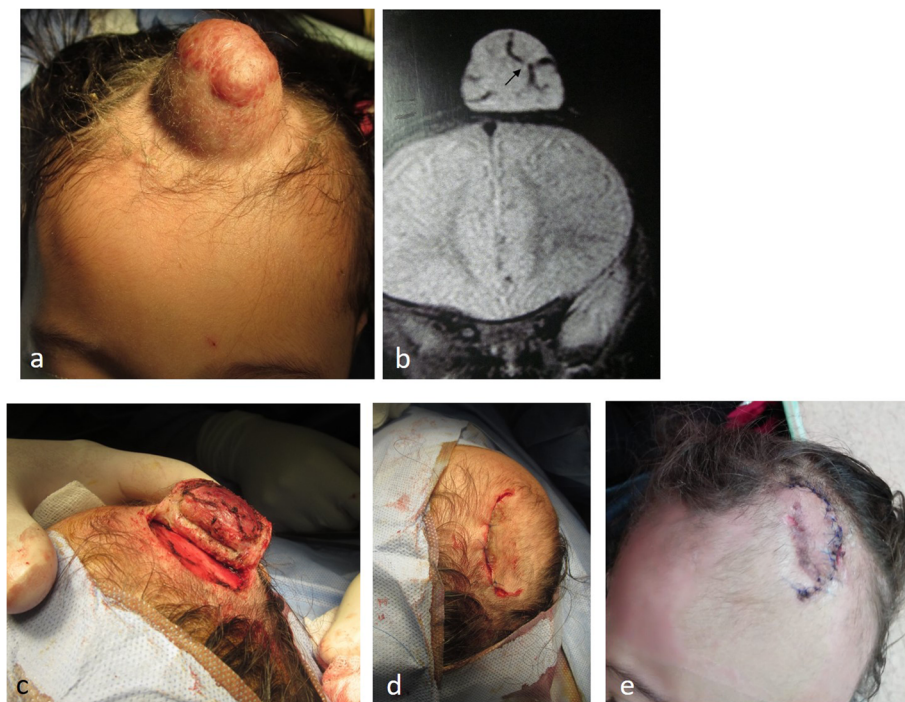

Fig. 3 a Infantile haemangioma of the scalp. **b** MRI showing typical hyperintense mass lesion with characteristic flow voids (black arrow). **c, d, e** Failure to respond to medical treatment (oral propranolol, intralesional steroid/bleomycin injection) was an indication for excision at the age of 3 years. Note: the overlying skin was not completely involved giving the chance of sparing a skin flap to be used to cover the skin defect after excision of the mass

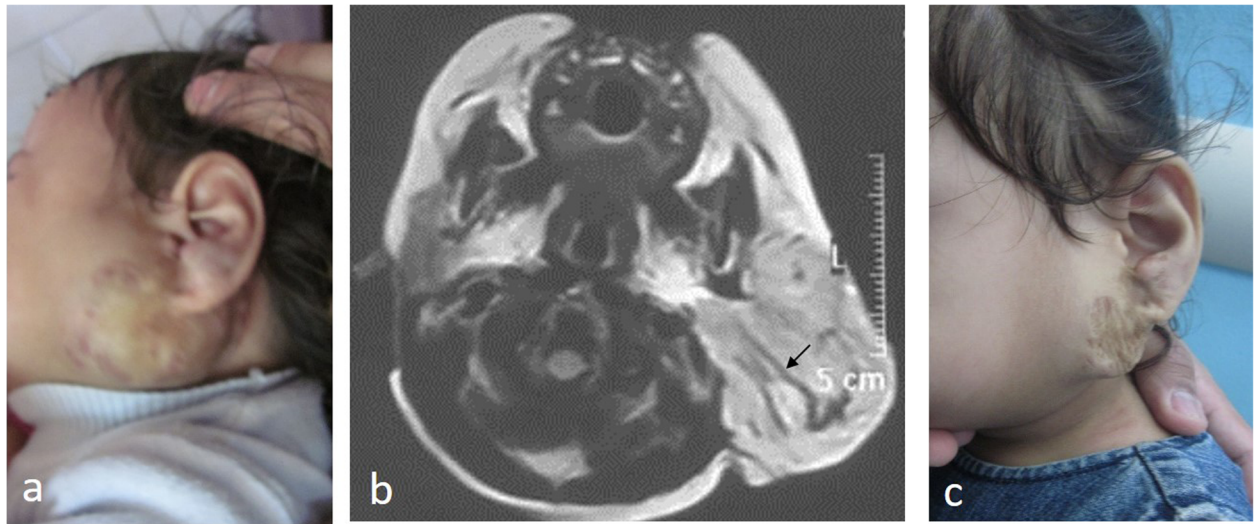


Fig. 4 Infantile haemangioma of the parotid. **a** The tumour size at presentation (14-month-old girl). **b** Axial MRI (T2WI) showing typical hyperintense mass lesion with characteristic flow voids (black arrow). **c** The same patient at 31 months of age showing good response to systemic propranolol and intralesional corticosteroid injection

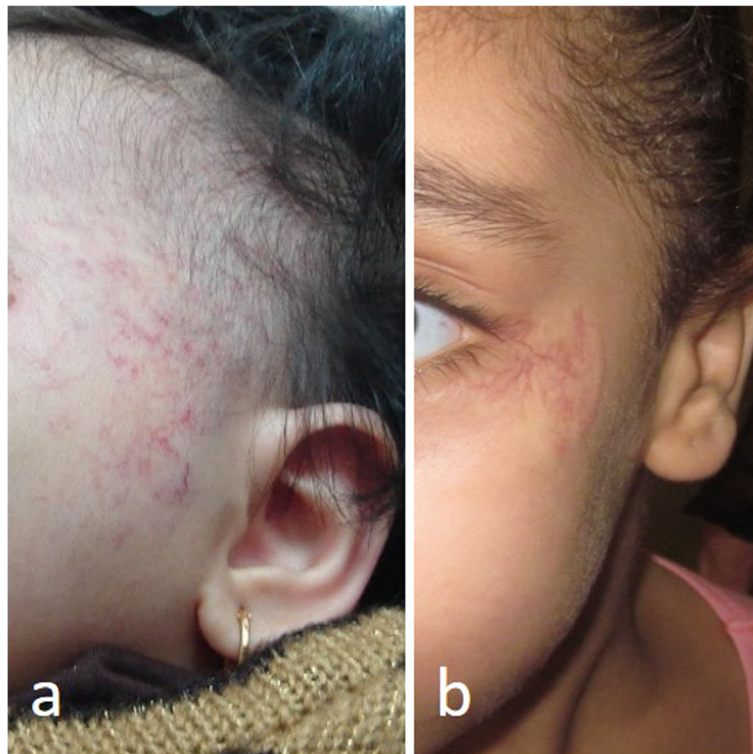

Fig. 5 Infantile haemangioma in the face of two different cases after stoppage of medical treatment and going into involution

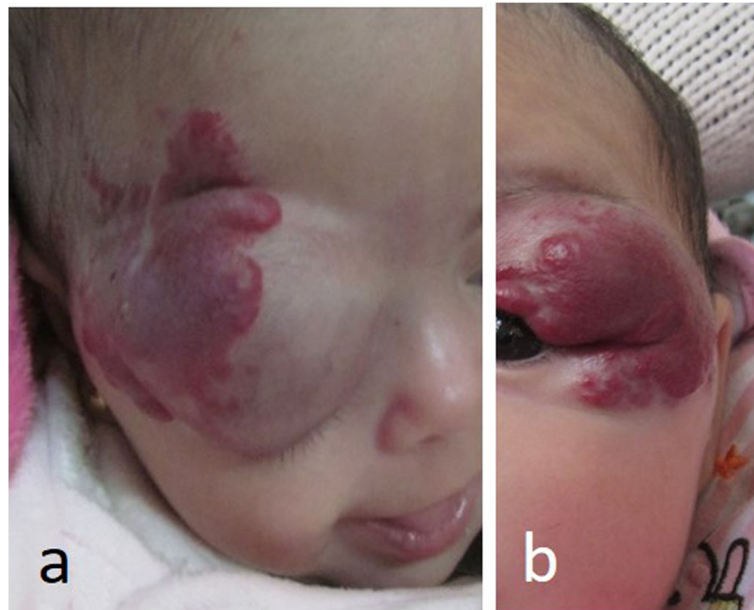

Fig. 6 Periorbital infantile haemangioma in two different cases (a, b). The visual field of the affected side is greatly compromised in (a)

a small hidden scar. Usually, surgery can be considered after the age of 3–4 years.

Neurological associations

Neurological associations were detected in three cases with IH (3%). The first presented with a midline haemangioma in the back (low lumbar) that was associated with spina bifida occulta and tethered spinal cord (Fig. 9). The patient did not have motor symptoms nor voiding problems. The other two cases had a segmental haemangioma in the face with associated posterior fossa brain anomalies (PHACE syndrome) [2]. These cases

were referred to follow-up their associated conditions at the neurology clinic.

Conclusion

Infantile haemangiomas represent a major sector (about 50%) of cases attending the specialised vascular anomaly clinic. We confirm the previously reported female predominance (3:1) [2, 3]. About 80% of cases present with localised lesions with special predilection to affect the head and neck (70%) [3]. The benign nature of the disease is obvious in most cases, except for overlying skin ulcerations that may accompany the rapid proliferative

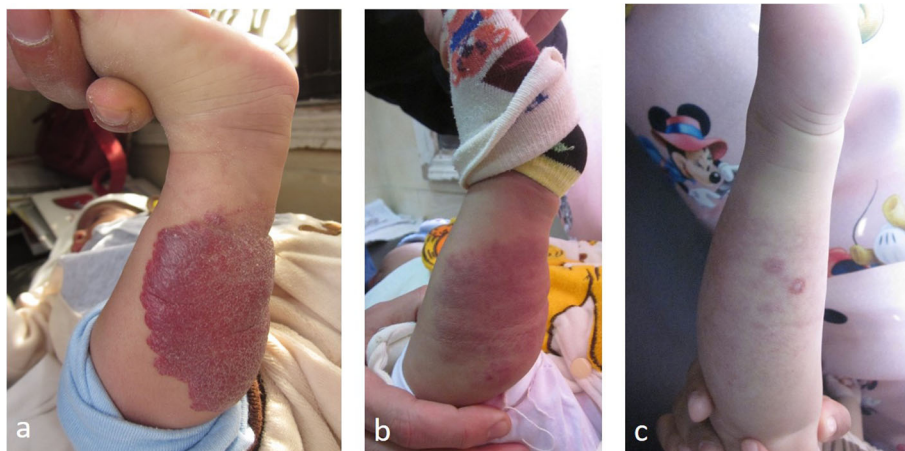


Fig. 7 Infantile haemangioma of the lower limb in the same patient at different stages showing excellent response to propranolol. **a** The lesion during proliferative phase at the age of 2.5 months. **b** The lesion at 7 months. **c** Haemangioma regression at the age of 12 months

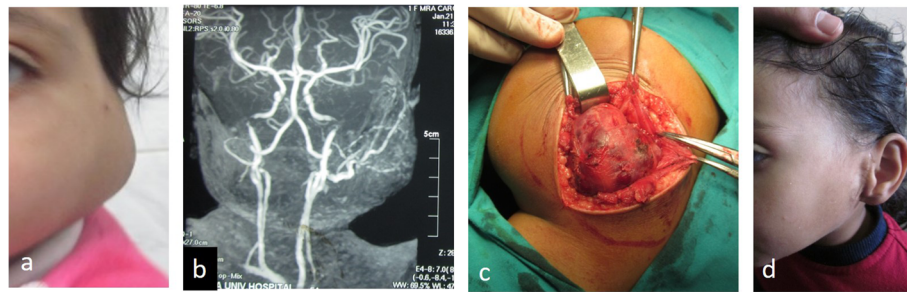


Fig. 8 **a** Infantile haemangioma in the left parotid of a 12-month-old girl. Failure to respond to medical treatment was an indication for excision at the age of 3 years. **b** MR angiography showing the feeding artery that was embolized by interventional radiologist 24 h before surgery to decrease bleeding during operation. **c** Care should be given to avoid fascial nerve injury during operation. **d** Outcome after excision of parotid haemangioma

phase of the tumour in some regions of the body. The main concern when managing IH is cosmesis. Cosmetic concerns are more pronounced in managing large/diffuse lesions and those affecting the face [2]. Lesions around natural orifices (lips, nose) can cause considerable disfigurement even if not large in size [2]. Lesions around the orbit may obstruct the visual field to a variable extent. Airway involvement by IH represents a rare but a life-threatening complication [2, 3]. Infantile haemangiomas may be associated with neurological anomalies (PHACE syndrome, occult spinal dysraphism) [2] but were uncommon in this case series as well (3%).

Spontaneous involution represents a great privilege in managing IH over other vascular anomalies. This can guarantee a favourable outcome at the end for most cases of IH [15]. The introduction of propranolol for managing complications of IH during the proliferative phase was a breakthrough [6]. Since its introduction in

2008, propranolol rapidly became the first line of treatment for IH in different centres all over the world [1–3].

The shift of managing vascular anomalies at a specialised multidisciplinary clinic should be highlighted in this report [7, 16, 17]. While the role of conventional surgery in managing these cases has been retreating over the past years [16], our colleagues at the paediatric oncology/haematology speciality were able to introduce new treating modalities that favourably changed the course of disease. At the beginning, systemic corticosteroids were used in managing diffuse haemangiomas, which later have been replaced by propranolol to a great extent. Also, cytotoxic drugs (vincristine, interferon) are used for managing more aggressive vascular tumours (haemangioendotheliomas). Most recently, sirolimus has been introduced as a new hope to control progression of complex vascular anomalies [14]. Another important role for the haematologist is to correct coagulopathies

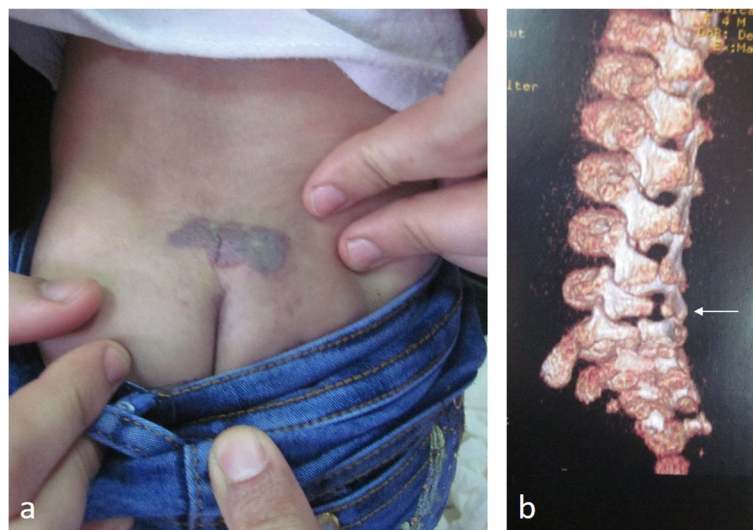


Fig. 9 Infantile haemangioma presenting as a midline back lesion (**a**) that was associated with spina bifida occulta demonstrated by white arrow in (**b**)

(thrombocytopenia, consumption coagulopathy) that can associate vascular anomalies other than IH [15].

Studying the medical images with experts in the field of paediatric radiology greatly improved our perception and understanding of anatomical details for different vascular anomalies [8]. Also, they provided guidance in choosing the best imaging modality and optimising MRI protocols to suit such a diverse spectrum of anomalies [9]. Interventional radiologists performed preoperative embolization for highly vascular lesions to reduce bleeding during operation and facilitate resection [7, 17].

This report may be criticised being retrospective and the relatively small number of cases included. This may be attributed to available digital archiving that mostly represented cases of IH having an indication for active intervention (either medical or surgical). Therefore, a selection bias cannot be excluded, yet we would like to emphasise in this report on the benign nature and the successful management protocol for cases of IH. Moreover, we highlighted the successful implementation of a multidisciplinary approach for managing vascular anomalies as an example that can be replicated in different fields of paediatric surgery.

Abbreviations

IH: Infantile haemangiomas; ISSVA: International Society for the Study of Vascular Anomalies; MRI: Magnetic resonance imaging; ENT: Ear, nose, and throat specialty

Acknowledgements

None.

Authors' contributions

All authors have read and approved the manuscript. Study conception and design: AAA. Data acquisition: AAA, IAR, SAM, WAG, HMN. Analysis and data interpretation: AAA, IAR, SAM. Drafting of the manuscript: AAA. Critical revision: OE.

Funding

None.

Availability of data and materials

The datasets used and/or analysed during the current study are available from the corresponding author on reasonable request.

Declarations

Ethics approval and consent to participate

A written parental consent was taken before operation in all cases. Owing to the retrospective nature of the study, an IRB number was not required, and the study was approved through expedited review by the scientific/ethical committee of the Pediatric Surgery department (Faculty of Medicine, Ain-Shams University).

Consent for publication

Patient identity did not appear in any part of the manuscript; therefore, consent for publication was not required.

Competing interests

The authors declare that they have no competing interests.

Author details

¹Pediatric Surgery Department, Faculty of Medicine, Ain Shams University, Cairo, Egypt. ²Department of Pediatric, Faculty of Medicine, Ain Shams

University, Cairo, Egypt. ³Department of Radiodiagnosis, Faculty of Medicine, Ain Shams University, Cairo, Egypt. ⁴Department of Radiodiagnosis (Interventional Radiology Unit), Faculty of Medicine, Ain Shams University, Cairo, Egypt.

Received: 15 September 2020 Accepted: 22 April 2021

Published online: 01 June 2021

References

- Gokani VJ, Sivakumar B, Kangesu L (2018) Vascular anomalies. *Surgery (Oxford)* 36(6):314–323. <https://doi.org/10.1016/j.jmpsurg.2018.03.010>
- Strub G, Sidbury R, Bauman N (2018) Vascular tumors: infantile hemangioma. In: Perkins JA, Balakrishnan K (eds) Evidence-based management of head and neck vascular anomalies. Springer Nature, Switzerland, pp 37–46
- Flors L, Park AW, Norton PT, Hagspiel KD, Leiva-Salinas C (2019) Soft-tissue vascular malformations and tumors. Part 1: classification, role of imaging and high-flow lesions. *Radiologia (English edition)* 61:4–15. <https://doi.org/10.1016/j.rxeng.2017.11.001>
- Mulliken JB, Glowacki J (1982) Hemangiomas and vascular malformations in infants and children: a classification based on endothelial characteristics. *Plast Reconstr Surg* 69(3):412–422. <https://doi.org/10.1097/00006534-198203000-00002>
- Dasgupta R, Fishman SJ (2014) ISSVA classification. *Semin Pediatr Surg* 23(4): 158–161. <https://doi.org/10.1053/j.sempedsurg.2014.06.016>
- Leaute-Labreze C et al (2008) Propranolol for severe hemangiomas of infancy. *N Engl J Med*. 358(24):2649–2651. <https://doi.org/10.1056/NEJMc0708819>
- Guevara CJ, Alomari AI (2013) Interdisciplinary approach to treatment of vascular anomalies. *Tech Vasc Interv Radiol* 16(1):55–58. <https://doi.org/10.1053/j.tvir.2013.01.008>
- Mohammad SA, AbouZeid AA, Fawzi AM et al (2017) Magnetic resonance imaging of head and neck vascular anomalies: pearls and pitfalls. *Ann Pediatr Surg* 13(3):116–124. <https://doi.org/10.1097/01.XPS.0000513183.56919.bf>
- Mamlouk MD, Nicholson AD, Cooke DL, Hess CP (2017) Tips and tricks to optimize MRI protocols for cutaneous vascular anomalies. *Clin Imaging* 45: 71–80. <https://doi.org/10.1016/j.clinimag.2017.05.019>
- Sadick M, Wohlgemuth WA, Huelse R, Lange B, Henzler T, Schoenberg SO, Sadick H (2017) Interdisciplinary management of head and neck vascular anomalies: clinical presentation, diagnostic findings and minimal invasive therapies. *Euro J Radiol Open* 4:63–68. <https://doi.org/10.1016/j.ejro.2017.05.001>
- Aly MMD, Hamza AF, Abdel Kader HM, Saafan HA, Ghazy MS, Ragab IA (2015) Therapeutic superiority of combined propranolol with short steroids course over propranolol monotherapy in infantile hemangioma. *Eur J Pediatr* 174(11):1503–1509. <https://doi.org/10.1007/s00431-015-2561-1>
- Herlihy E, Hochman M (2018) Periocular vascular tumors: infantile hemangioma. In: Perkins JA, Balakrishnan K (eds) Evidence-based management of head and neck vascular anomalies. Springer Nature, Switzerland, pp 105–111
- Elluru RG (2018) Vascular tumors of the airway. In: Perkins JA, Balakrishnan K (eds) Evidence-based management of head and neck vascular anomalies. Springer Nature, Switzerland, pp 131–137
- Mizuno T, Emoto C, Fukuda T, Hammill AM, Adams DM, Vinks AA (2017) Model-based precision dosing of sirolimus in pediatric patients with vascular anomalies. *Euro J Pharm Sci* 109:s124–s131. <https://doi.org/10.1016/j.ejps.2017.05.037>
- Greene AK, Liu AS, Mulliken JB, Chalache K, Fishman SJ (2011) Vascular anomalies in 5621 patients: guidelines for referral. *J Pediatr Surg* 46(9):1784–1789. <https://doi.org/10.1016/j.jpedsurg.2011.05.006>
- Adams DM, Fishman SJ (2017) Late sequelae and long-term outcomes of vascular anomalies. *Semin Pediatr Surg* 26(5):317–321. <https://doi.org/10.1053/j.sempedsurg.2017.09.007>
- Mamlouk MD, Lee PW (2018) Developing a multidisciplinary vascular anomaly clinic and reviewing the radiologist's clinic role. *Curr Probl Diagn Radiol* 47(6):378–381. <https://doi.org/10.1067/j.cpradiol.2017.10.009>

Publisher's Note

Springer Nature remains neutral with regard to jurisdictional claims in published maps and institutional affiliations.