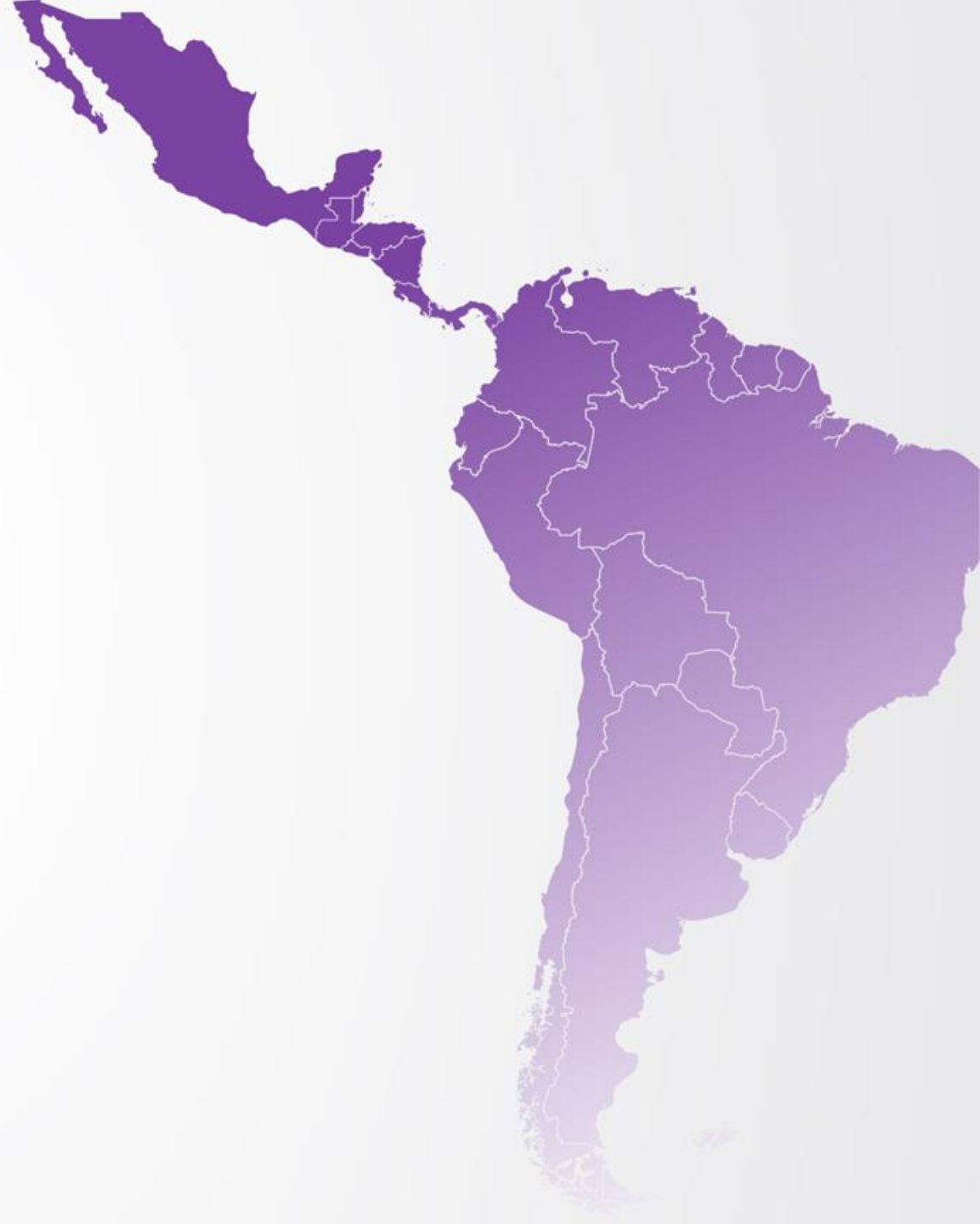

European Course on
Pediatric Neuroradiology in
Latin America (ECPNR-LATAM)

3rd Cycle - Module 1

PHAKOMATOSES



Idealização:



Organização:



European Course on
Pediatric Neuroradiology in
Latin America (ECPNR-LATAM)
3rd Cycle - Module 1

Dr Victor Hugo Rocha Marussi

**Neurorradiologist – Beneficência
Portuguesa Hospital – SP - Brazil**

Idealização:



Organização:



PHAKOMATOSES

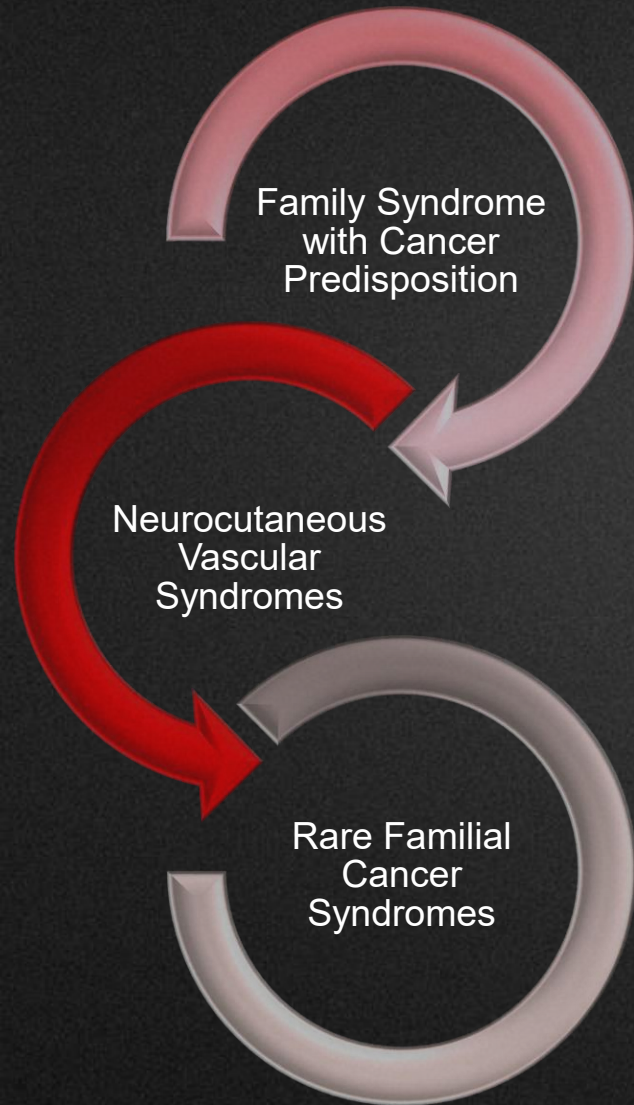
European Course on
Pediatric Neuroradiology in
Latin America (ECPNR-LATAM)
3rd Cycle - Module 1

There is no conflict of interest in this presentation

PHAKOMATOSES

Group of disorders characterized by malformations, hamartomas, and/or tumors in ectodermal-derived structures.

- Not all Neurocutaneous Syndromes are inherited.
- Not all have a predisposition to develop CNS neoplasms.
- Not all syndromes present with cutaneous lesions.
- Not all have visceral abnormalities.



PHAKOMATOSES – General Concept

Etymology:

Phako (φακός) = lens or spot
-oma = tumor
-osis = condition

Definition: Term coined in 1920 by Jan van der Hoeve (Dutch ophthalmologist). He introduced it to describe benign, tumor-like nodules of the eye seen in systemic disorders.

Core Idea: Phakomatoses are a group of neurocutaneous syndromes, characterized by hamartomas (benign malformations) affecting the skin, nervous system, and eyes.

The “four major” phakomatoses classically described include:

Syndrome	Genetic Basis	Key Systemic Features	Ocular Manifestations
Neurofibromatosis Type 1 (Recklinghausen's disease)	Mutation in NF1 gene (chromosome 17) → loss of neurofibromin (tumor suppressor)	- Multiple neurofibromas (cutaneous, plexiform)- Café-au-lait spots- Axillary/inguinal freckling- Skeletal abnormalities (scoliosis, pseudoarthrosis)- CNS gliomas	- Lisch nodules (iris hamartomas)- Optic pathway gliomas
Tuberous Sclerosis Complex (Bourneville's disease)	Mutation in TSC1 (hamartin) or TSC2 (tuberin) genes	- Cortical tubers , subependymal nodules- Epilepsy, intellectual disability, autism- Adenoma sebaceum (facial angiofibromas)- Cardiac rhabdomyomas- Renal angiomyolipomas	- Retinal hamartomas (original “phakoma”)
Sturge-Weber Syndrome (Encephalotrigeminal angiomatosis)	Somatic mutation in GNAQ gene (not inherited; sporadic)	- Facial port-wine stain (trigeminal nerve distribution)- Leptomeningeal angiomas → seizures, hemiparesis- Developmental delay	- Choroidal hemangioma - Secondary glaucoma
Von Hippel-Lindau Disease (Cerebroretinal angiomatosis)	Mutation in VHL gene (chromosome 3) → impaired tumor suppression	- Hemangioblastomas of CNS and retina- Renal cell carcinoma- Pheochromocytoma- Pancreatic cysts and tumors	- Retinal hemangioblastomas (may cause exudation, detachment)

PHAKOMATOSSES – 3 TIPS

European Course on
Pediatric Neuroradiology in
Latin America (ECPNR-LATAM)
3rd Cycle - Module 1



LOOK AT THE SKIN!

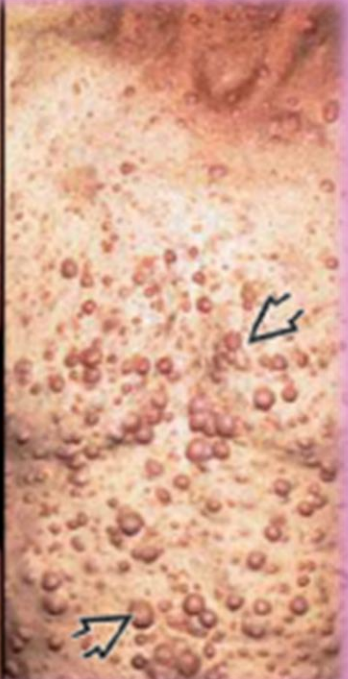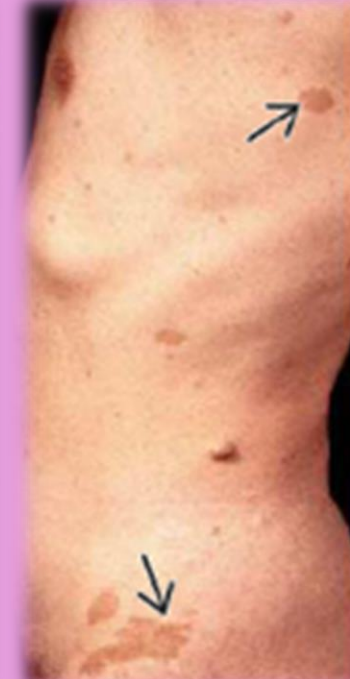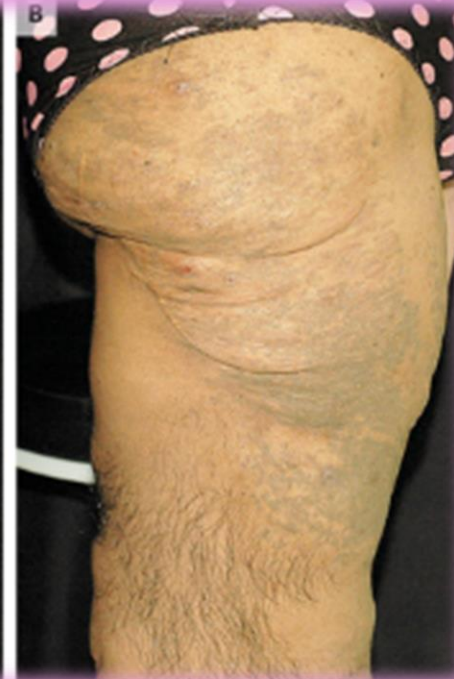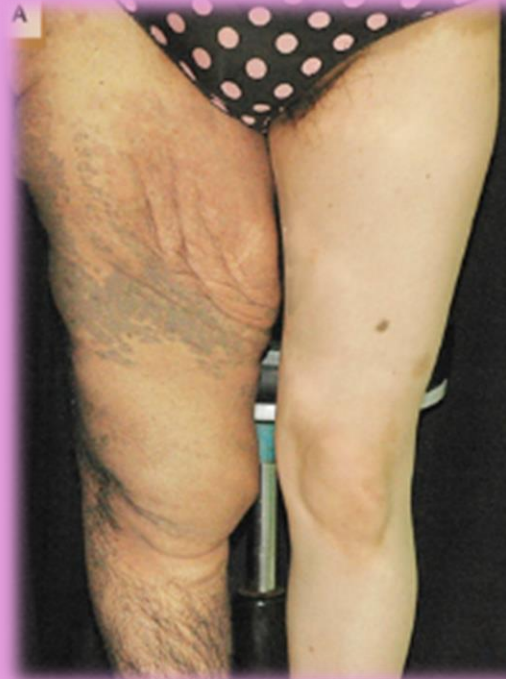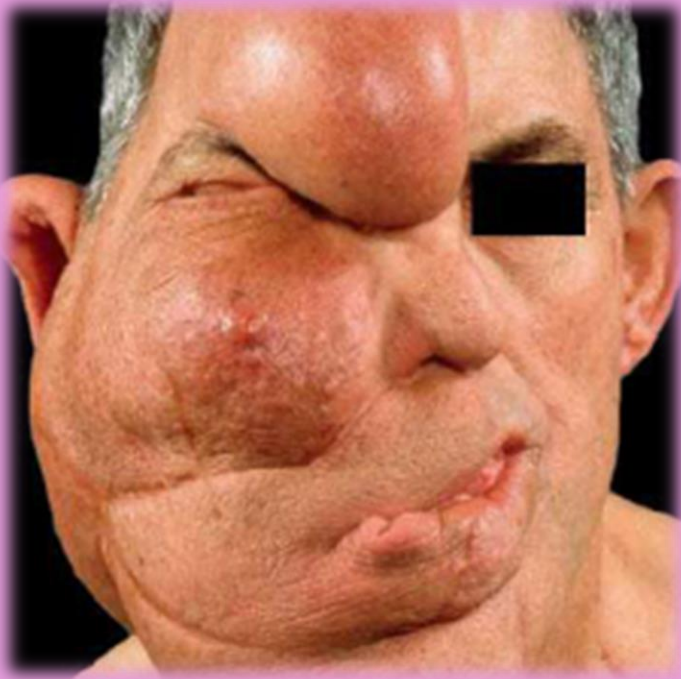LOOK AT THE VESSELS!

REVIEW THE DIFFERENTIAL DIAGNOSES!

PHAKOMATOSES

European Course on
Pediatric Neuroradiology in
Latin America (ECPNR-LATAM)
3rd Cycle - Module 1

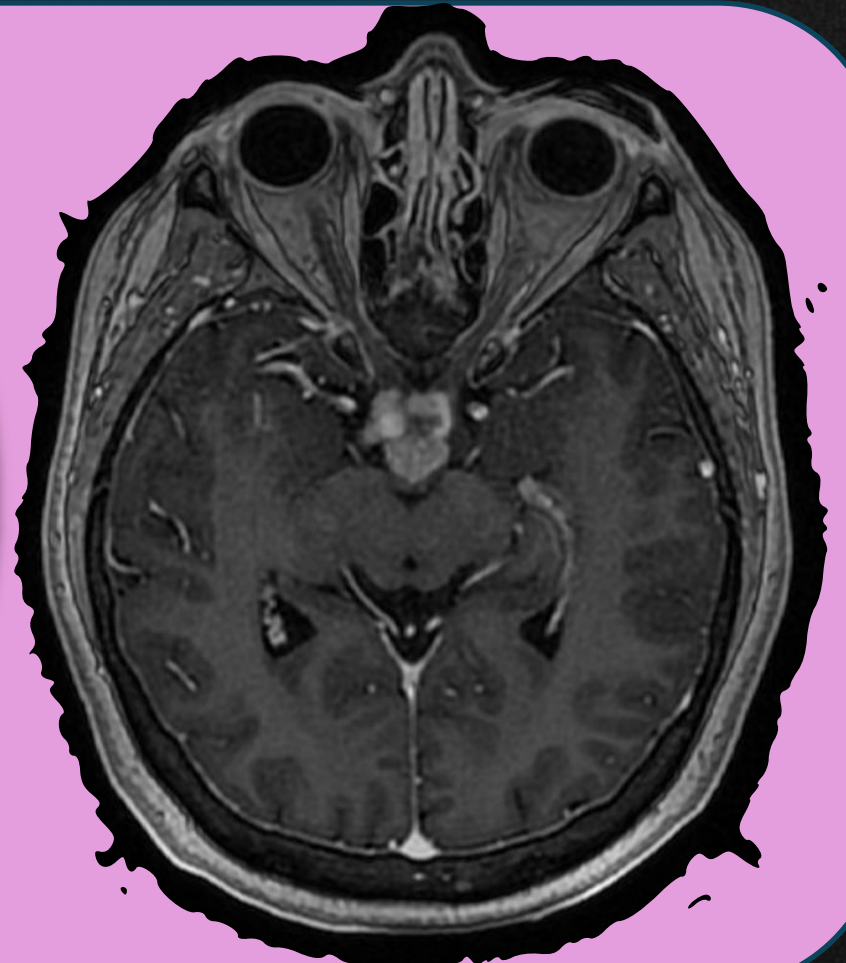
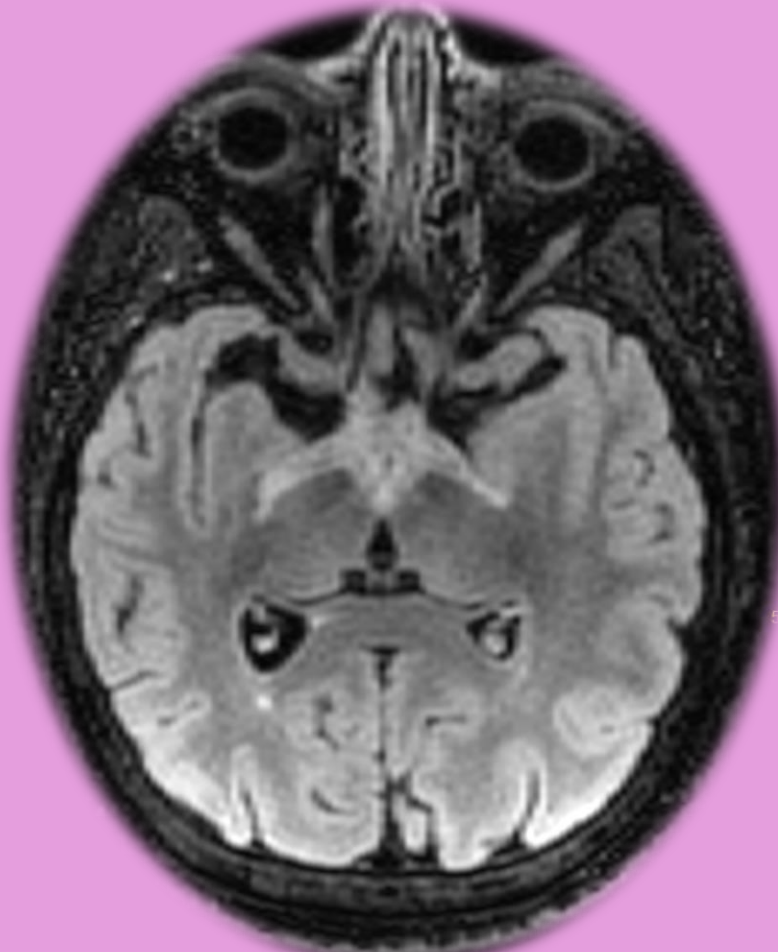
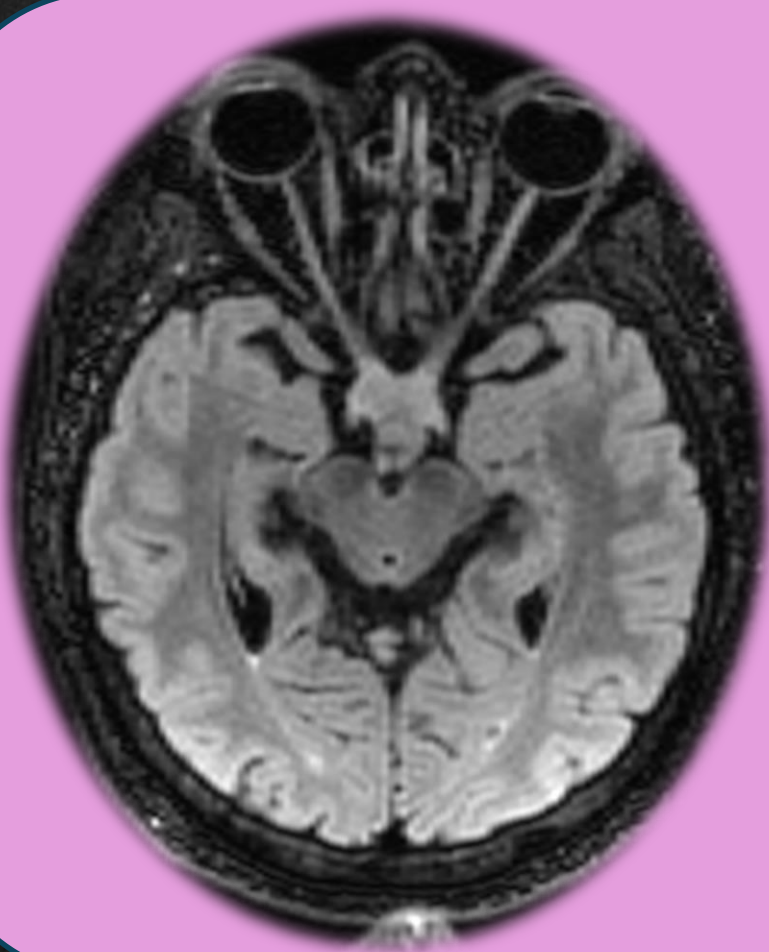
LOOK AT THE SKIN!



PHAKOMATOSES

European Course on
Pediatric Neuroradiology in
Latin America (ECPNR-LATAM)
3rd Cycle - Module 1

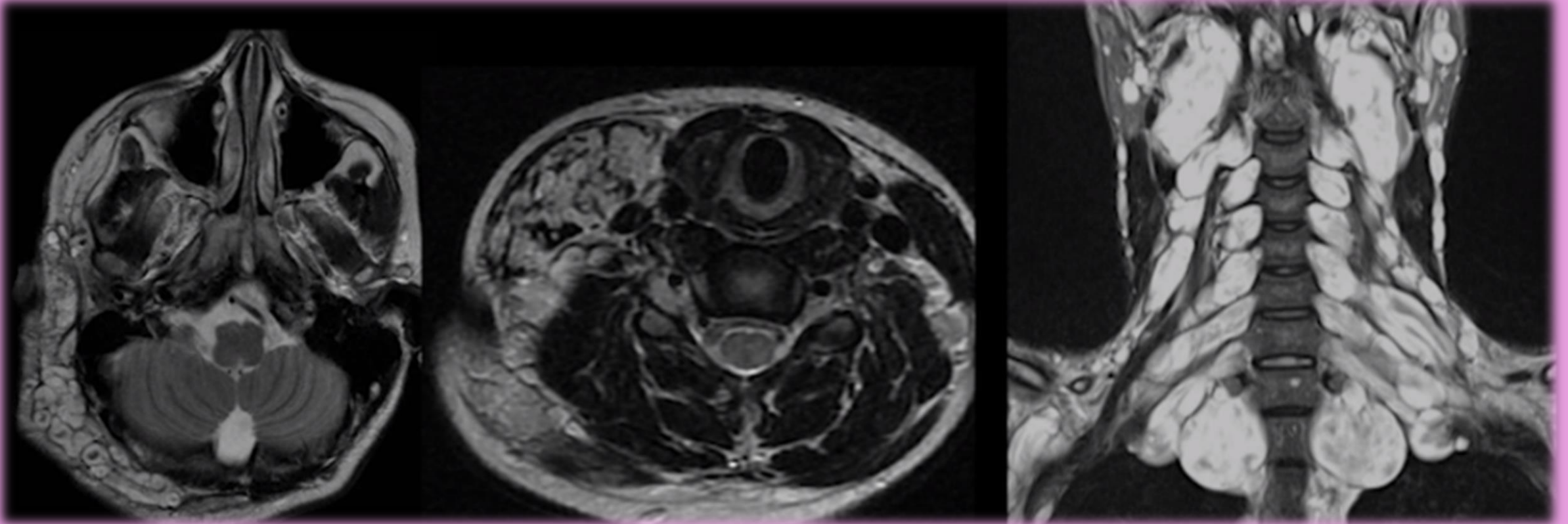
LOOK AT THE SKIN!



PHAKOMATOSES

European Course on
Pediatric Neuroradiology in
Latin America (ECPNR-LATAM)
3rd Cycle - Module 1

LOOK AT THE SKIN!



NEUROFIBROMATOSIS TYPE I von Recklinghausen disease

Inheritance: Autosomal dominant (\approx 50% new mutations \rightarrow no family history).

Gene: NF1 gene on chromosome 17q11.2.

Protein: Encodes neurofibromin, a tumor suppressor that downregulates RAS signaling.

Epidemiology: Affects about 1 in 3,000 live births worldwide.

Vascular Abnormalities in NF1

1. NON-CNS VASCULAR LESIONS +++
Renal artery stenosis, aortic stenosis
2. CNS VASCULAR LESIONS

NF1 – Diagnostic Criteria (NIH Consensus 1987)

✓ Diagnosis requires 2 or more of the following:

Café-au-lait macules

- \geq 6 spots

Neurofibromas

- \geq 2 of any type OR 1 plexiform neurofibroma (pathognomonic)

Freckling

- Axillary (Crowe's sign) or inguinal freckling

Optic pathway glioma

- Tumor involving optic nerve/chiasm

Lisch nodules

- \geq 2 iris hamartomas seen on slit-lamp exam

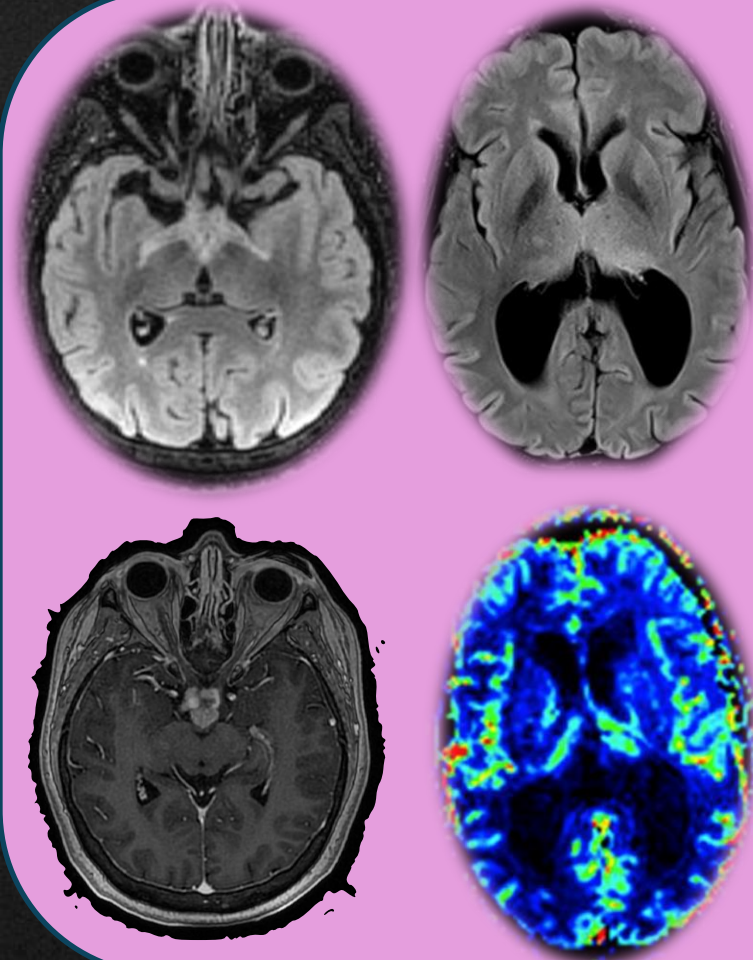
Bony lesion

- Sphenoid wing dysplasia OR Thinning of long bone cortex with or without pseudoarthrosis

Family history

- First-degree relative with NF1 (meets the above criteria)

NF I - OPTIC PATHWAY GLIOMA (OPGs)



Definition:

- Low-grade astrocytomas (often pilocytic) that arise along the optic nerves, chiasm, or tracts.
- Strongly associated with Neurofibromatosis type 1 (NF1).

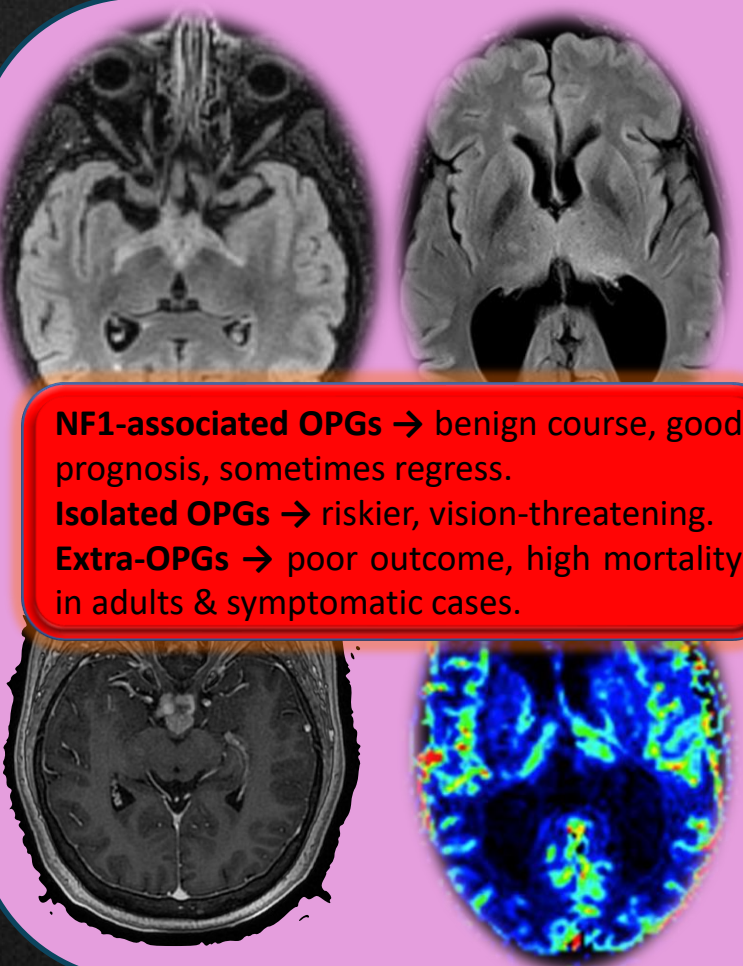
Epidemiology:

- Age: Mostly in the first two decades of life.
 - Peak incidence: Around 4–5 years of age.
 - NF1 association: Present in 30–70% of NF1 patients.
- ⚠ Important: Many tumors are asymptomatic, so the incidence of symptomatic patients is significantly lower.

Anatomical Distribution:

- Single optic nerve involvement: ~40–50% of cases.
 - Bilateral optic nerves: ~20% of cases.
 - Posterior extension: Possible involvement of the optic chiasm, tracts, and hypothalamus, which worsens clinical outcomes.
- 👉 “NF1 optic gliomas: better prognosis, sometimes regress spontaneously (Parazzini 1995).”

NF 1 - OPTIC PATHWAY GLIOMA (OPGs)



NF1-associated OPGs → benign course, good prognosis, sometimes regress.

Isolated OPGs → riskier, vision-threatening.

Extra-OPGs → poor outcome, high mortality in adults & symptomatic cases.

◆ Diffuse Brainstem Gliomas (DBSGs) in NF1

General Features:

- Rare compared to OPGs.
- Infiltrative, often pontine or midbrain-based.
- Non-resectable, but clinical course is different from sporadic DIPG.

Prognosis & Clinical Course:

- NF1-associated DBSGs → more indolent than sporadic diffuse gliomas.
- Slow progression documented: 30–50% remain stable until puberty (Pollack, 1996).
- Survival significantly longer than sporadic DIPGs, which usually have rapid, fatal course (<2 years).

Extension Patterns

- 12% → extend to spinal cord.
- 20% → extend to middle cerebellar peduncle (MCP) or vermis.

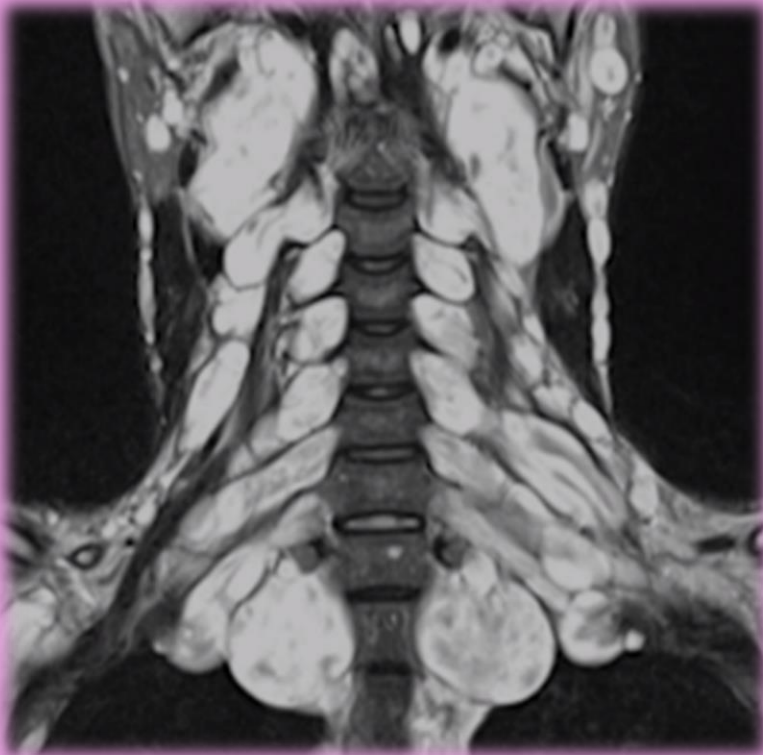
📄 Spinal Cord Tumors in NF1

- **Very rare: ~ 3% incidence** in NF1 patients (Lee 1996, Thakkar 1999).
- Astrocytomas predominate among the spinal tumors in NF1.
- Must be differentiated from NF2 spinal tumors.

PHAKOMATOSES

FEATURE	NF1-associated OPG	Sporadic OPG	Extra-OPG (non-optic PA)	Diffuse Brainstem Glioma (DBSG) in NF1	Sporadic DBSG / DIPG
AGE	Childhood (peak 4–5 yrs)	Childhood	Children & adults	Childhood / adolescence (rare in NF1)	Mostly children (5–10 yrs)
FREQUENCY	30–70% of NF1 cases (but fewer symptomatic)	Rare	Rare	Rare (less common than OPGs)	Sporadic, not NF1-related
COURSE	Indolent, many asymptomatic	More aggressive, symptomatic	Poor if symptomatic/adult	Indolent, slow progression (30–50% stable until puberty – Pollack 1996)	Very aggressive, rapid progression
PROGNOSIS	Better (may regress spontaneously – Parazzini 1995)	Worse	High mortality in adults & symptomatic patients	Better than sporadic DIPG; prolonged survival possible	Poor prognosis – median survival < 2 yrs
EXTENSION	40–50% one optic nerve, 20% both, can involve chiasm/hypothalamus	Same pattern but more aggressive	Variable (cerebellum, thalamus, brainstem, cord)	12% → spinal cord, 20% → MCP/vermis	Widely infiltrative brainstem
TREATMENT	Often observation; chemo if progressive	Chemo / surgery if needed	Surgery if resectable, otherwise poor outcome	Observation if indolent; chemo/radiotherapy only if symptomatic/progressive	No effective cure; palliative RT/chemo
MORTALITY	Low	Moderate	High (esp. adults)	Low–moderate, long survival possible	High – nearly all fatal

NF I – PLEXIFORM NEUROFIBROMA



Plexiform Neurofibroma – NF1

◆ Definition

- WHO Grade I peripheral nerve sheath tumor.
- Benign, but with aggressive local growth and potential for malignant transformation.
- Considered pathognomonic of NF1 (seen in ~30% of patients).

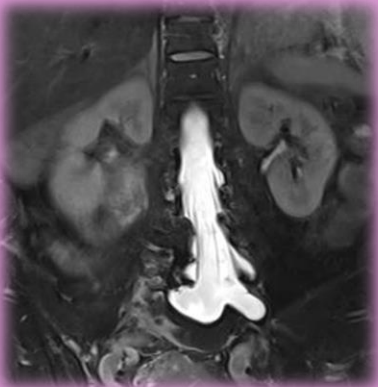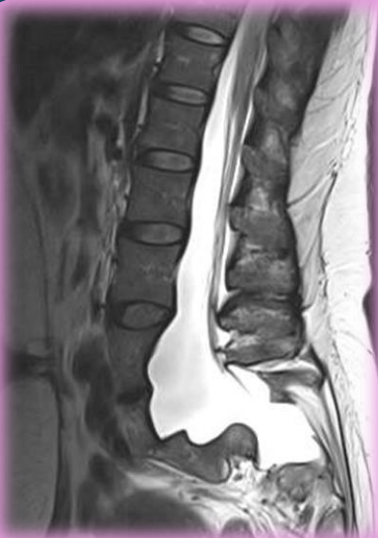◆ Histopathology

- Tortuous cords of Schwann cells + neurons.
- Fibroblastic proliferation within an unorganized intercellular matrix.
- Infiltrates surrounding structures → diffuse, infiltrating nature.
- Risk of anaplastic degeneration → Malignant Peripheral Nerve Sheath Tumor (MPNST).
- Can involve superficial nerves (skin/subcutaneous tissue) or deep nerves (brachial/lumbosacral plexus).

◆ Clinical Features

- Often congenital or presents in early childhood.
- Can cause disfigurement, functional impairment, pain.
- Malignant transformation risk: ~8–13% over lifetime in NF1.

NF I – DURAL ECTASIA



Dural Ectasia in NF1 – High-Yield Note

◆ Pathogenesis

Primary dysplasia of the meninges → inherent defect of the dura in NF1.
This dural weakness makes the tissue unable to resist normal CSF pulsations.

Result: progressive focal stretching and ballooning of the dural sac.

◆ Morphology

Posterior vertebral scalloping (classic radiologic sign).

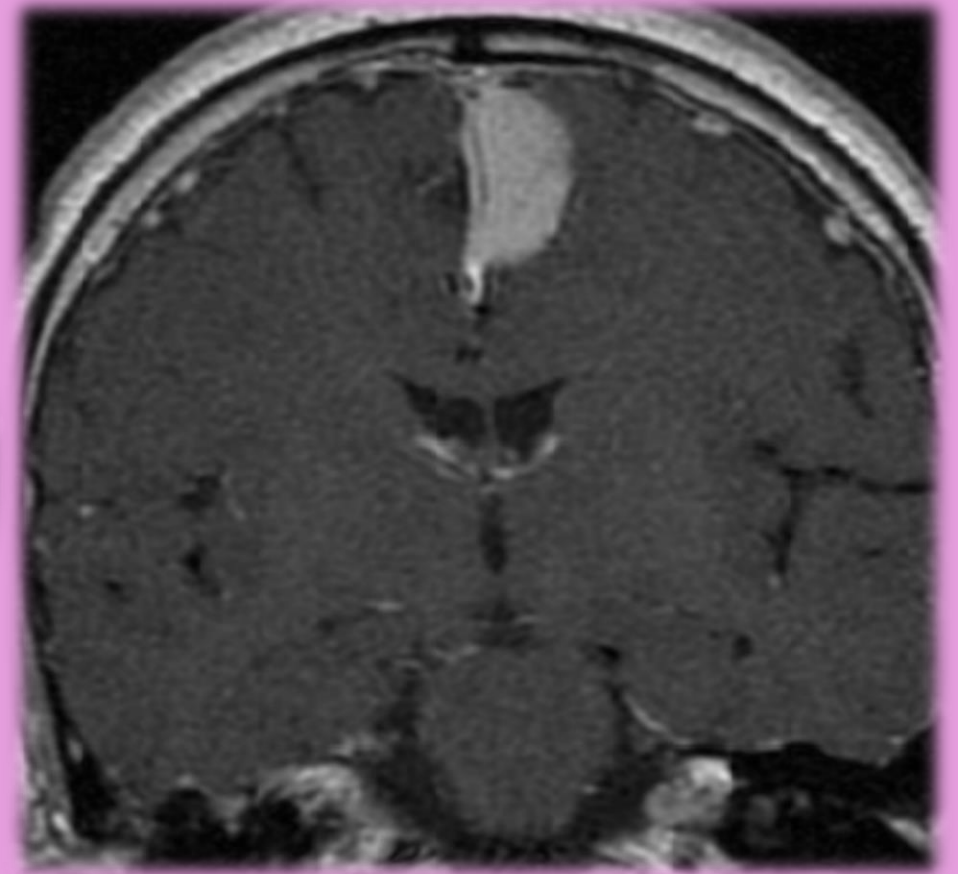
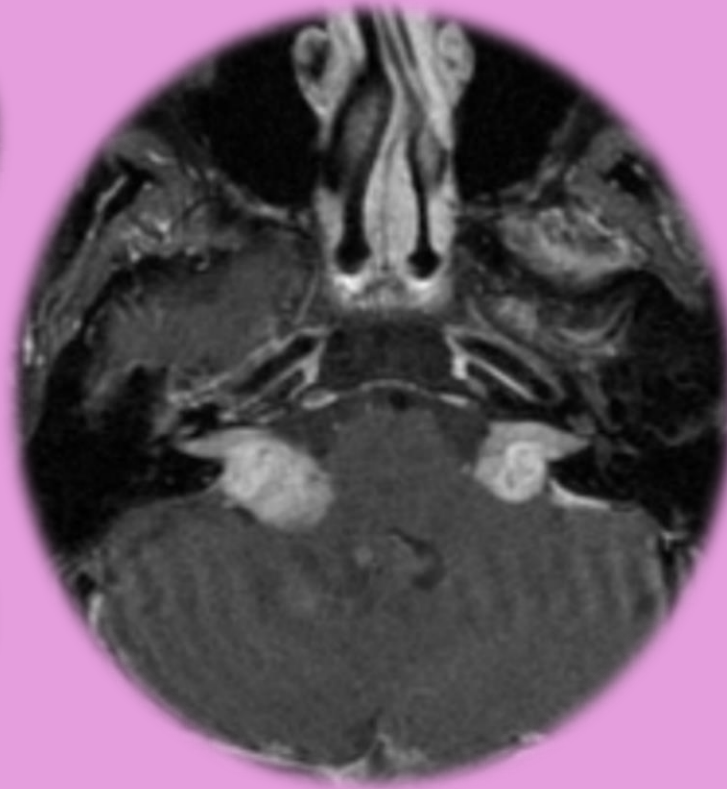
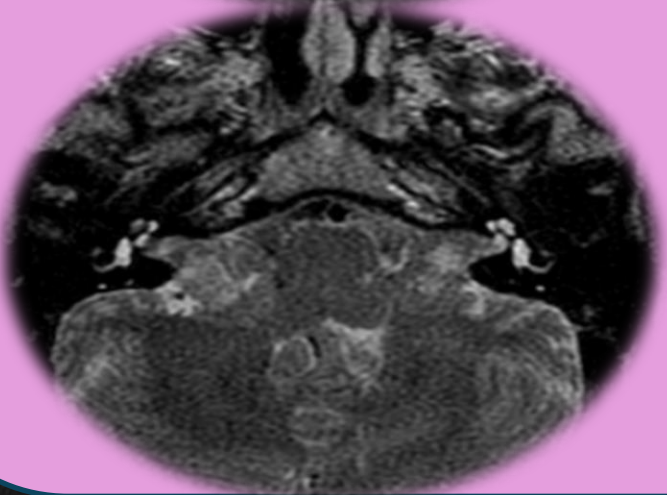
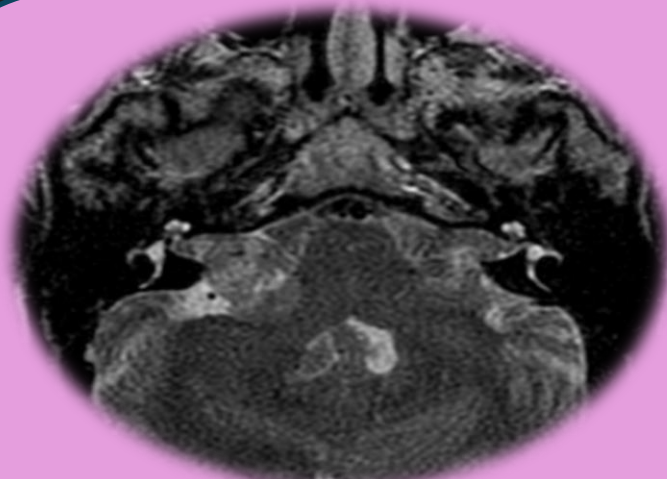
Enlargement of neural foramina.

Widened dural sac, most often in lumbosacral spine.

PHAKOMATOSES

European Course on
Pediatric Neuroradiology in
Latin America (ECPNR-LATAM)
3rd Cycle - Module 1

LOOK AT THE SKIN!



NEUROFIBROMATOSIS TYPE II

◆ NIH (Consensus) Diagnostic Criteria

Diagnosis of NF2 can be made if either of the following is present:

1. Definite NF2

Bilateral vestibular schwannomas (VS) **OR**

A first-degree relative with NF2 *plus* one of the following:

- Unilateral VS before age 30
- Any two of the following:
 - Meningioma
 - Glioma (often spinal ependymoma)
 - Schwannoma (non-vestibular)
 - Juvenile posterior subcapsular lenticular opacities / juvenile cataract

2. Probable NF2

Unilateral VS < 30 y plus one other NF2-associated tumor (meningioma, schwannoma, glioma, or juvenile cataract).

Neurofibromatosis Type II – MRI Findings:

- Bilateral vestibular schwannomas (CPA/IAC)
- Multiple meningiomas (intracranial & spinal)
- Ependymomas (spinal > intracranial)
- Schwannomas of other cranial/spinal nerves
- Possible ocular involvement (cataracts)

Mnemonic: MISME

- **M**ultiple
- **I**nherited
- **S**chwannomas (esp. bilateral vestibular)
- **M**eningiomas (intracranial & spinal)
- **E**pendymomas (mainly spinal)

NEUROFIBROMATOSIS TYPE II

Meningioangiomatosis (MA) – NF2

◆ Definition

- **Rare, benign, hamartomatous lesion** of the **leptomeninges** and underlying cortex.
- Associated with **NF2**, but can also occur sporadically.

◆ Epidemiology & NF2 Association

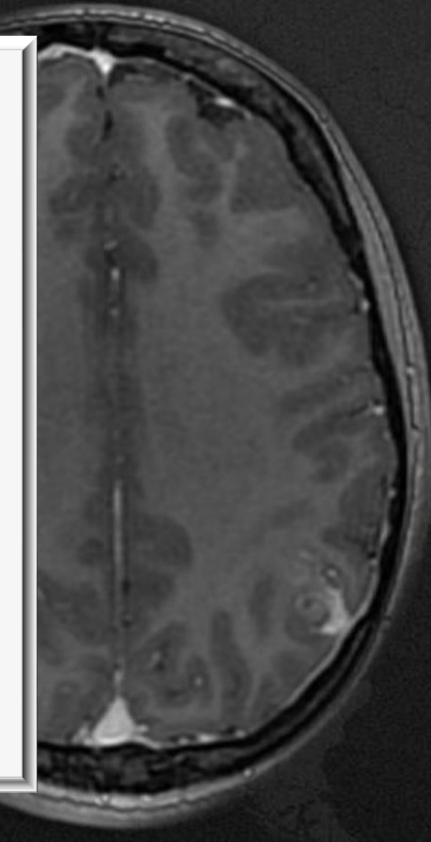
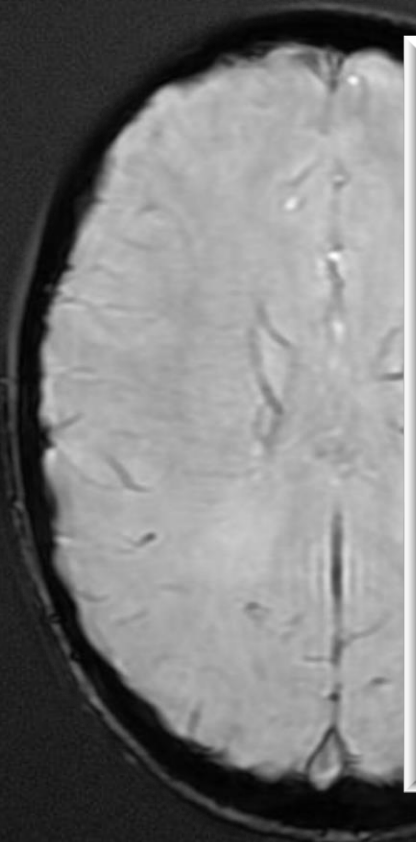
- Sporadic cases: usually **solitary**, sometimes symptomatic (seizures).
- NF2-associated: often **multiple, asymptomatic lesions** discovered incidentally.

◆ Location

- Predilection for **temporal** and **frontal lobes**.

◆ Imaging Features (MRI/CT)

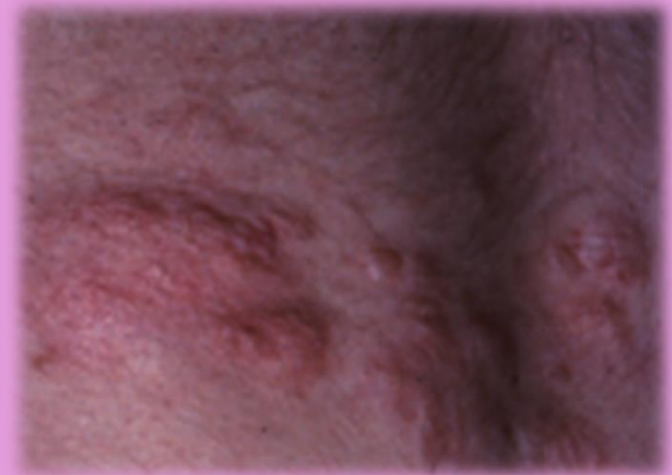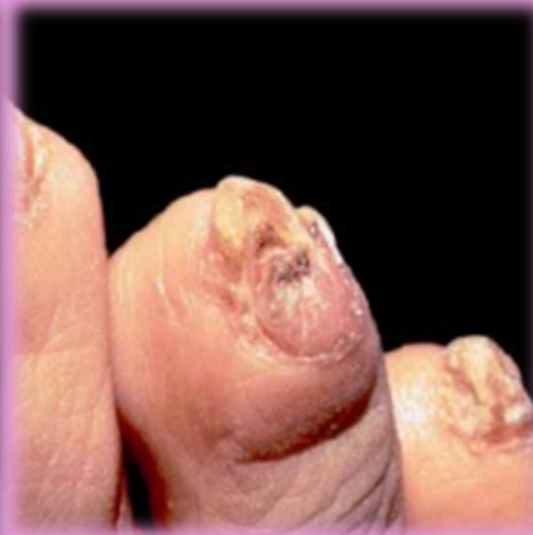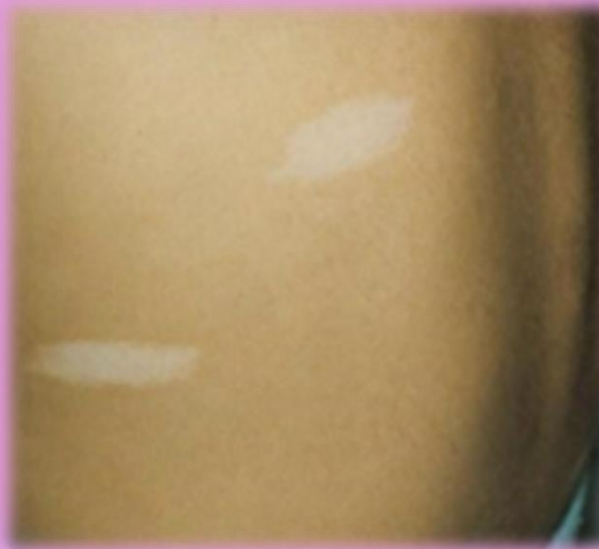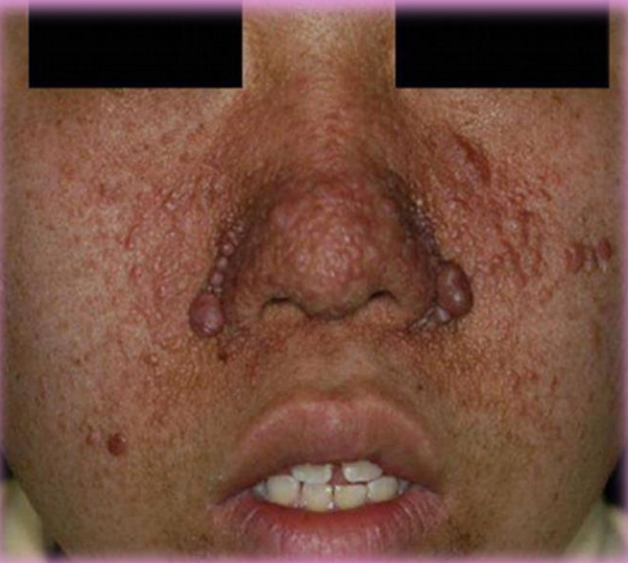- **Enhancing, well-demarcated cortical lesion**.
- **Perilesional edema** often present.
- **Leptomeningeal enhancement** (distinguishes from other cortical lesions).
- May mimic meningioma, oligodendroglioma, or cortical dysplasia.



PHAKOMATOSES

European Course on
Pediatric Neuroradiology in
Latin America (ECPNR-LATAM)
3rd Cycle - Module 1

LOOK AT THE SKIN!

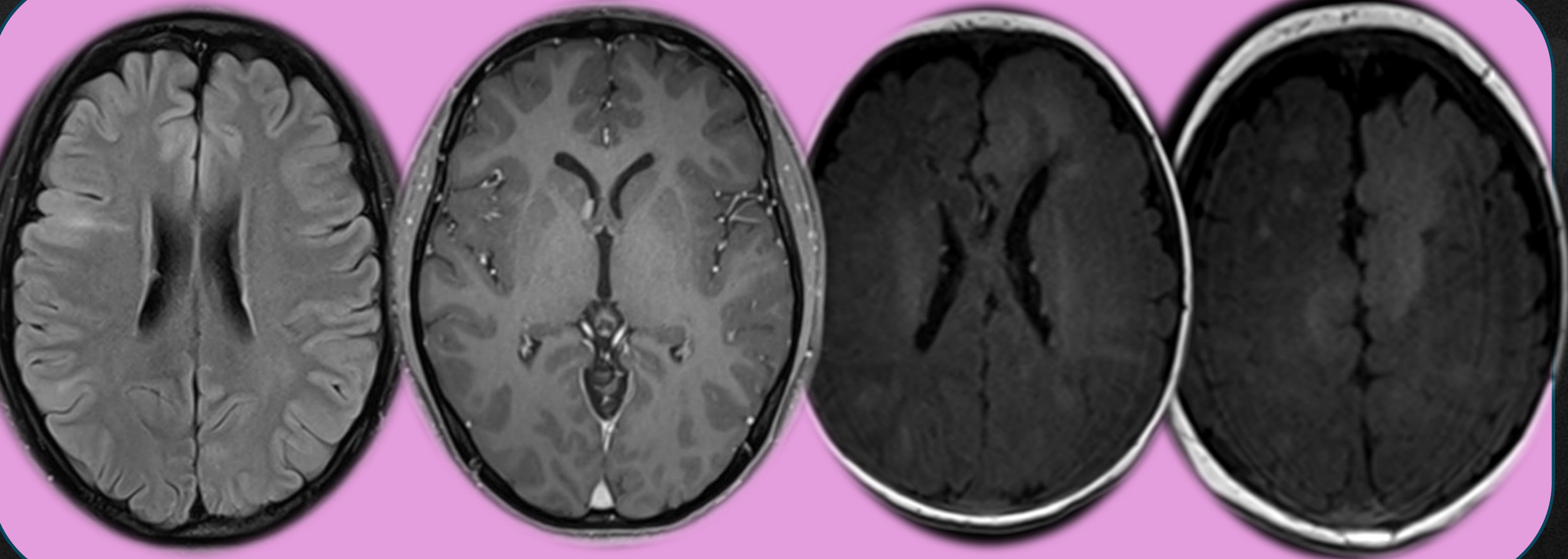


Anne G. Osborn, Gary L. Hedlund, Karen L. Salzman. Osborn's Brain E-Book. (2017)
Umeoka S, Koyama T, Miki Y, Akai M, Tsutsui K, Togashi K. Pictorial review of tuberous sclerosis in various organs. RadioGraphics 2008;28(7):e32.

PHAKOMATOSES

European Course on
Pediatric Neuroradiology in
Latin America (ECPNR-LATAM)
3rd Cycle - Module 1

LOOK AT THE SKIN!



PHAKOMATOSES – 3 TIPS

European Course on
Pediatric Neuroradiology in
Latin America (ECPNR-LATAM)
3rd Cycle - Module 1

LOOK AT THE SKIN!

TUBEROUS SCLEROSIS COMPLEX (TSC) Bourneville-Pringle disease

- MULTI-ORGAN HAMARTOMAS (skin, brain, lungs, heart, kidneys)
- Incidence 1/6,000 - 1/10,000; Autosomal Dominant
- GENETIC HETEROGENEITY:
TSC1 - 9q34 – Hamartin; **TSC2** - 16p13 – Tuberin (SIMILAR PHENOTYPE)
- **Original “VOGT TRIAD”**:
Facial nevus (Adenoma Sebaceum) + Seizures + Mental deficiency

Cortical / Subcortical Lesions

- Cortical tubers

- T1: hypointense
- T2/FLAIR: hyperintense
- May calcify → hypointense on SWI
- Often associated with cortical dysplasia and epilepsy

Periventricular Lesions

- Subependymal nodules (SENs)

- Along lateral ventricles
- T2/FLAIR: iso- to hyperintense
- May calcify or enhance
- Stable size (key feature vs SEGA - Size > 10 mm)

Tumoral Lesions

- Subependymal giant cell astrocytomas (SEGAs)

- Classically near foramen of Monro
- T1: iso- to hypointense
- T2/FLAIR: hyperintense
- Enhance after gadolinium
- Progressive growth → risk of obstructive hydrocephalus

White Matter Changes

- Radial migration lines

- Linear T2/FLAIR hyperintensities
- Extend from ventricle → cortex
- Represent altered neuronal migration



PHAKOMATOSES

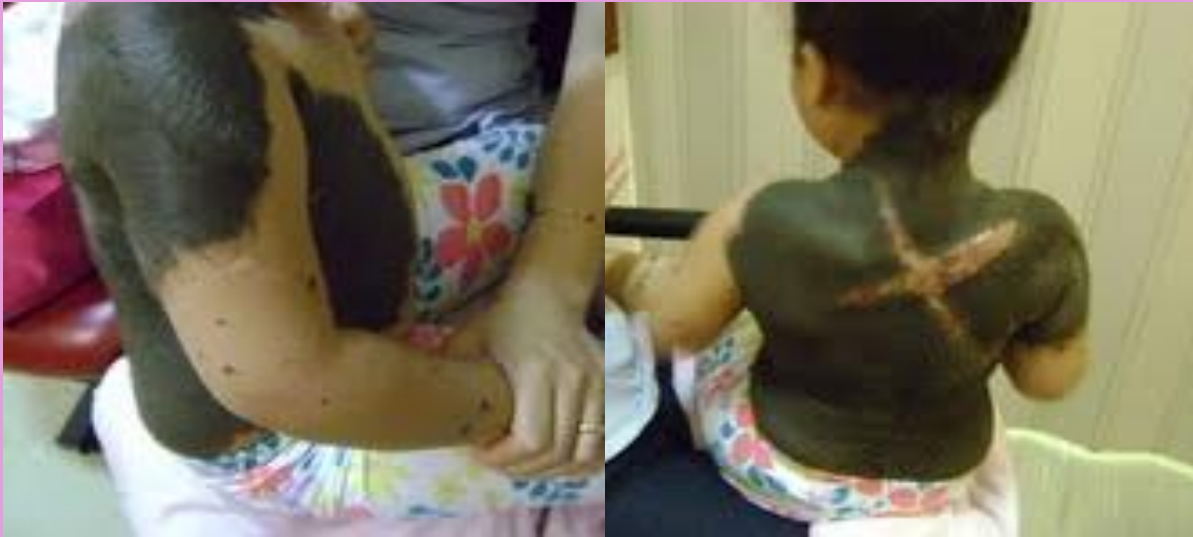TUBEROUS SCLEROSIS



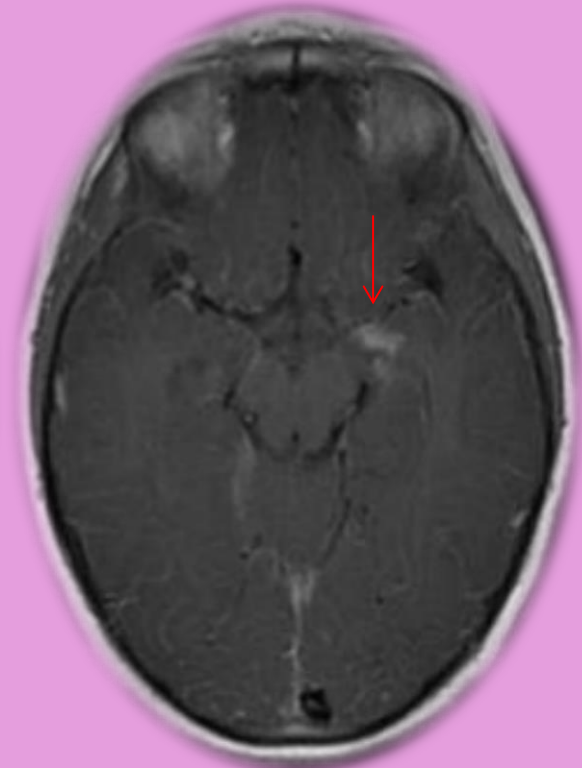
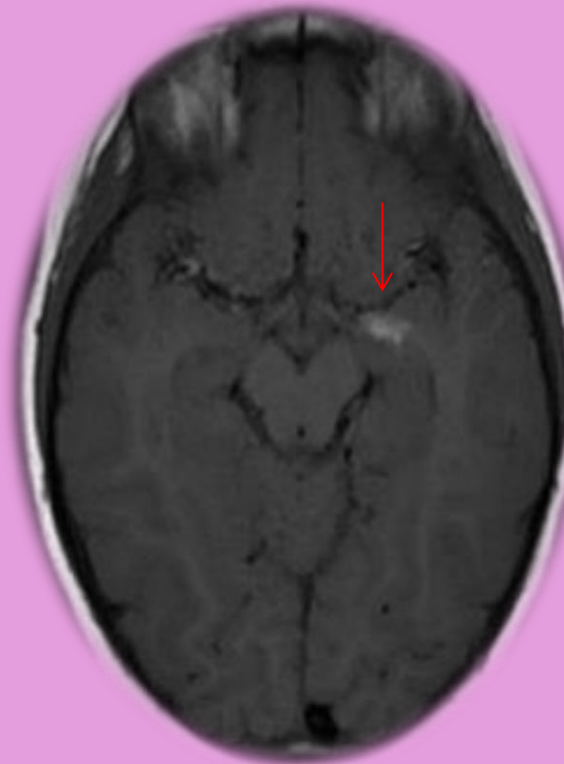
Major features	Minor features
Facial angiofibromas or forehead plaques	Confetti skin lesions
Shagreen patch (connective tissue nevus)	Gingival fibromas
Three or more hypomelanotic macules	Multiple randomly distributed pits in dental enamel
Nontraumatic unguual or periungual fibromas	Hamartomatous rectal polyps
Lymphangiomyomatosis	Multiple renal cysts
Renal angiomyolipoma	Nonrenal hamartomas
Cardiac rhabdomyoma	Bone cysts
Multiple retinal nodular hamartomas	Retinal achromic patch
Cortical tubers	Cerebral white matter radial migration lines
Subependymal nodules	
Subependymal giant cell astrocytoma	
Definite TSC:	2 major features or 1 major + 2 minor features
Probable TSC:	1 major + 1 minor feature
Possible TSC:	1 major feature or 2+ minor features

PHAKOMATOSES

LOOK AT THE SKIN!



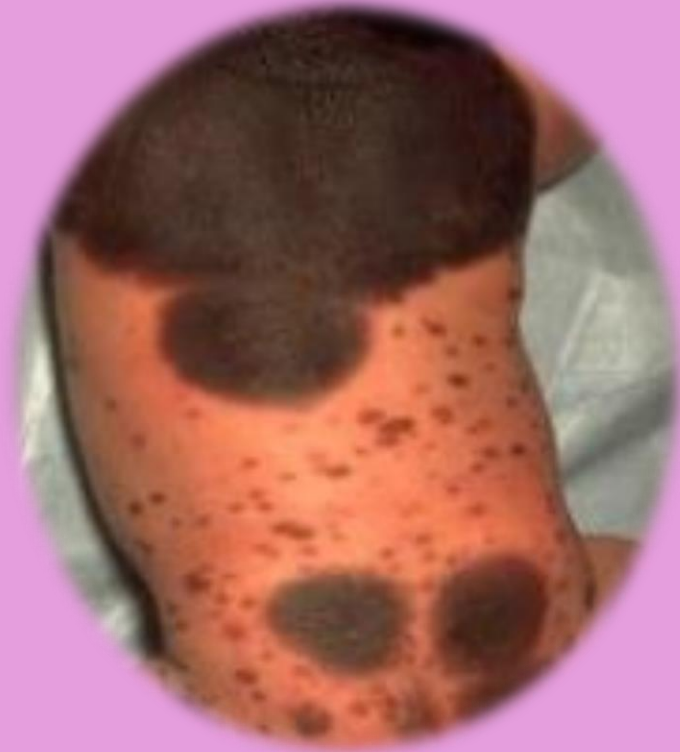Giant melanocytic nevus involving the dorsal region, posterior cervical region, right arm and anterior abdominal wall.



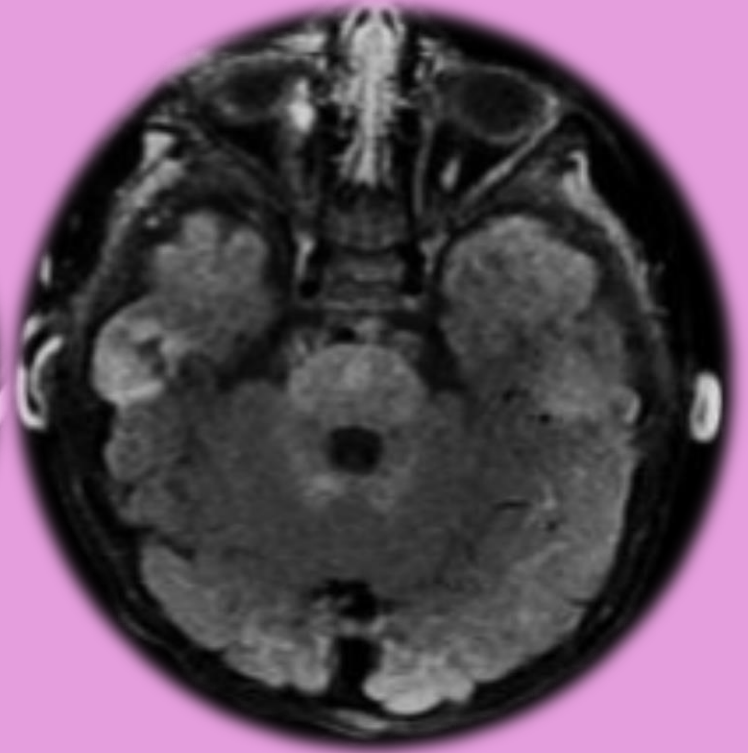
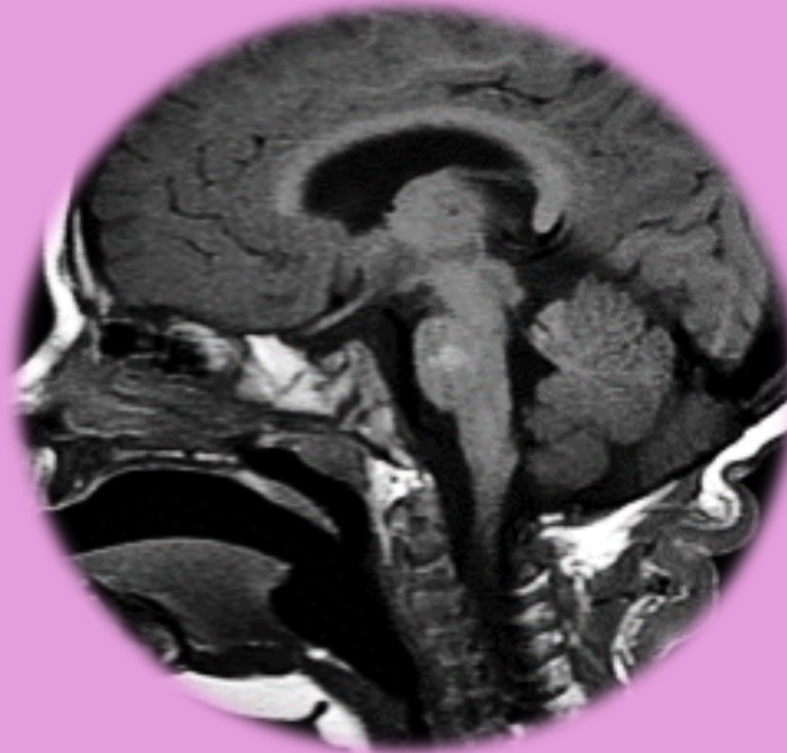
PHAKOMATOSES

European Course on
Pediatric Neuroradiology in
Latin America (ECPNR-LATAM)
3rd Cycle - Module 1

LOOK AT THE SKIN!



Giant melanocytic nevus that extent to most of the dorsal region.



LOOK AT THE SKIN!

NEUROCUTANEOUS MELANOSIS



- Rare neuroectodermic dysplasia, characterized by the presence of multiples hyperpigmentated congenital nevus, with proliferation of melanin-producing cells at the leptomeninges and cerebral parenchyma.
- Somatic mutations of the gene NRAS, at chromosome 1p13

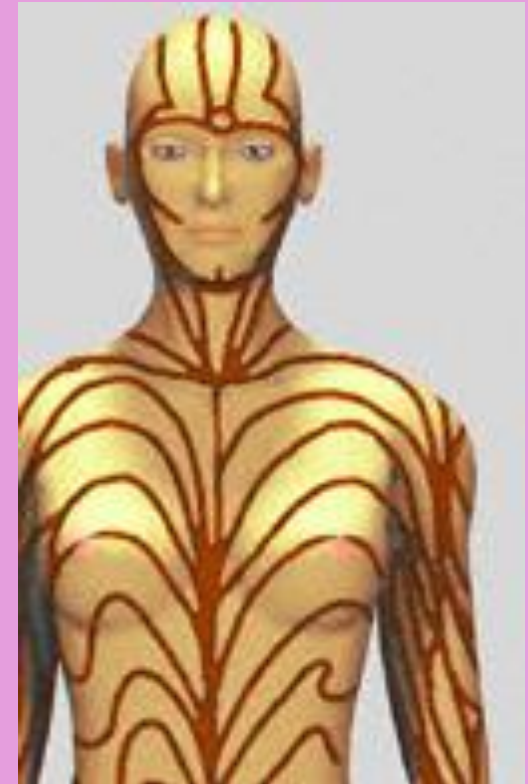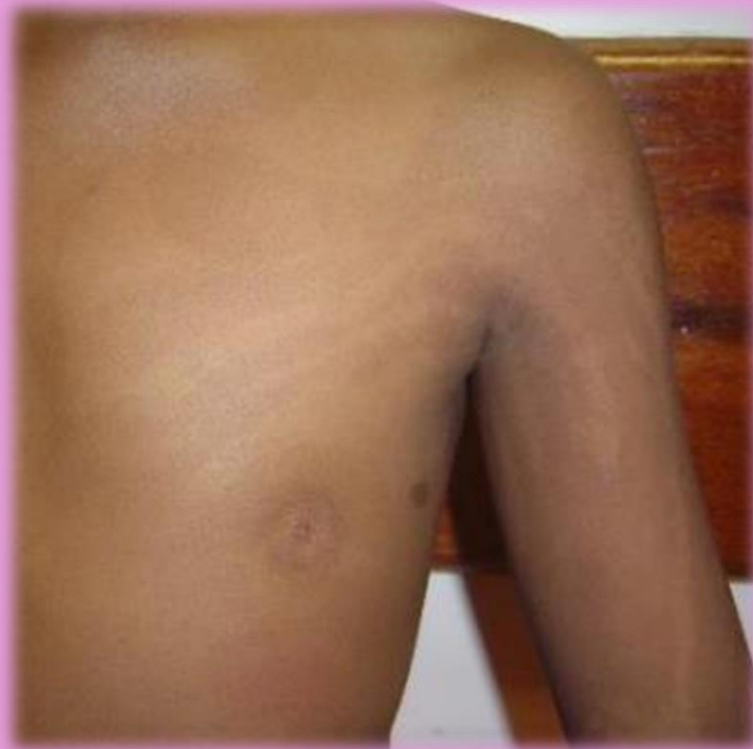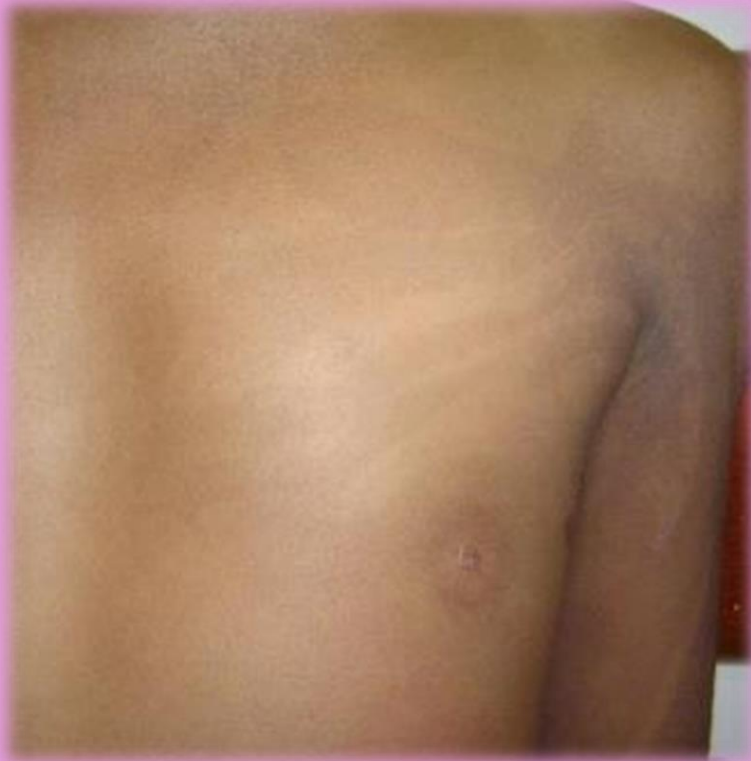NEUROIMAGING:

- T1 hyperintensity (melanin) nodular or linear aspect on the surface of the cerebral parenchyma (cerebellum, brainstem, meninges and temporal lobes - amygdala) PREDILECTION areas > melanocytic cells
- Cases that evolves for melanoma: diffuse leptomeningeal dissemination (leptomeningeal melanomatosis)
- HYDROCEPHALUS

PHAKOMATOSES

European Course on
Pediatric Neuroradiology in
Latin America (ECPNR-LATAM)
3rd Cycle - Module 1

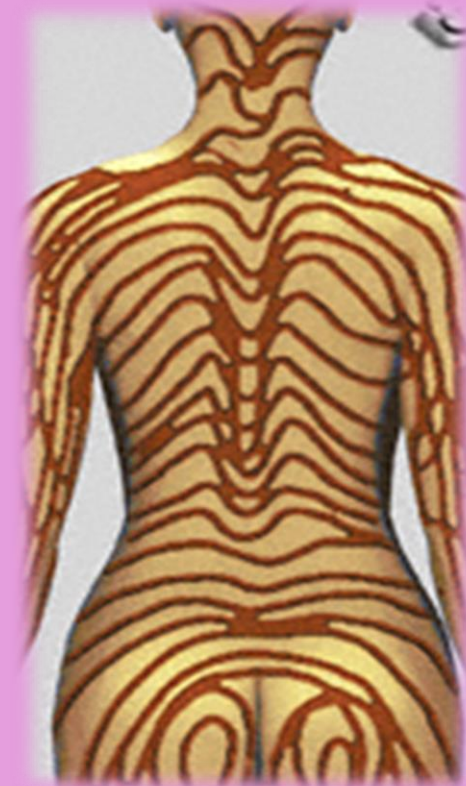

LOOK AT THE SKIN!



PHAKOMATOSES

European Course on
Pediatric Neuroradiology in
Latin America (ECPNR-LATAM)
3rd Cycle - Module 1

LOOK AT THE SKIN!

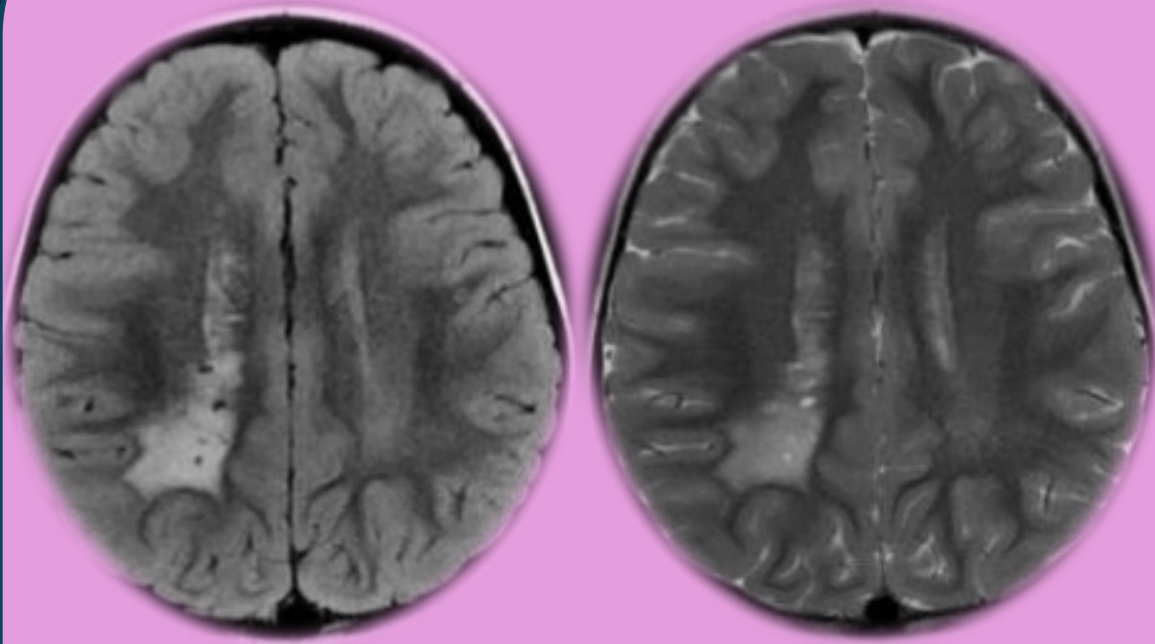


PHAKOMATOSES

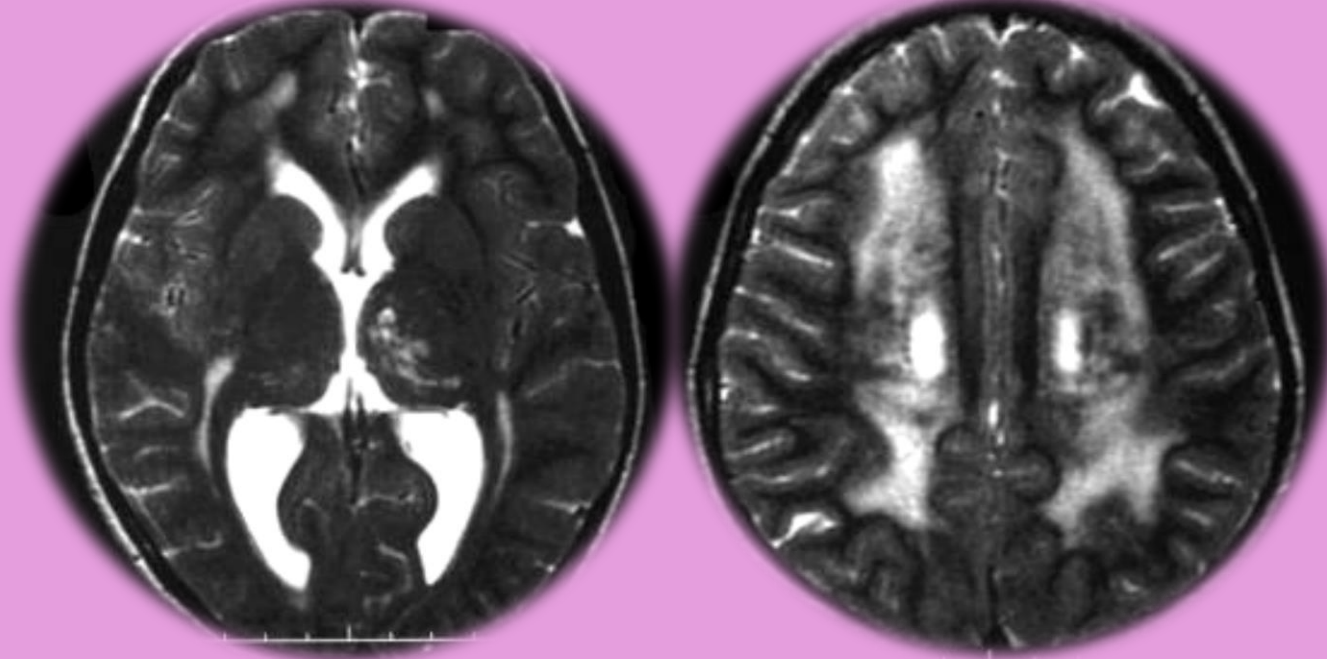
European Course on
Pediatric Neuroradiology in
Latin America (ECPNR-LATAM)
3rd Cycle - Module 1

LOOK AT THE SKIN!

Patient 1



Patient 2



LOOK AT THE SKIN!

HYPOMELANOSIS OF ITO



**“Incontinentia Pigmenti
Achromians, group of diseases
characterized by
hypopigmented streaks/spots
that follow the lines of
Blaschko.”**

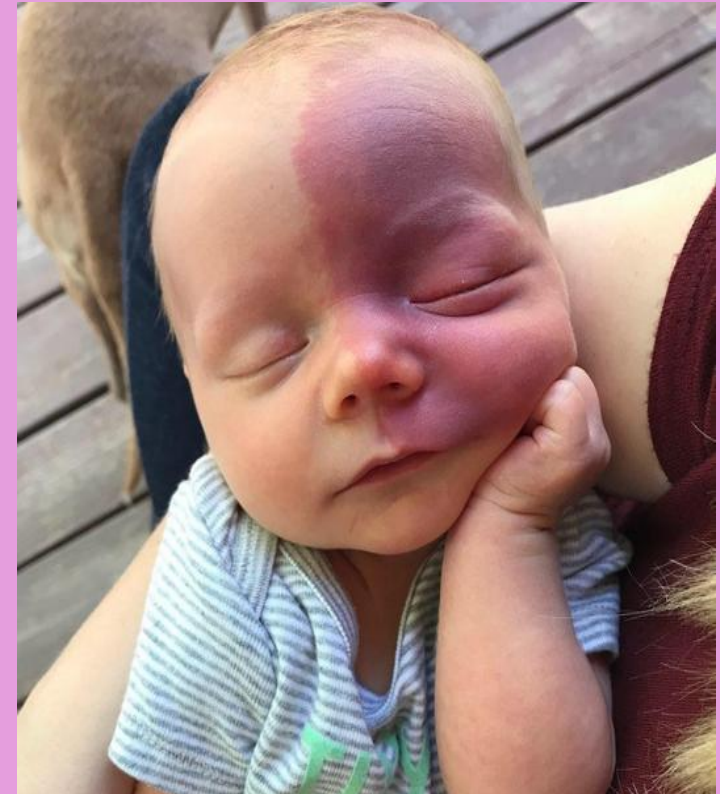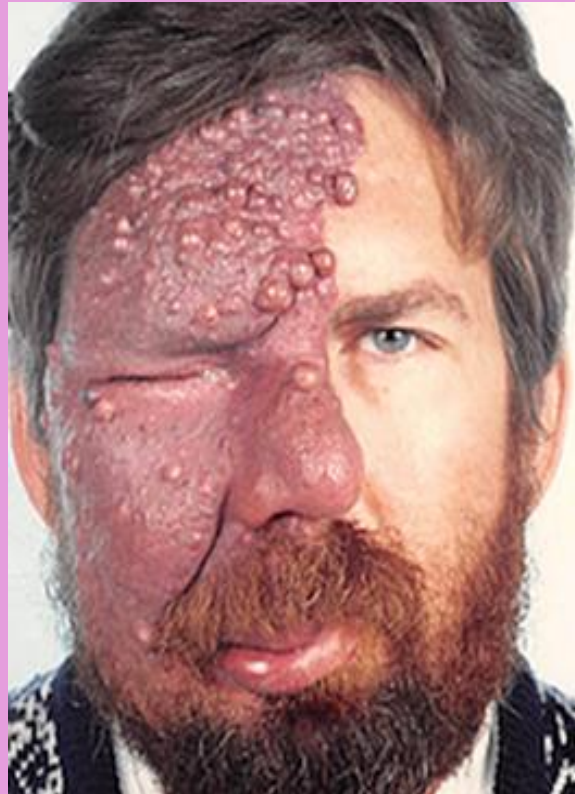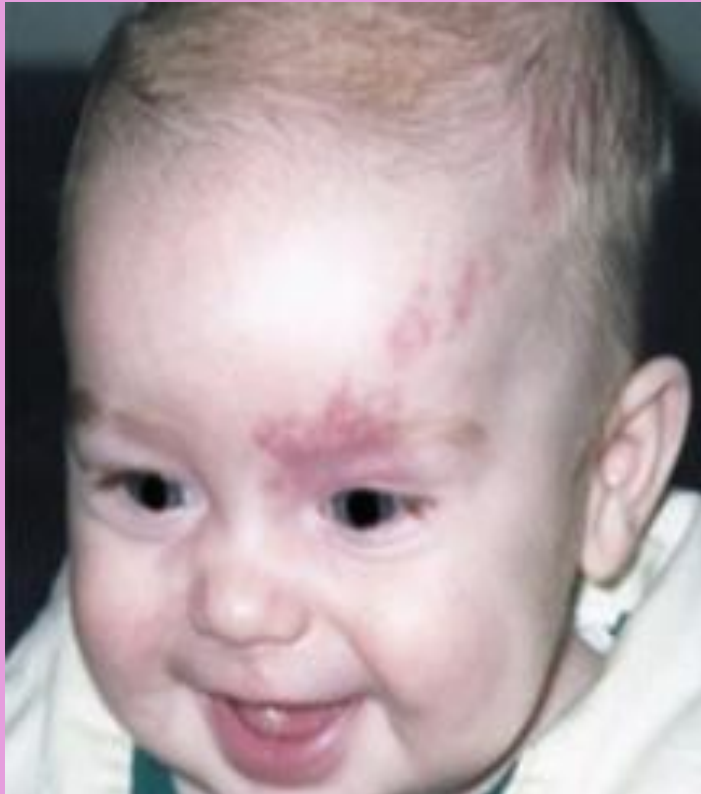Neuroimaging:

- Enlarged perivascular Spaces
- Signal alteration foci on T2/FLAIR in the white matter
- Hemimegalencephaly/hemiatrophy
- Hypoplasia/dysplasia of the CC (corpus callosum)

PHAKOMATOSES

European Course on
Pediatric Neuroradiology in
Latin America (ECPNR-LATAM)
3rd Cycle - Module 1

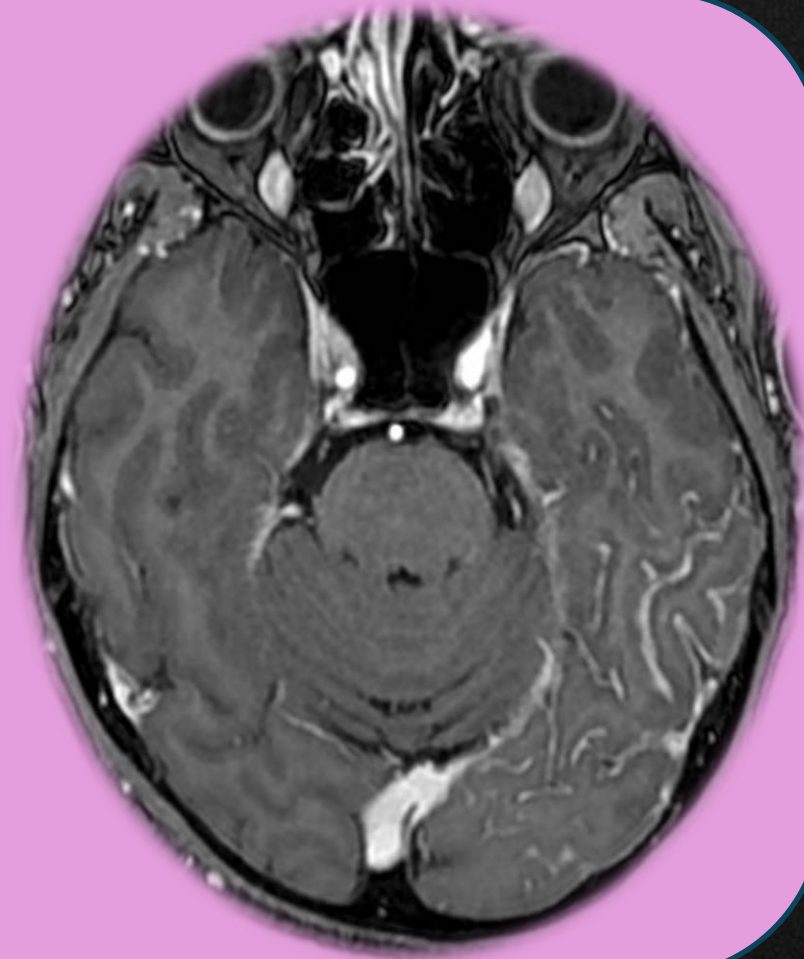
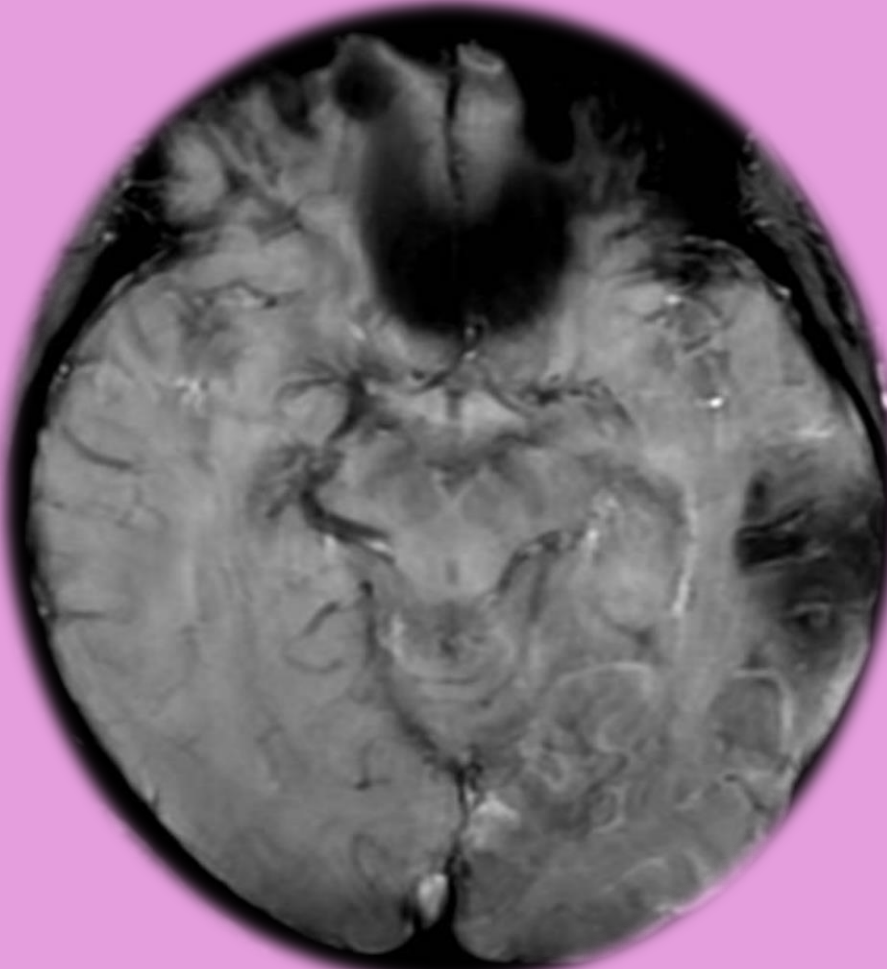
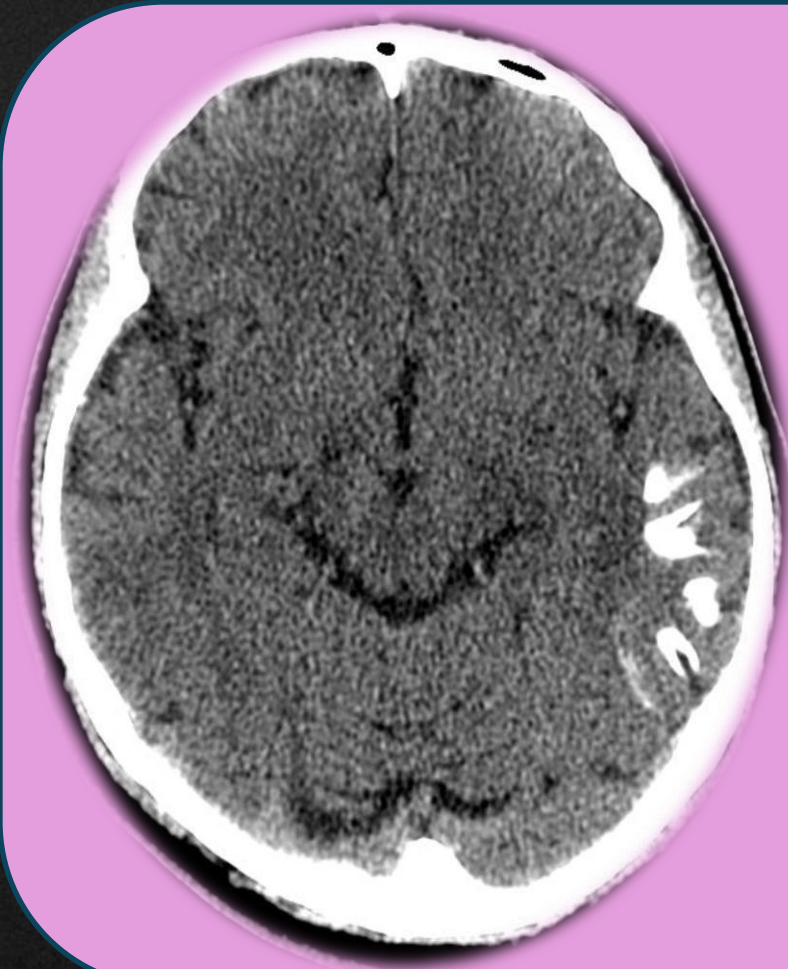
LOOK AT THE SKIN!



PHAKOMATOSES

European Course on
Pediatric Neuroradiology in
Latin America (ECPNR-LATAM)
3rd Cycle - Module 1

LOOK AT THE SKIN!



LOOK AT THE SKIN!

STURGE-WEBER SYNDROME Encephalotrigeminal Angiomas



Neurocutaneous syndrome, somatic mutation, congenital vascular dysfunction.

Key Features:

- Facial port-wine stain (usually V1 trigeminal area).
- Leptomeningeal angiomas (brain).
- ~5%: brain involvement without skin lesion.

Clinical:

- Seizures in childhood (~80%), often drug-resistant.
- Developmental delay, hemiplegia/hemiparesis, hemianopia.

Ocular involvement (~1/3):

- Choroidal/scleral angiomas → possible retinal detachment, buphthalmos, glaucoma.

⚡ Accelerated Myelination (Porto et al., Eur Radiol 2006):

In SWS, accelerated myelination can be seen on MRI in early childhood. It's considered a transient finding, often observed before the later appearance of atrophy and calcifications.

ROACH SCALE

TYPE I: Leptomeningeal plus facial +/- glaucoma

TYPE II: Facial only +/- glaucoma

TYPE III: Leptomeningeal only

Leptomeningeal Angiomas:

- Cortical/subcortical enhancement on post-contrast T1-weighted images, typically unilateral.

Cortical Atrophy

Calcifications:

- Tram-track or gyriform pattern, best visualized on CT but sometimes seen as low signal on T2/FLAIR MRI.

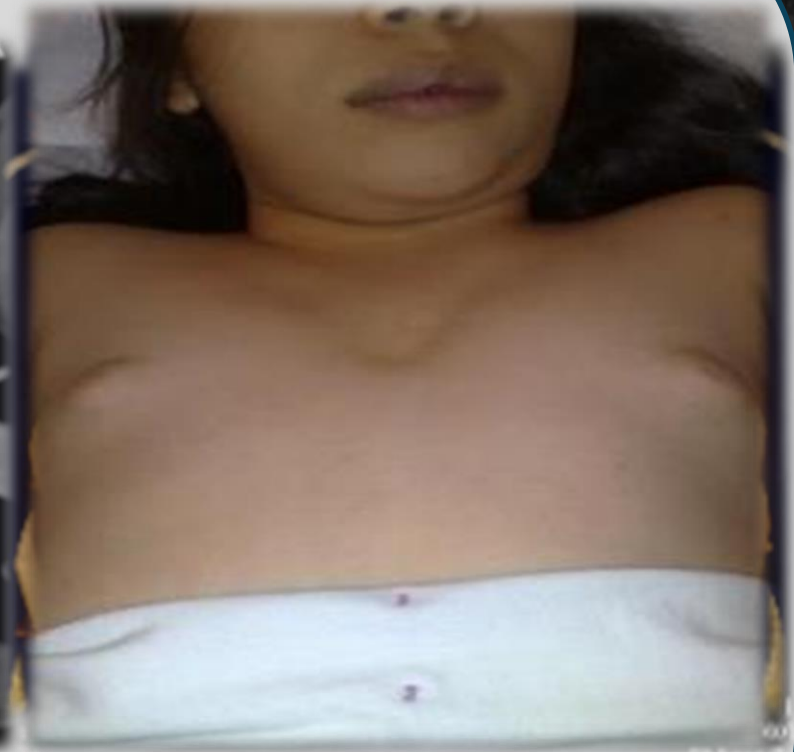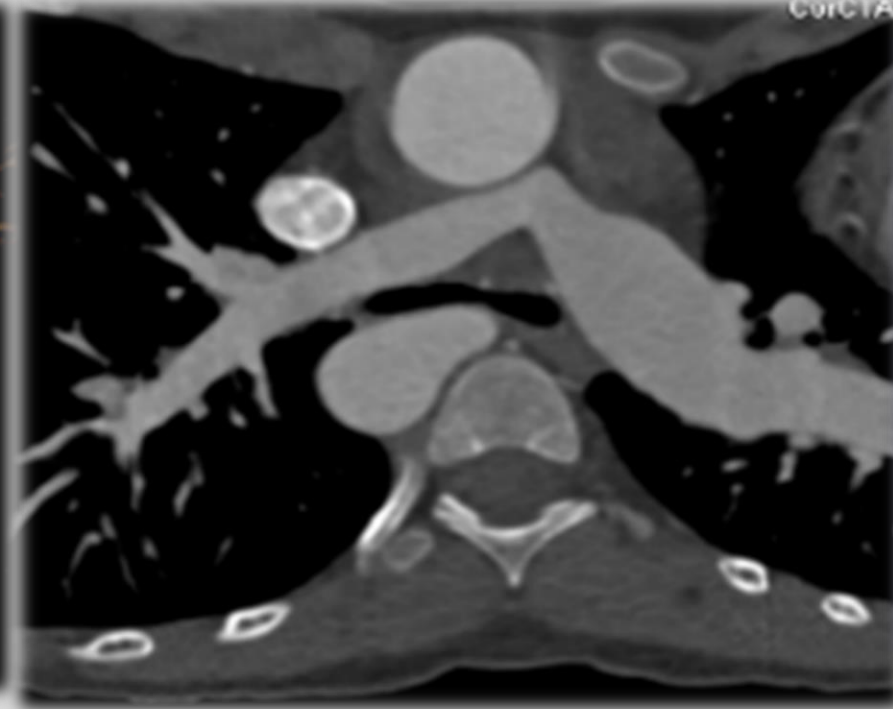
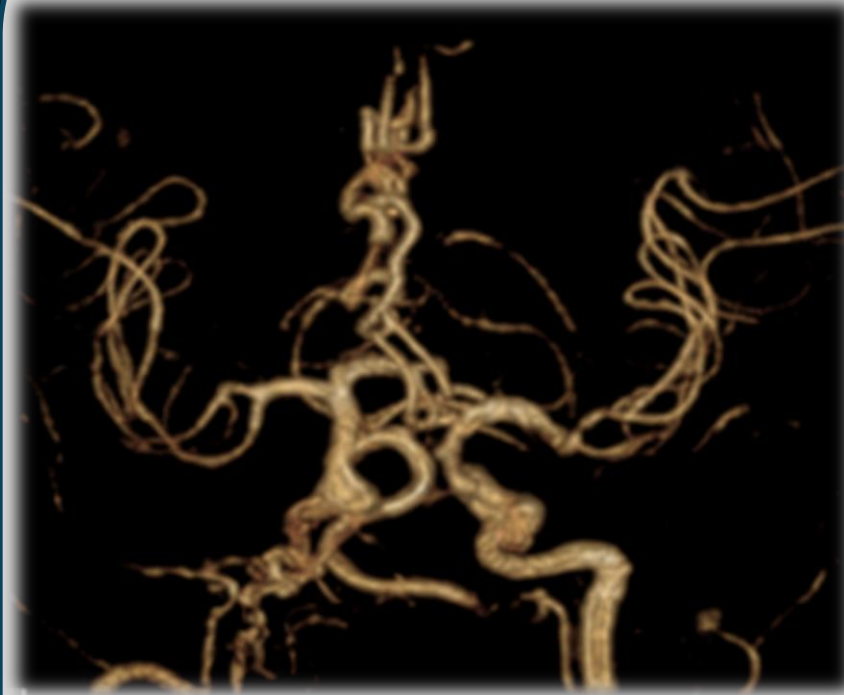
Enlarged Choroid Plexus:

- Frequently ipsilateral to the affected hemisphere.

PHAKOMATOSES

European Course on
Pediatric Neuroradiology in
Latin America (ECPNR-LATAM)
3rd Cycle - Module 1

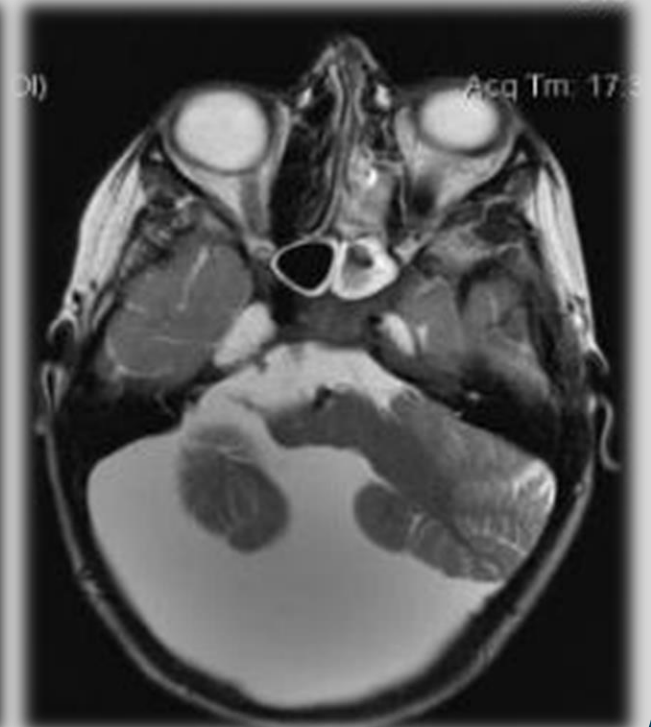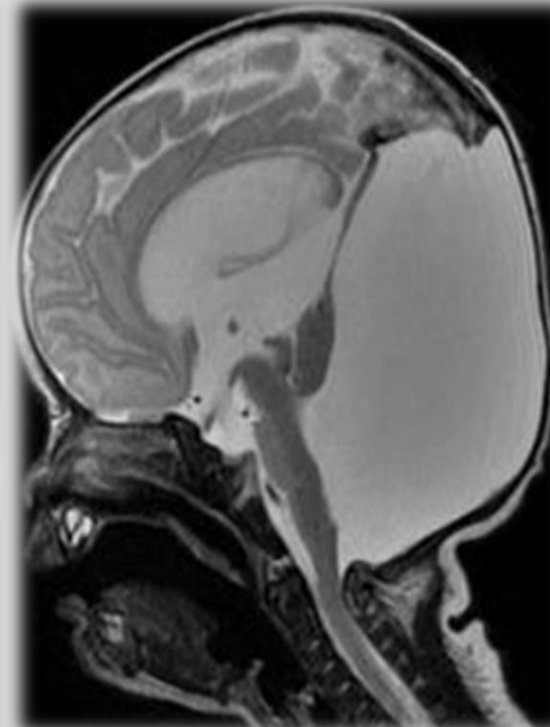
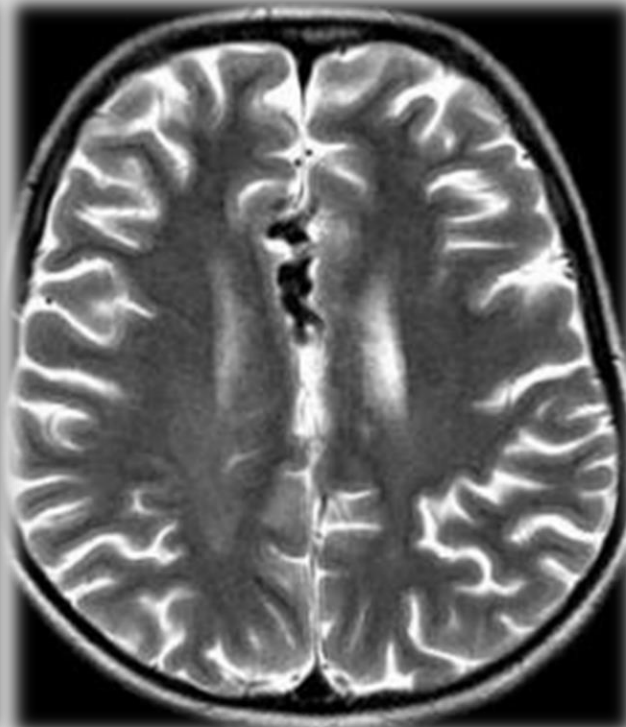
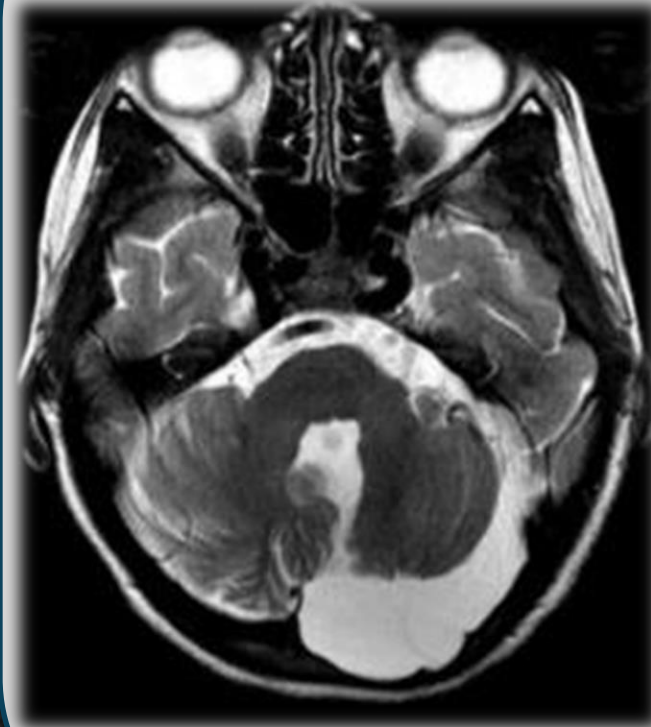LOOK AT THE VESSELS!



PHAKOMATOSES

European Course on
Pediatric Neuroradiology in
Latin America (ECPNR-LATAM)
3rd Cycle - Module 1

LOOK AT THE VESSELS!



PHAKOMATOSES

LOOK AT THE VESSELS!

PHACES

Definite PHACE = hemangioma >5 cm on face/scalp + ≥1 major or ≥2 minor criteria.
Possible PHACE = hemangioma >5 cm on face/scalp + ≥1 minor criterion.
Expanded definition = hemangioma on neck/chest/arm **or even absent hemangioma**, if systemic major/minor criteria are otherwise met.

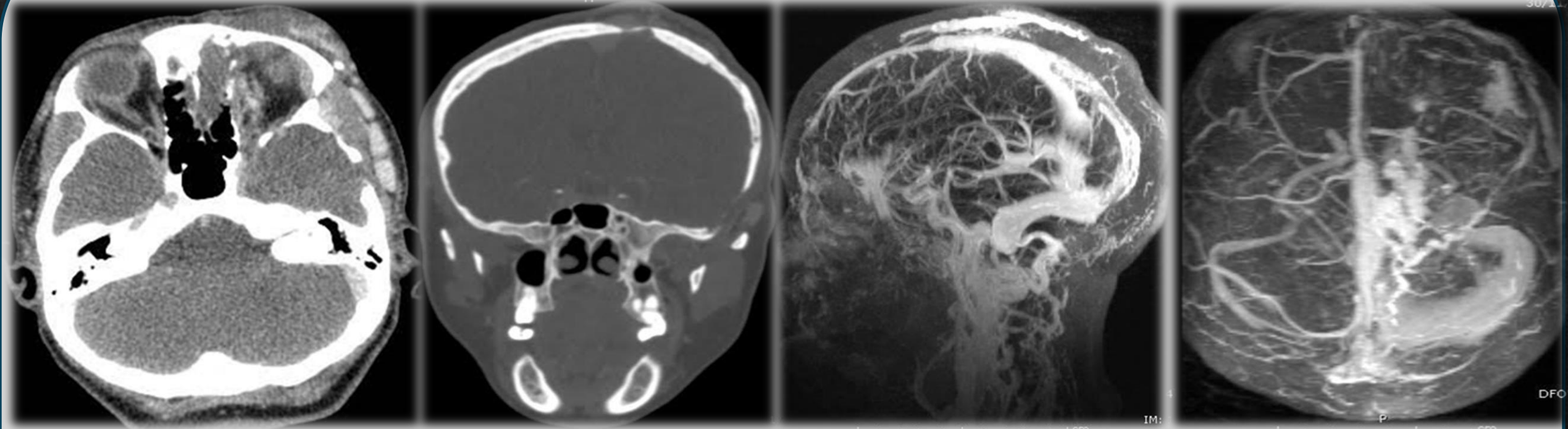
- P** Posterior fossa malformation
- H** Hemangiomas
- A** Arterial anomalies
- C** Coarctation of the aorta
- E** Eye abnormalities
- S** Cleft of the sternum and supraumbilical rafe

Category	Major Criteria	Minor Criteria
Posterior fossa brain malformations	Dandy–Walker malformation or variant	Other structural brain malformations (e.g., cerebellar hypoplasia)
Arterial anomalies	Dysplasia, stenosis, occlusion, or absence of major cerebral/cervical arteries; persistent embryonic arteries (trigeminal, hypoglossal, etc.)	Aberrant origin/course of cerebral/cervical arteries (without stenosis/occlusion)
Cardiac anomalies & aortic arch	Coarctation of the aorta, aneurysm, or dysplasia of the great vessels	Ventricular septal defect (VSD), atrial septal defect (ASD), patent ductus arteriosus (PDA)
Eye anomalies	Posterior segment anomalies: coloboma, persistent hyperplastic primary vitreous (PHPV), morning glory disc anomaly, optic nerve hypoplasia	Anterior segment anomalies: microphthalmia, cataract, sclerocornea
Sternal defects / supraumbilical raphe	Sternal cleft, supraumbilical raphe	—

PHAKOMATOSES

European Course on
Pediatric Neuroradiology in
Latin America (ECPNR-LATAM)
3rd Cycle - Module 1

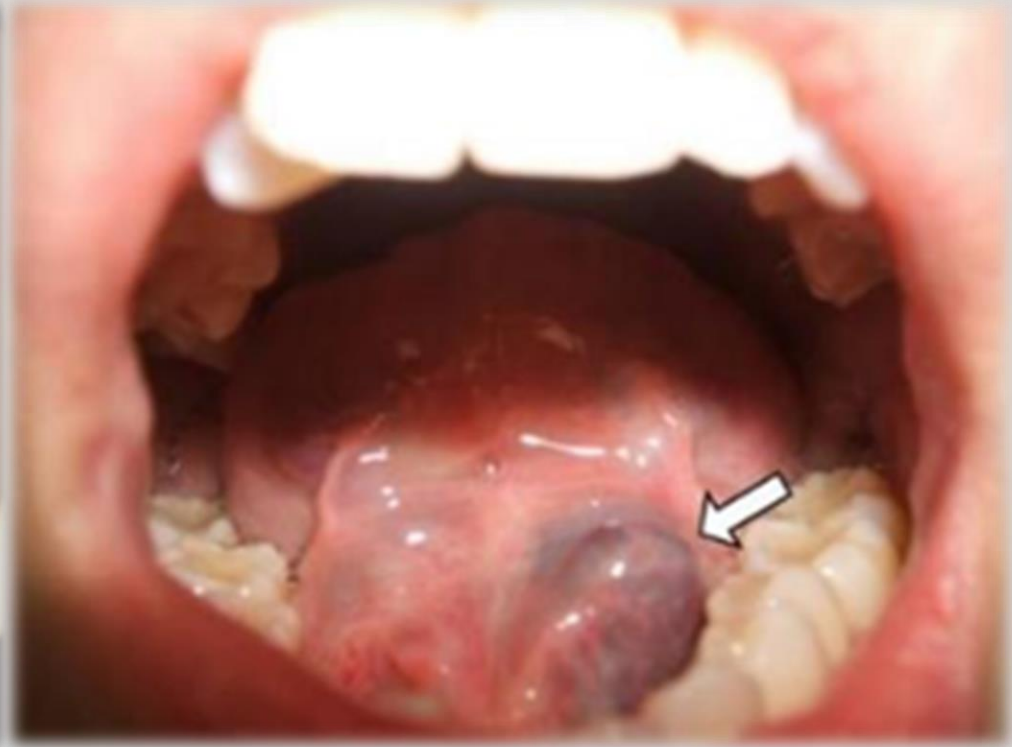
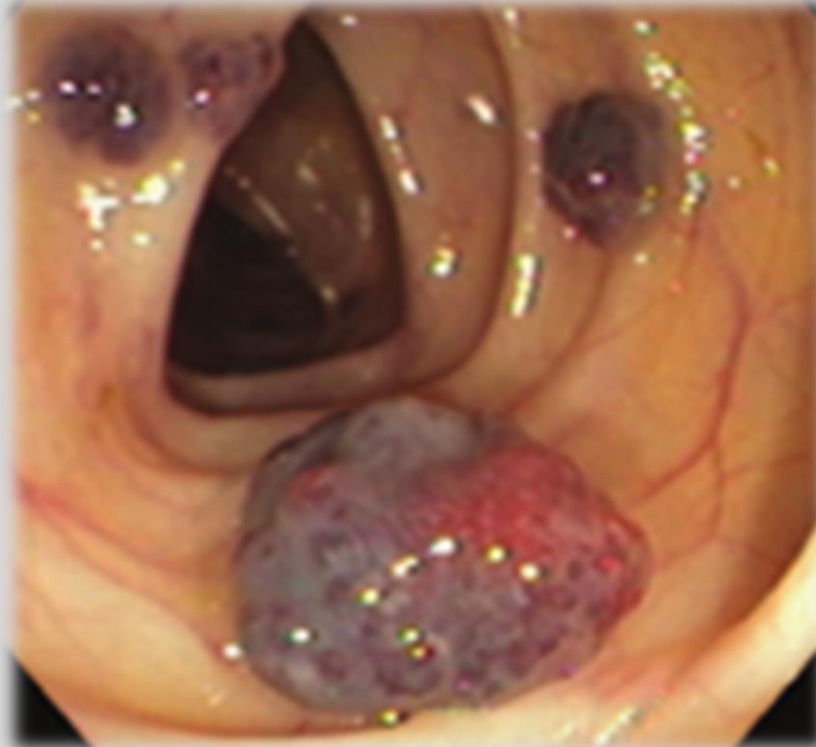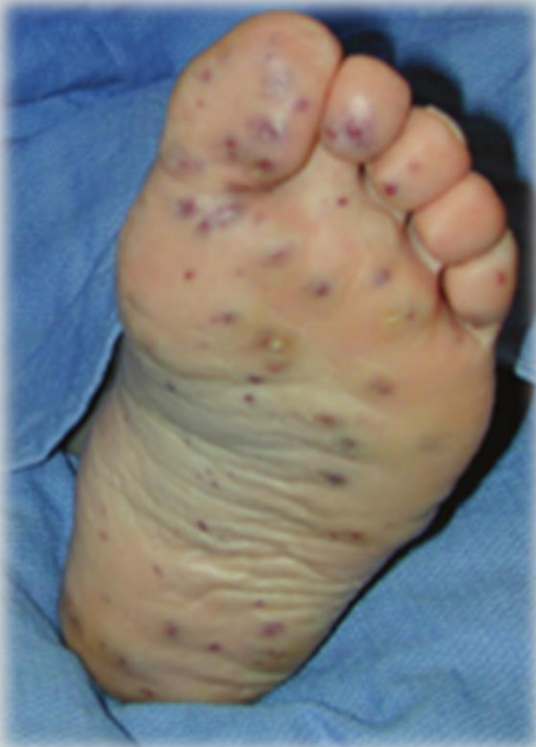LOOK AT THE VESSELS!



PHAKOMATOSES

European Course on
Pediatric Neuroradiology in
Latin America (ECPNR-LATAM)
3rd Cycle - Module 1

LOOK AT THE VESSELS!



PHAKOMATOSES – 3 TIPS

European Course on
Pediatric Neuroradiology in
Latin America (ECPNR-LATAM)
3rd Cycle - Module 1

LOOK AT THE VESSELS!

BLUE RUBBER BLEB NEVUS SYNDROME

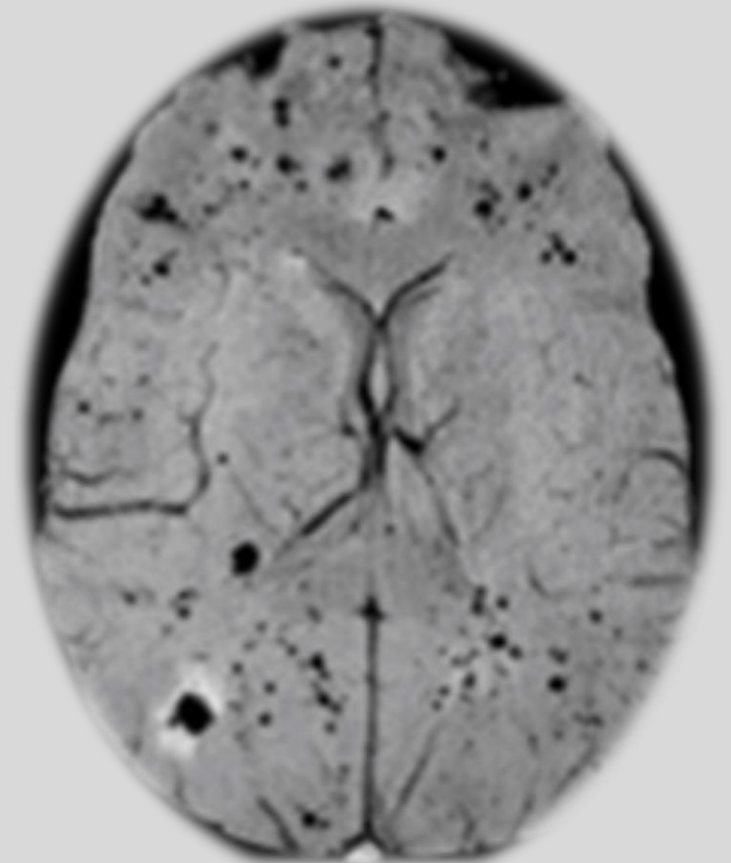
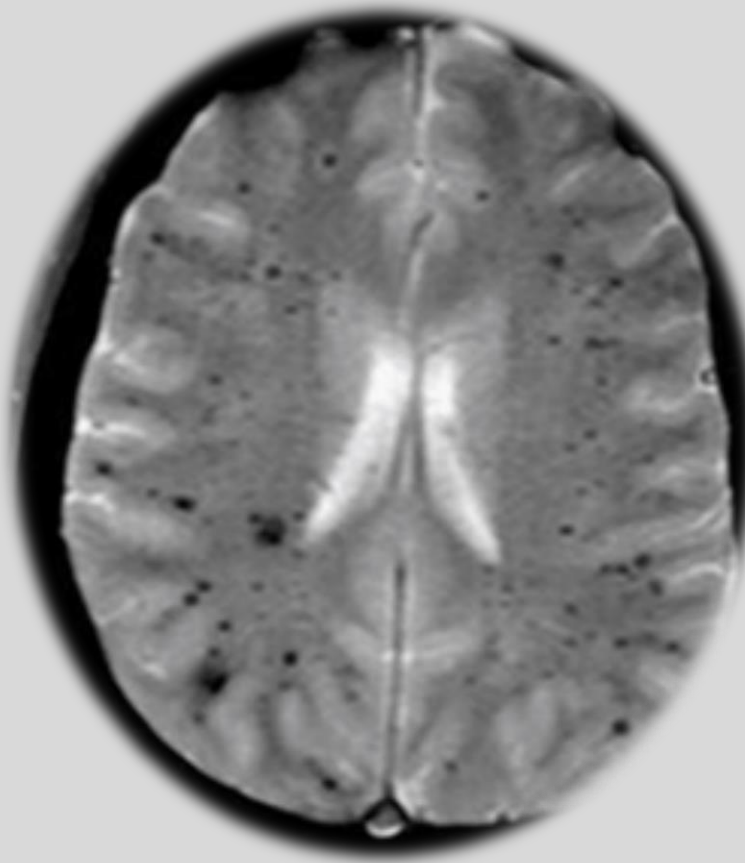
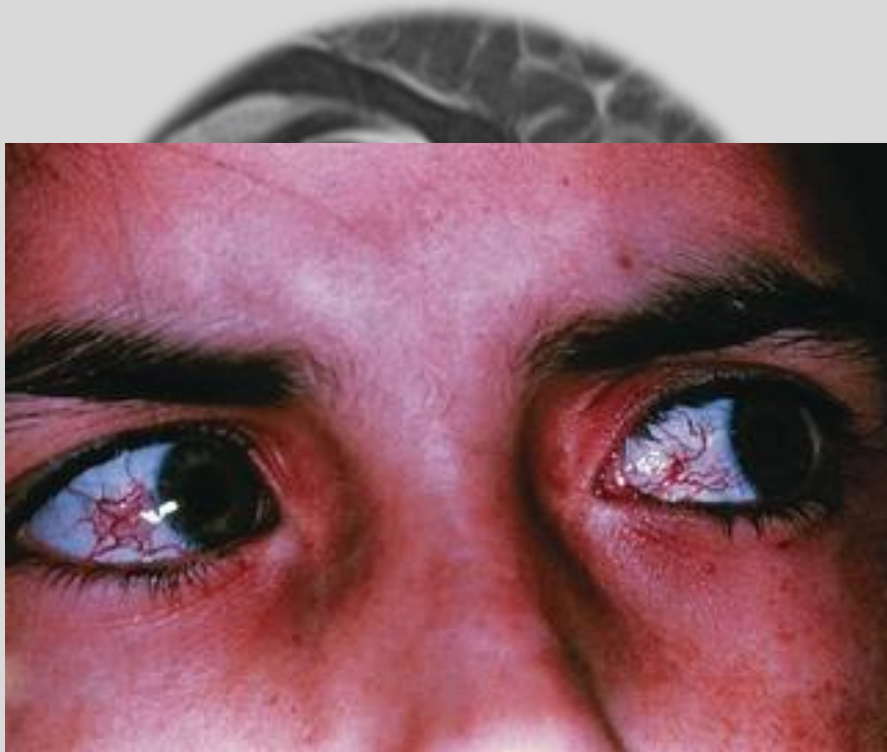

- Rare sporadic syndrome characterized by multifocal venous anomalies.
- Neuroimaging in the syndrome is composed of Hemangiomas, DVA, Sinus pericranii, Capillary Telangiectasia...

PHAKOMATOSES

European Course on
Pediatric Neuroradiology in
Latin America (ECPNR-LATAM)
3rd Cycle - Module 1

LOOK AT THE VESSELS!



Insights Imaging (2011) 2:335–347.

LOOK AT THE VESSELS!

ATAXIA-TELANGIECTASIA

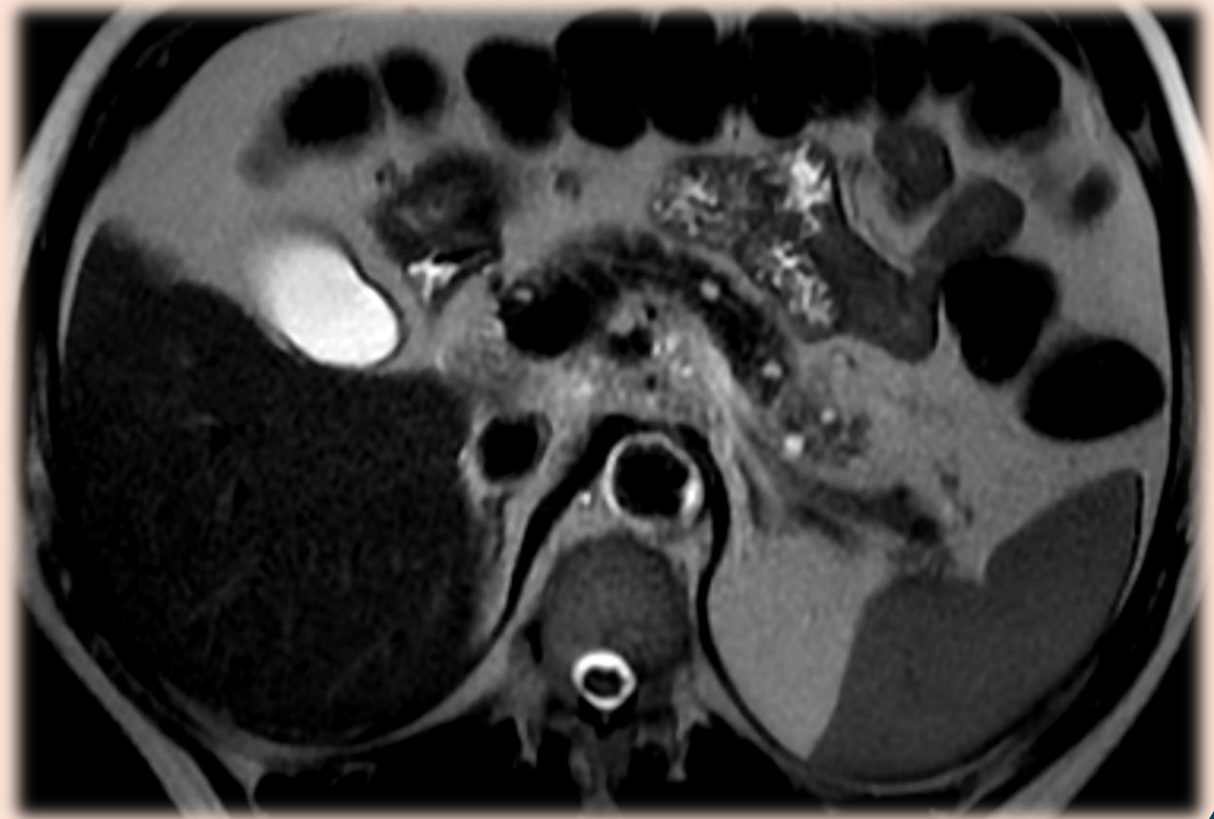
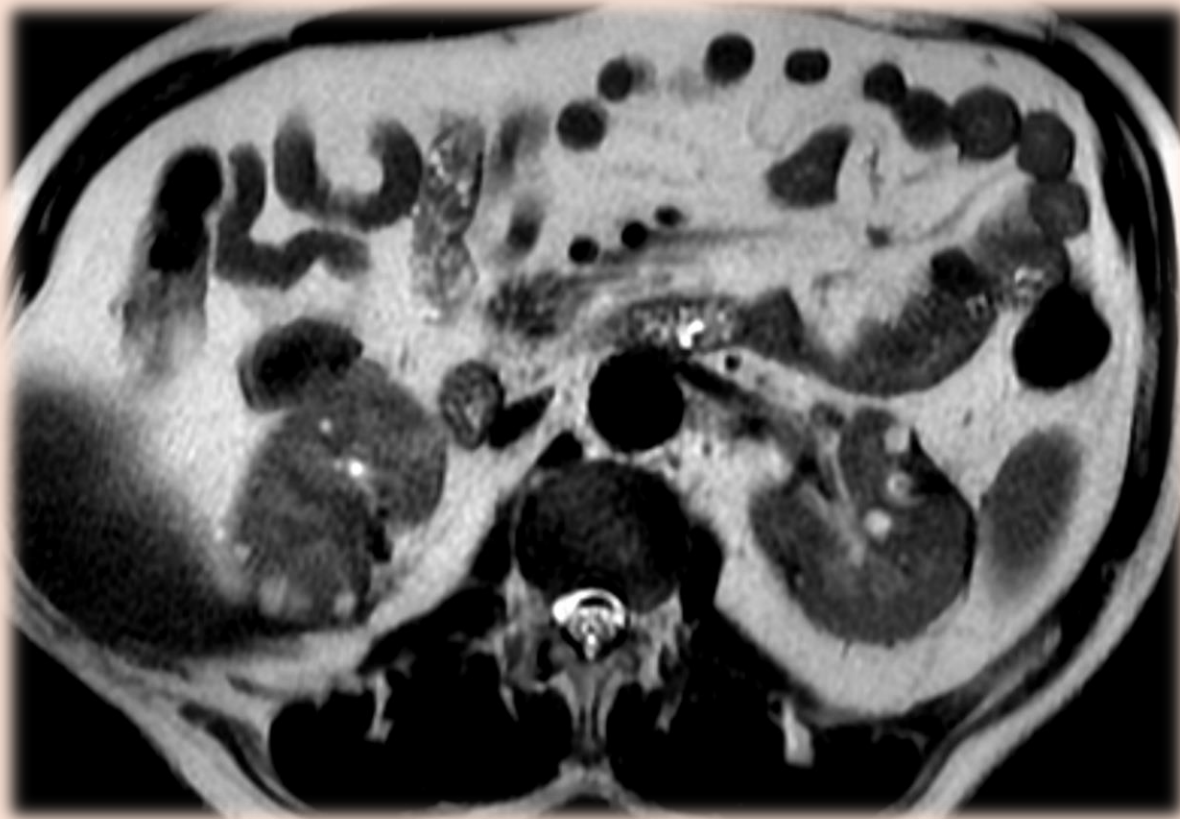


- **Louis-Bar Syndrome**
 - Incidence: 1:40,000 to 100,000
- **Autosomal recessive inheritance**
 - **ATM gene mutation**
 - Location: 11q22.3
- **Genomic instability** → increased sensitivity to ionizing radiation
- **Inadequate DNA repair** → neuronal degeneration
- Greater susceptibility to neoplasms: lymphoid, gliomas, medulloblastomas

PHAKOMATOSES

European Course on
Pediatric Neuroradiology in
Latin America (ECPNR-LATAM)
3rd Cycle - Module 1

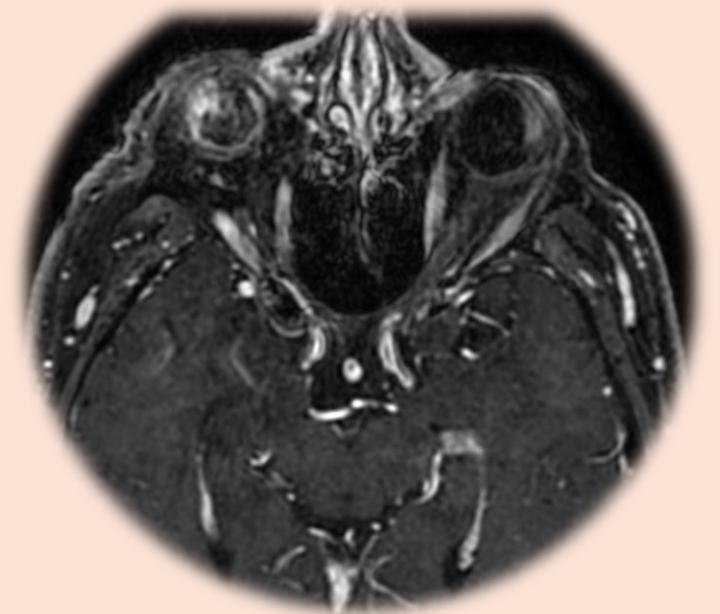
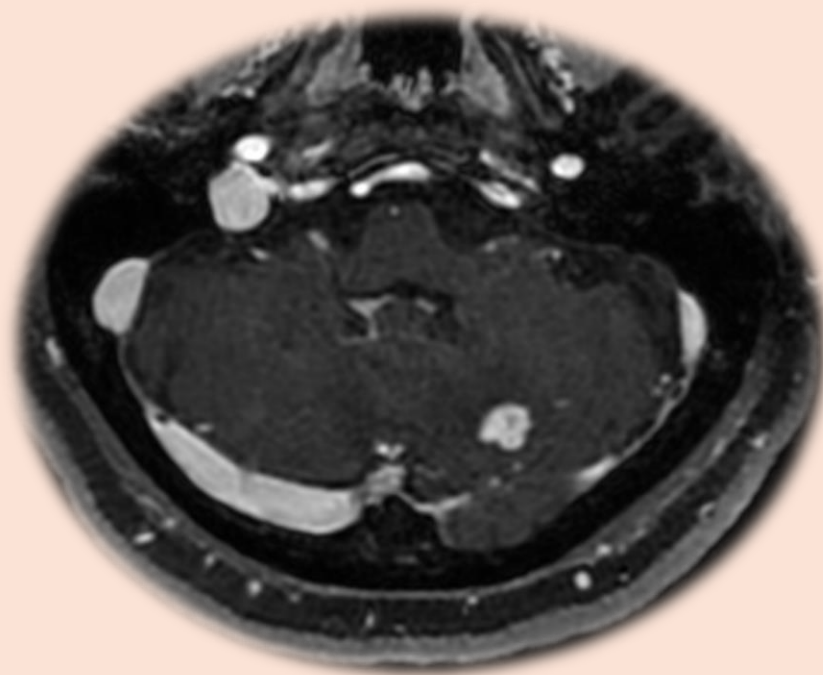
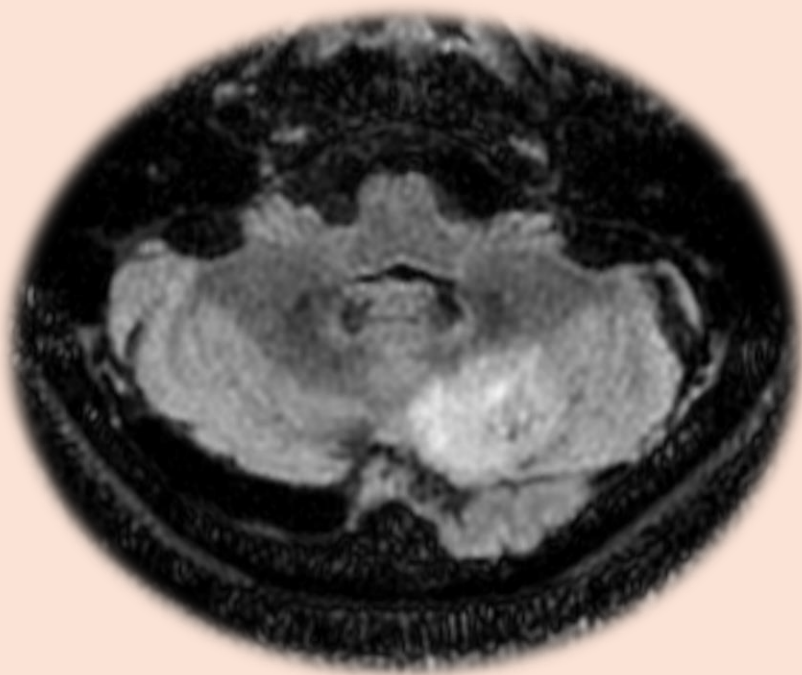
REVIEW THE DIFFERENTIAL DIAGNOSES!



PHAKOMATOSES

European Course on
Pediatric Neuroradiology in
Latin America (ECPNR-LATAM)
3rd Cycle - Module 1

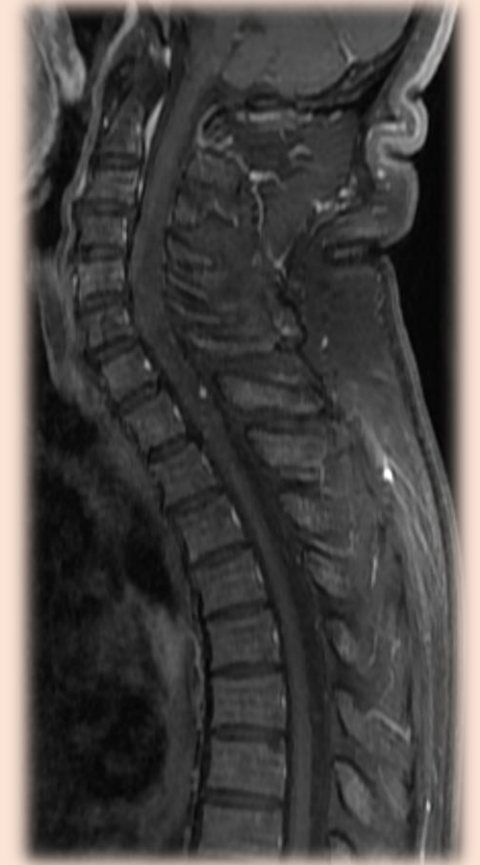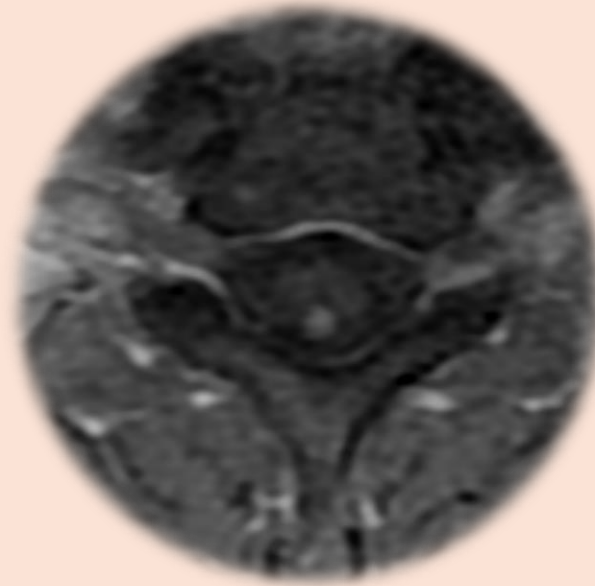
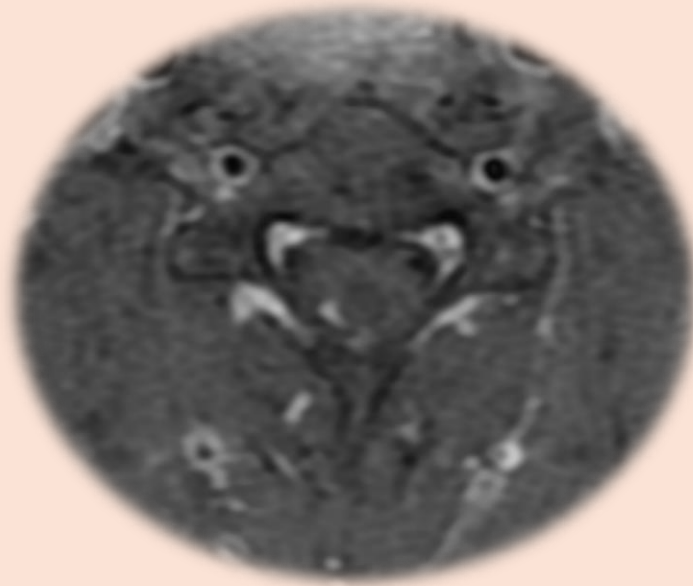
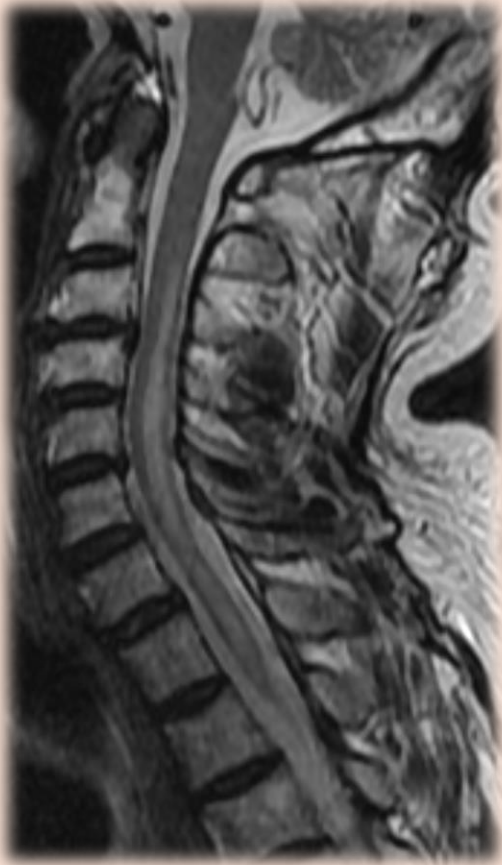REVIEW THE DIFFERENTIAL DIAGNOSES!



PHAKOMATOSES

European Course on
Pediatric Neuroradiology in
Latin America (ECPNR-LATAM)
3rd Cycle - Module 1

REVIEW THE DIFFERENTIAL DIAGNOSES!



REVIEW THE DIFFERENTIAL DIAGNOSES!

VON HIPPEL–LINDAU DISEASE (VHL)



- Autosomal dominant genetic condition (mutation in the tumor suppressor gene on chromosome 3p25.3)
- Characterized by visceral cysts, benign masses, and the potential for malignant transformation in multiple organ systems

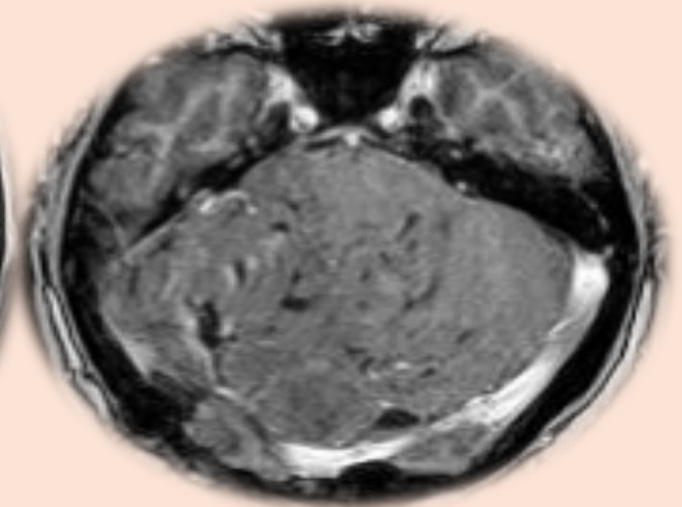
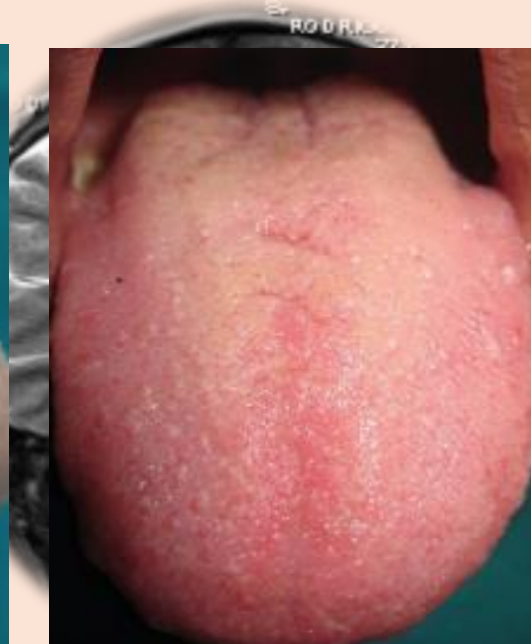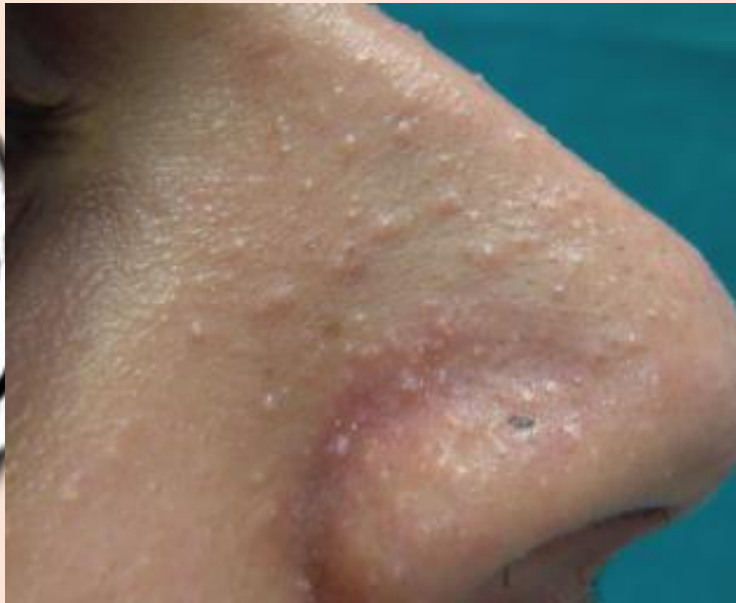
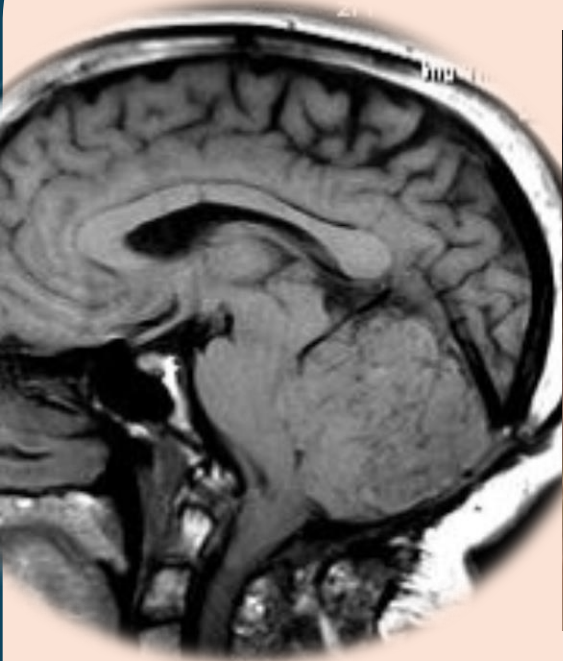
Clinical features:

- Eye tumor (*retinal hemangioblastomas*)
- Brain tumor (*CNS hemangioblastomas*)
- Kidney tumor (renal cell carcinoma)
- Adrenal gland tumor (pheochromocytoma)
- Pancreatic tumors (pancreatic serous cystadenoma)
- Cafe au lait spots
- CVS (strokes, and heart attacks)

PHAKOMATOSES

European Course on
Pediatric Neuroradiology in
Latin America (ECPNR-LATAM)
3rd Cycle - Module 1

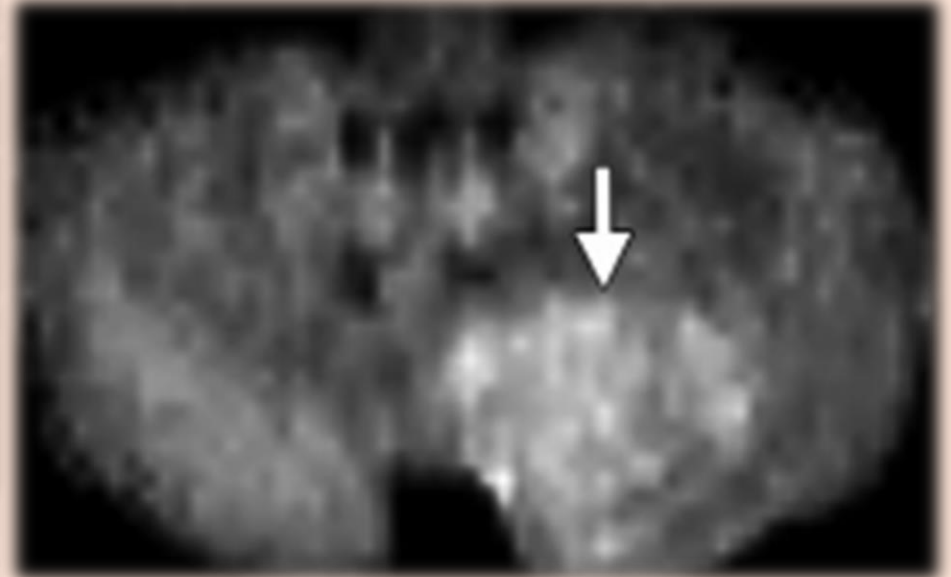
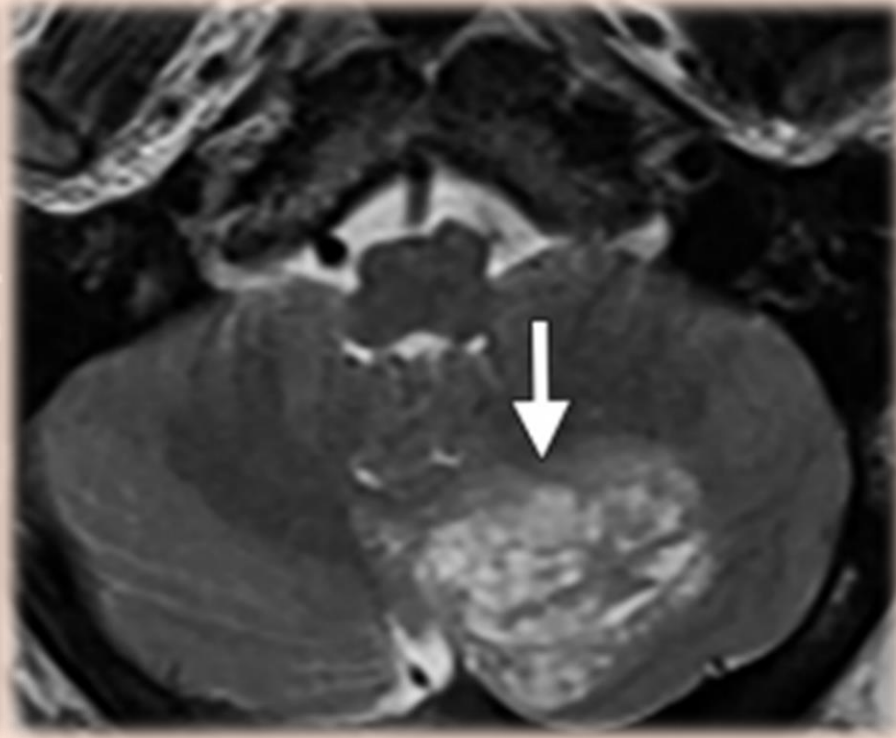
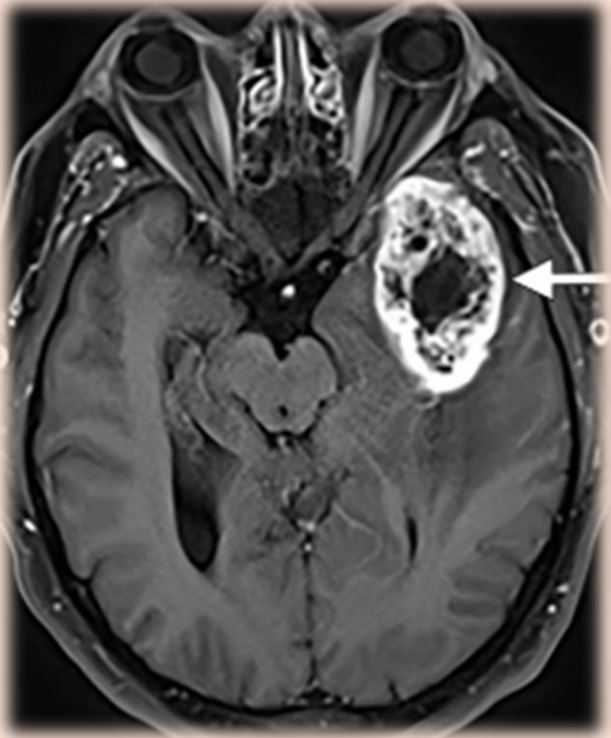
REVIEW THE DIFFERENTIAL DIAGNOSES!



PHAKOMATOSES

European Course on
Pediatric Neuroradiology in
Latin America (ECPNR-LATAM)
3rd Cycle - Module 1

REVIEW THE DIFFERENTIAL DIAGNOSES!



REVIEW THE DIFFERENTIAL DIAGNOSES!

COWDEN SYNDROME

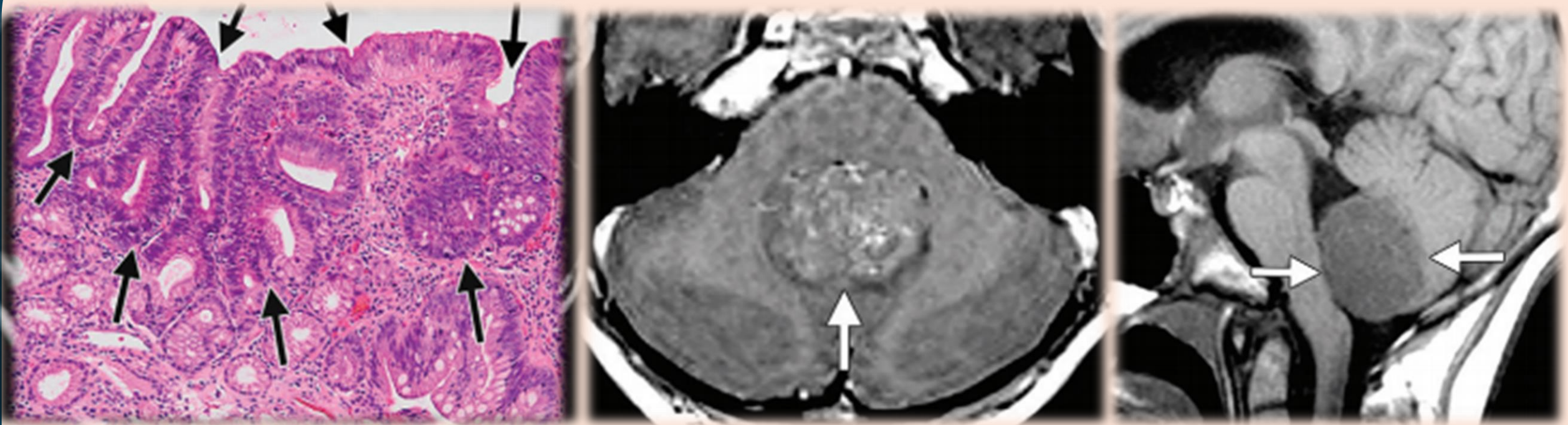


Pathognomonic criteria	Major criteria	Minor criteria
Mucocutaneous lesions:	Breast cancer	Other thyroid lesions (eg, goiter)
Trichilemmomas (facial)	Thyroid cancer	Mental retardation (IQ <75)
Acral keratoses	Macrocephaly	Hamartomatous intestinal polyps
Papillomatous lesions	Endometrial carcinoma	Fibrocystic disease of breast
Mucosal lesions		Lipomas
Lhermitte-Duclos disease (cerebellar dysplastic gangliocytoma)		Fibromas
		Genitourinary tumors

PHAKOMATOSES

European Course on
Pediatric Neuroradiology in
Latin America (ECPNR-LATAM)
3rd Cycle - Module 1

REVIEW THE DIFFERENTIAL DIAGNOSES!



PHAKOMATOSSES – 3 TIPS

European Course on
Pediatric Neuroradiology in
Latin America (ECPNR-LATAM)
3rd Cycle - Module 1

REVIEW THE DIFFERENTIAL DIAGNOSES!

TURCOT SYNDROME



- Turcot syndrome is a historical term used to describe the association of primary CNS tumors and two different forms of colorectal polyps: FAP and hereditary colorectal cancer not related to polyposis (Lynch syndrome).
- Medulloblastoma (WNT), Astrocytoma, and Ependymoma.

PHAKOMATOSES

European Course on
Pediatric Neuroradiology in
Latin America (ECPNR-LATAM)
3rd Cycle - Module 1

TAKE HOME MESSAGE



LOOK AT THE SKIN!

LOOK AT THE VESSELS!

REVIEW THE DIFFERENTIAL DIAGNOSES!

REFERENCES

1. Anne G. Osborn, Gary L. Hedlund, Karen L. Salzman. Osborn's Brain E-Book. (2017).
2. Rocha, Antônio J., Leonardo, Vedolin, Mendonça, Renato A. Encéfalo – Série CBR. Editora Elsevier. 1^a Edição, 2013.
3. McCarville MB: What MRI can tell us about neurogenic tumors and rhabdomyosarcoma. *Pediatr Radiol.* 46(6):881-90, 2016.
4. Rad E et al: Neurofibromatosis type 1: fundamental insights into cell signalling and cancer. *Semin Cell Dev Biol.* 52:39-46, 2016.
5. Chaudhry IA et al: Orbitofacial neurofibromatosis: clinical characteristics and treatment outcome. *Eye (Lond).* 26(4):583-92, 2012.
6. Moharir M et al: Utility of positron emission tomography for tumour surveillance in children with neurofibromatosis type 1. *Eur J Nucl Med Mol Imaging.* 37(7):1309-17, 2010,
7. Brems H et al: Mechanisms in the pathogenesis of malignant tumours in neurofibromatosis type 1. *Lancet Oncol.* 10(5):508-15, 2009.
8. Laffan EE et al: Pediatric soft-tissue tumors and pseudotumors: MR imaging features with pathologic correlation: part 2. Tumors of fibroblastic/myofibroblastic, so-called fibrohistiocytic, muscular, lymphomatous, neurogenic, hair matrix, and uncertain origin. *Radiographics.* 29(4):e36, 2009.
8. Nissenkorn A, Ben-Zeev B. Ataxia telangiectasia. *Handb Clin Neurol* 2015;132:199–214.
9. Sahnane N, Bernasconi B, Carnevali I, et al. Disruption of the APC gene by t(5;7) translocation in a Turcot family. *Cancer Genet* 2016;209(3):107–111.
10. Selvanathan SK, Shenton A, Ferner R, et al. Further genotype-phenotype correlations in neurofibromatosis 2. *Clin Genet* 2010;77(2):163–170.
11. Smith MJ, Higgs JE, Bowers NL, et al. Cranial meningiomas in 411 neurofibromatosis type 2 (NF2) patients with proven gene mutations: clear positional effect of mutations, but absence of female severity effect on age at onset. *J Med Genet* 2011;48(4):261–265.
12. Kwiatkowski DJ, Manning BD. Molecular basis of giant cells in tuberous sclerosis complex. *N Engl J Med* 2014;371(8): 778–780.
13. Child ND, Benarroch EE. mTOR: its role in the nervous system and involvement in neurologic disease. *Neurology* 2014;83(17):1562–1572.
14. Gossage L, Eisen T, Maher ER. VHL: the story of a tumour suppressor gene. *Nat Rev Cancer* 2015;15(1):55–64. 8. Zannolli R, Buoni S, Betti G, et al. A randomized trial of oral betamethasone to reduce ataxia symptoms in ataxia telangiectasia. *Mov Disord* 2012;27(10):1312–1316.
15. Amakye D, Jagani Z, Dorsch M. Unraveling the therapeutic potential of the Hedgehog pathway in cancer. *Nat Med* 2013; 19(11):1410–1422.
16. Pilarski R, Burt R, Kohlman W, Pho L, Shannon KM, Swisher E. Cowden syndrome and the PTEN hamartoma tumor syndrome: Systematic review and revised diagnostic criteria. *J Natl Cancer Inst* 2013;105:1607-16.

vhmarussi@gmail.com

