

European Course on
Pediatric Neuroradiology in
Latin America (ECPNR-LATAM)

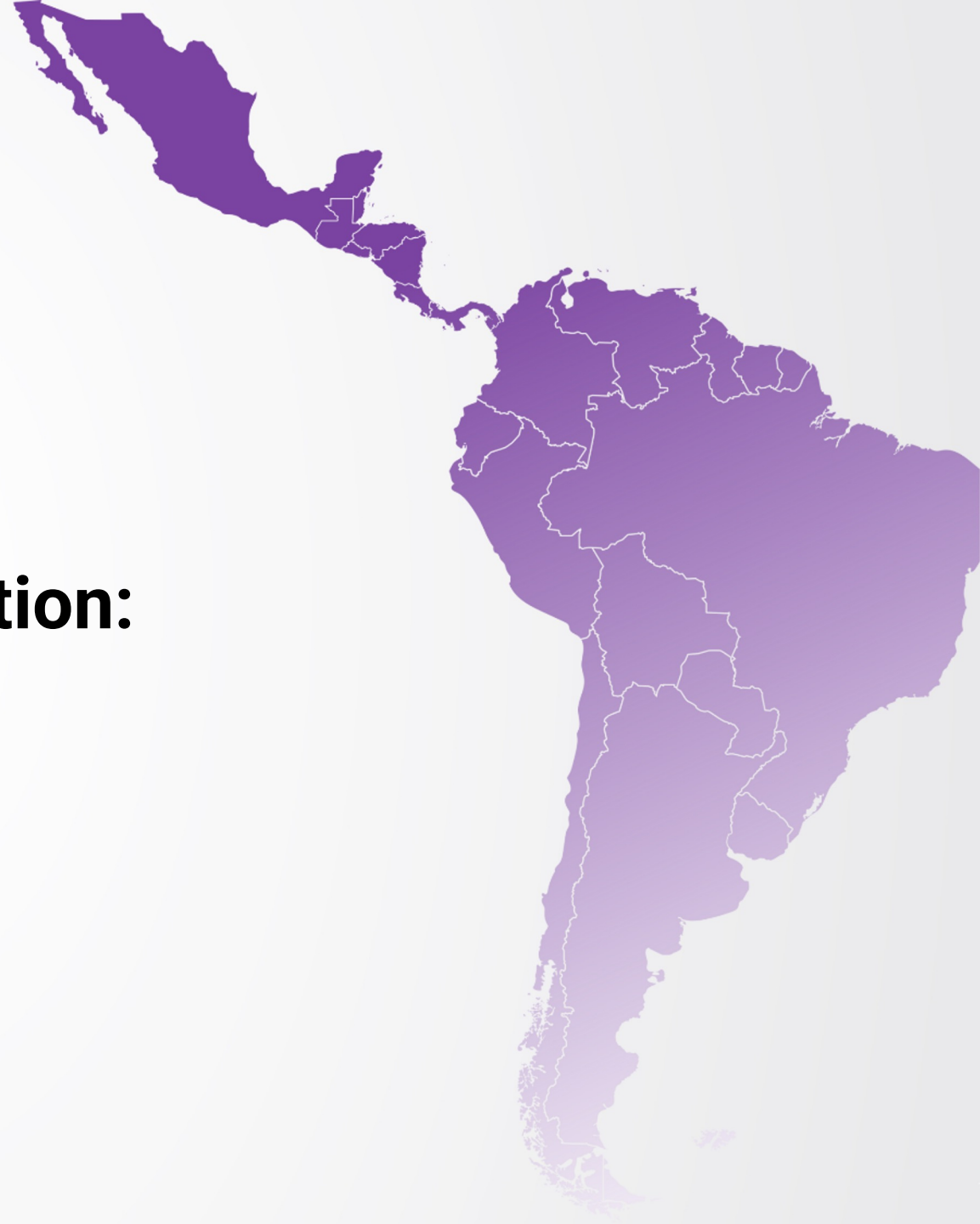3rd Cycle - Module 1

**MRI from Microstructure to Function:
*DTI, Perfusion, ASL, MRS***

Idealização:



Organização:



European Course on
Pediatric Neuroradiology in
Latin America (ECPNR-LATAM)
3rd Cycle - Module 1

CESAR ALVES

- **Pediatric Neuroradiologist at Boston Children's Hospital**
- **Assistant Professor at Harvard Medical School**
- **Associate Program Director of Clinical Fellowship**

Idealização:



Organização:



MRI from Microstructure to Function: *DTI, Perfusion, ASL, MRS*

European Course on
Pediatric Neuroradiology in
Latin America (ECPNR-LATAM)
3rd Cycle - Module 1

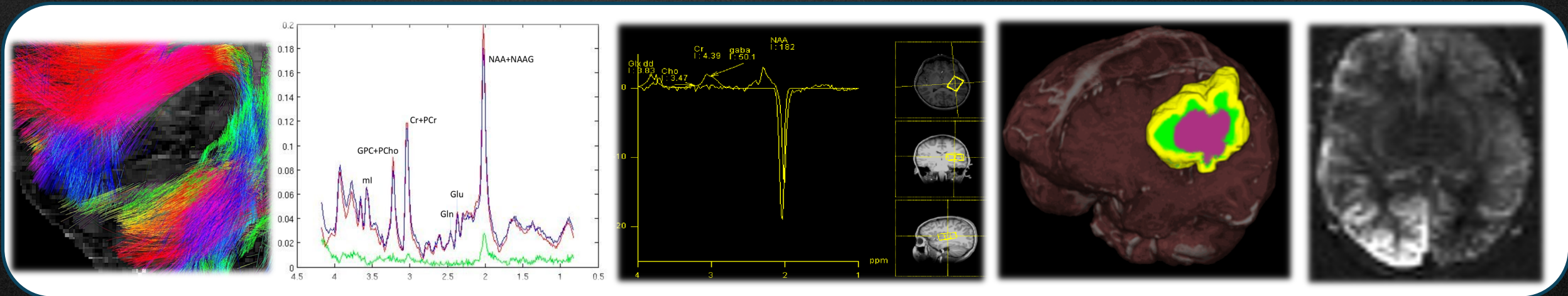
There is no conflict of interest in this presentation

MRI from Microstructure to Function: DTI, Perfusion, ASL, MRS

European Course on
Pediatric Neuroradiology in
Latin America (ECPNR-LATAM)
3rd Cycle - Module 1

Advanced techniques

- **Perfusion:** DCS, ASL, DCE permeability, IVIM
- **Diffusion:** DWI, DTI, DSI, HARDI, IVIM, DKI, DBSI, SMT, CHARMED, NODDI
- **MR Spectroscopy:** 3D MRSI, MIDAS, advances spectral editing, Non-H1 MRS
- **F-MRI:** tasked based, rsf, various functional connective measures
- **Various Mapping:** T1 Mapping, T2 Mapping, T1 rho-Mapping, R2* Mapping, SWI QSM, MPI, myelin water, McDESPOT, qMT, MTC, MTR, CEST, APT, NA imaging, Calibrated BOLD, qBOLD, TRUST, Oxflow, QUIXOTIC



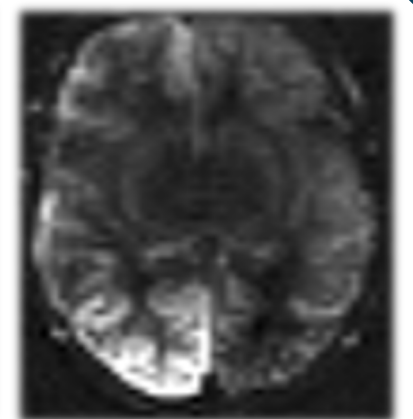
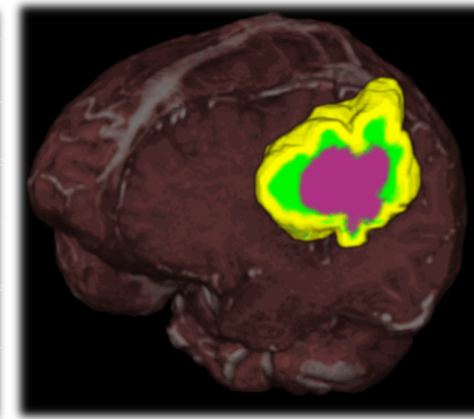
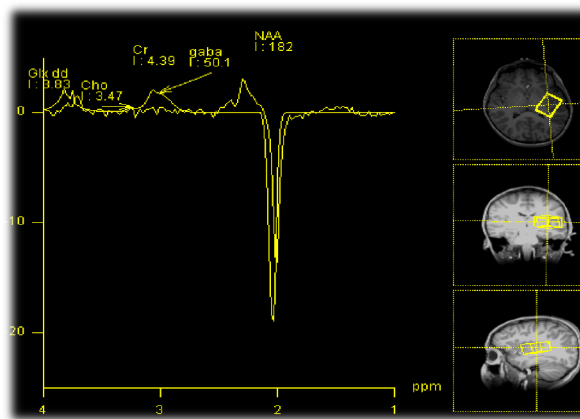
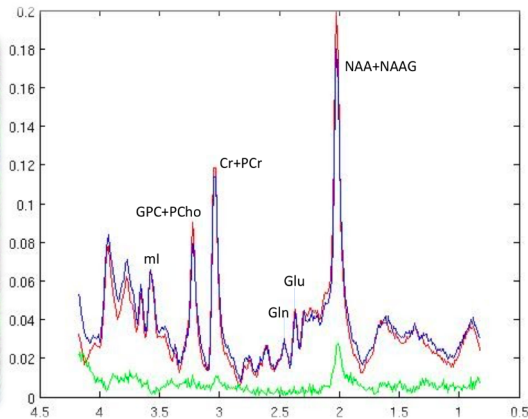

MRI from Microstructure to Function: *DTI, Perfusion, ASL, MRS*

European Course on
Pediatric Neuroradiology in
Latin America (ECPNR-LATAM)
3rd Cycle - Module 1

DTI


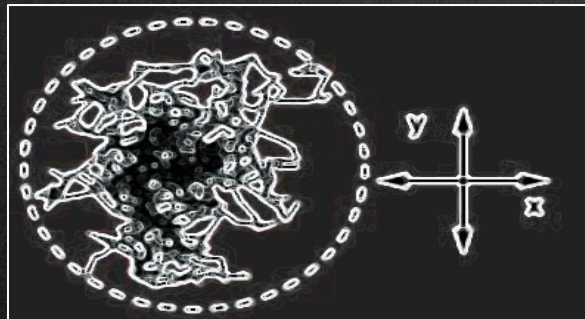
MRS

ASL



Diffusion tensor imaging


- DTI: quantitative technique
 - Measures the **rate** and **direction** of movement of water molecules within tissues - *Multiple DW gradients applied in various directions*
- **In the CNS:** axonal tracts and myelin present physical barriers
 - Impose directionality or **anisotropy** on water diffusion



“Measures the movement of water along axons, analogous to the straws in a glass of water”

Diffusion tensor imaging

- DTI: quantitative technique
 - Measures the **rate** and **direction** of movement of water molecules within tissues - *Multiple DW gradients applied in various directions*
- **In the CNS:** axonal tracts and myelin present physical barriers
 - Impose directionality or **anisotropy** on water diffusion



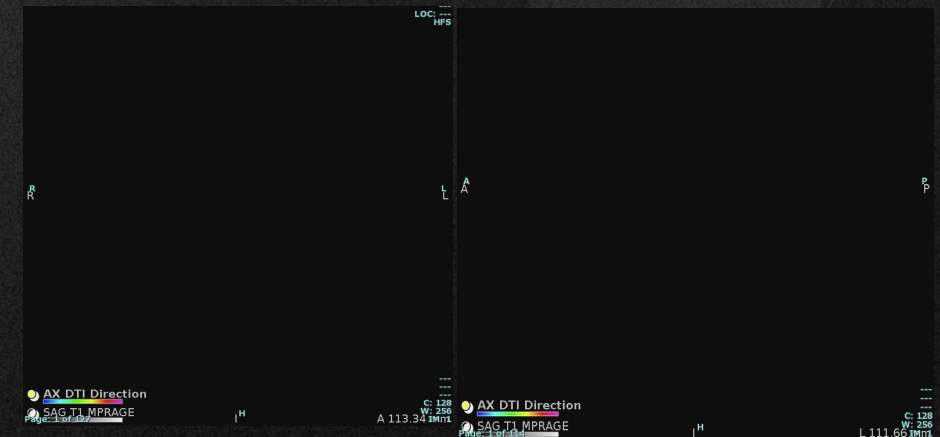
- Deviation, infiltration, destruction of white matter

- ROI (region of interest) based
- Voxel-based
- Histogram analysis

“Measures the movement of water along axons, analogous to the straws in a glass of water”

Diffusion tensor imaging

- DTI: quantitative technique
 - Measures the **rate** and **direction** of movement of water molecules within tissues - *Multiple DW gradients applied in various directions*
- **In the CNS:** axonal tracts and myelin present physical barriers
 - Impose directionality or **anisotropy** on water diffusion



“Measures the movement of water along axons, analogous to the straws in a glass of water”

3 - BRAIN - CRITICAL (5 MINUTES)

3 - Brain - Stroke - Critical (5 minutes)

1 - AX DTI (fast) (brain) 2 minutes

1 - AX T2 (fast) (brain) 2 minutes

1 - AX SWI (fast) (brain) 2 minutes

Total Sequence Time: 6 minutes

METABOLIC BRAIN – DETAILED – METABOLIC QUANTIFICATION (3T)

(CESAR –cesar.alves@children.harvard.edu)

Brain – Metabolic detailed quantification (3T)

DEFAULT: MD CHECK

1. *AX MP2RAGE STEALTH (brain) (no angle; entire nose and ears thru top of skull; no AV system) 10 minutes (postprocessing MPRAGE should be done)
2. AX T2 (brain) 4 minutes
3. AX T2 FLAIR FS (brain) 4 minutes
4. +MRS 3D CSI TE=30ms (basal ganglia) 3 minutes
5. +MRS 3D CSI TE= 135ms (basal ganglia) 3 minutes
6. +MRS 3D CSI TE= 30ms (posterior fossa) 3 minutes
7. AX CUSP90 Tractography w/AP-PA dist corr (brain) 11 minutes
8. COR T2 (brain) 4 minutes
9. SAG T2 (brain) FAST 2 minutes (optional)
10. AX PASL 3D (brain) 5 minutes (mostly with GM involvement - optional)
11. AX SWI (fast) 2 minutes

+ Post-processing before the end of the scan

- (45 - 50 minutes) future with sequence improvement may reduce to around 35 minutes

Myelin quantification -----

1. CPMG Myelin (3D multi-echo GRASE) -requires consent 10 minutes
2. * QALAS (or QSM depending on availability) requires consent (10 minutes)

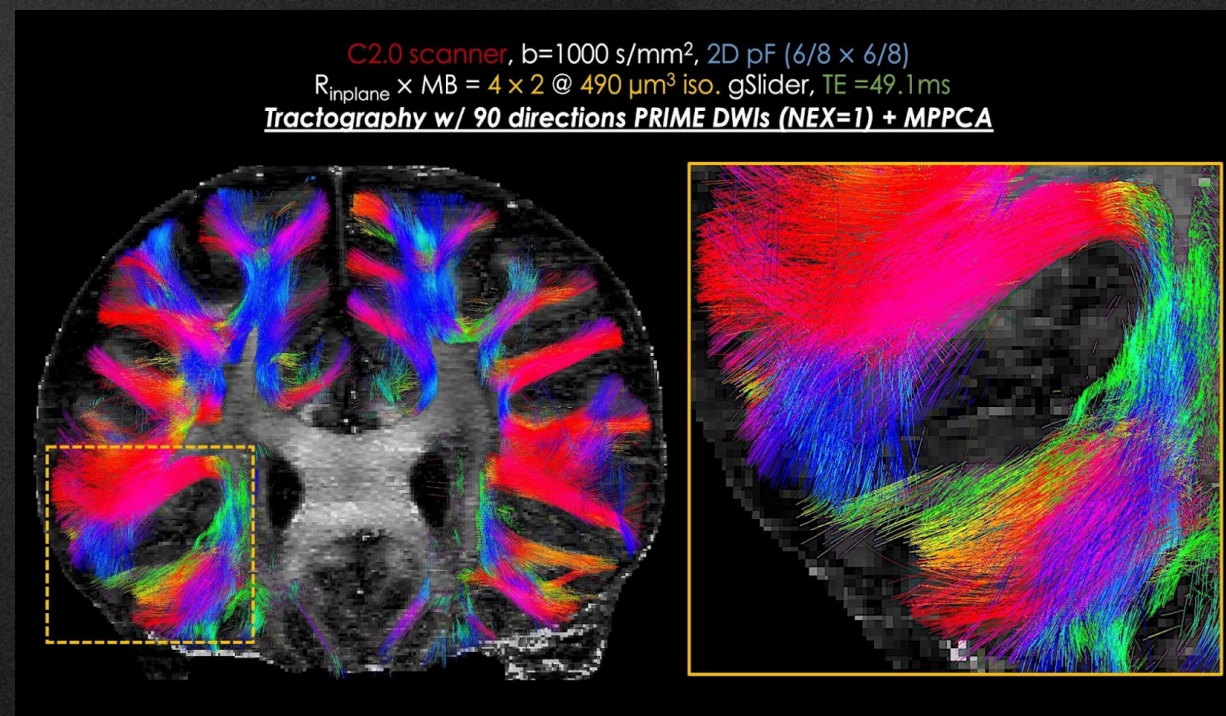
- Notes *Sequences that may become faster soon

Protocol indicated for patients with high probability / confirmed neurometabolic disorder that can tolerate/ under sedation for full detailed brain analysis.

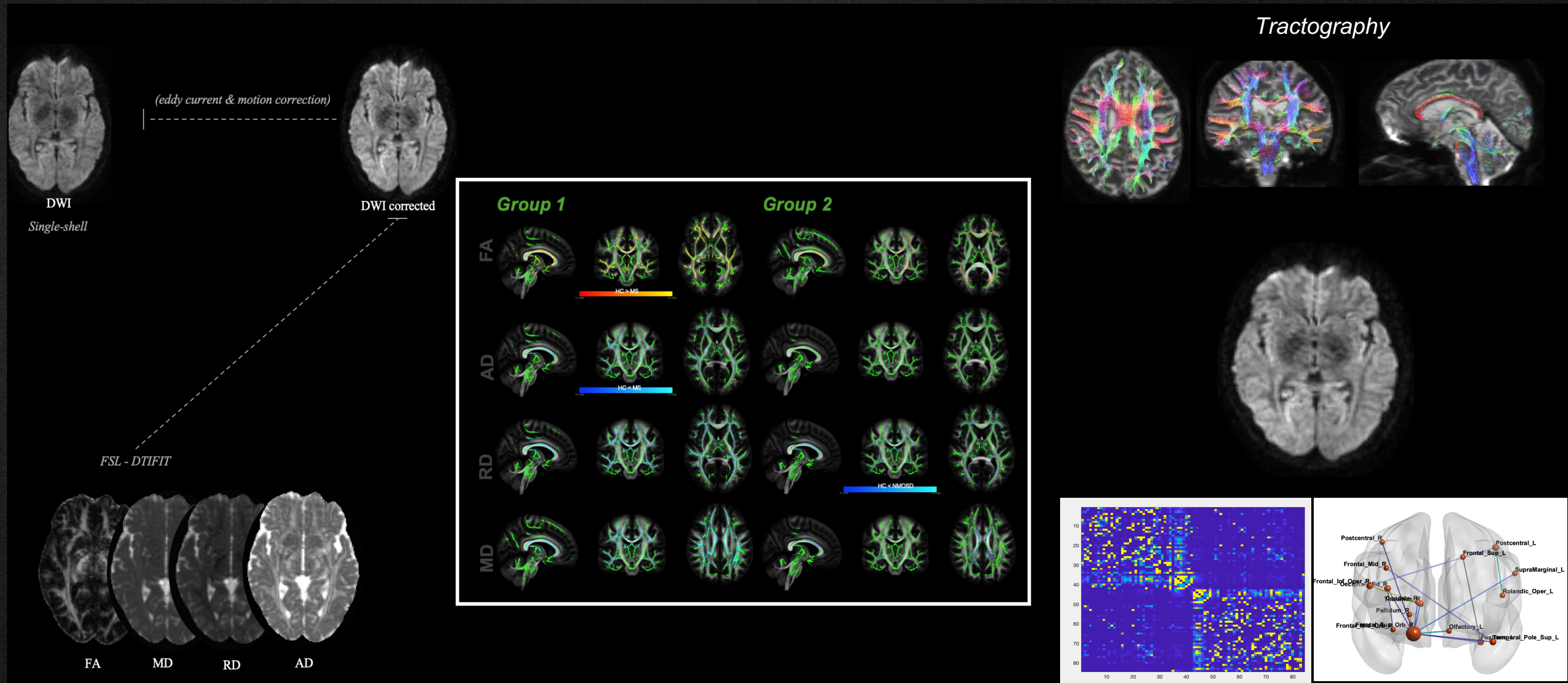
Please note that this protocol can be performed only under consent

- (needs to storage MRS / CPMG/ QSM)

Principal application for DTI is in the imaging of white matter, where the orientation, location, and anisotropy of the tracts can be measured and evaluated

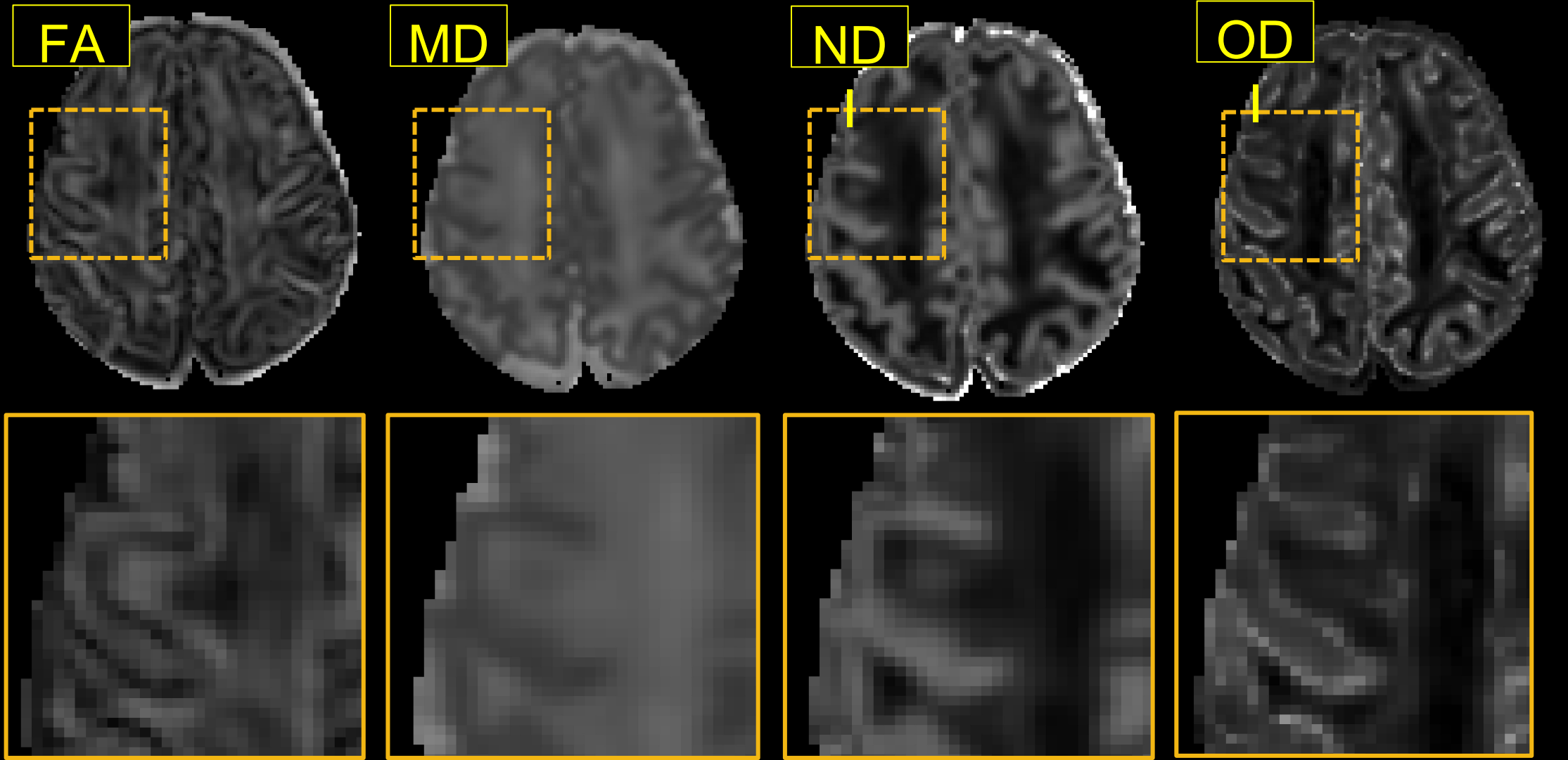


Diffusion tensor imaging



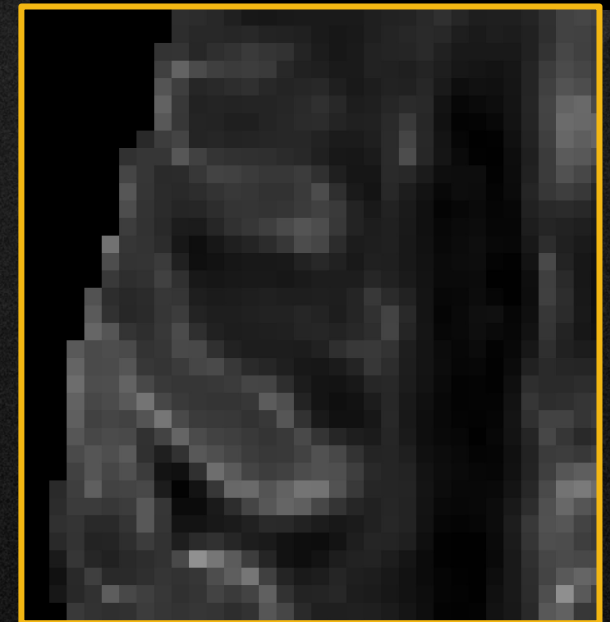
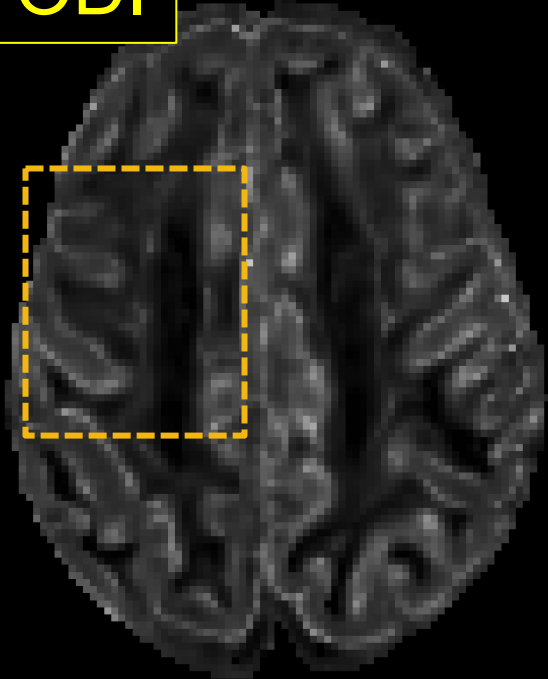
Diffusion tensor imaging - *mutishell*

European Course on
Pediatric Neuroradiology in
Latin America (ECPNR-LATAM)
3rd Cycle - Module 1

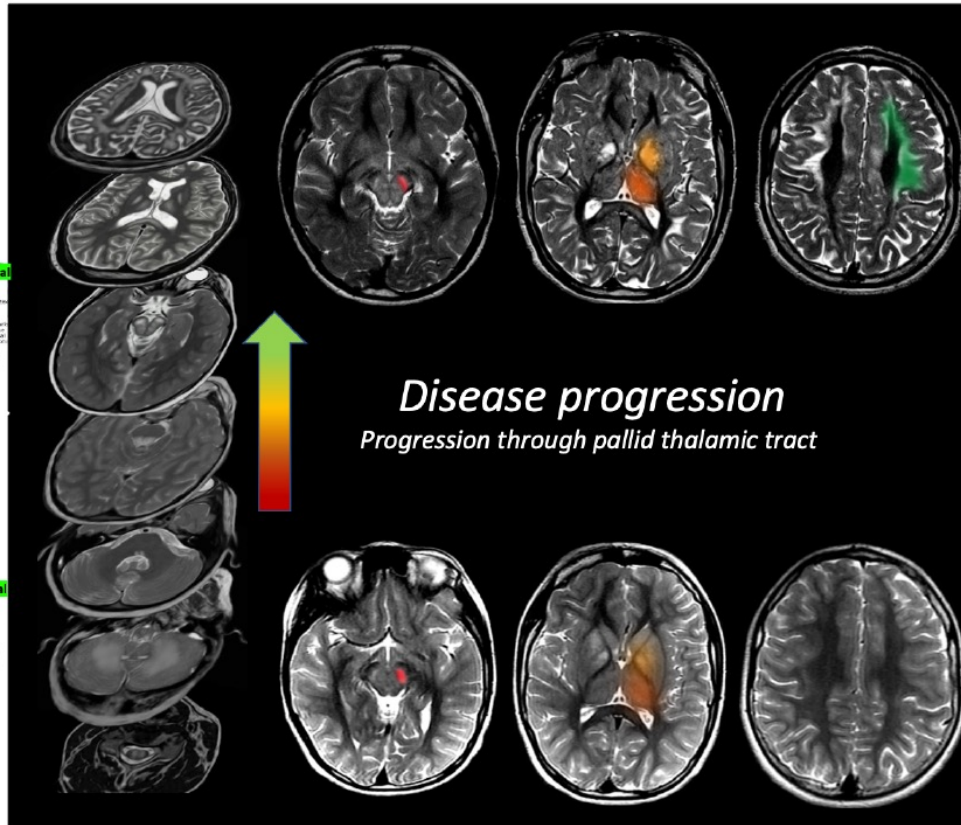
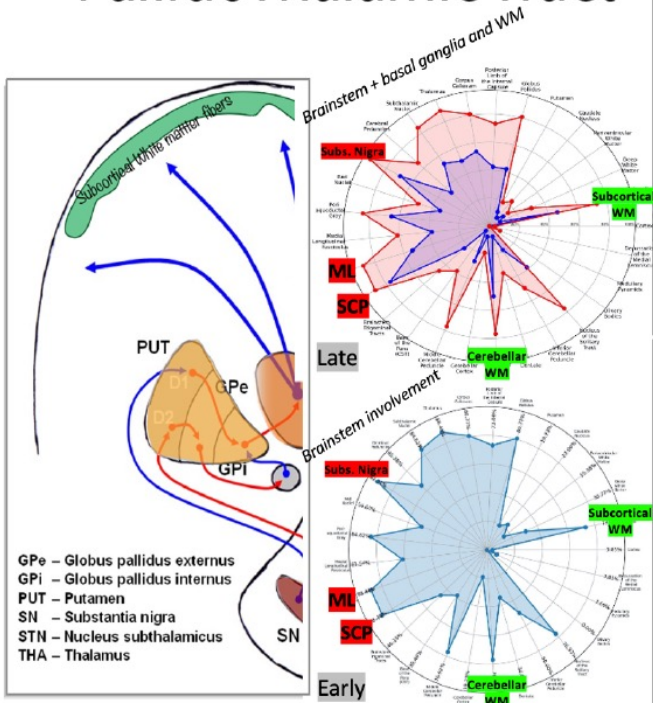


Diffusion tensor imaging – Ongoing Projects

ODI



PallidoThalamic Tract

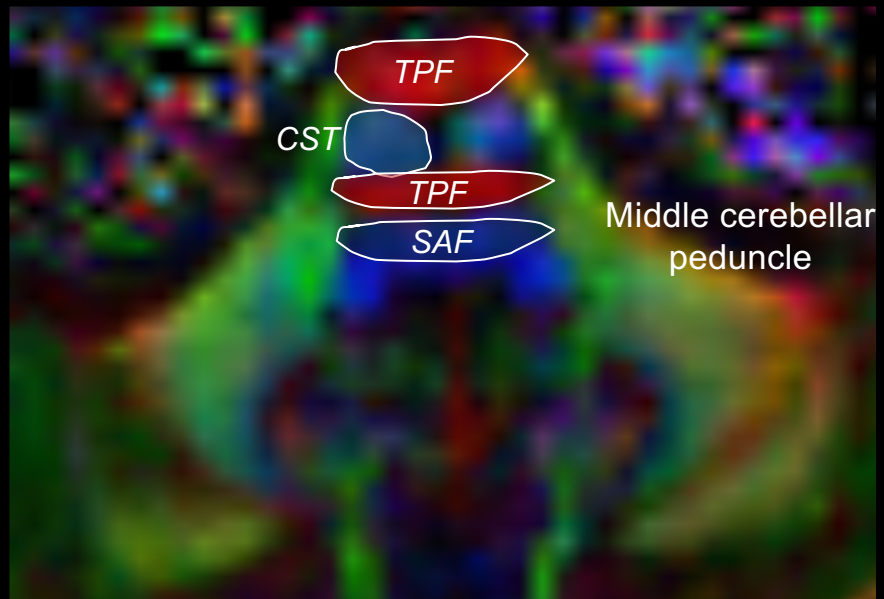
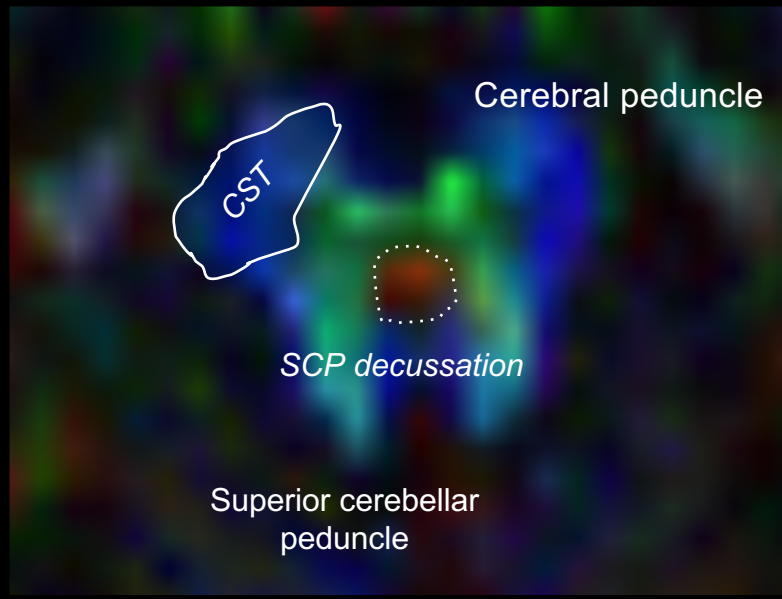
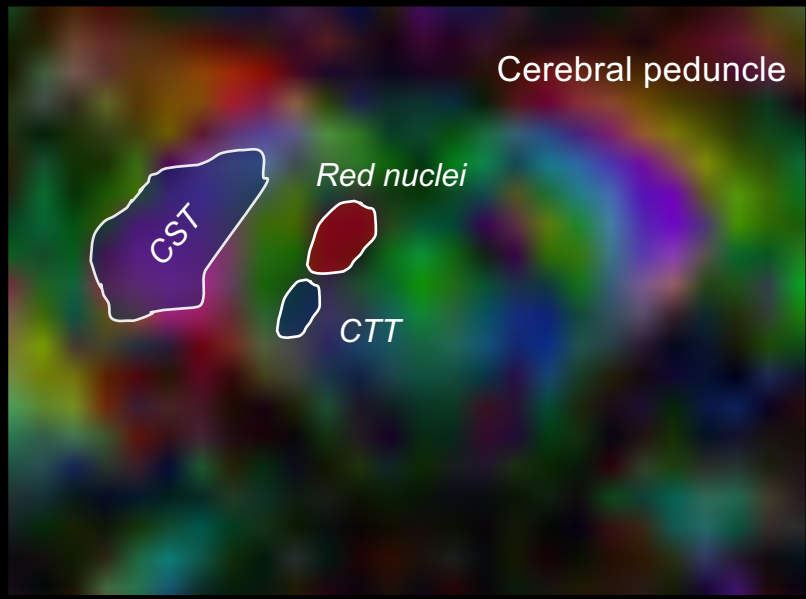
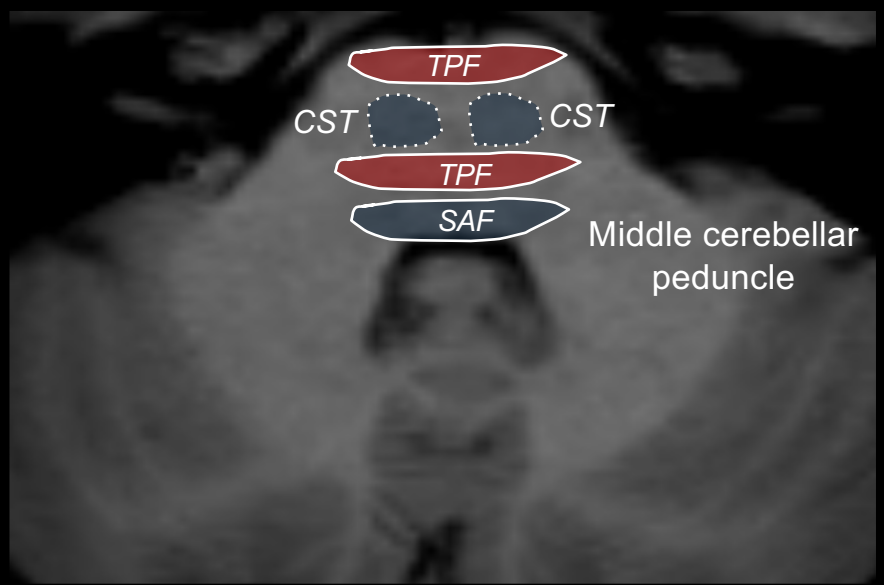
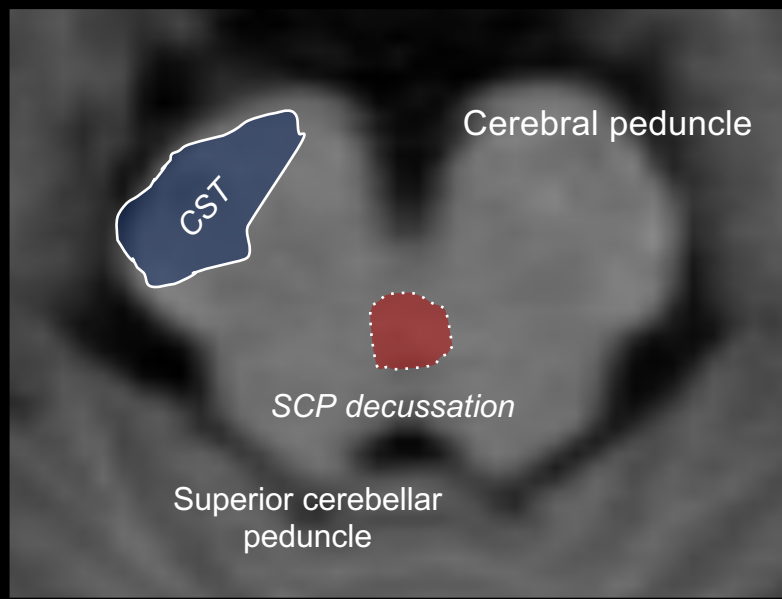
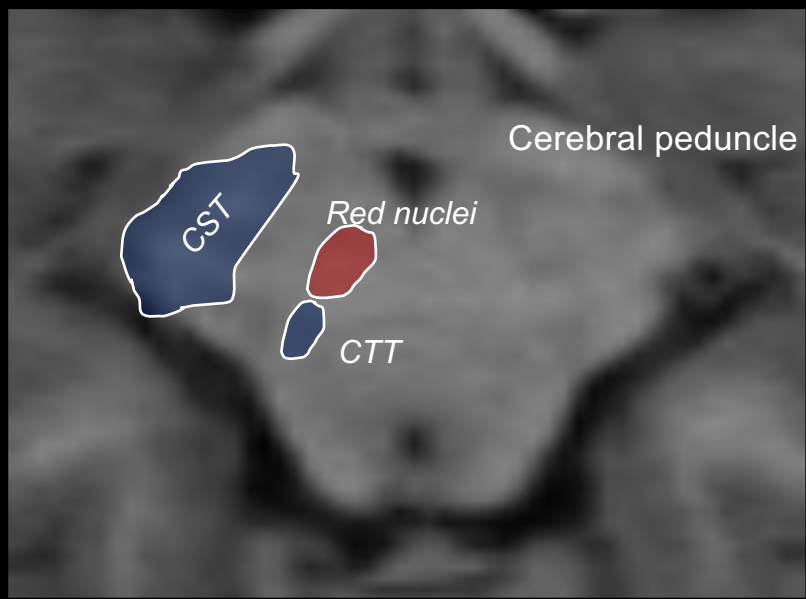


■ Early ■ Intermediate ■ Late

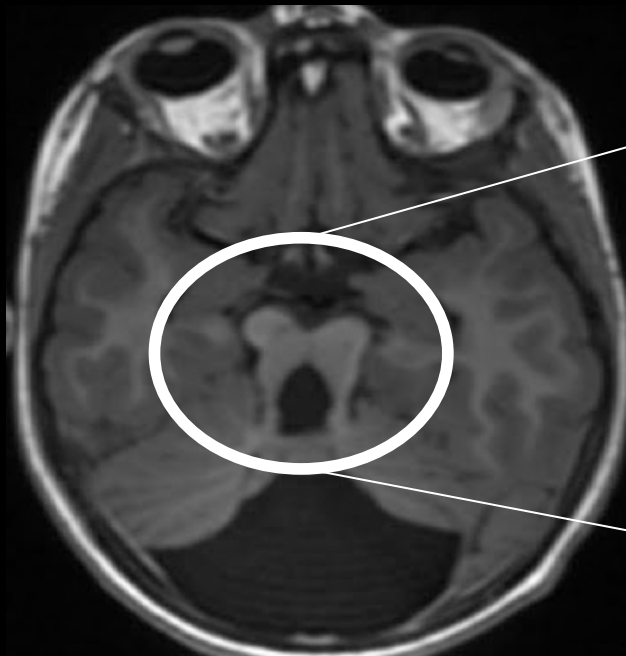
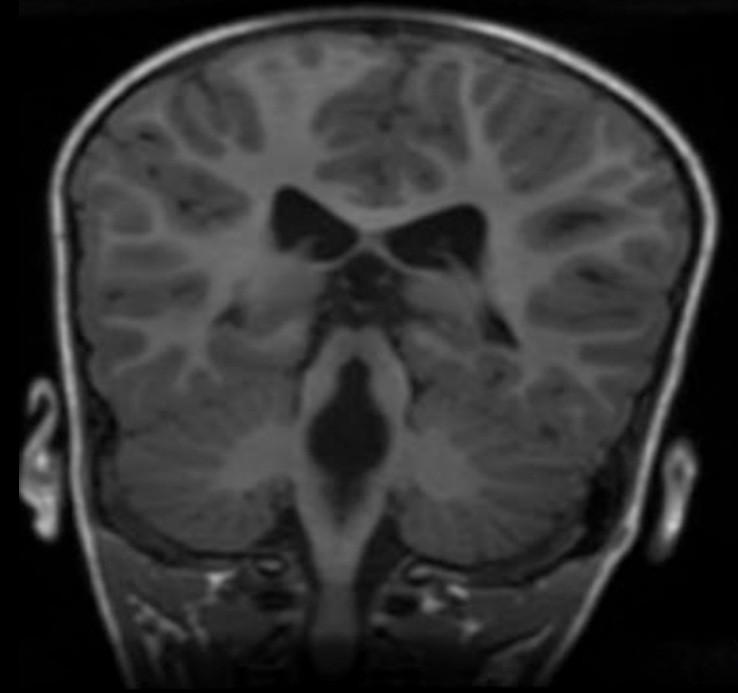
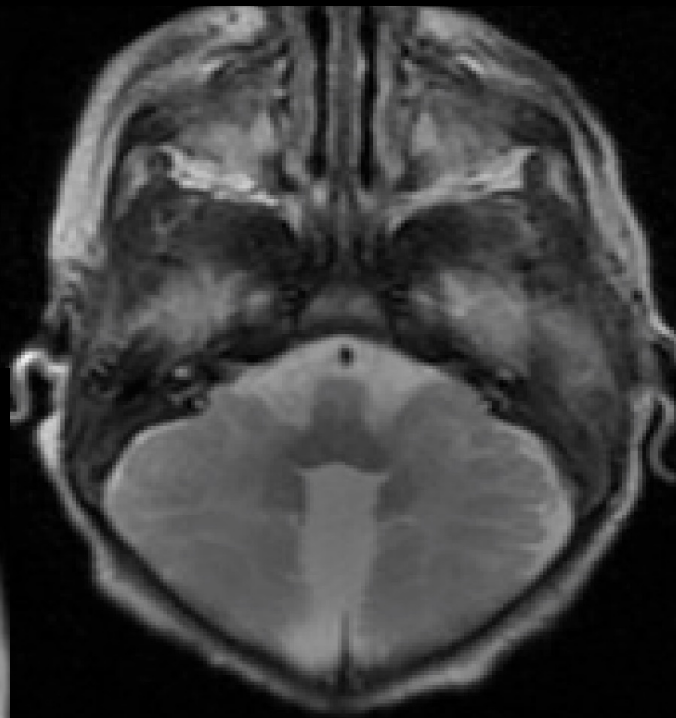
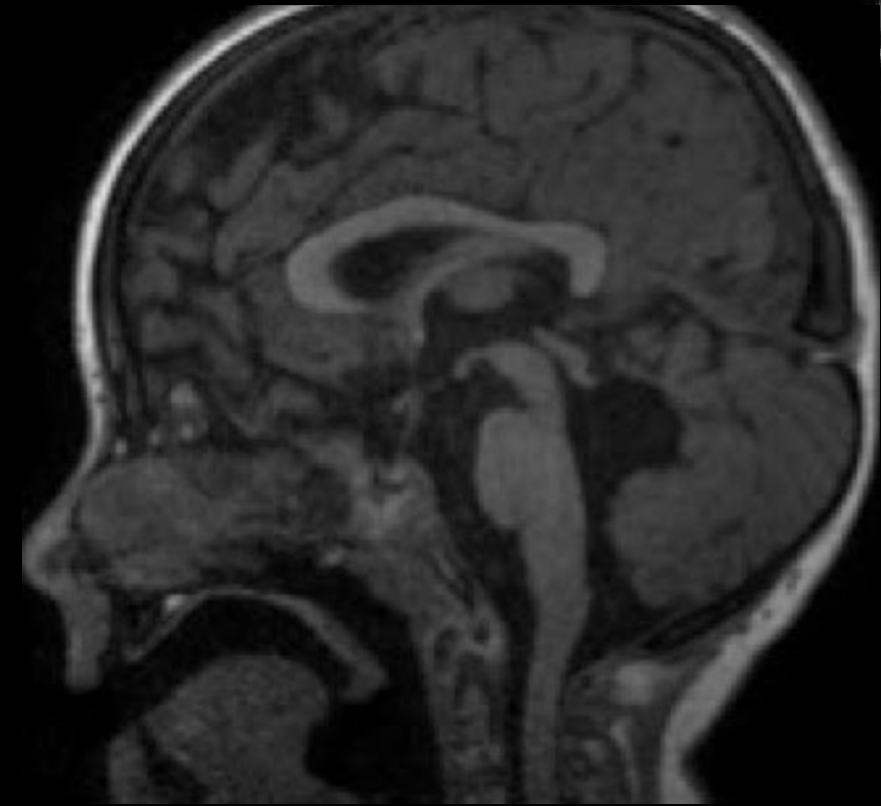
Ongoing project

CLINICAL APPLICATION

Diffusion tensor imaging – Color Map

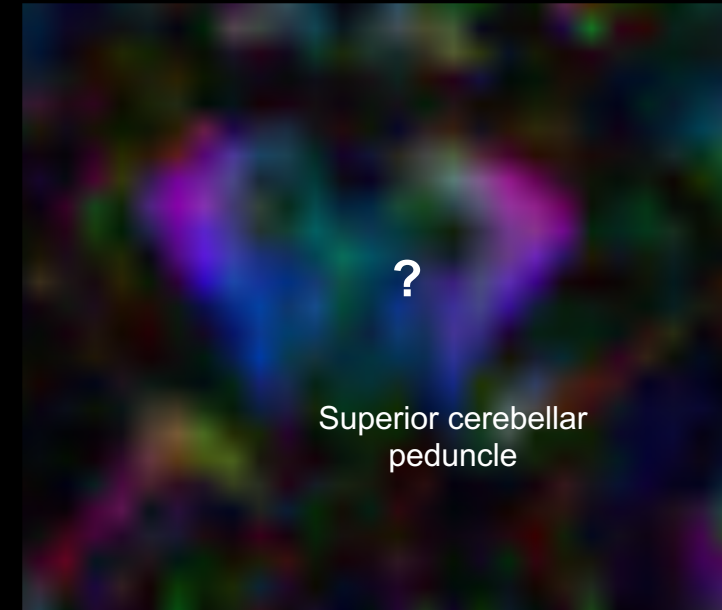
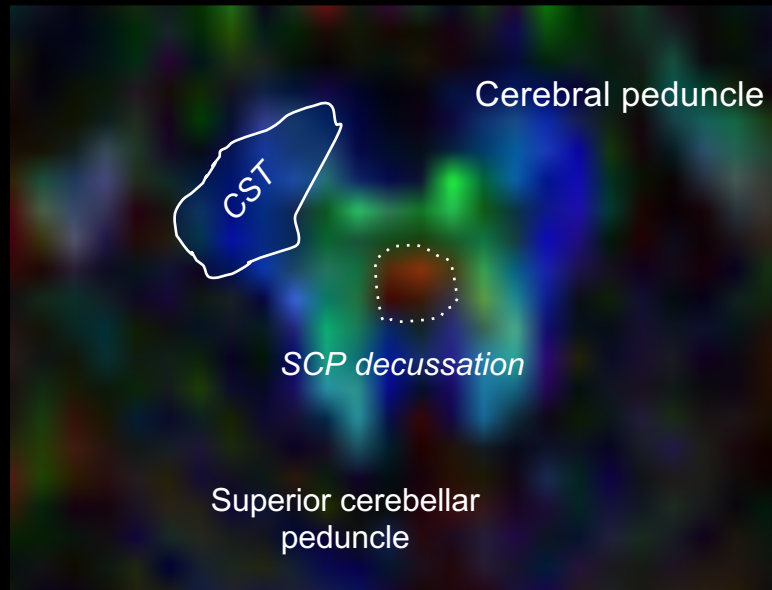
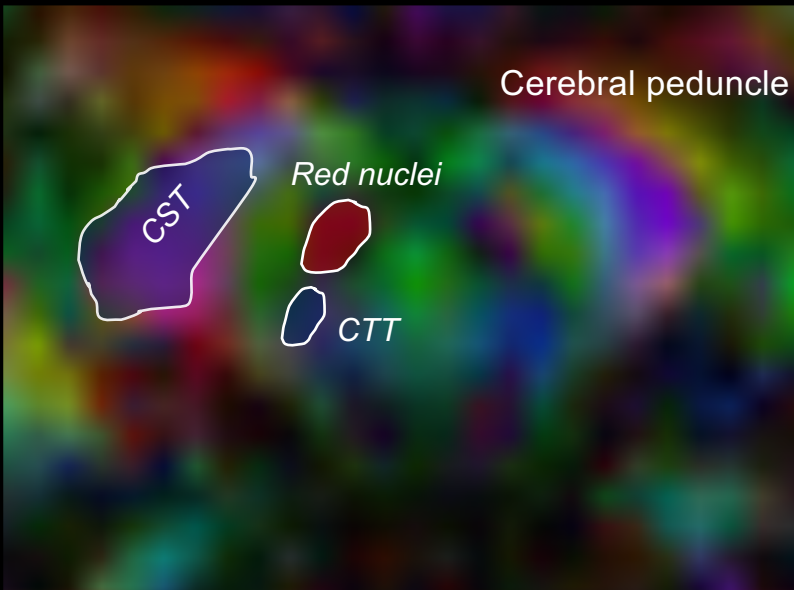
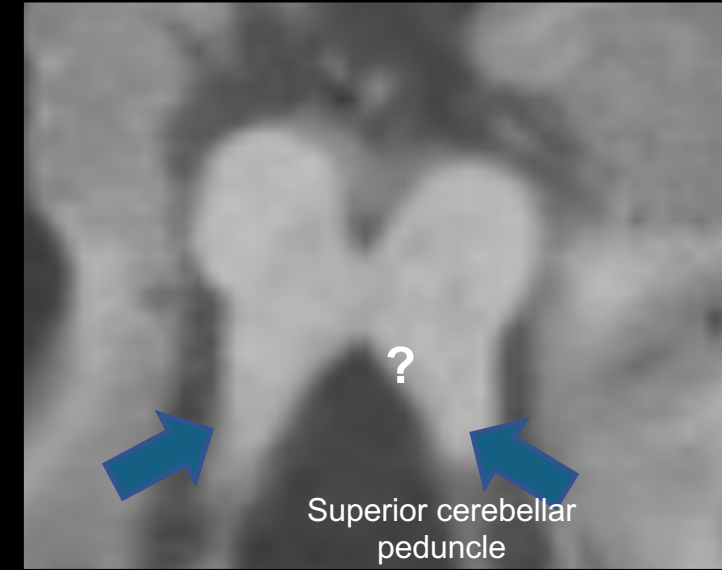
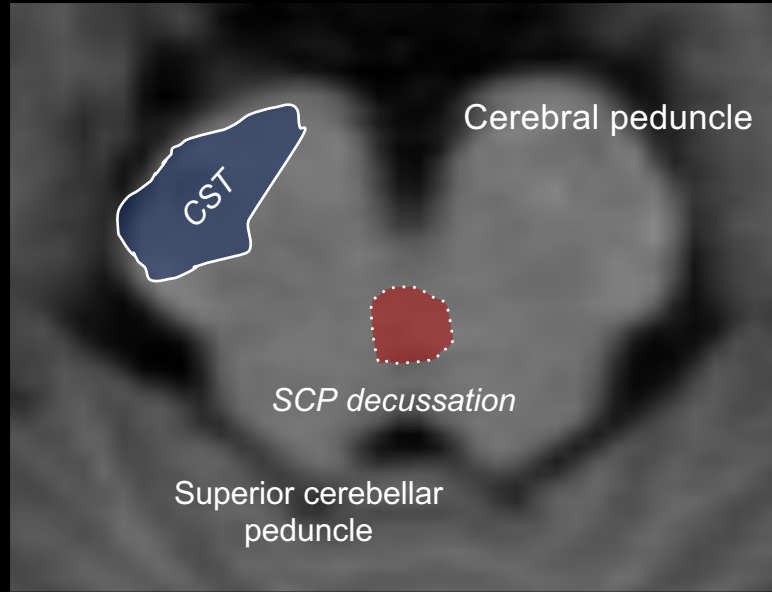
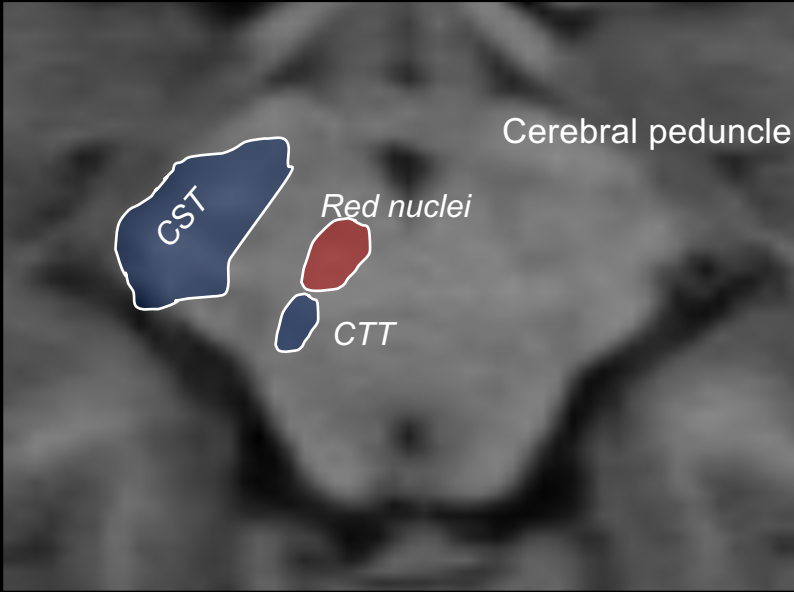


**7 YO, Oculomotor Apraxia
and hypotonia**



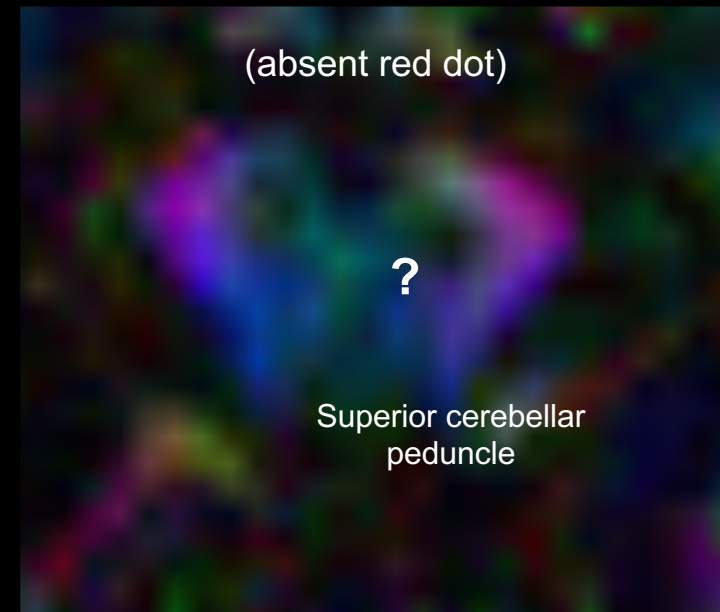
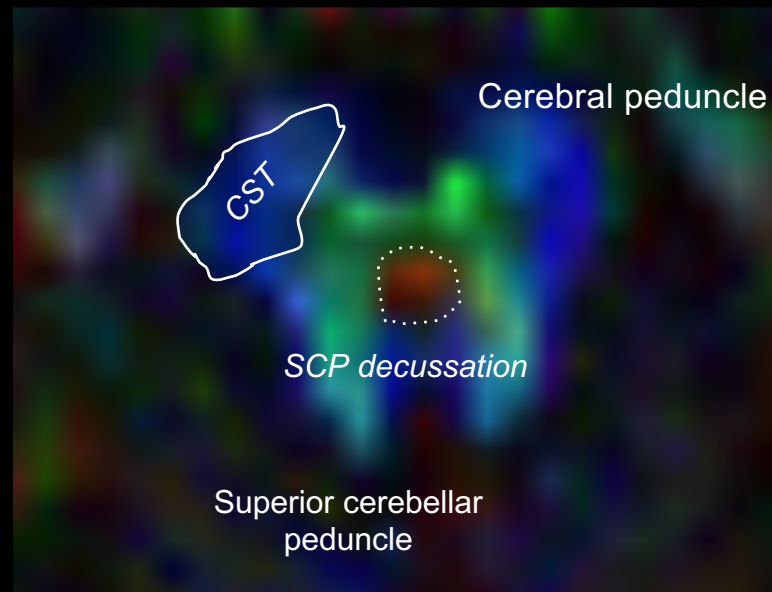
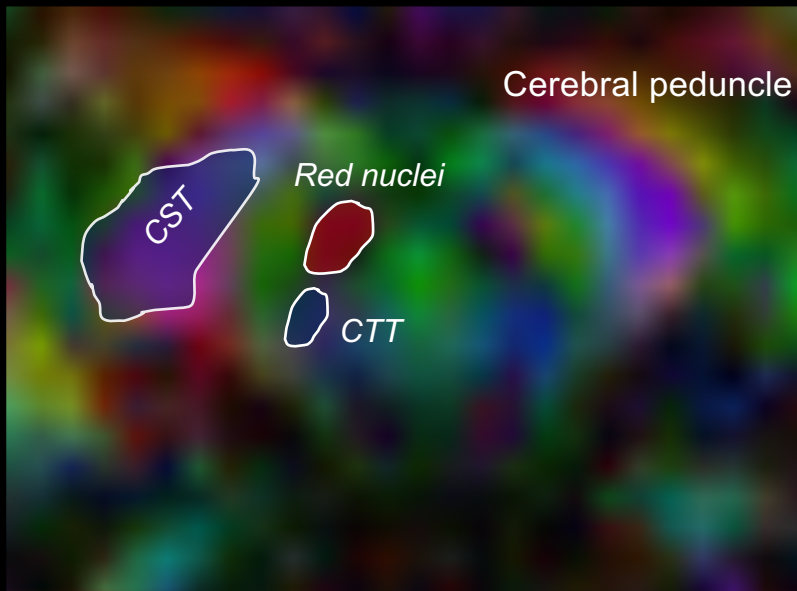
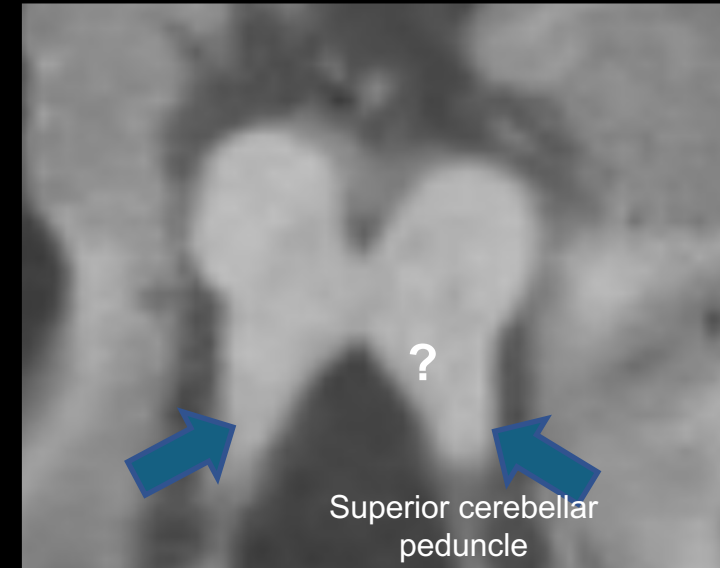
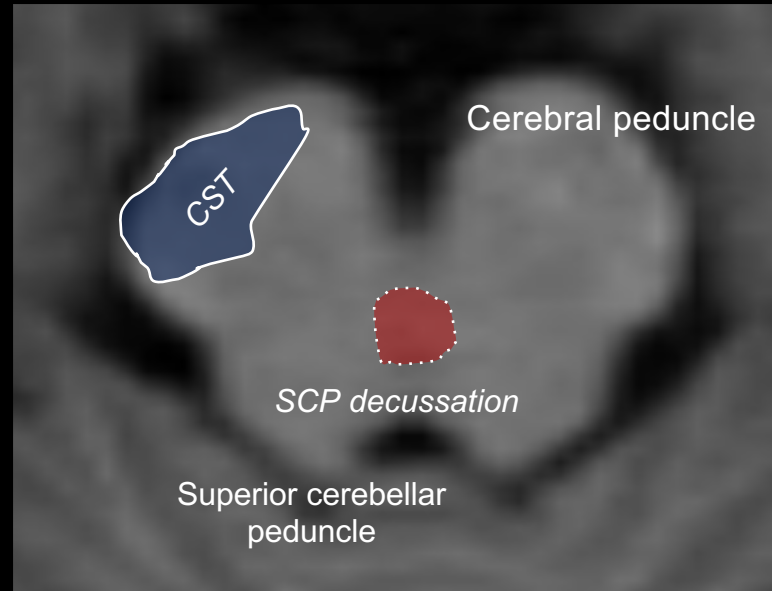
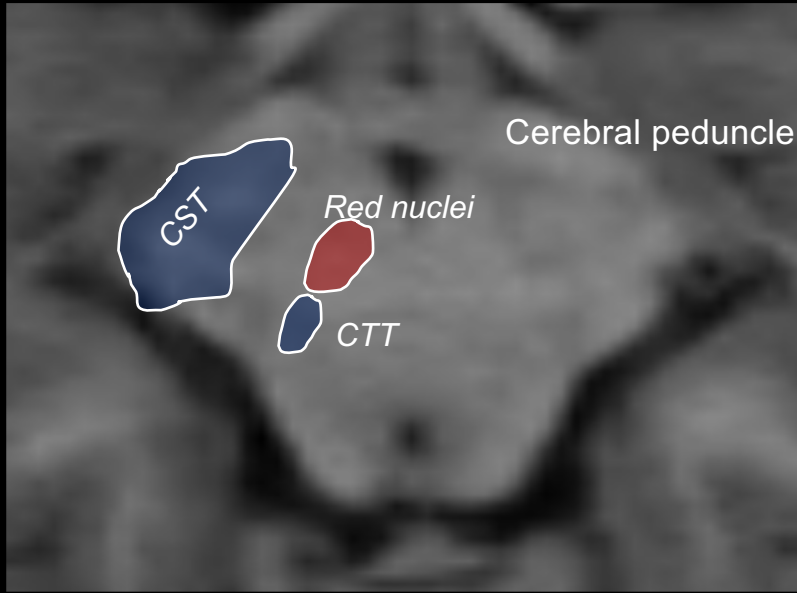
Diffusion tensor imaging- Color Maps

DIAGNOSIS ?

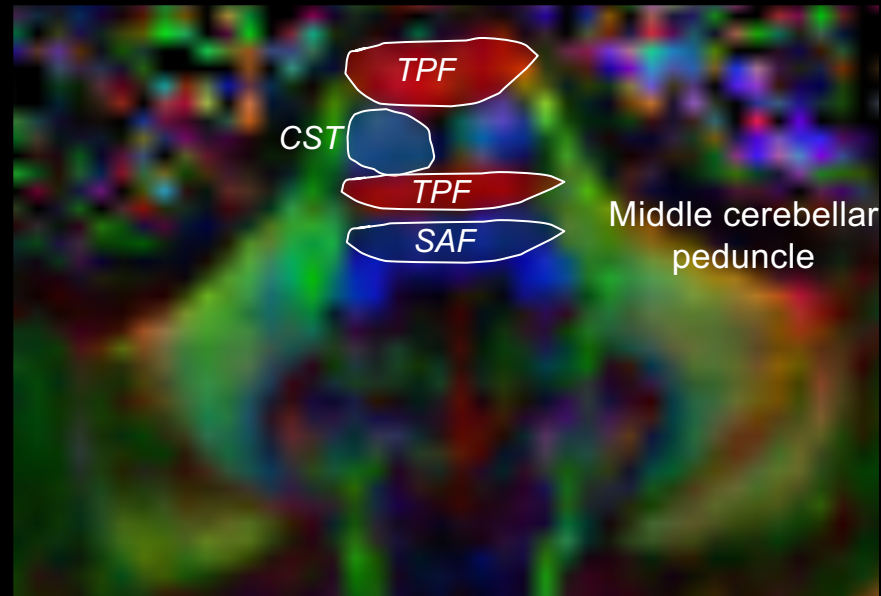
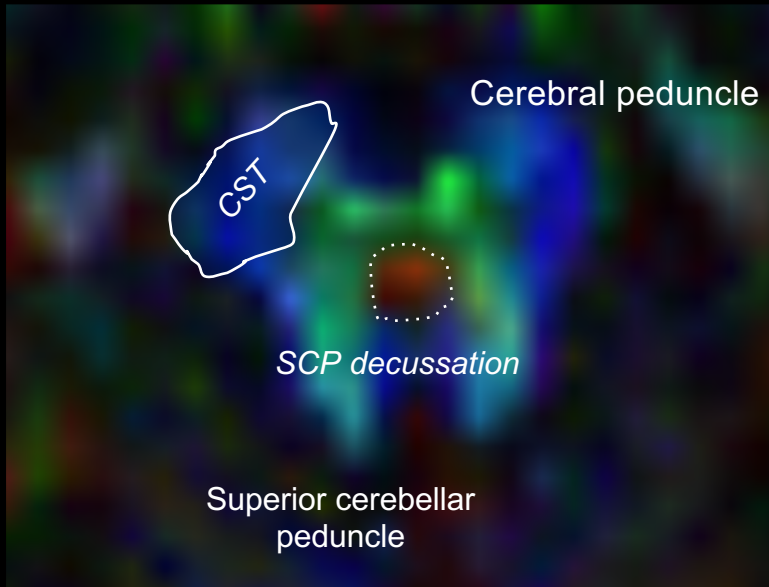
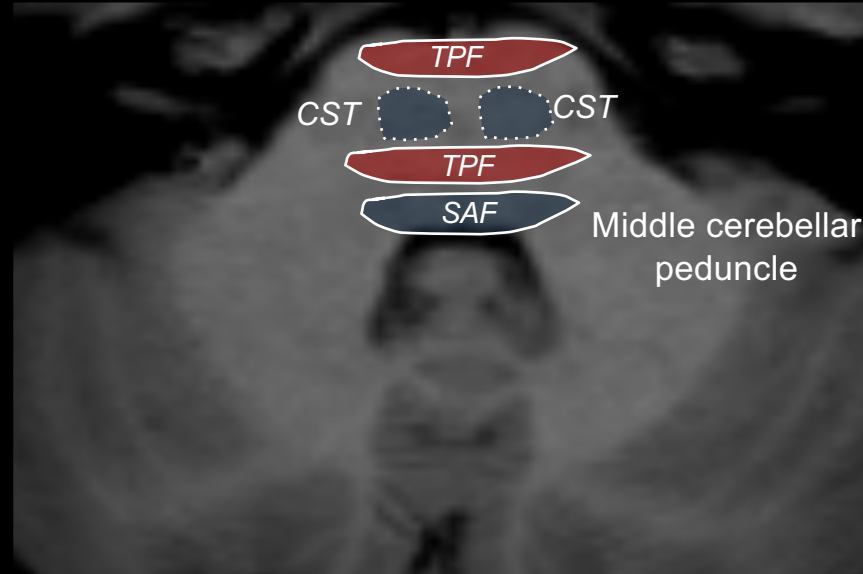
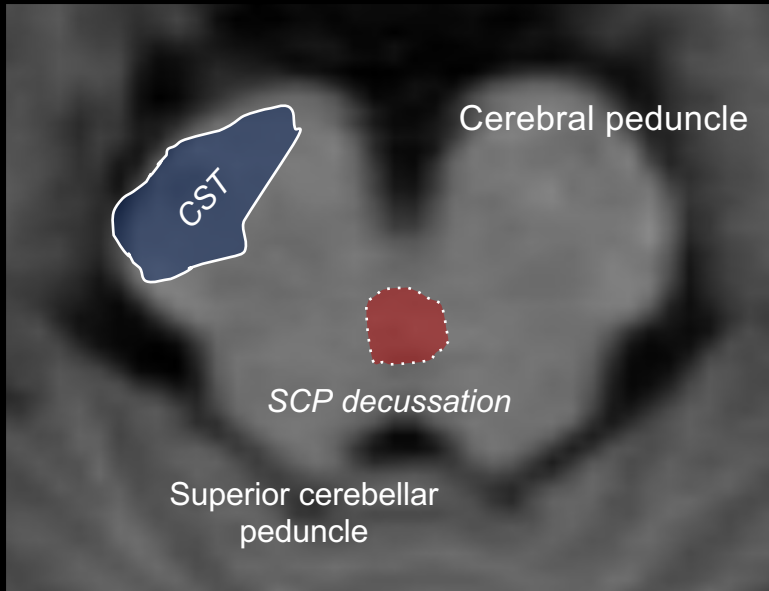


Diffusion tensor imaging- Color Maps

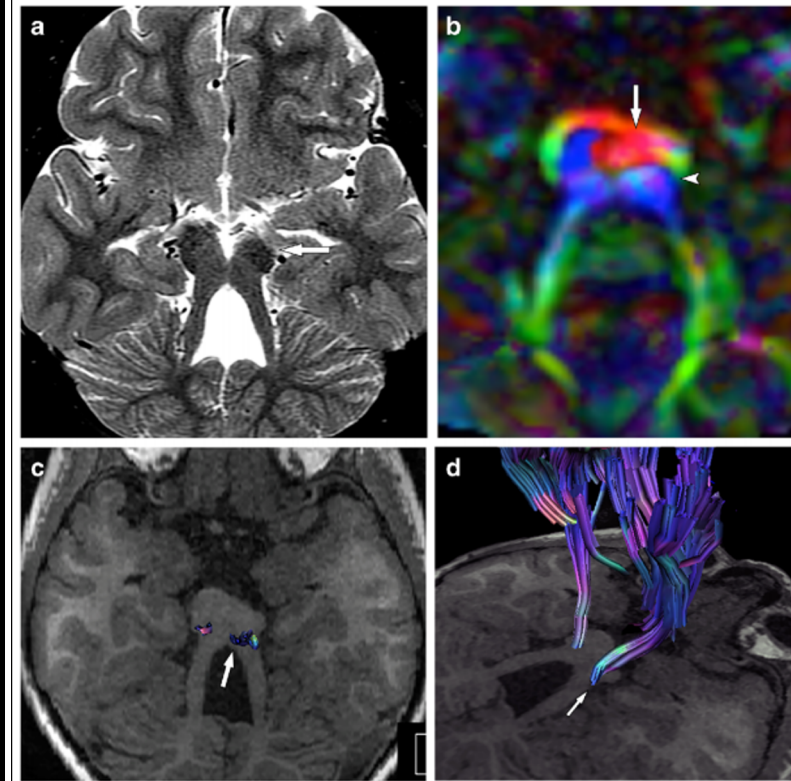
Joubert Syndrome and Related Disorders



Diffusion tensor imaging- Color Maps



Joubert Syndrome and Related Disorders CST displacement



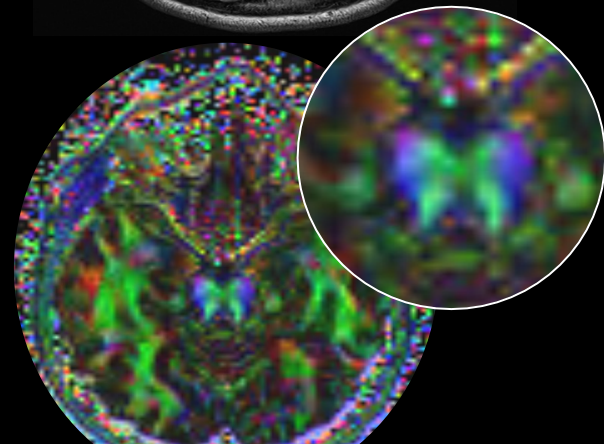
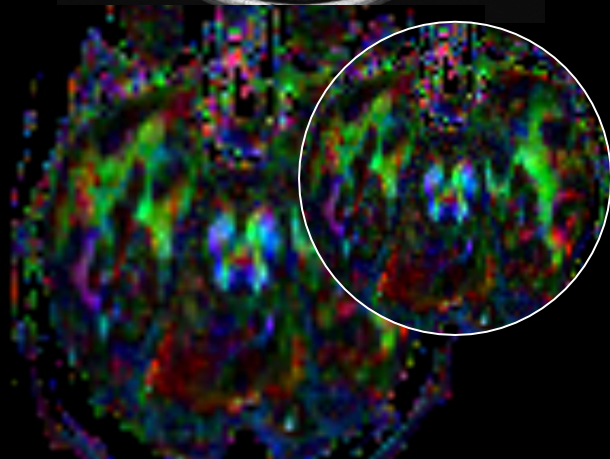
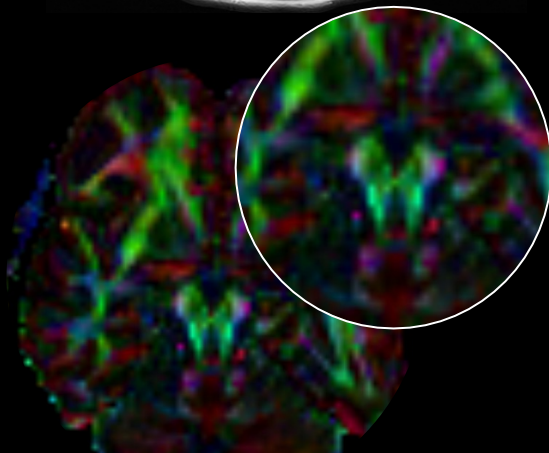
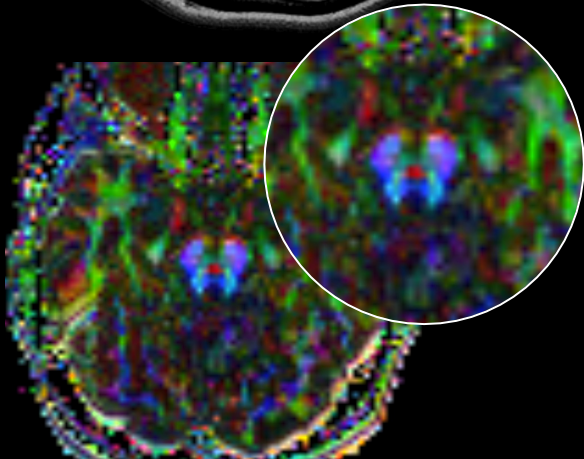
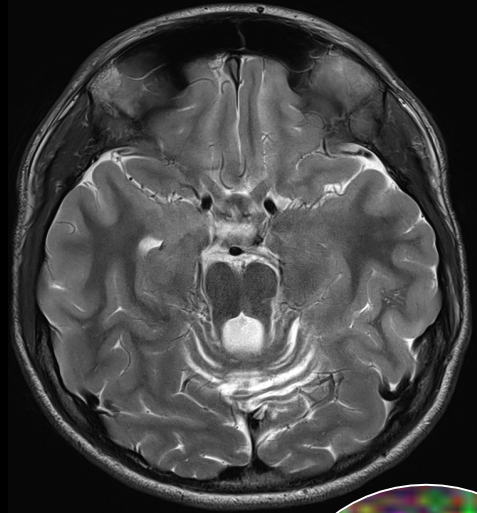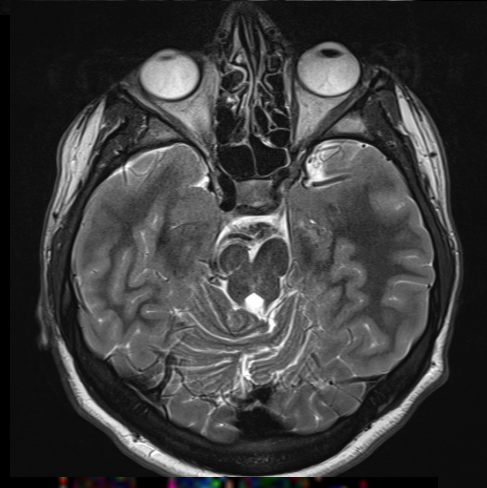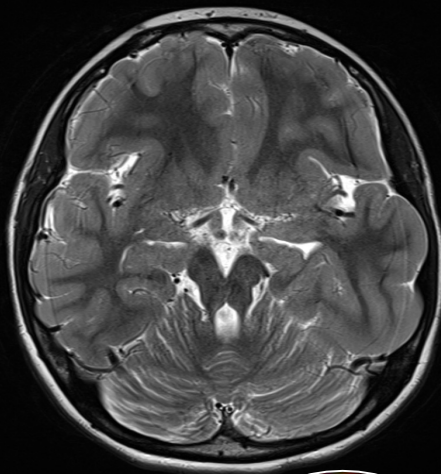
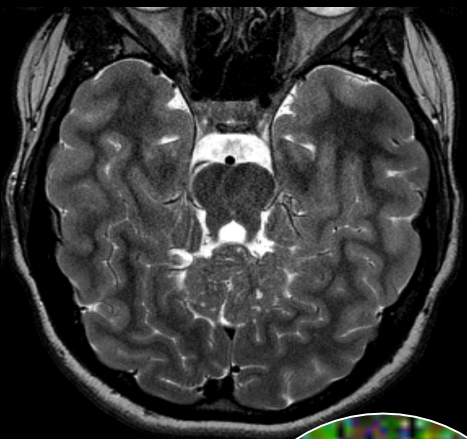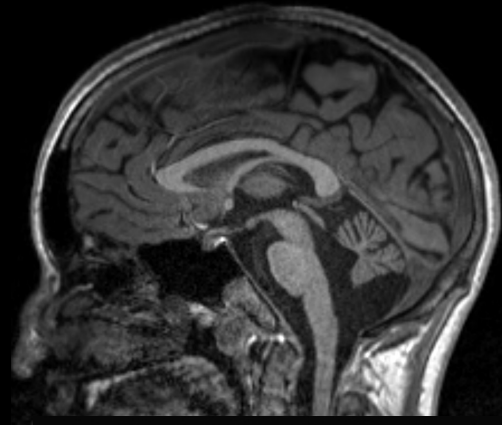
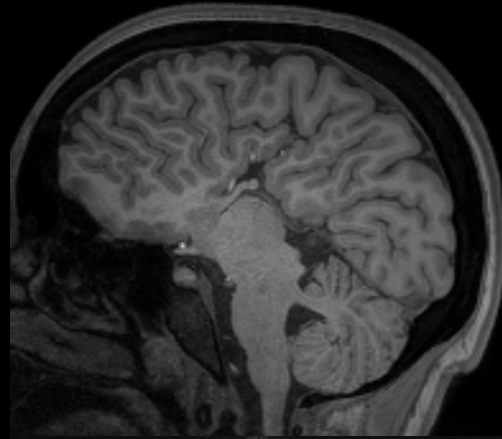
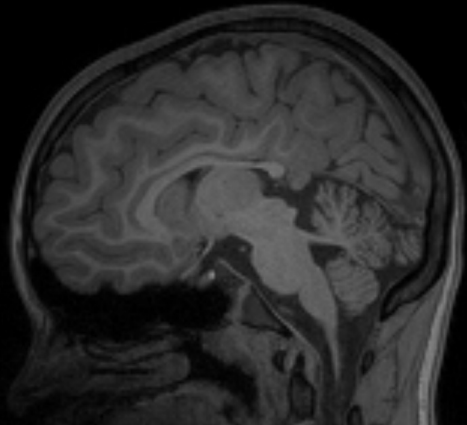
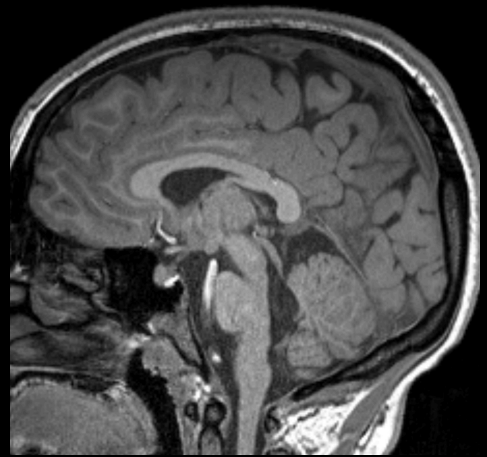
Alves CA, et al. Decaying molar tooth sign in Joubert syndrome and related disorders is correlated to a displacement of the corticospinal tract. *Neuroradiology* 2017.

LAMA1

TUBB3

TUBB3

KIF21A



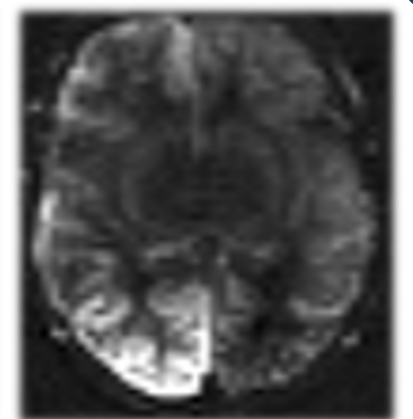
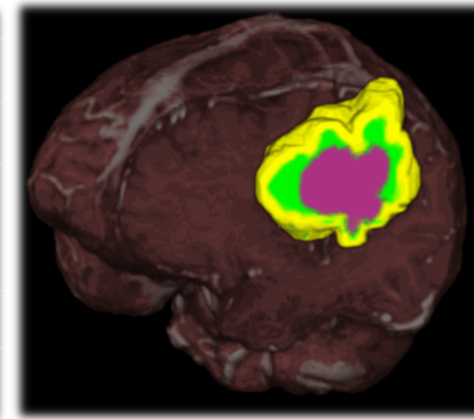
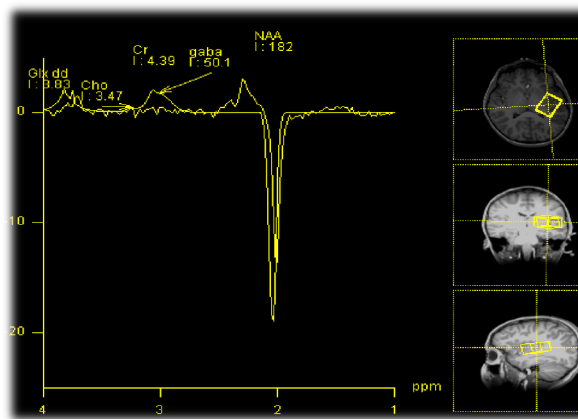
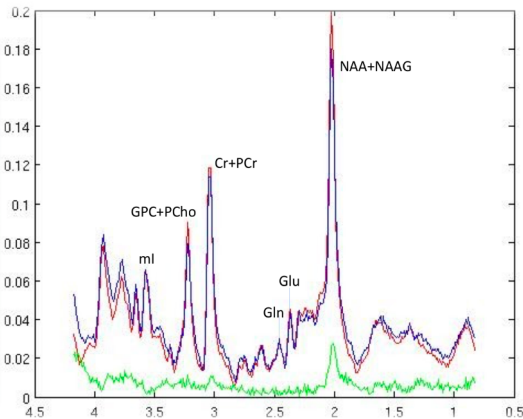
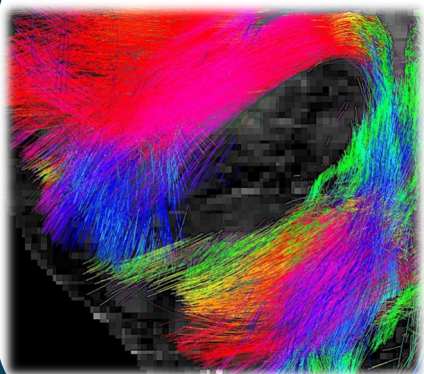
MRI from Microstructure to Function: *DTI, Perfusion, ASL, MRS*

European Course on
Pediatric Neuroradiology in
Latin America (ECPNR-LATAM)
3rd Cycle - Module 1

DTI

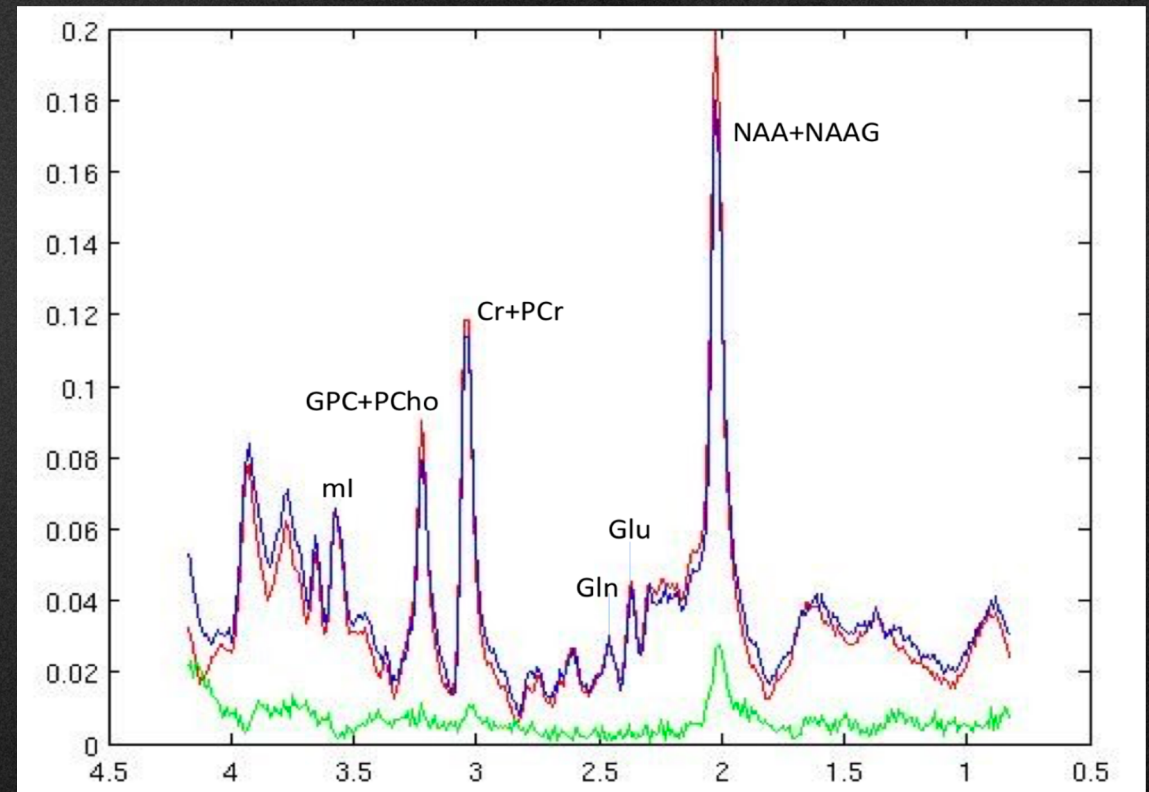
MRS

ASL



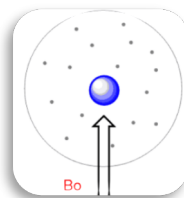
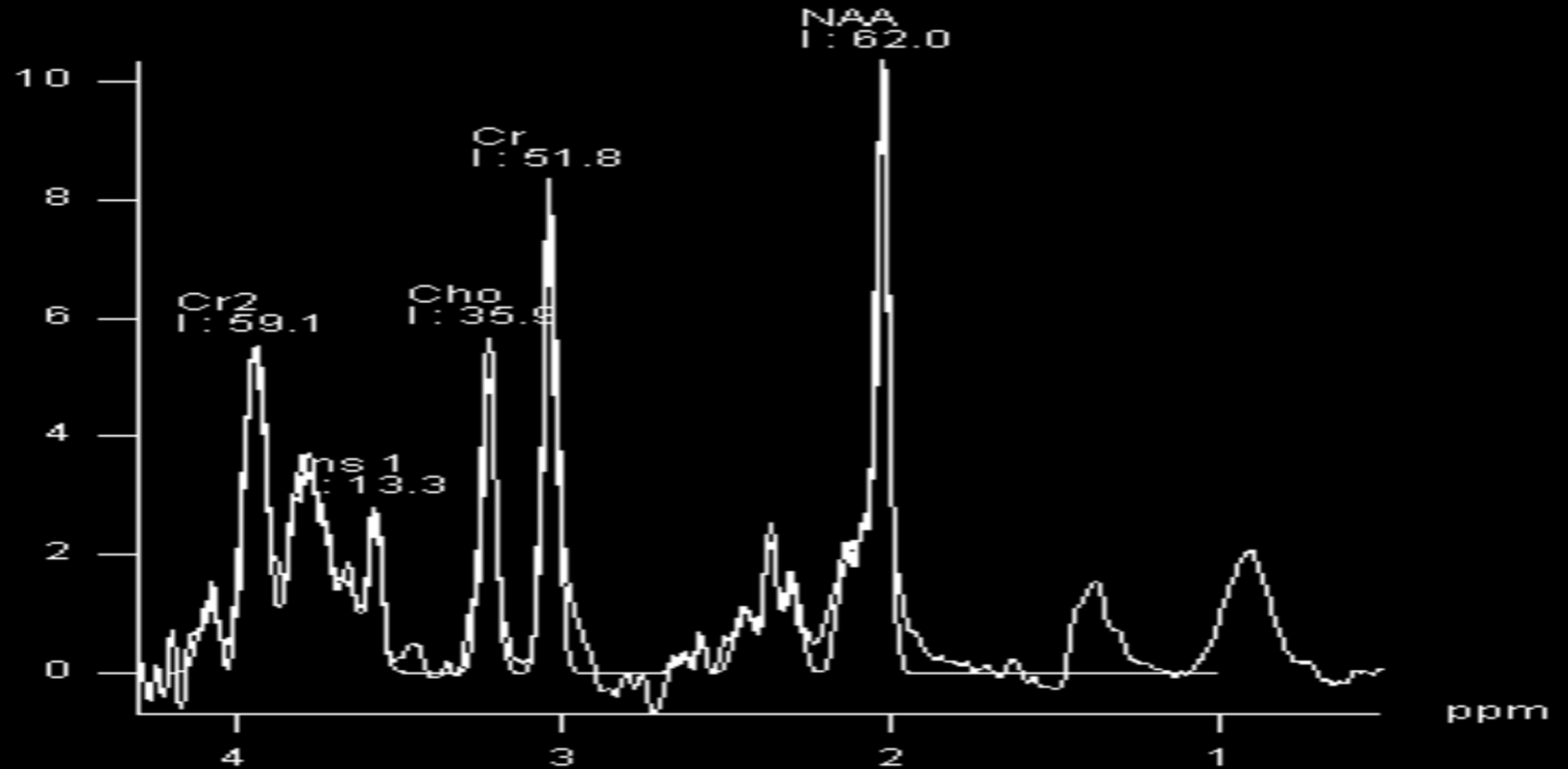
1H MR Spectroscopy

- **Introduction**
 - **Physics: Basic information needed**
- **Protocol**
 - **Where, When and Why?**
- **Cases**
 - **Crucial request**
 - **Useful request**



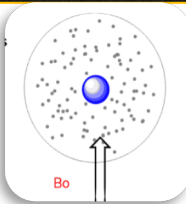
1H MR Spectroscopy

- Introduction
 - Physics: Basic info
- Protocol
 - Where, When and V
- Cases
 - Crucial request
 - Useful request



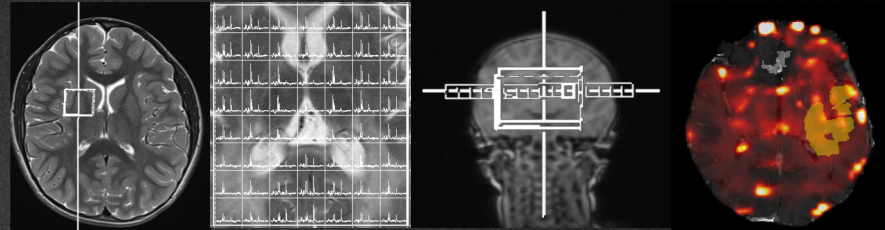
Signal from nuclei with weaker shielding- along the left

Signals from nuclei with stronger shielding – along the right



1H-MRS standardized conditions

1. The voxel of interest (VOI) must be placed in the least inhomogeneous area of gray or white matter



2. High field strength improves signal-to-noise ratio

3. Optimal shimming methods improve spectral resolution

4. **Time of Echo (TE)** conditions the number of measurable metabolites:

intermediate TE (144 ms) / long TE (272 ms) vs short **TE (10-50 ms)**.

Be careful with lactate inversion 3.0 T

False negative lactate peaks – suggestions: increase TE or
adiabatic excitation pulses

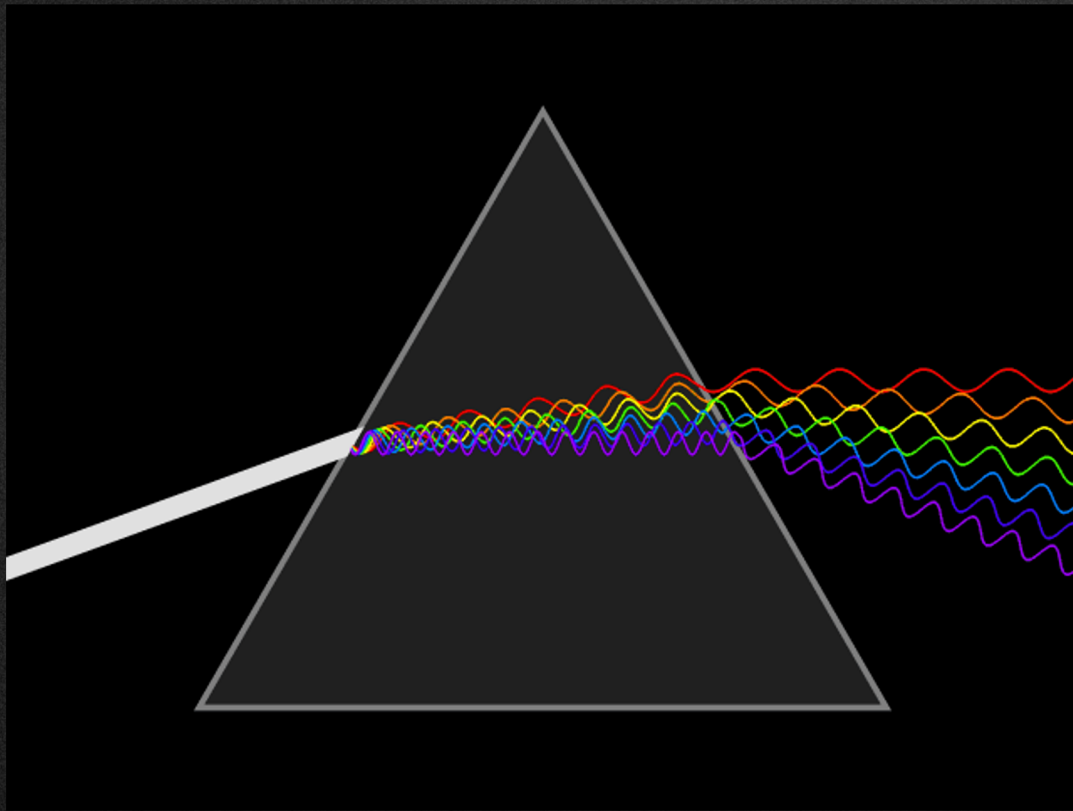
Brain Spectroscopy

European Course on
Pediatric Neuroradiology in
Latin America (ECPNR-LATAM)
3rd Cycle - Module 1

- Separate order
- **5-7 minutes single voxel**
- **10 minutes multivoxel and volumetric (CSI) / Whole Brain Spectroscopy**
- Additional/ complementary report separate from the MRI study

Concept and Terminology

European Course on
Pediatric Neuroradiology in
Latin America (ECPNR-LATAM)
3rd Cycle - Module 1

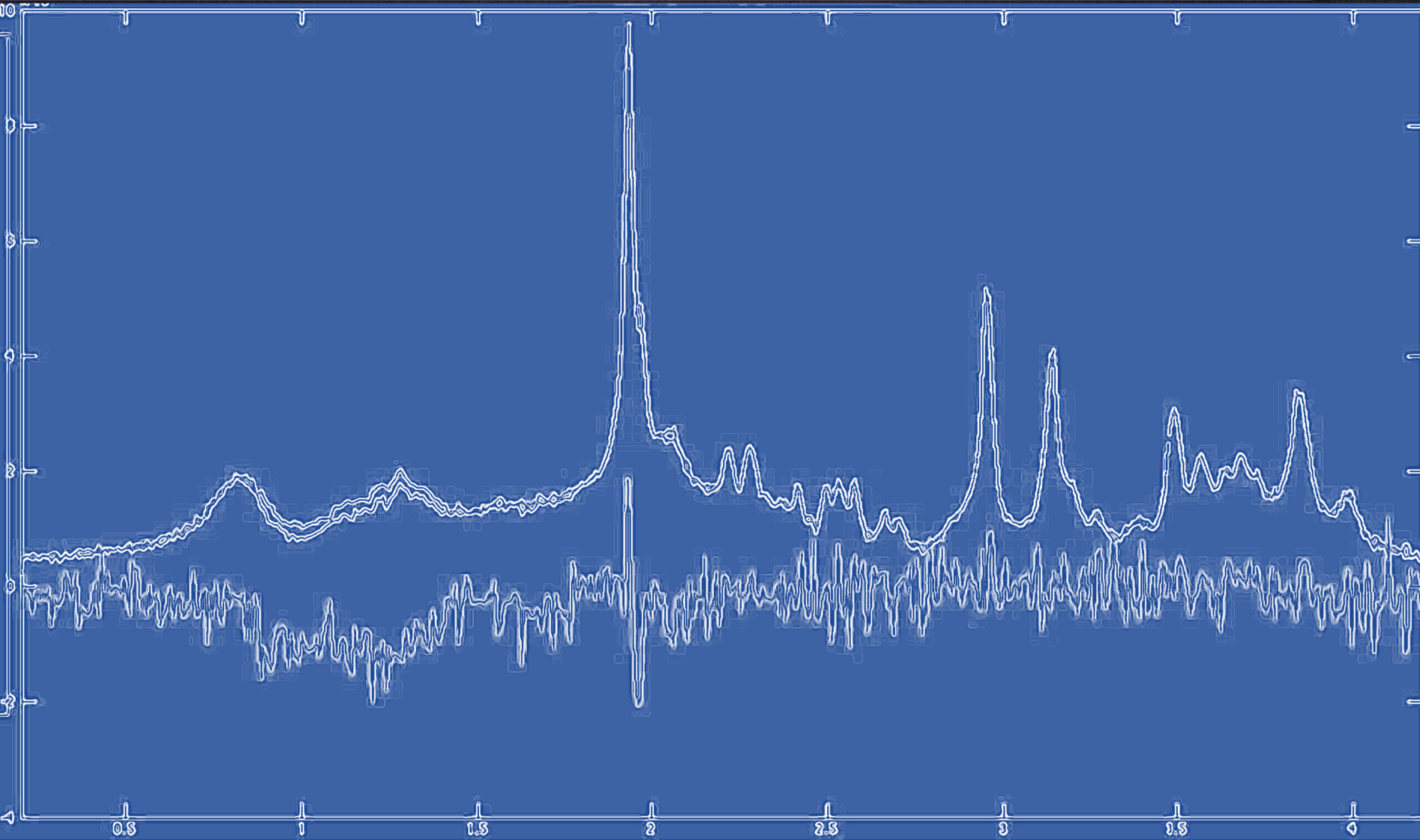


BEFORE

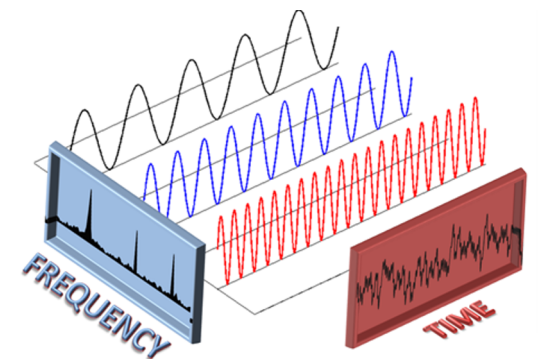

AFTER

Concept and Terminology

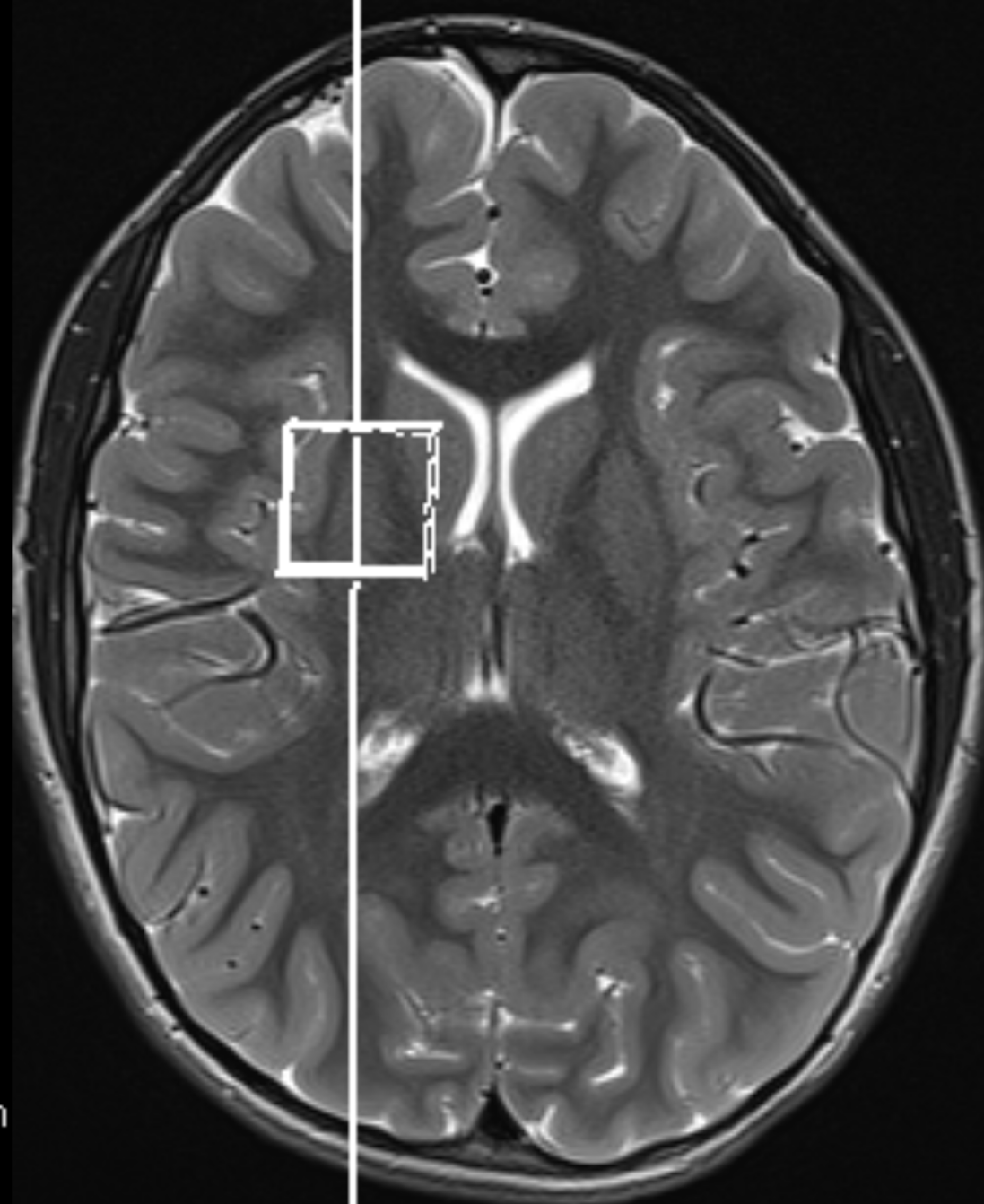
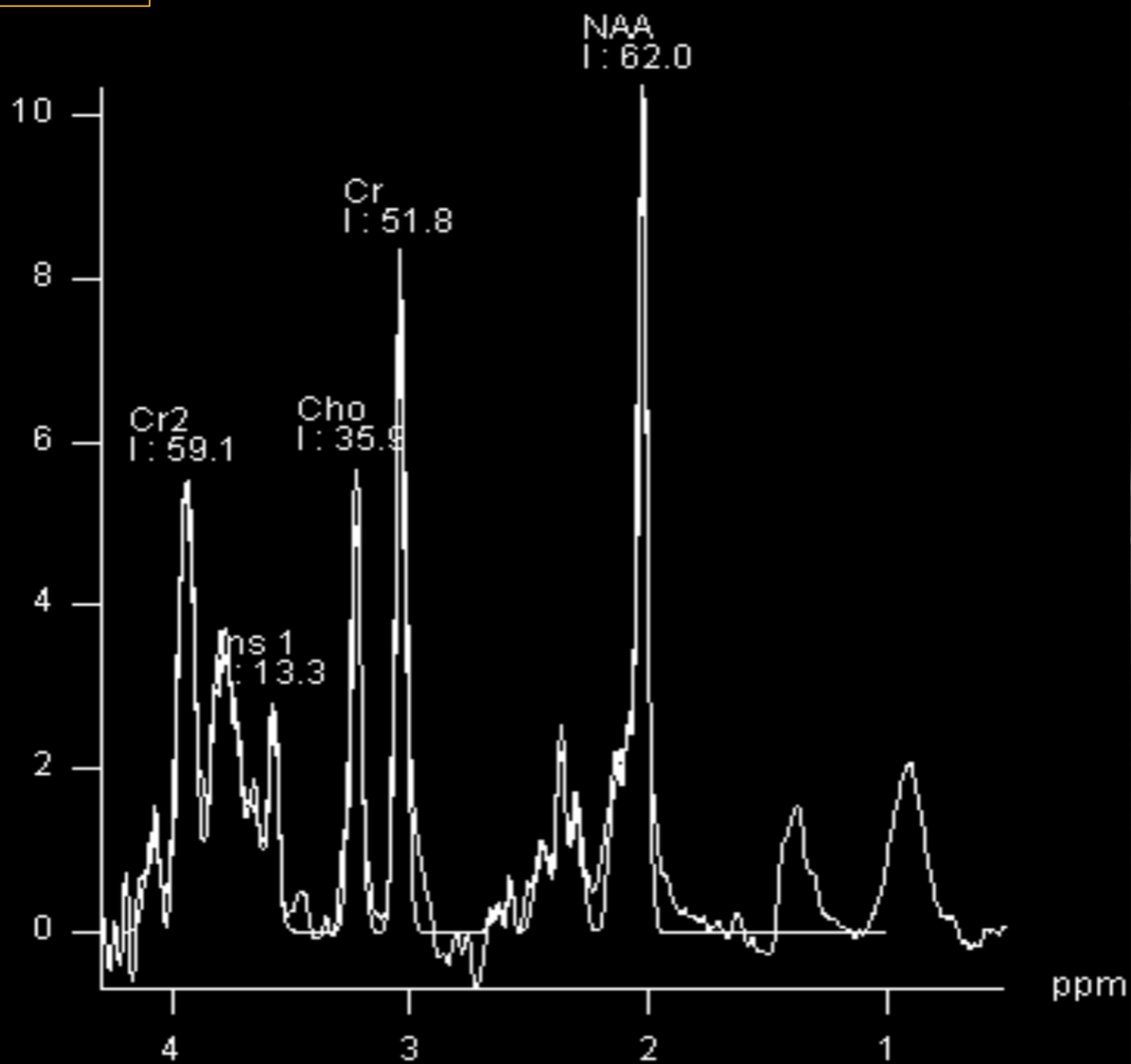
European Course on
Pediatric Neuroradiology in
Latin America (ECPNR-LATAM)
3rd Cycle - Module 1



Spectrum
Fourier Transform




TE:35 ms

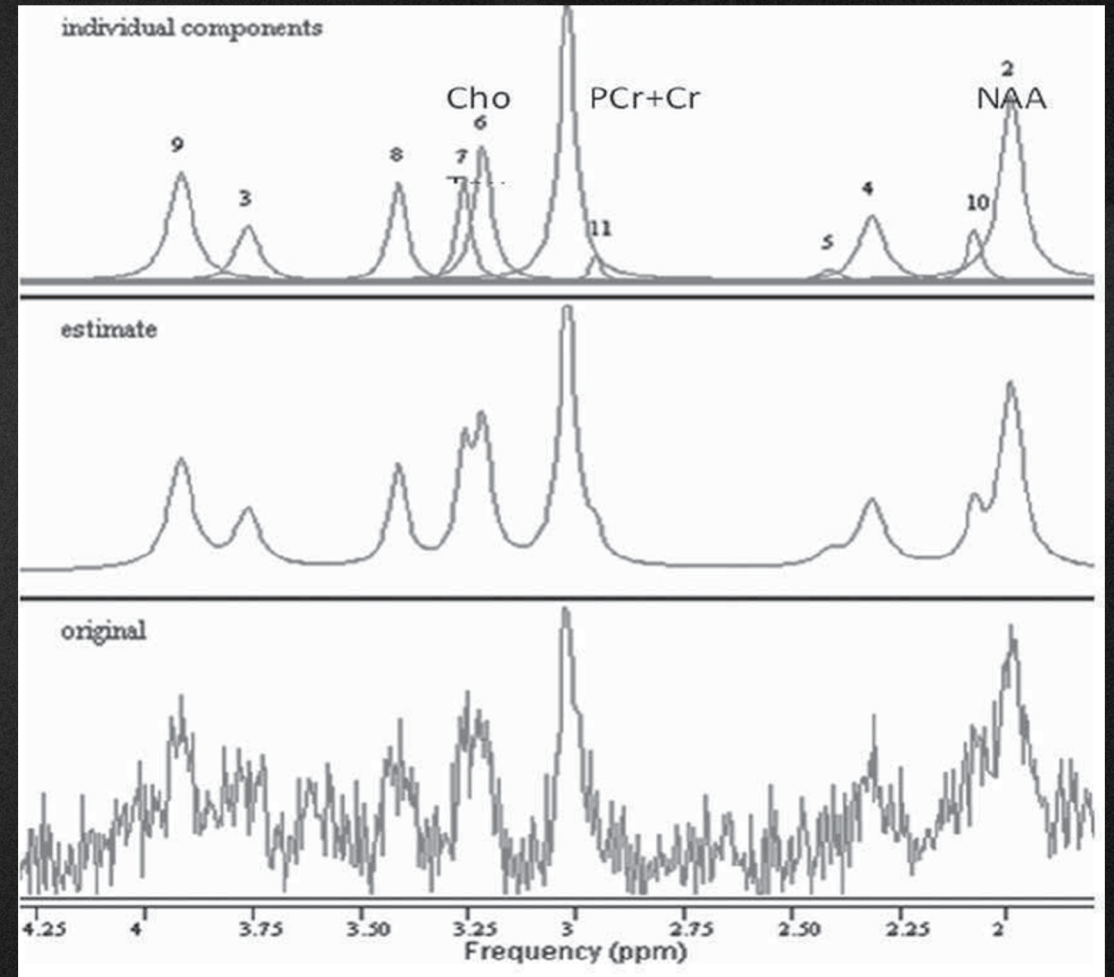


LC-Model

Fit acquired data to a linear combination of individual metabolite “basis spectra” (LC Model)



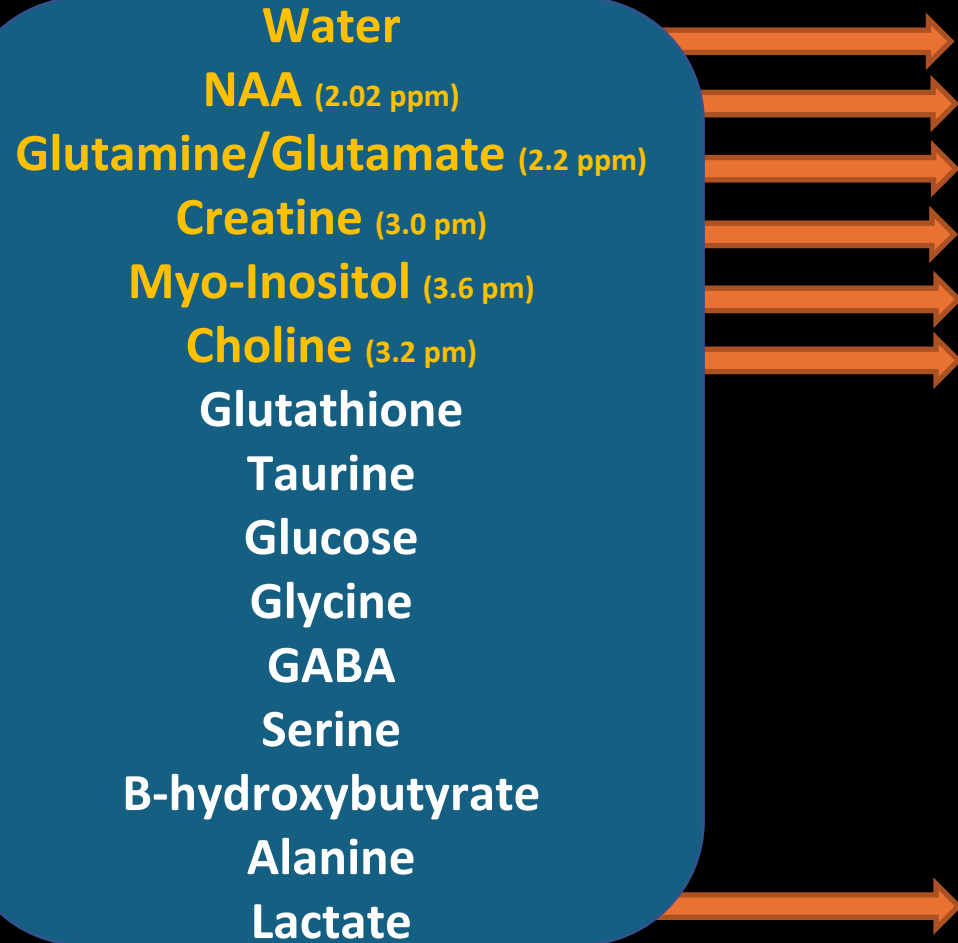
Compare the reference peaks with the ones from our data to have some estimation of quantity



“internal ratios of comparison and external ratio of comparison”

1H-MRS- What are the normal peaks to detect

What can be detected



What can not be detected

(mmol/L)

35.000 (remove)

12

10

8

6

2

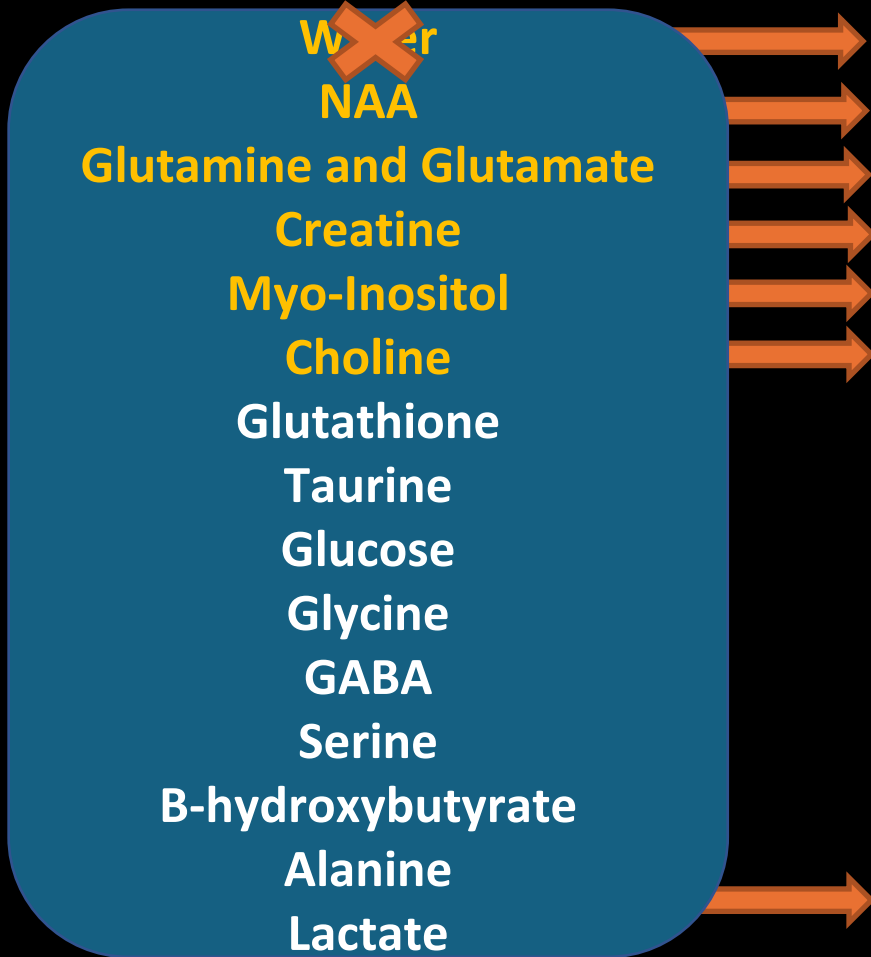
0,2

Dopamine
Serotonin
Acetylcholine

Proteins
Enzymes
Molecules with tightly bound

1H-MRS- What are the normal peaks to detect?

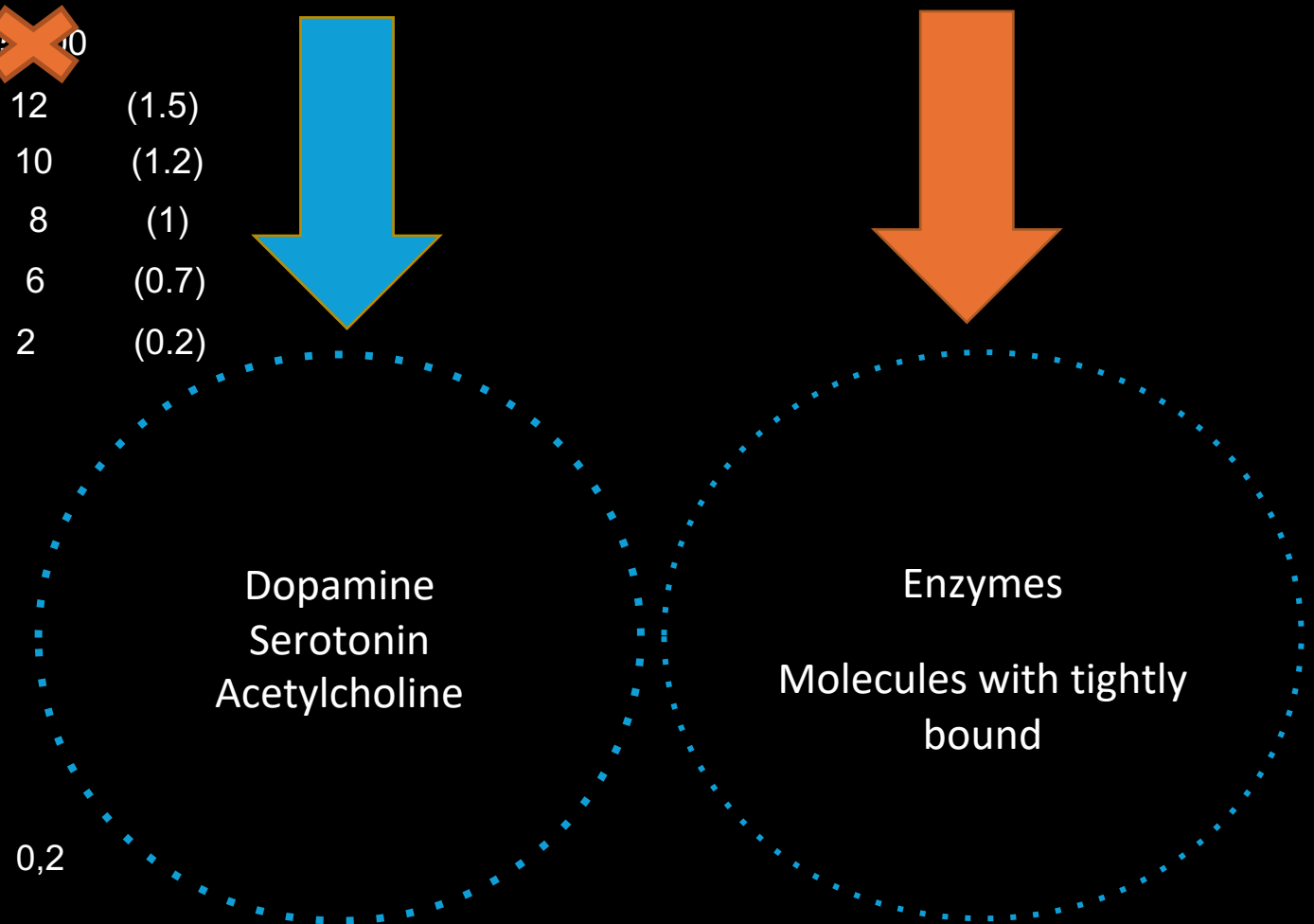
What we can detect



(mmol/L)

30	10
12	(1.5)
10	(1.2)
8	(1)
6	(0.7)
2	(0.2)

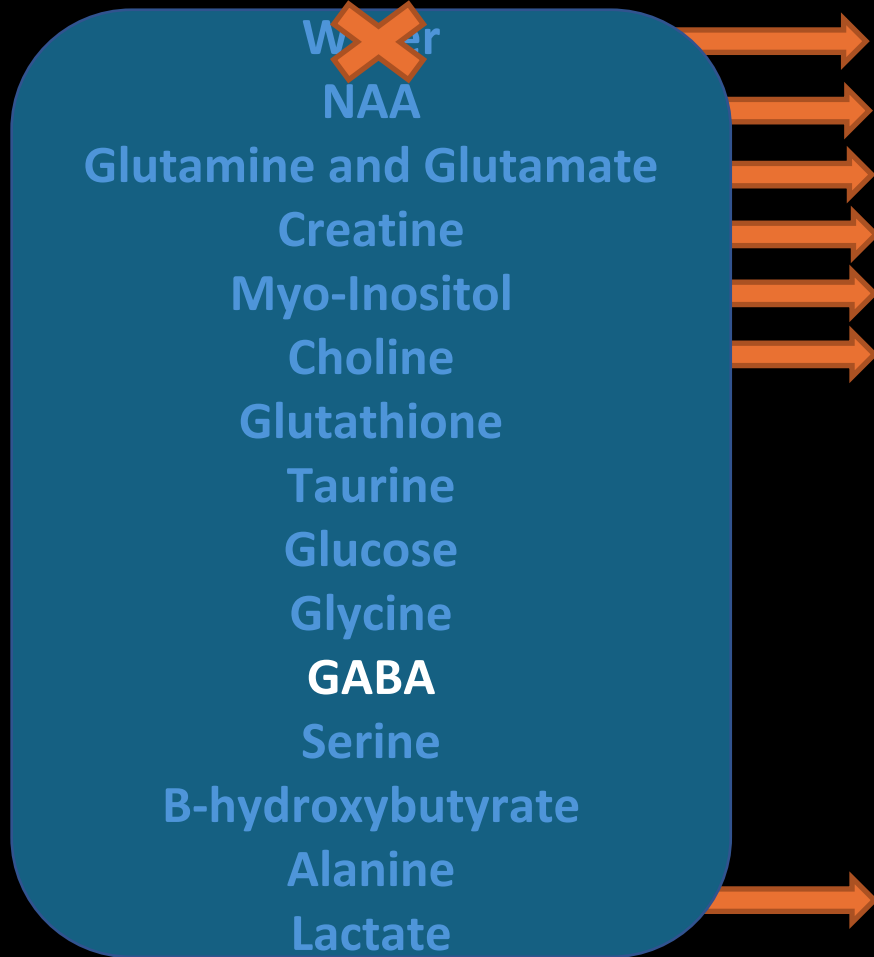
What we can't detect



0,2

1H-MRS- What are the normal peaks to detect?

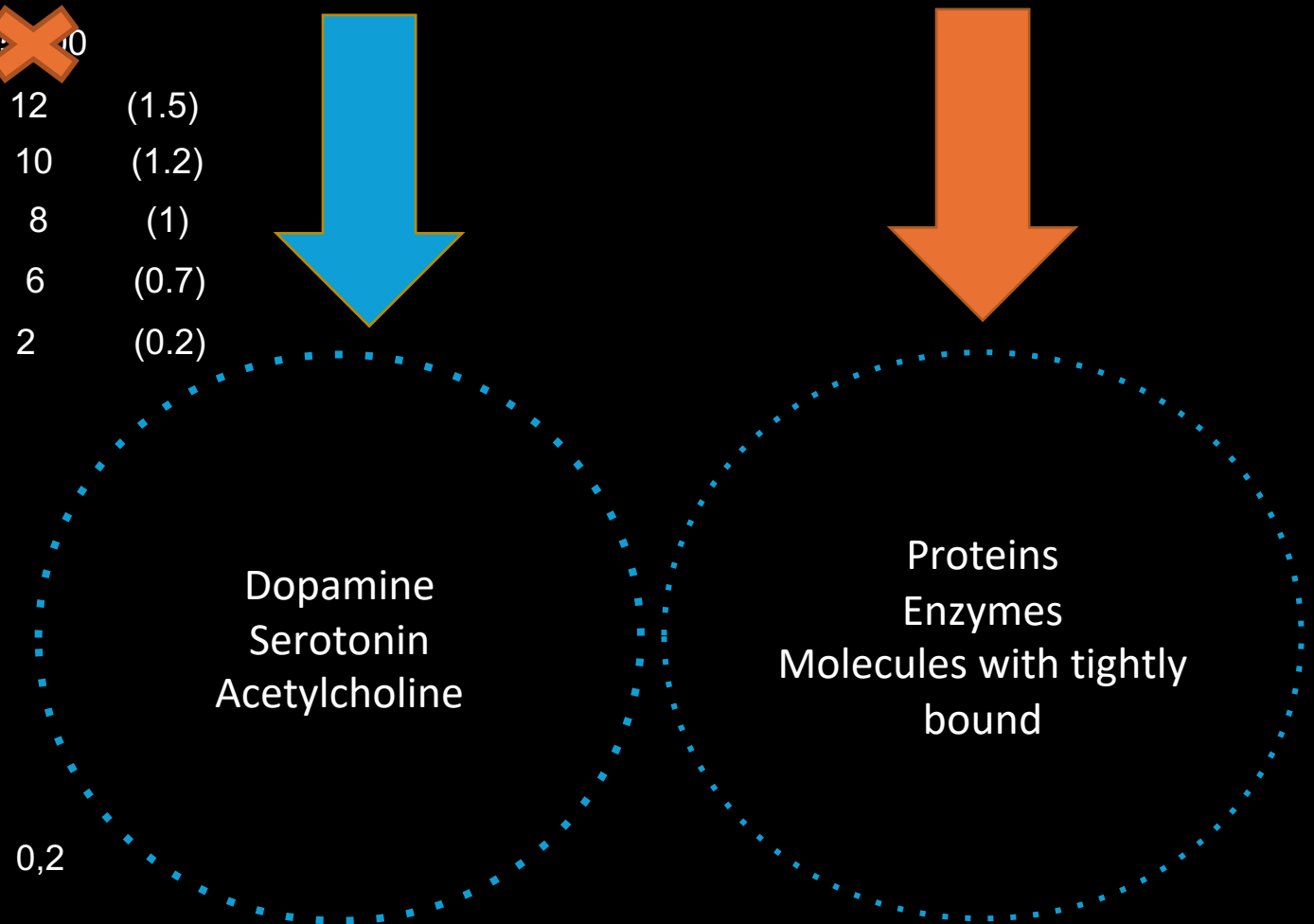
What we can detect



(mmol/L)

30	10
12	(1.5)
10	(1.2)
8	(1)
6	(0.7)
2	(0.2)

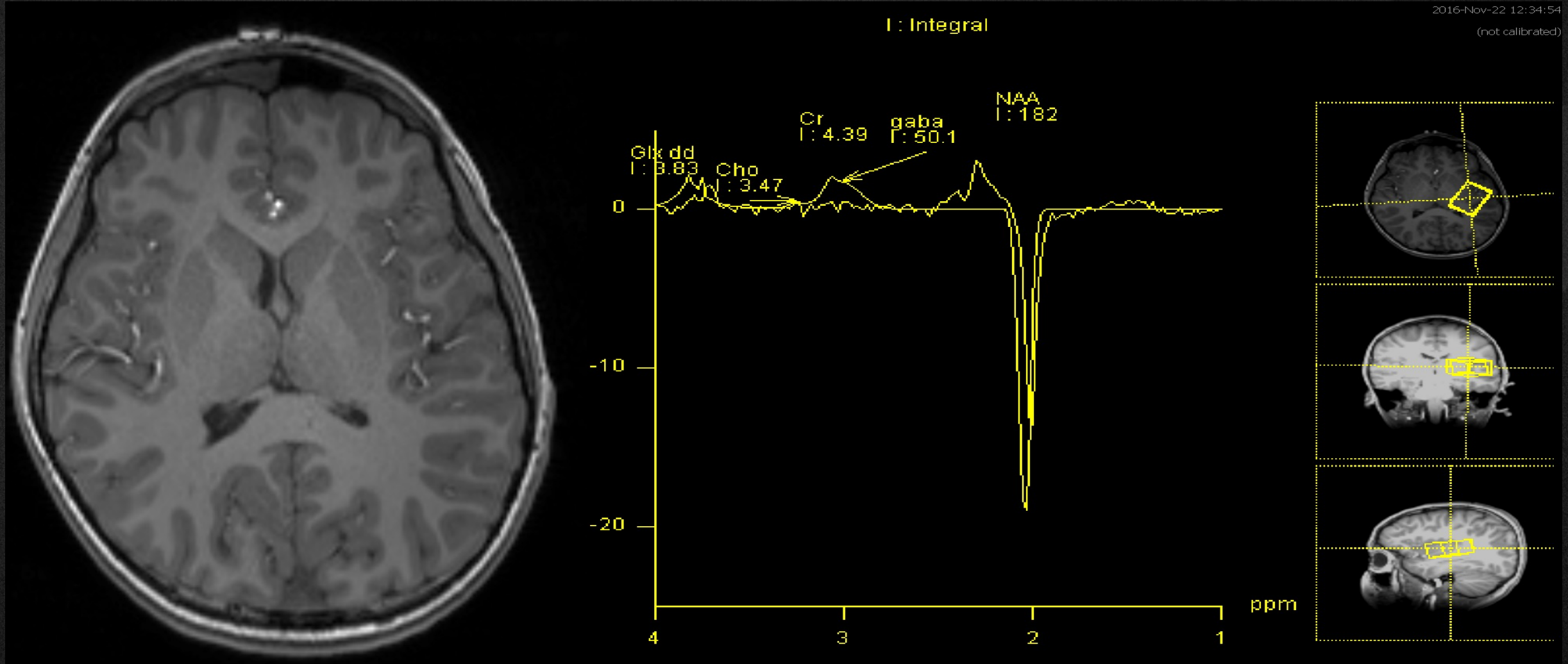
What we can't detect



0,2

1H-EDITING-MRS – GABA

European Course on
Pediatric Neuroradiology in
Latin America (ECPNR-LATAM)
3rd Cycle - Module 1

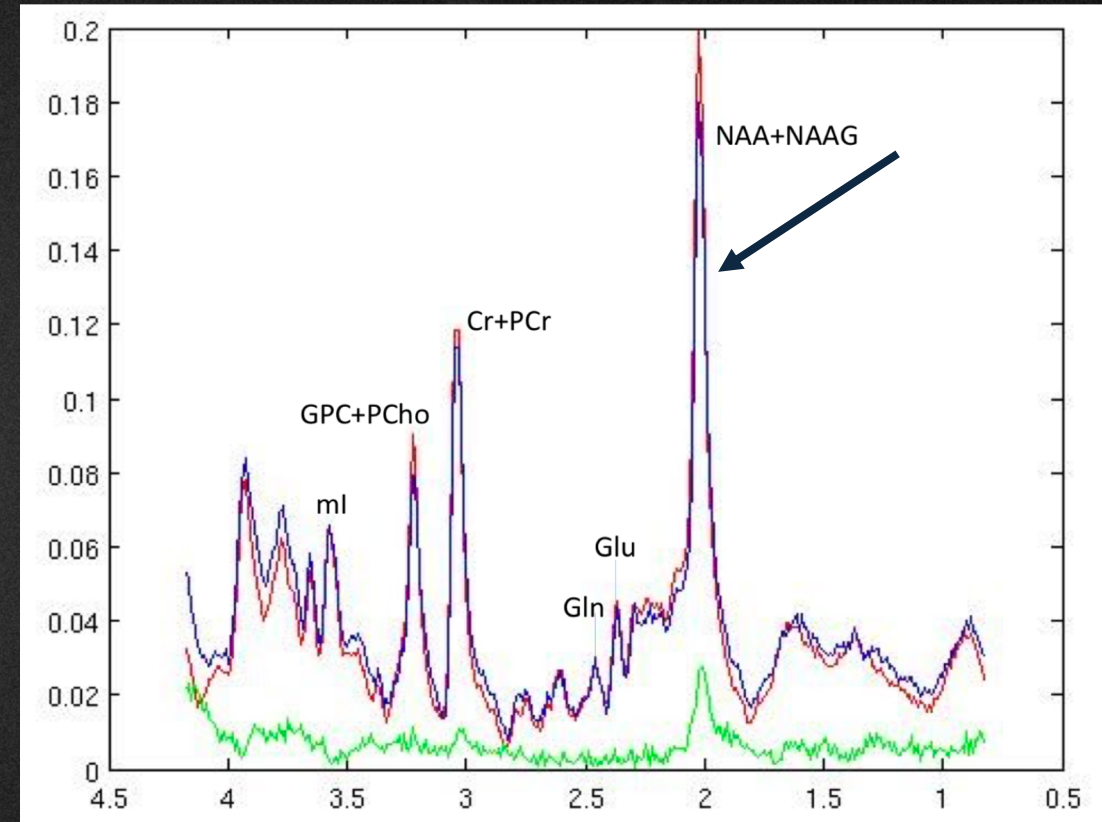


NAA- N-acetylaspartate

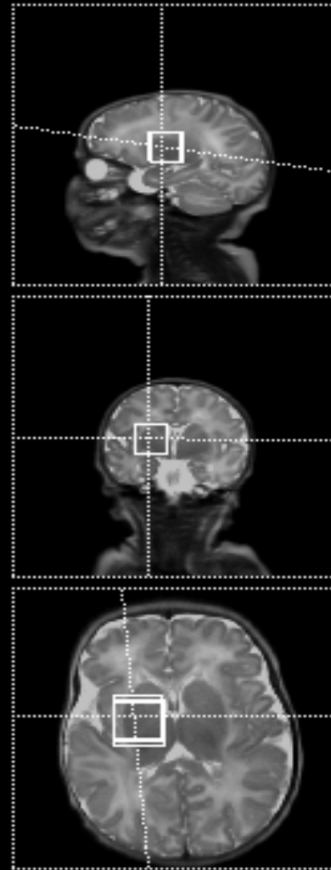
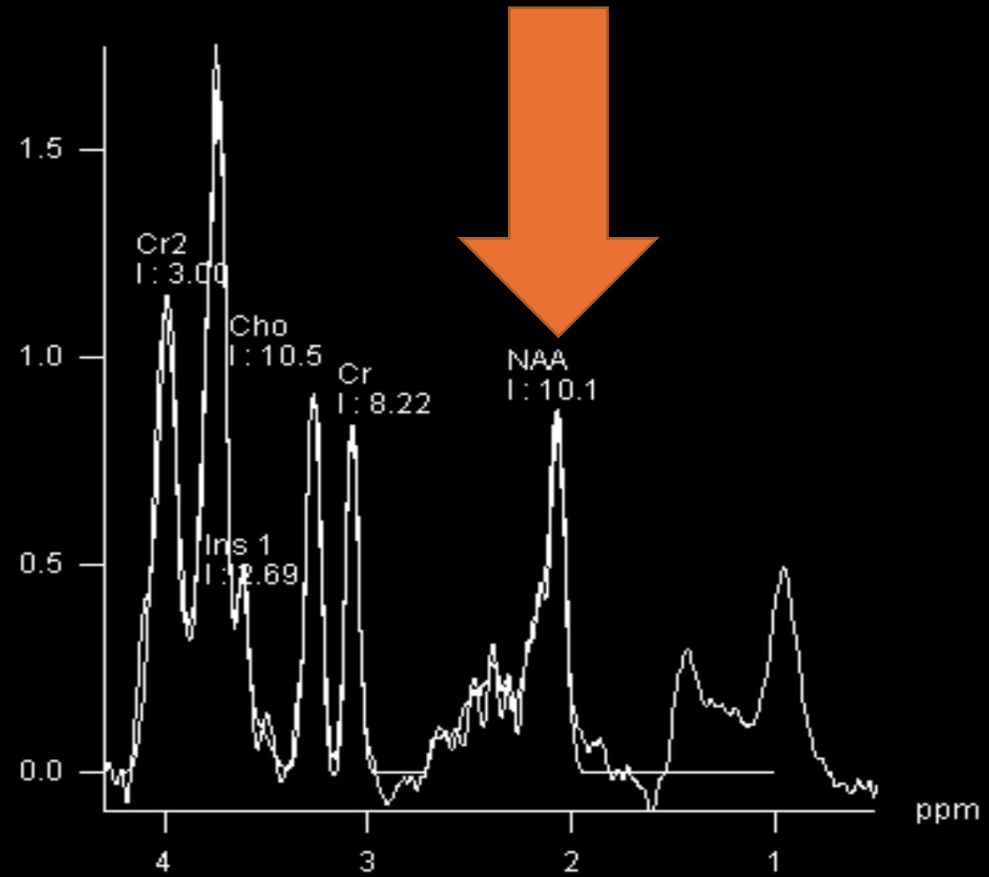
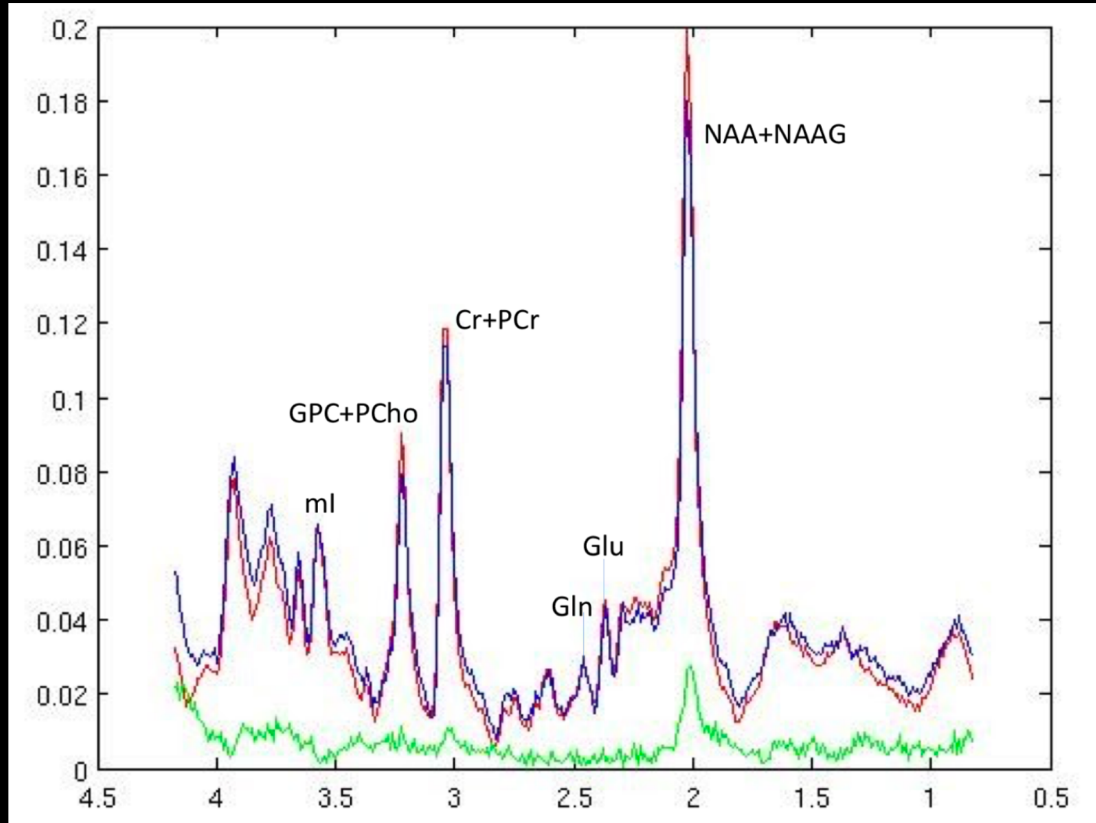
Resonates at 2.02 ppm chemical shift

NAA is a marker of neuronal and axonal function

- NAA → mitochondrial activity
- NAA → degree and maintenance of myelin

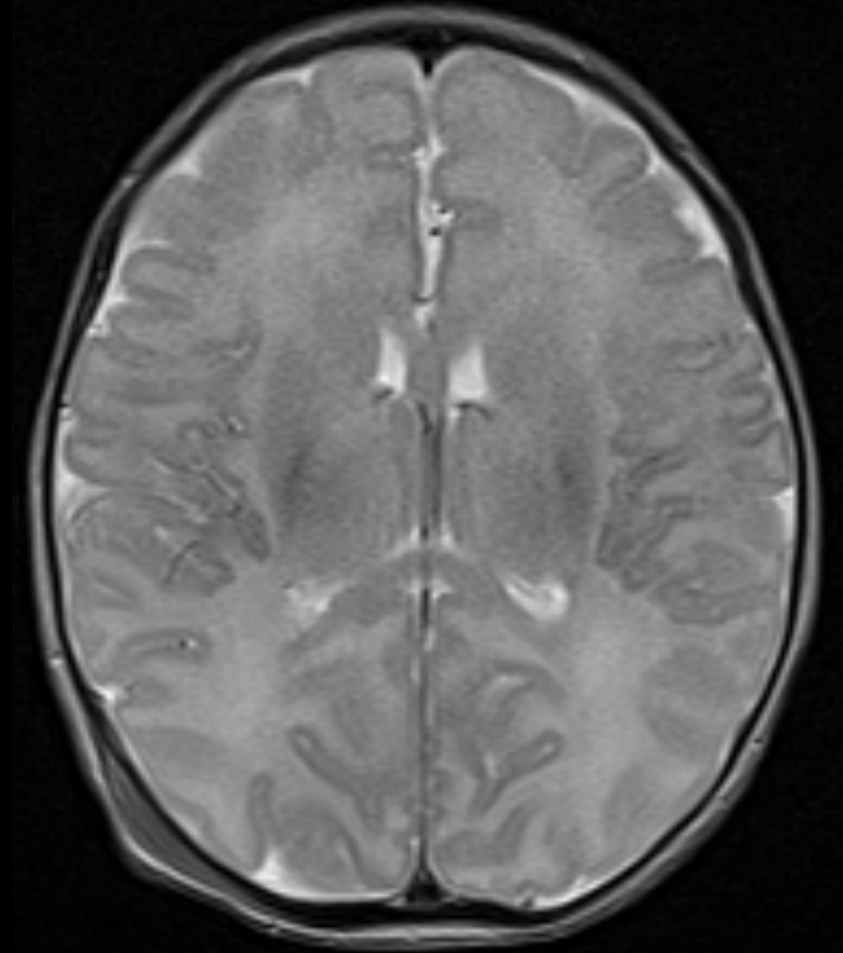
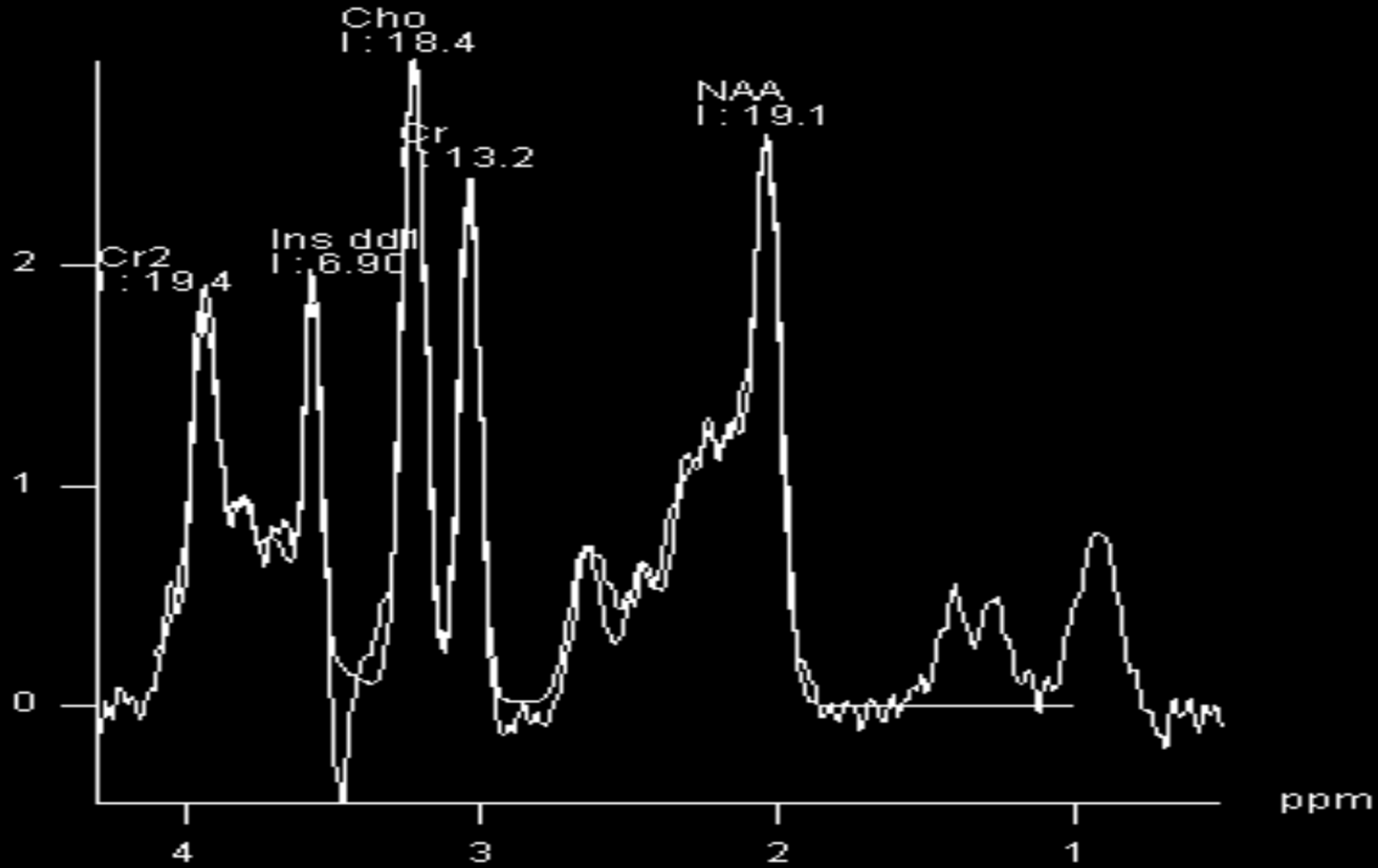


Neuronal and axonal dysfunction



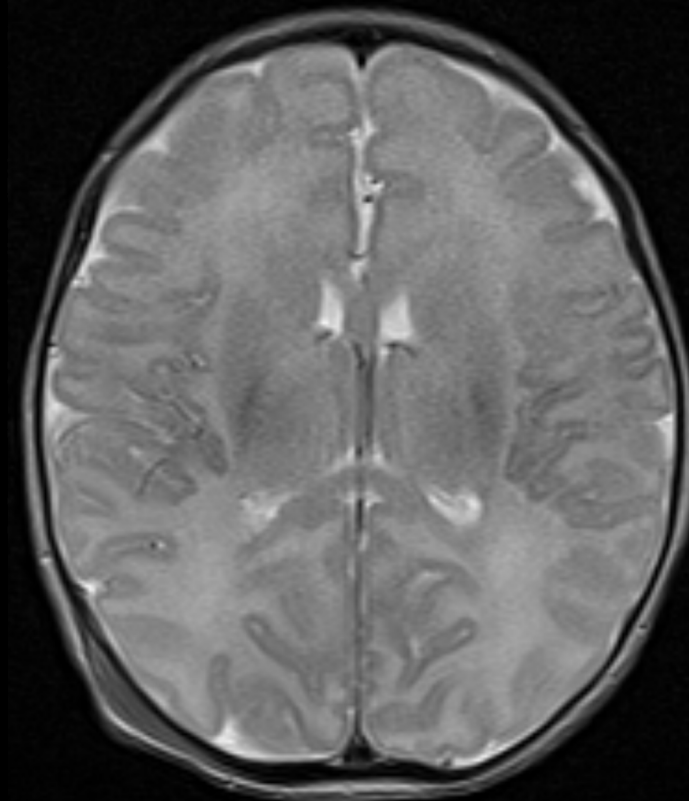
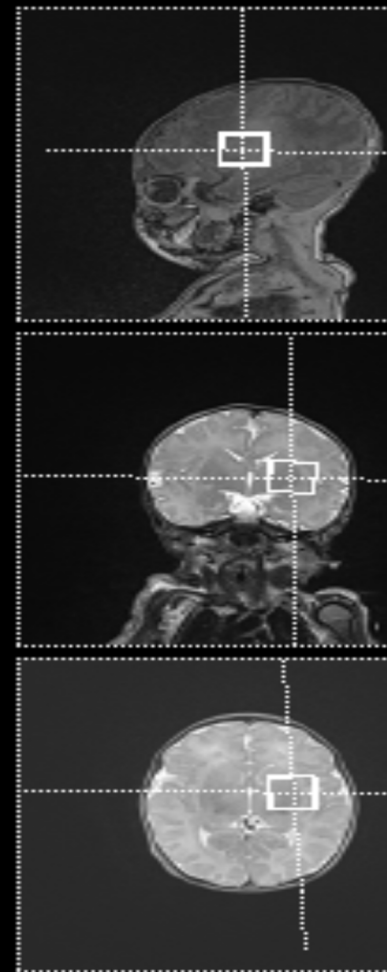
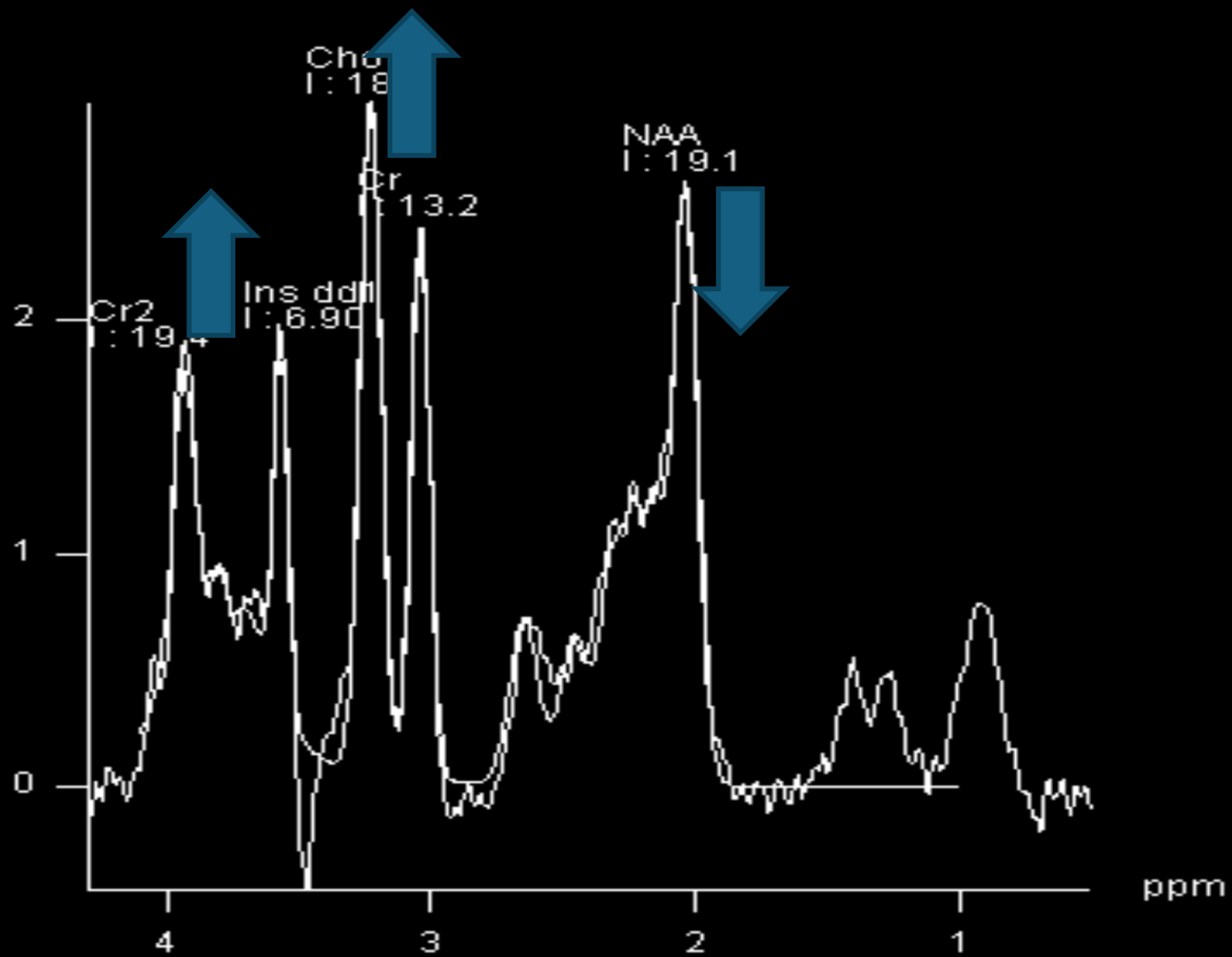
CASE 0

Multiple episodes of vomiting



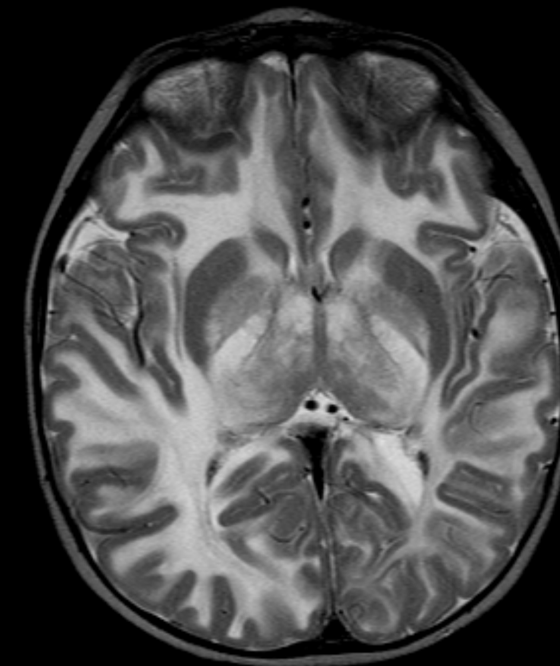
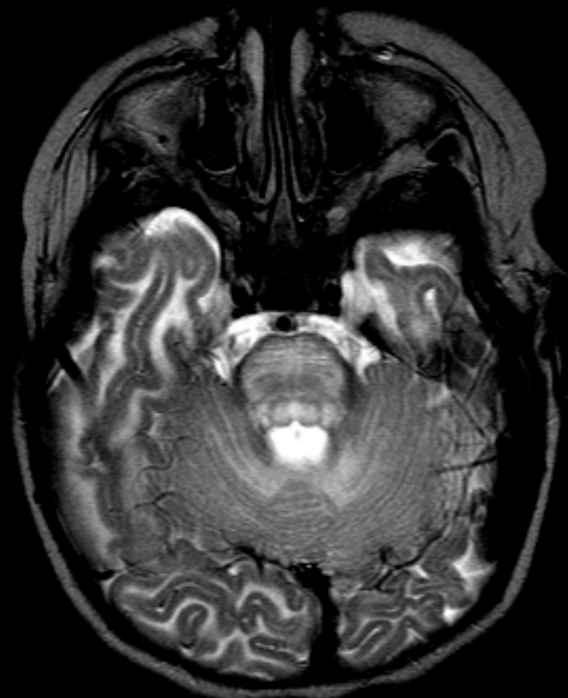
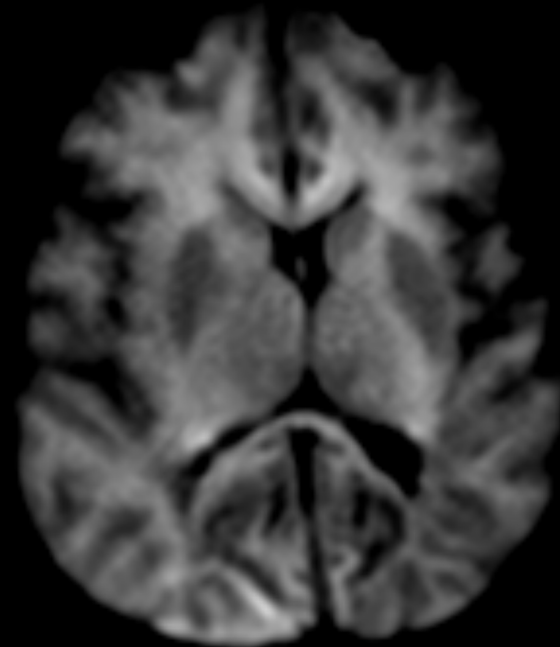
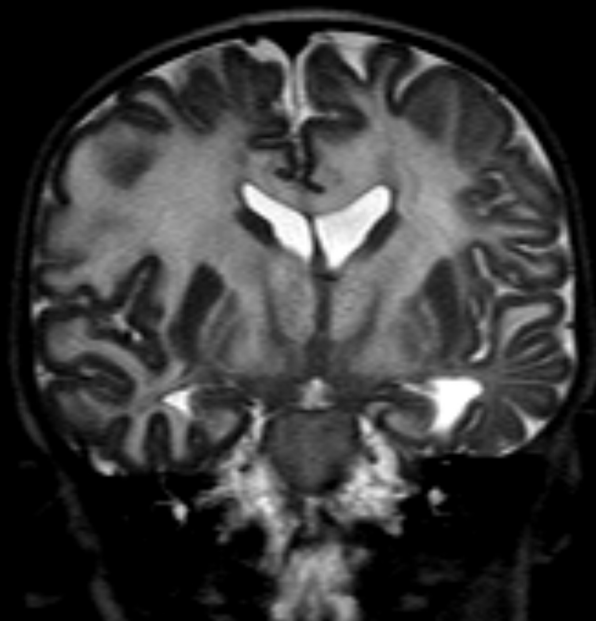
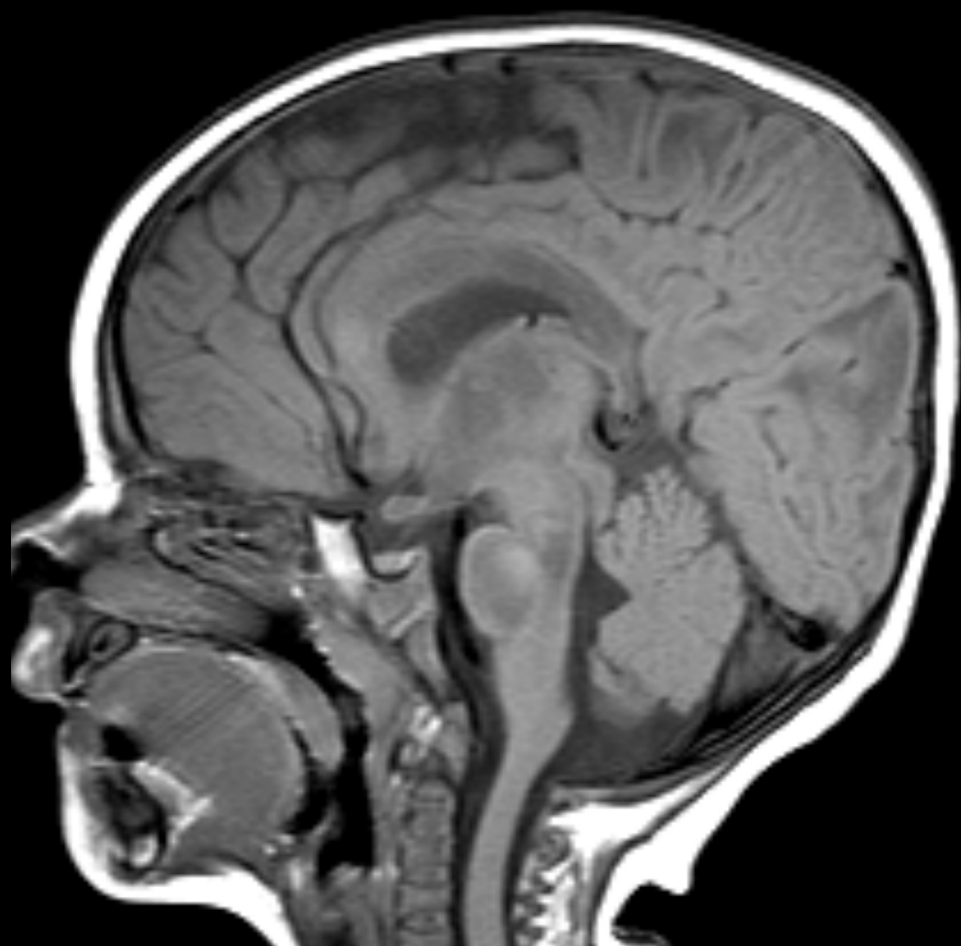
WHAT IS THE MOST IMPORTANT QUESTION HERE?

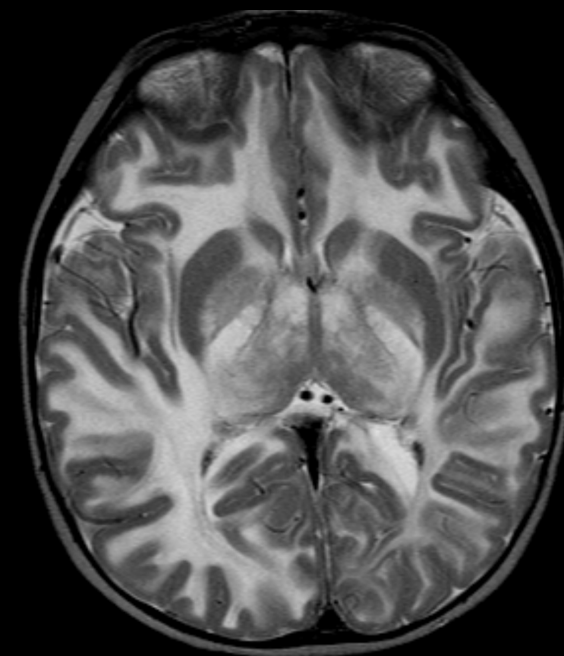
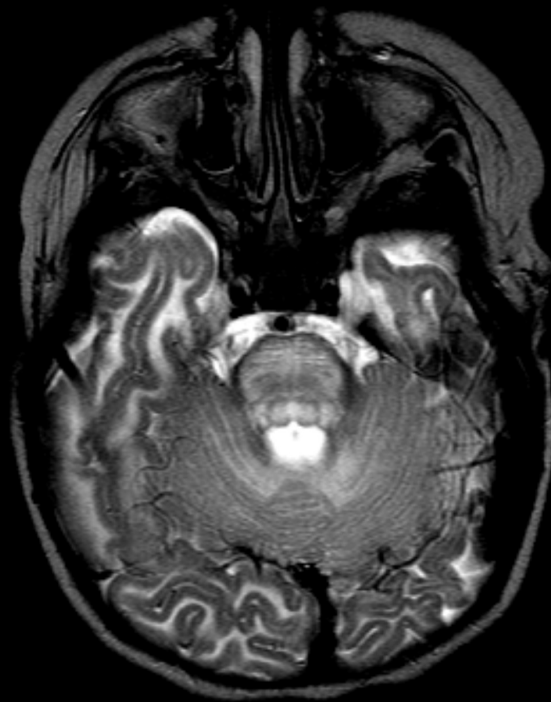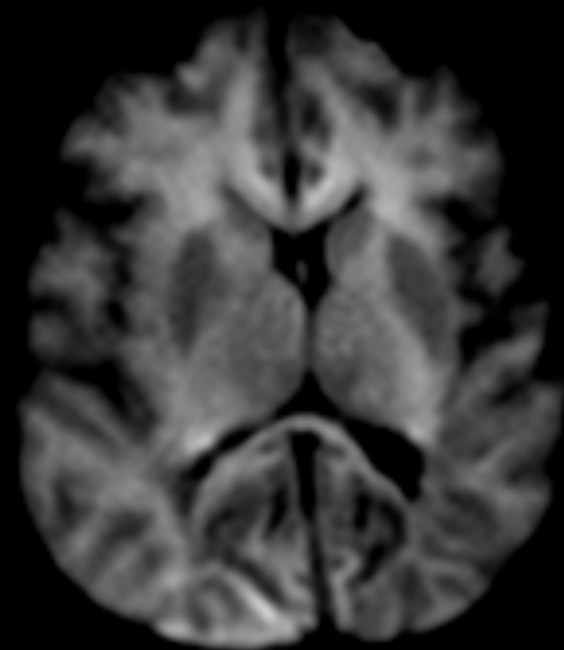
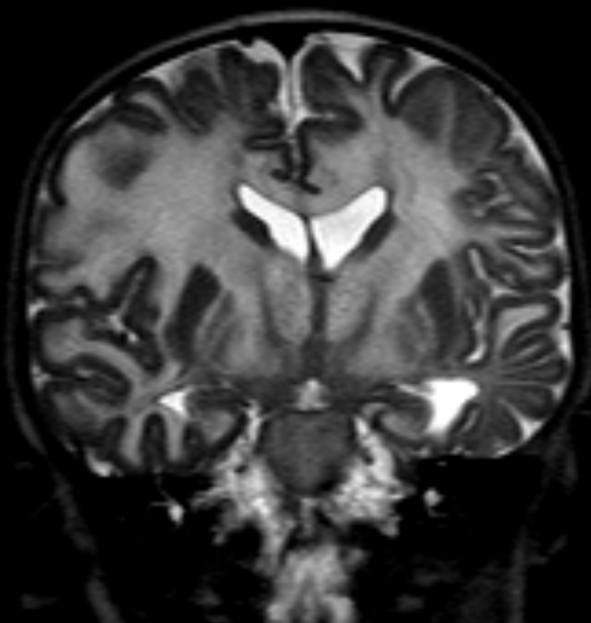
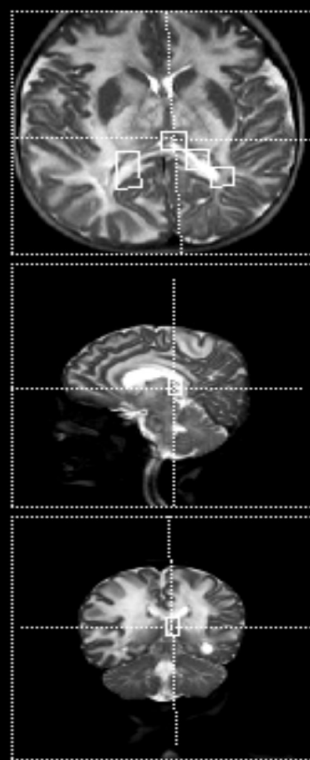
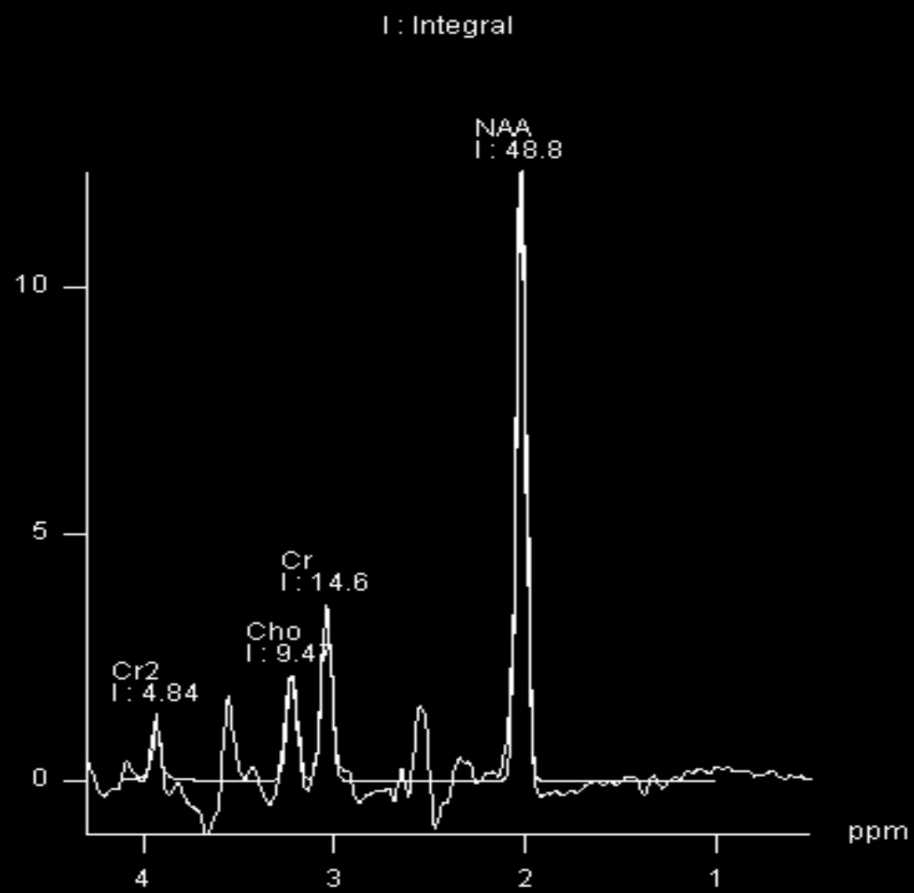
NEWBORN- NORMAL



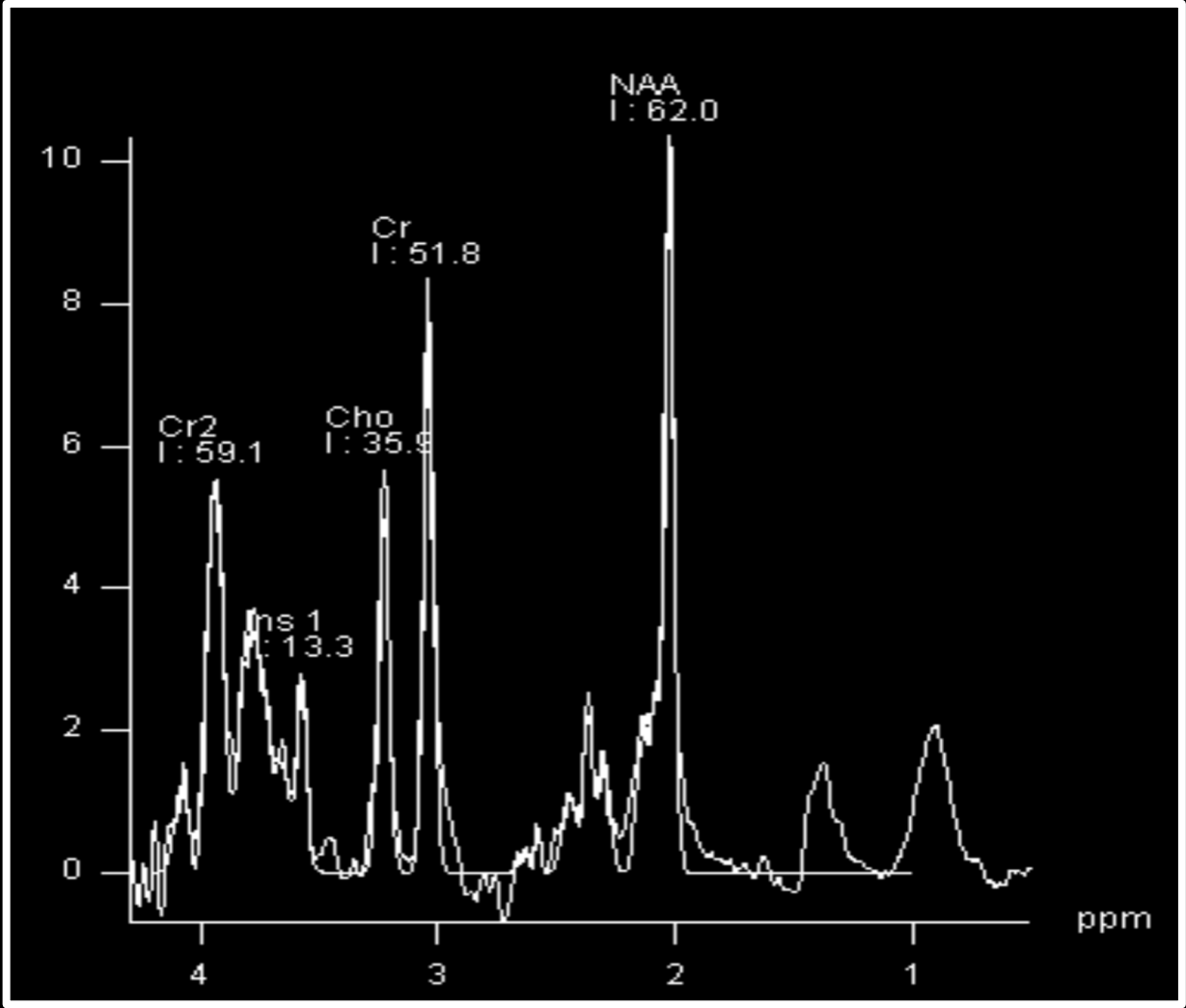
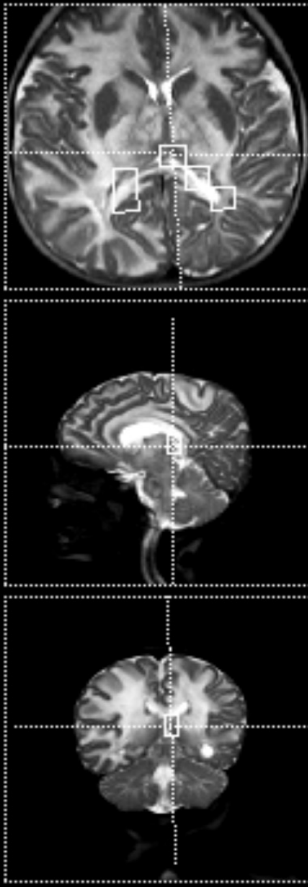
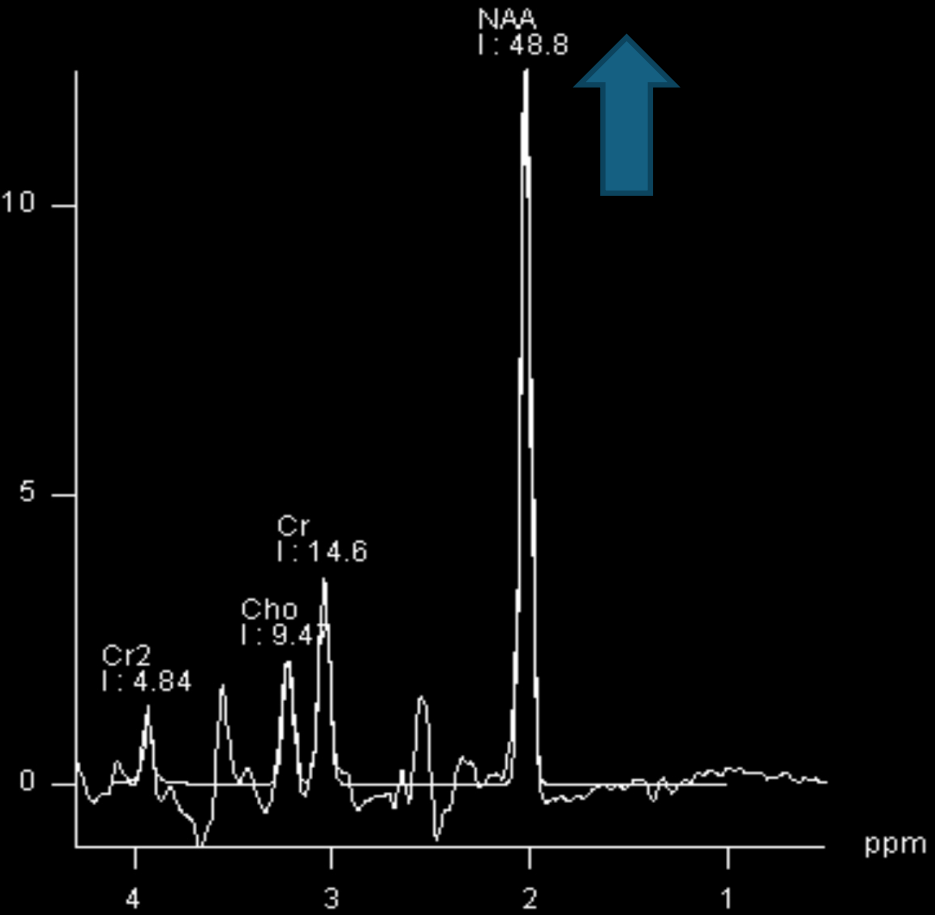
CASE 1

6 months old, male patient
Macrocephaly, hypotonia and impaired milestones

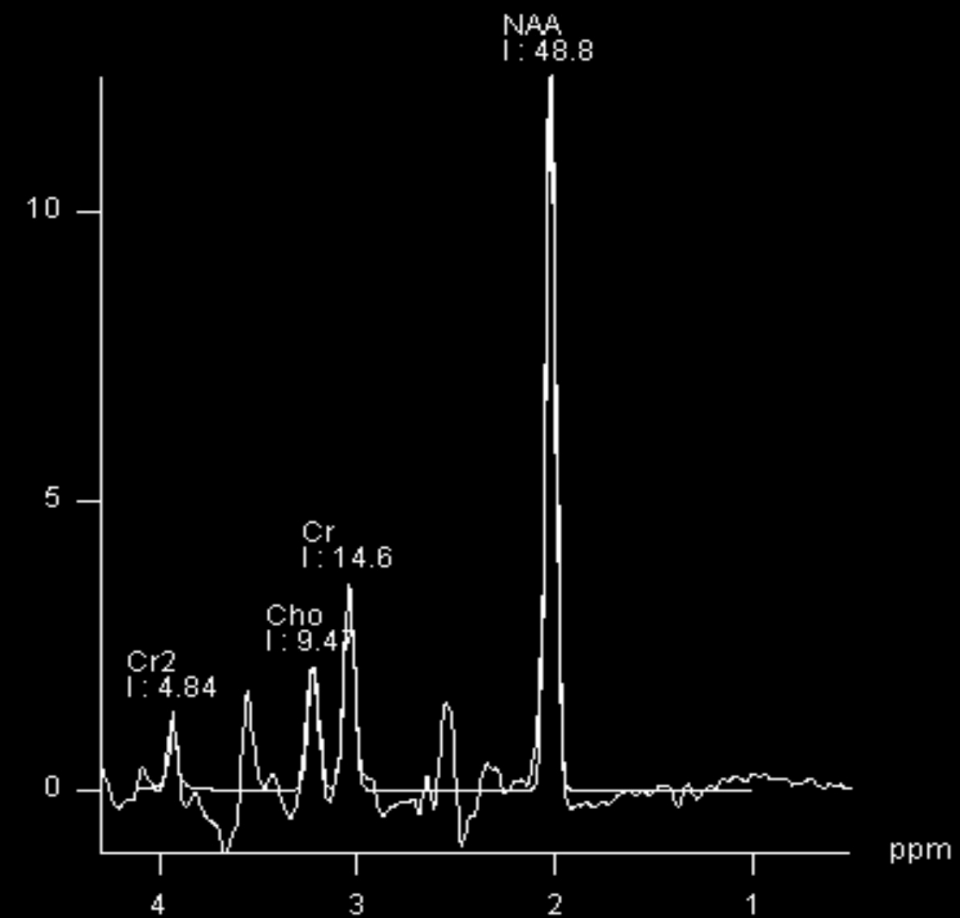




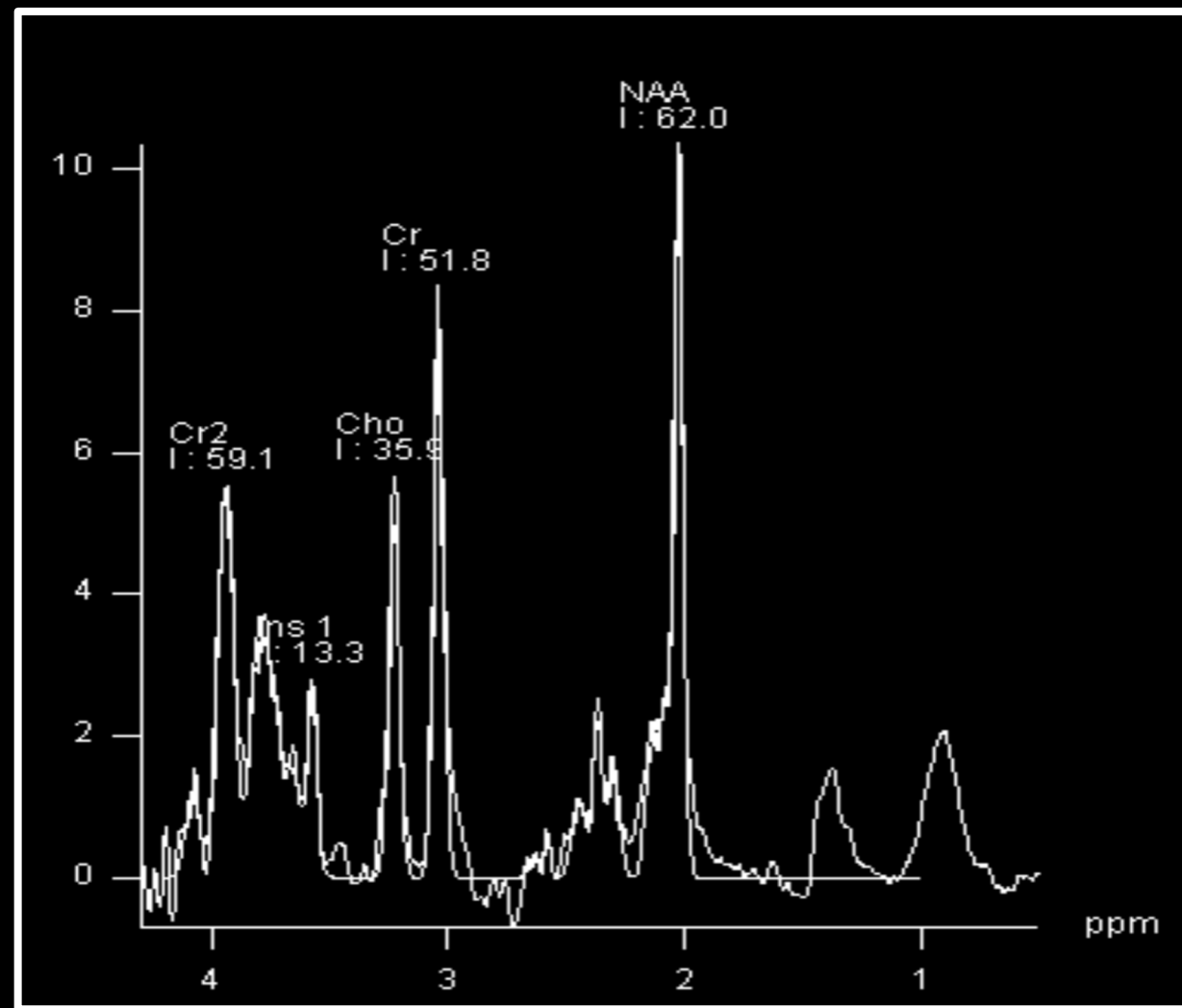
NORMAL



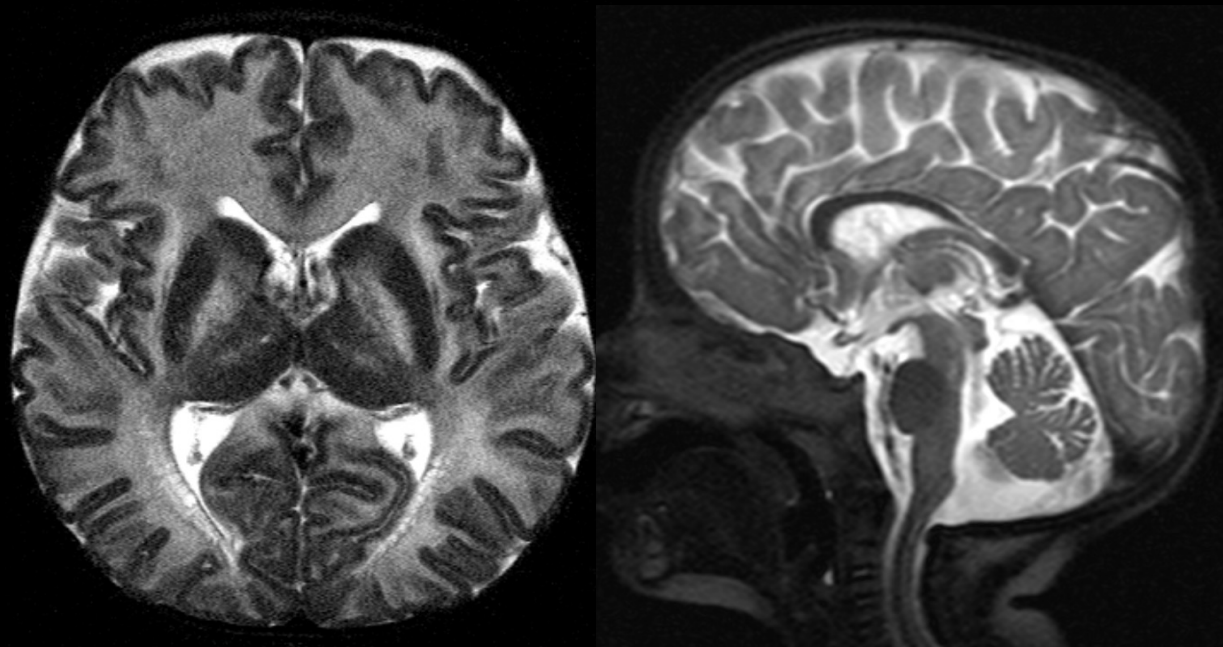
CANAVAN



NORMAL



MR- Spectroscopy- Canavan



C

↓ Aspartatociclase enzyme

A

NAA acumulation

Edema

Espongiform degeneration of WM

N

Macrocrania

A

V

Imaging Characteristics

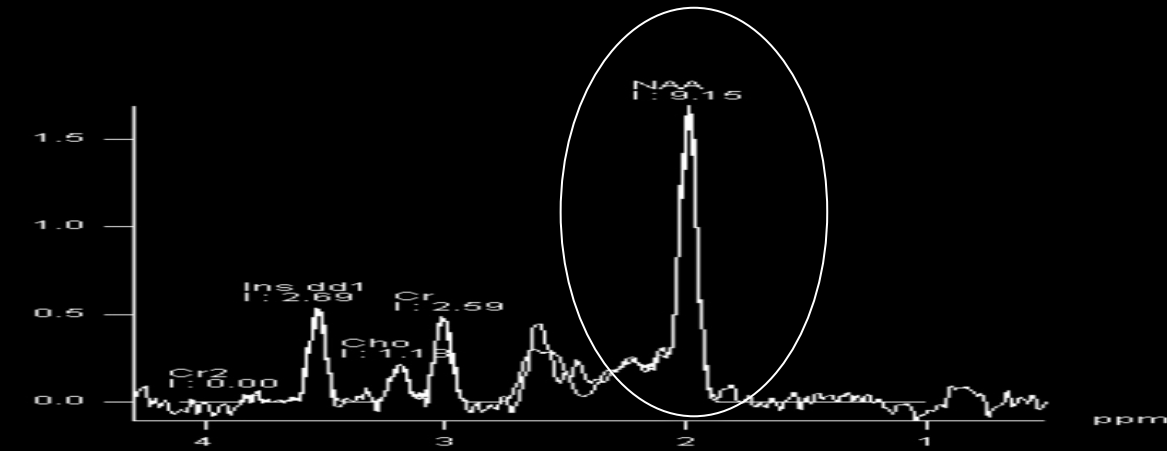
Diffuse WM involvement

U fiber involvement

Increased MRS-NAA

A

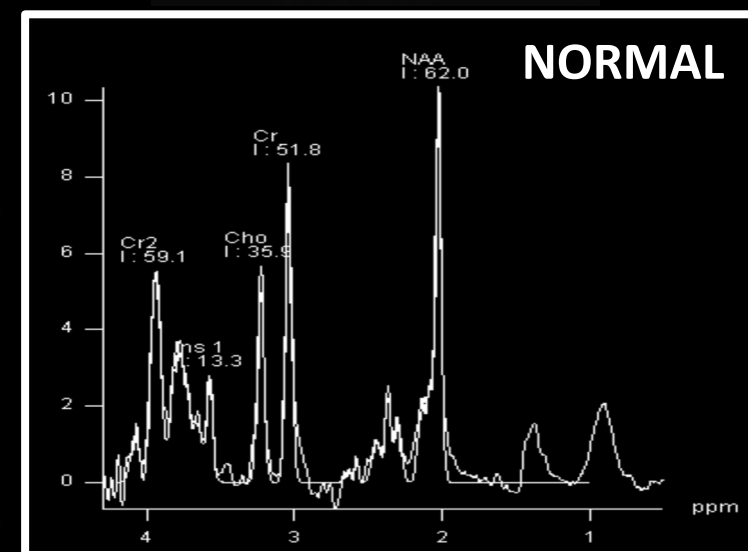
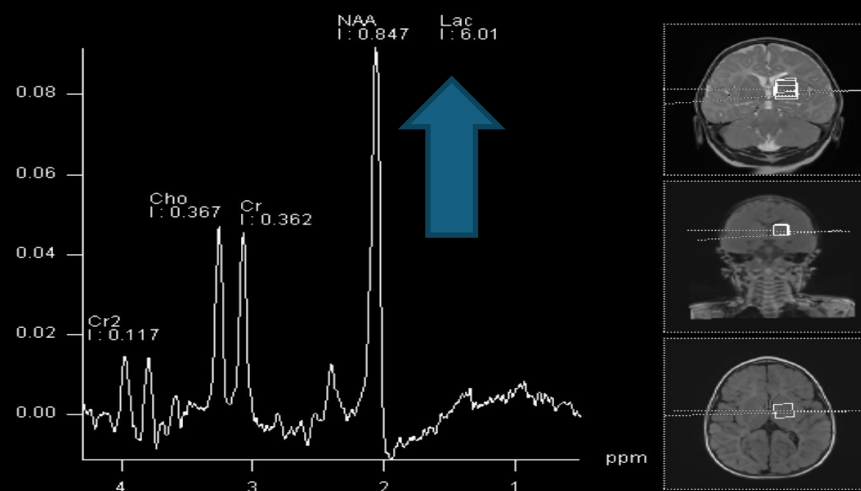
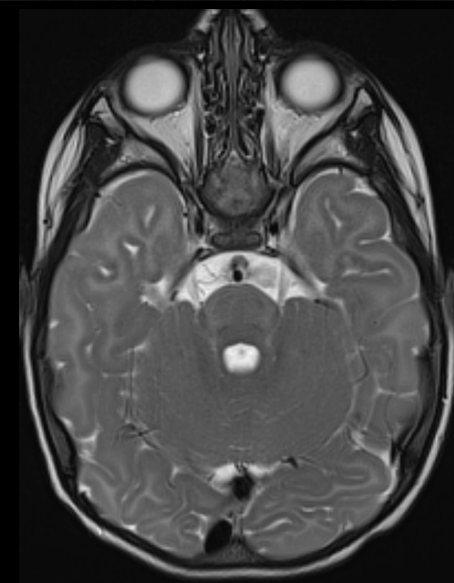
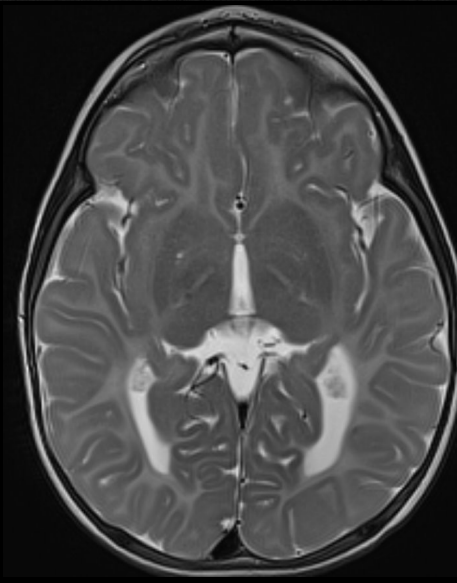
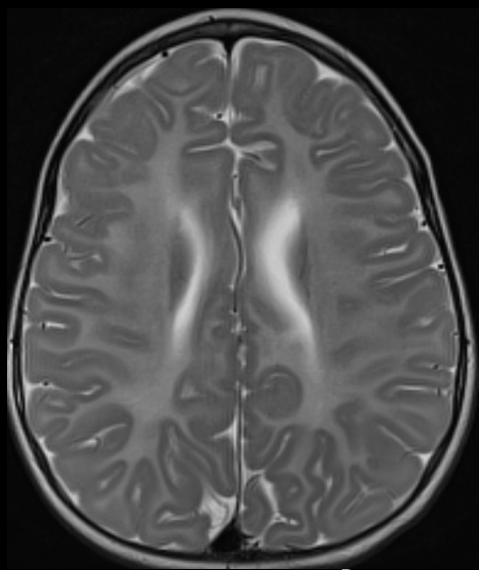
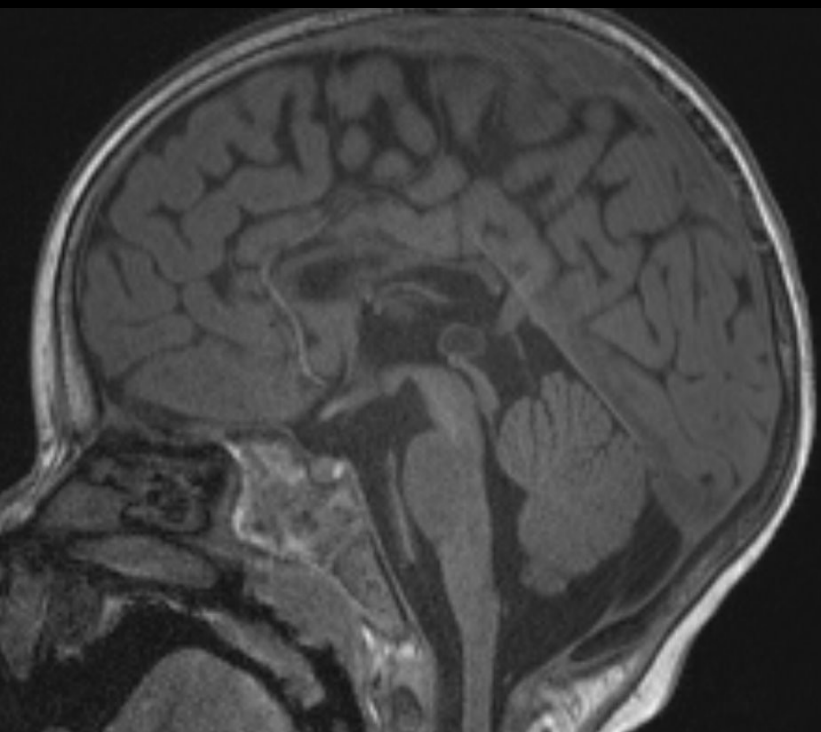
N



CHALLENGING CASE

European Course on
Pediatric Neuroradiology in
Latin America (ECPNR-LATAM)
3rd Cycle - Module 1

3 years old male with hypotonia, and movement disorders such as ataxia and athetosis.

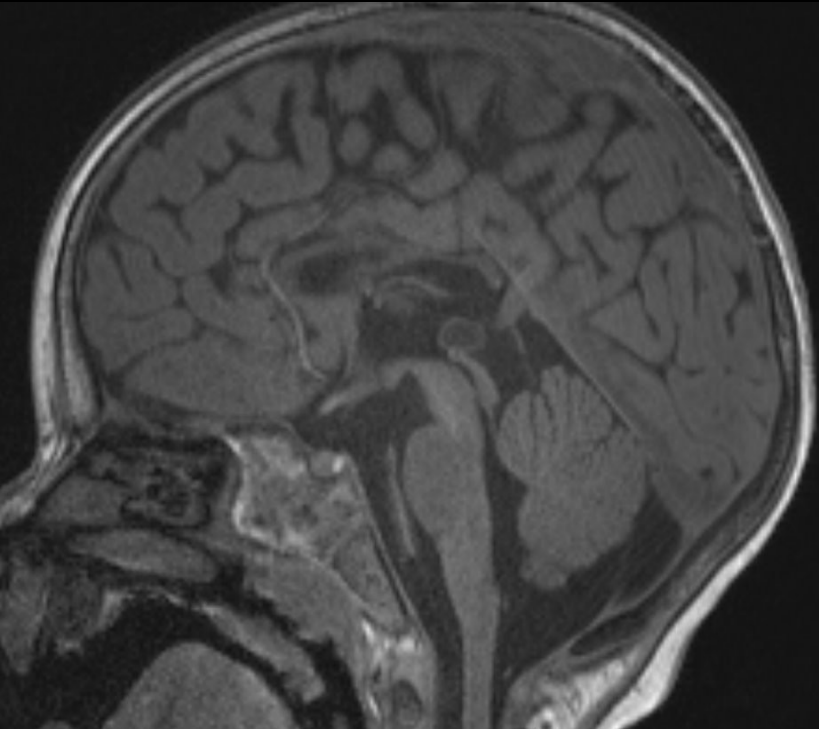


SALLA

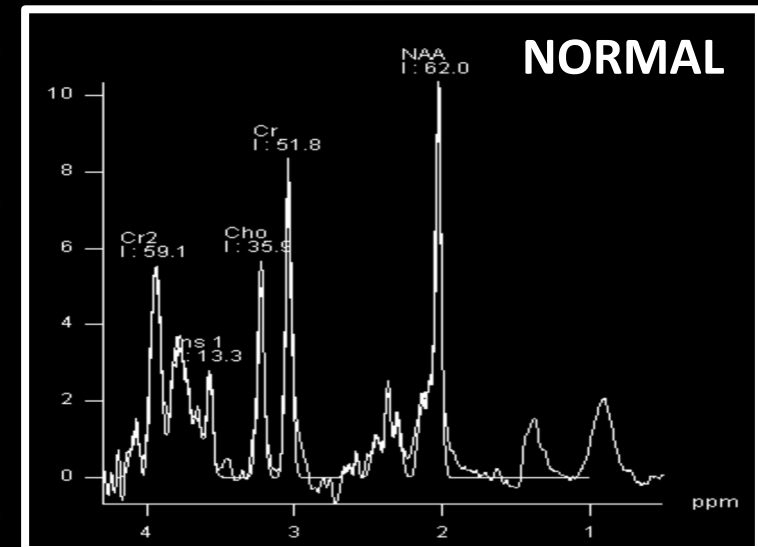
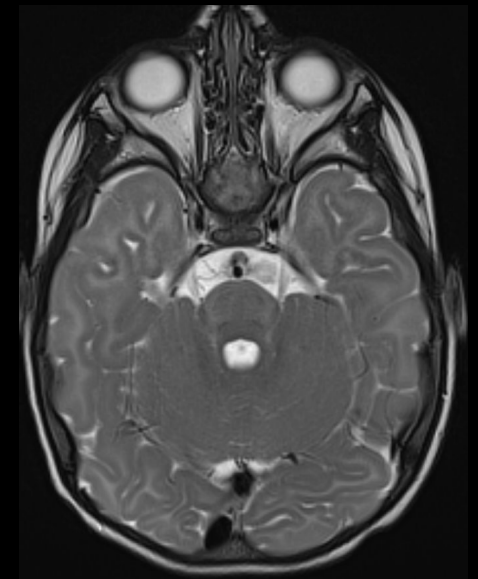
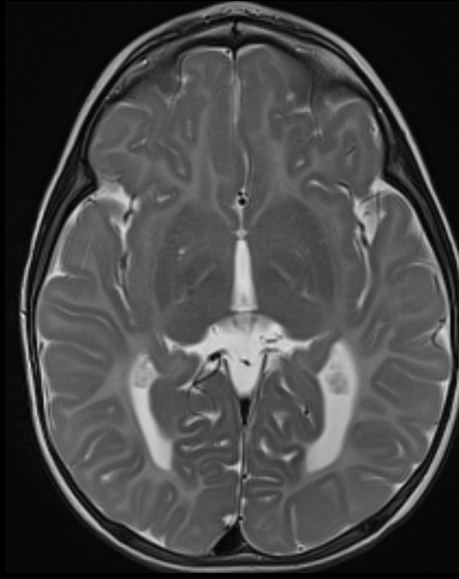
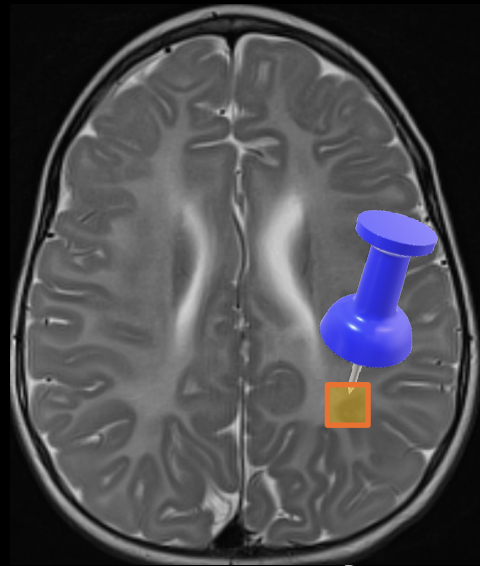
Lysosomal - Free sialic acid storage disorder

European Course on
Pediatric Neuroradiology in
Latin America (ECPNR-LATAM)
3rd Cycle - Module 1

N-acetylneuraminic acid (NANA) –resonates close to NAA

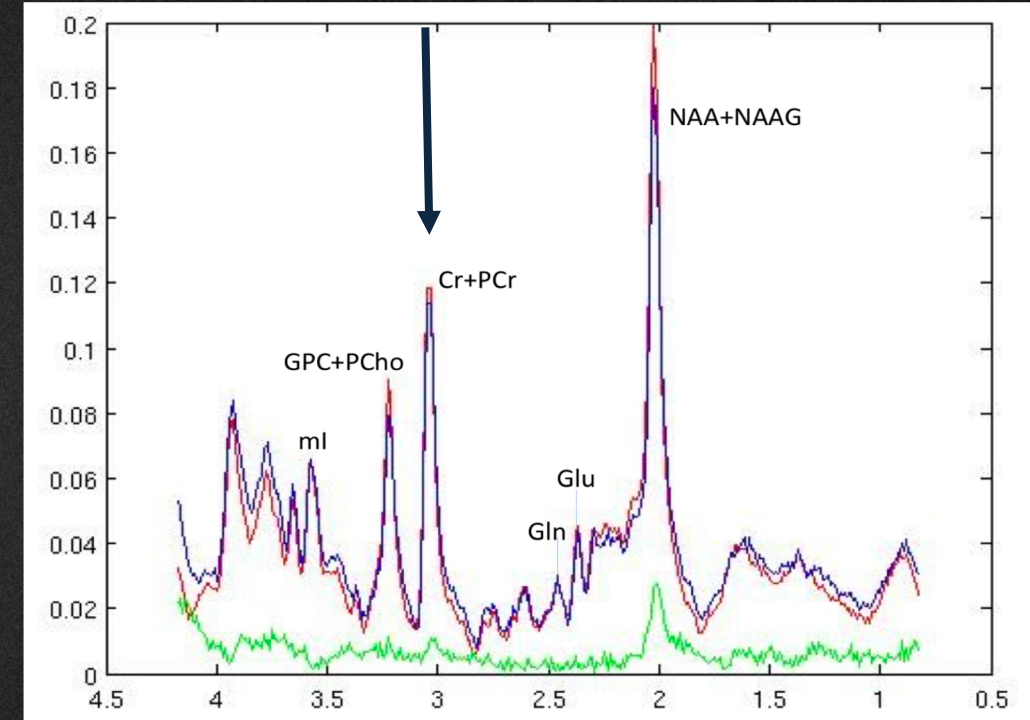


SLC17A5 C.406A>G, p. K136E)



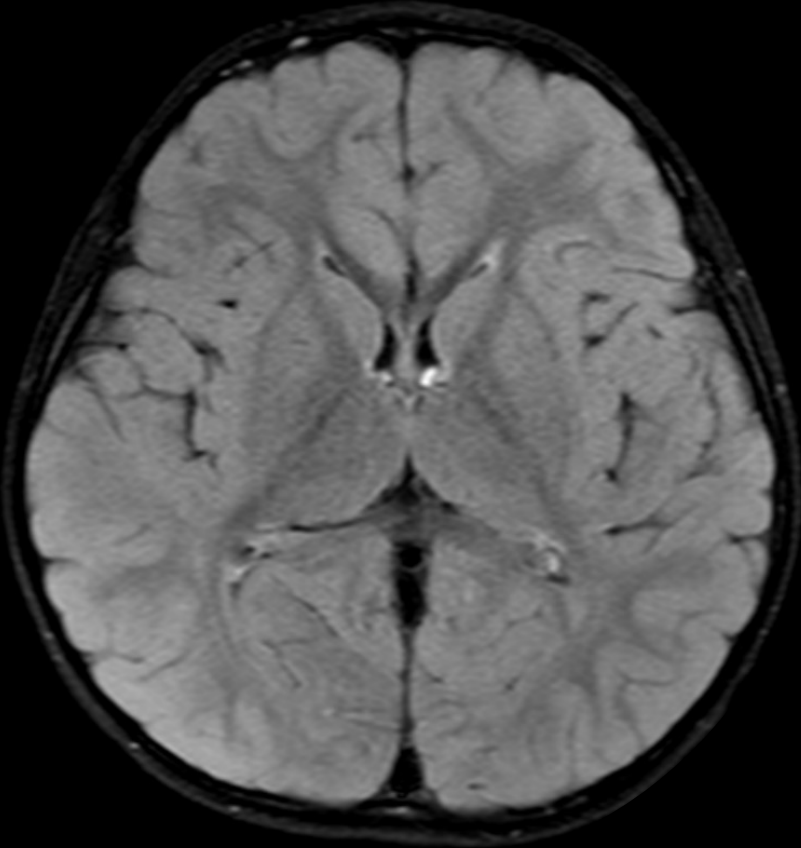
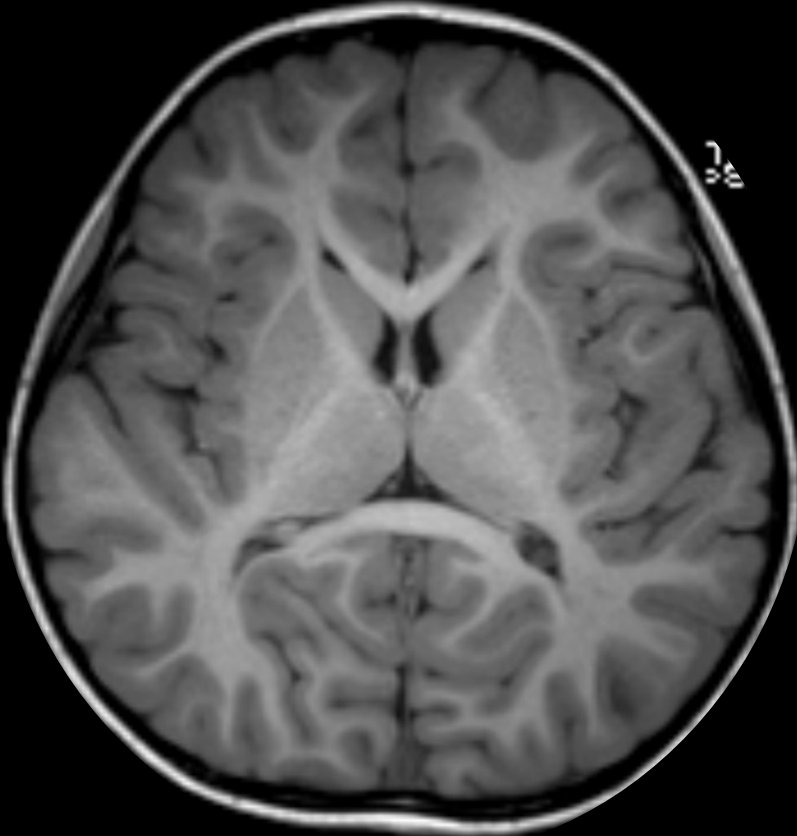
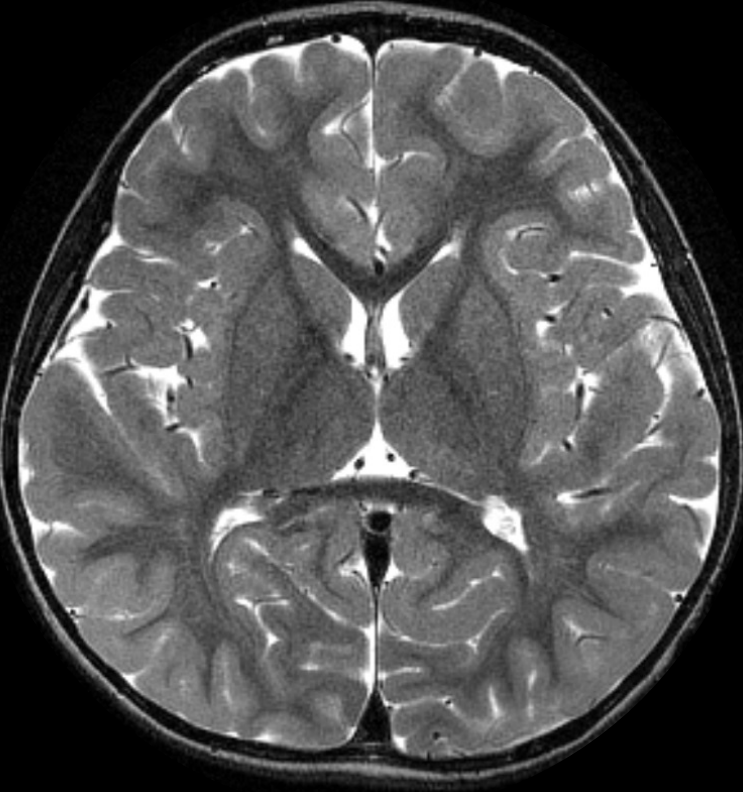Creatine

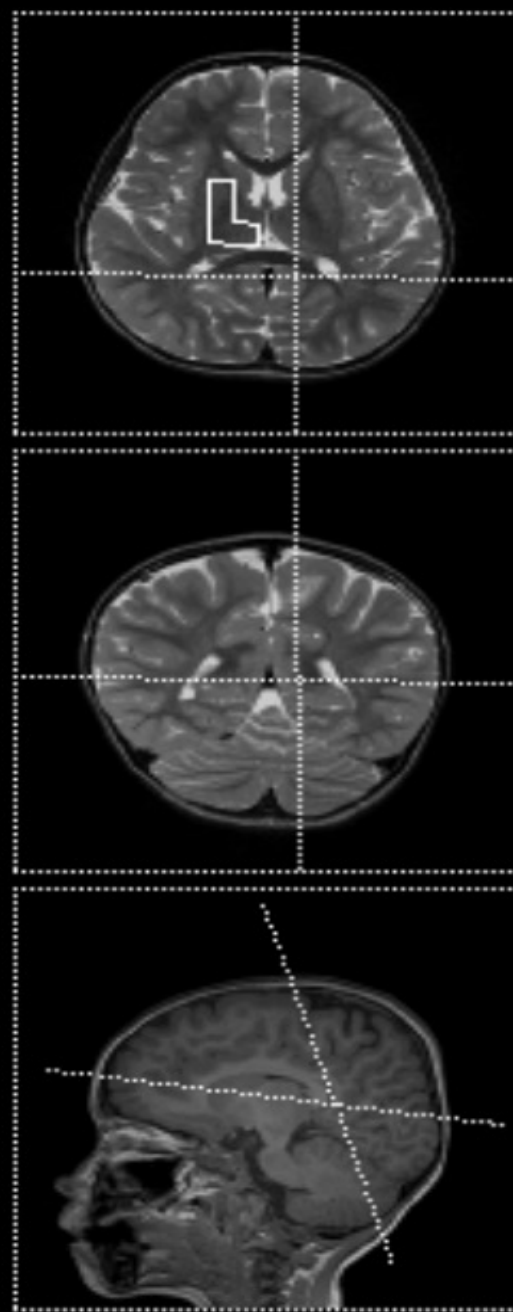
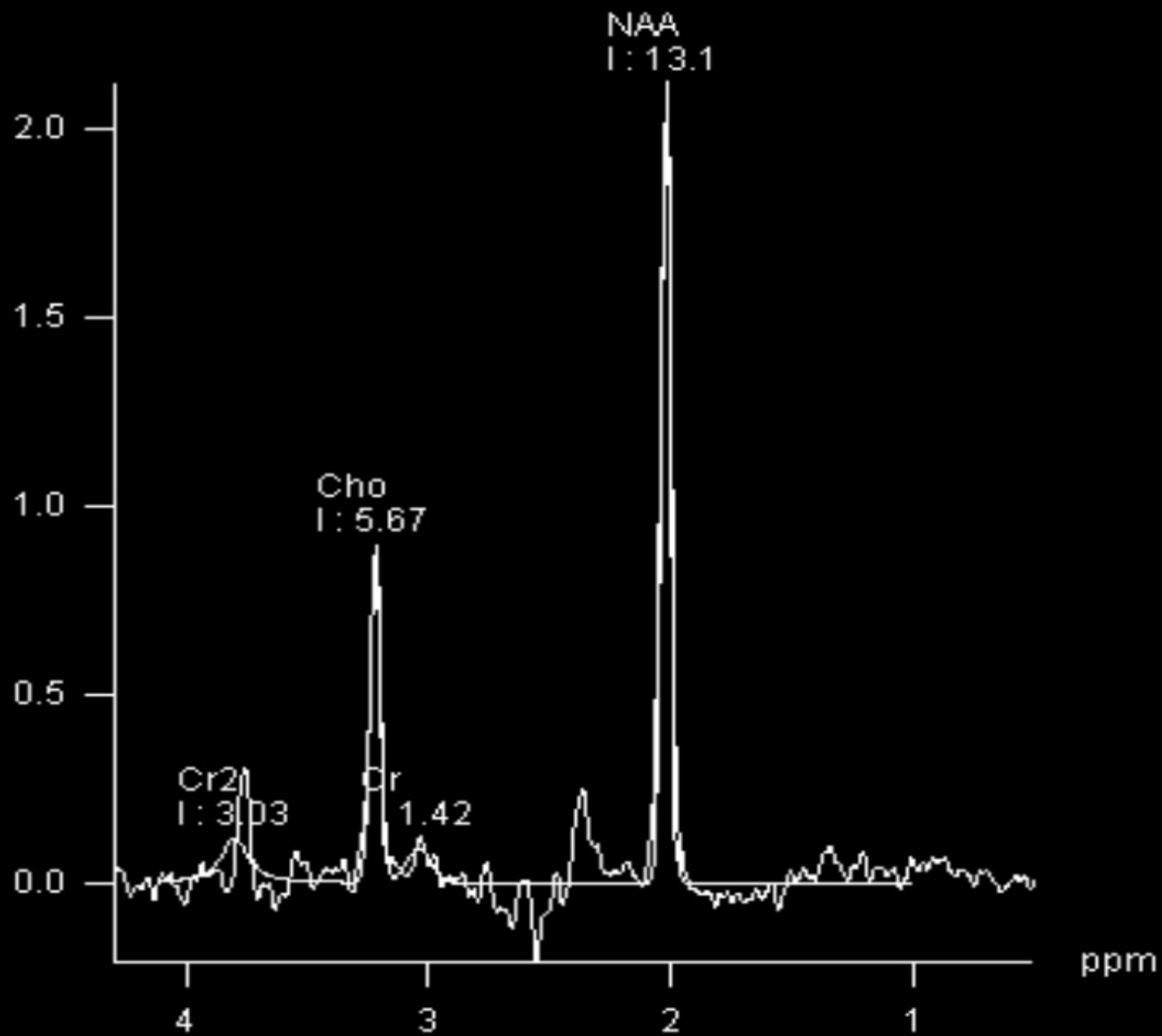
- Resonates at 3.0 ppm chemical shift.
- Important in the storage and transfer of energy
- Relatively constant level.
- Convenient internal standard (ratio calculations)

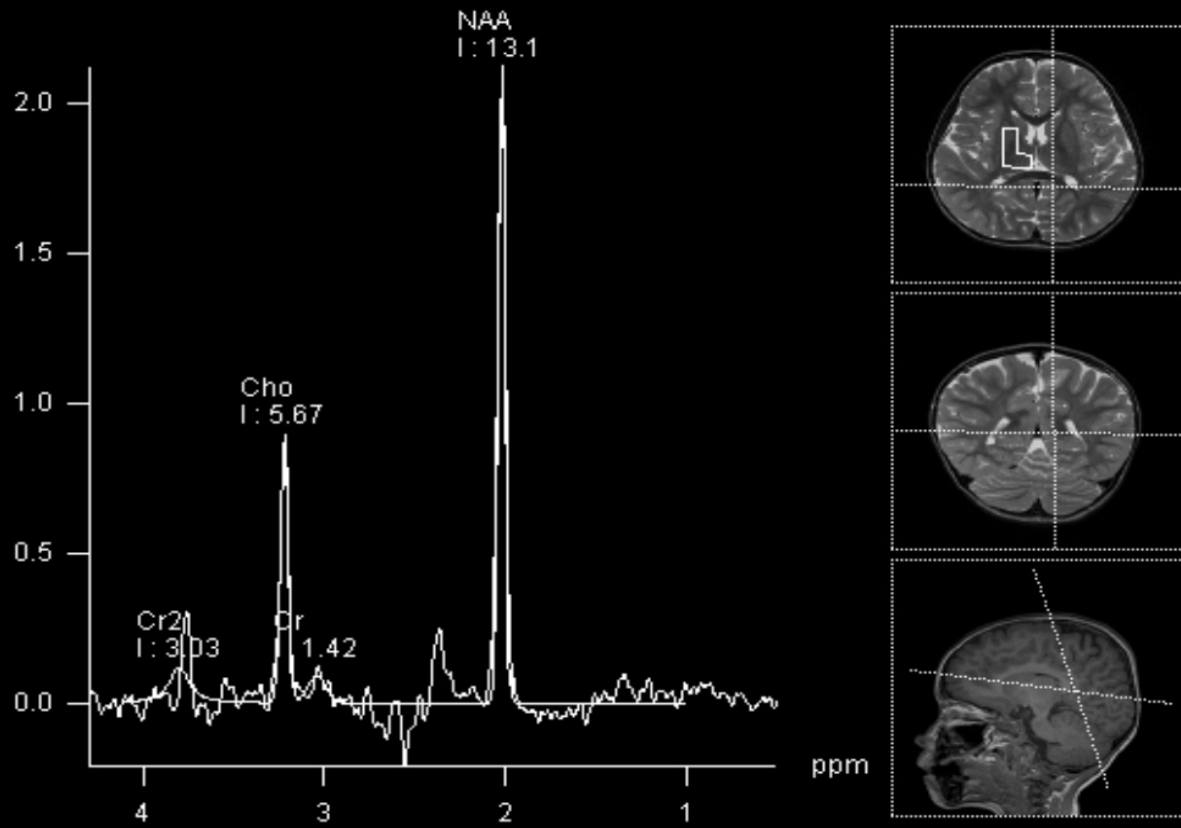


CASE 2

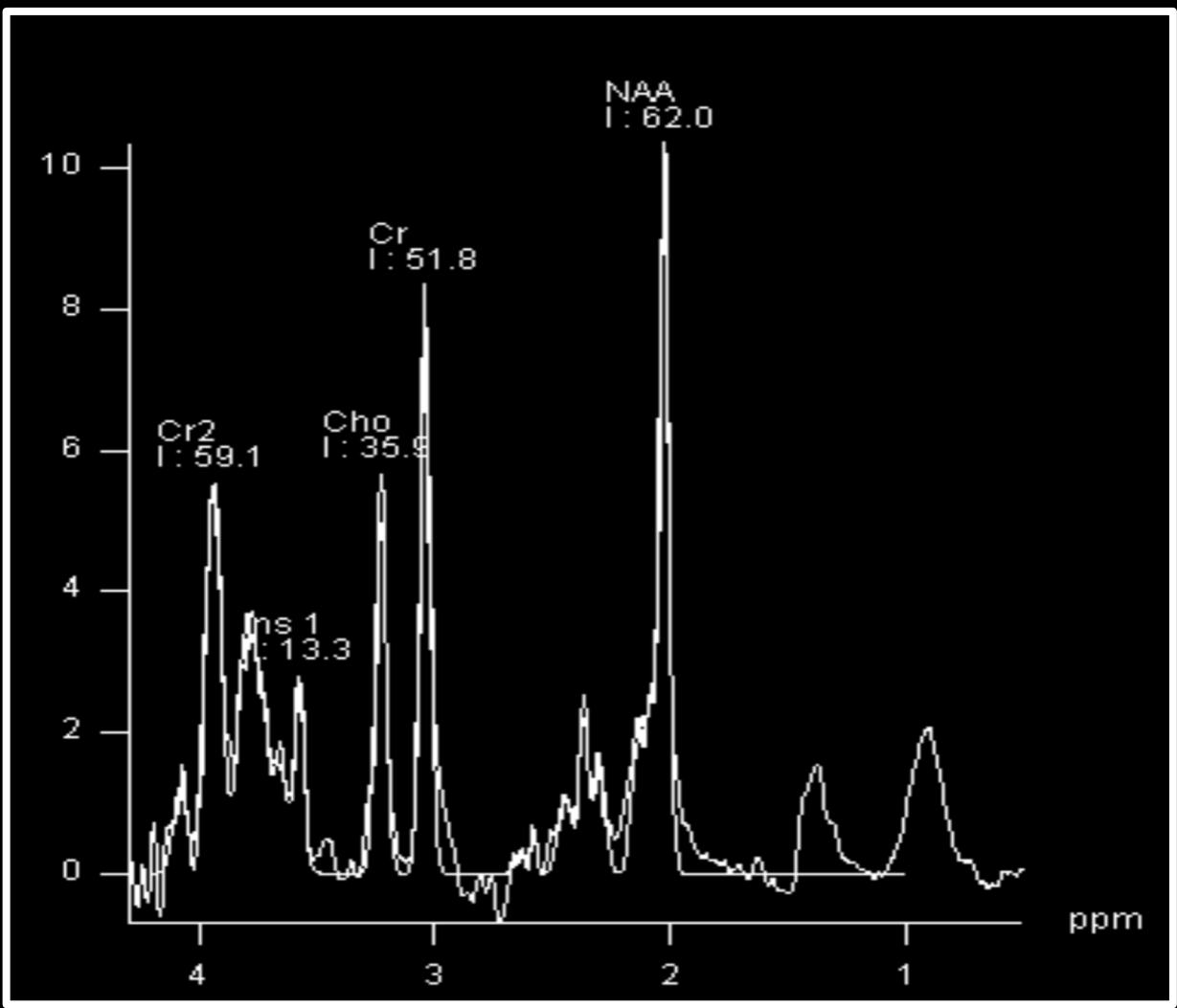
5 yeas-old Male patient: Autism Spectrum Disorder- Developmental delay and speech-language disorder



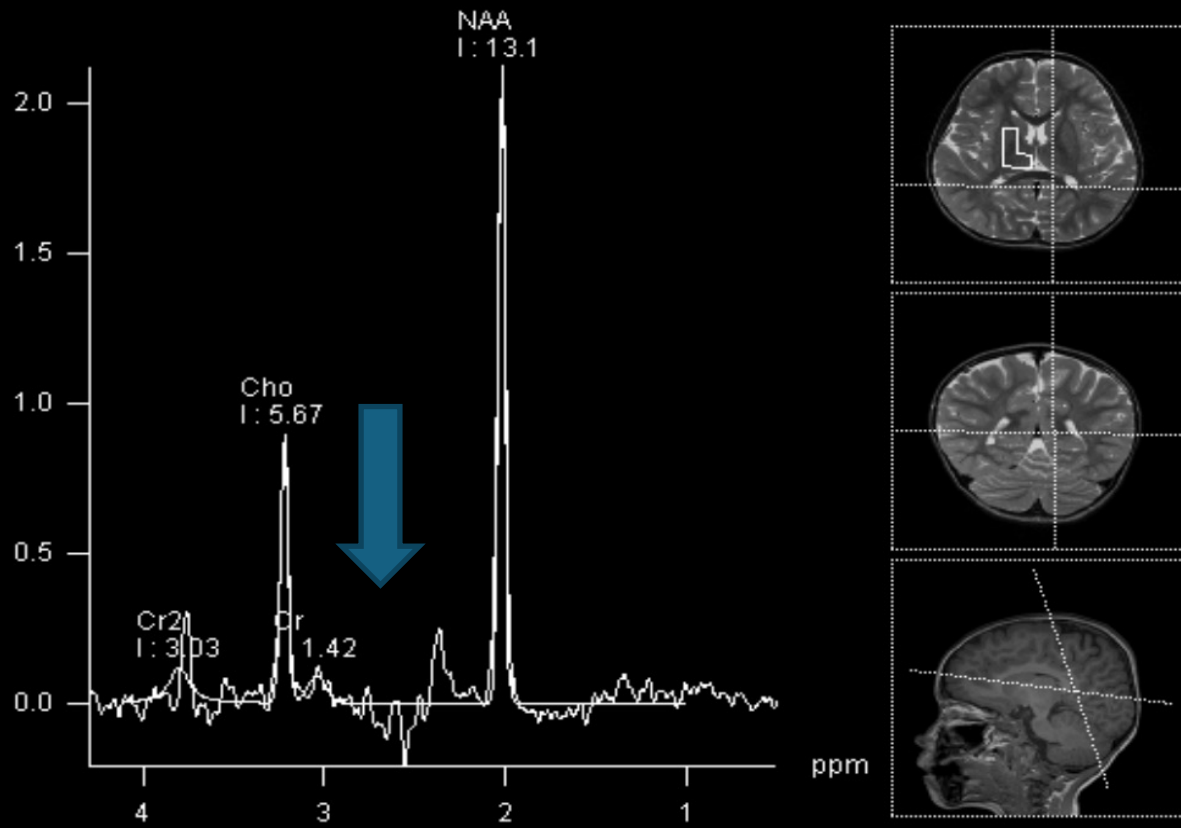




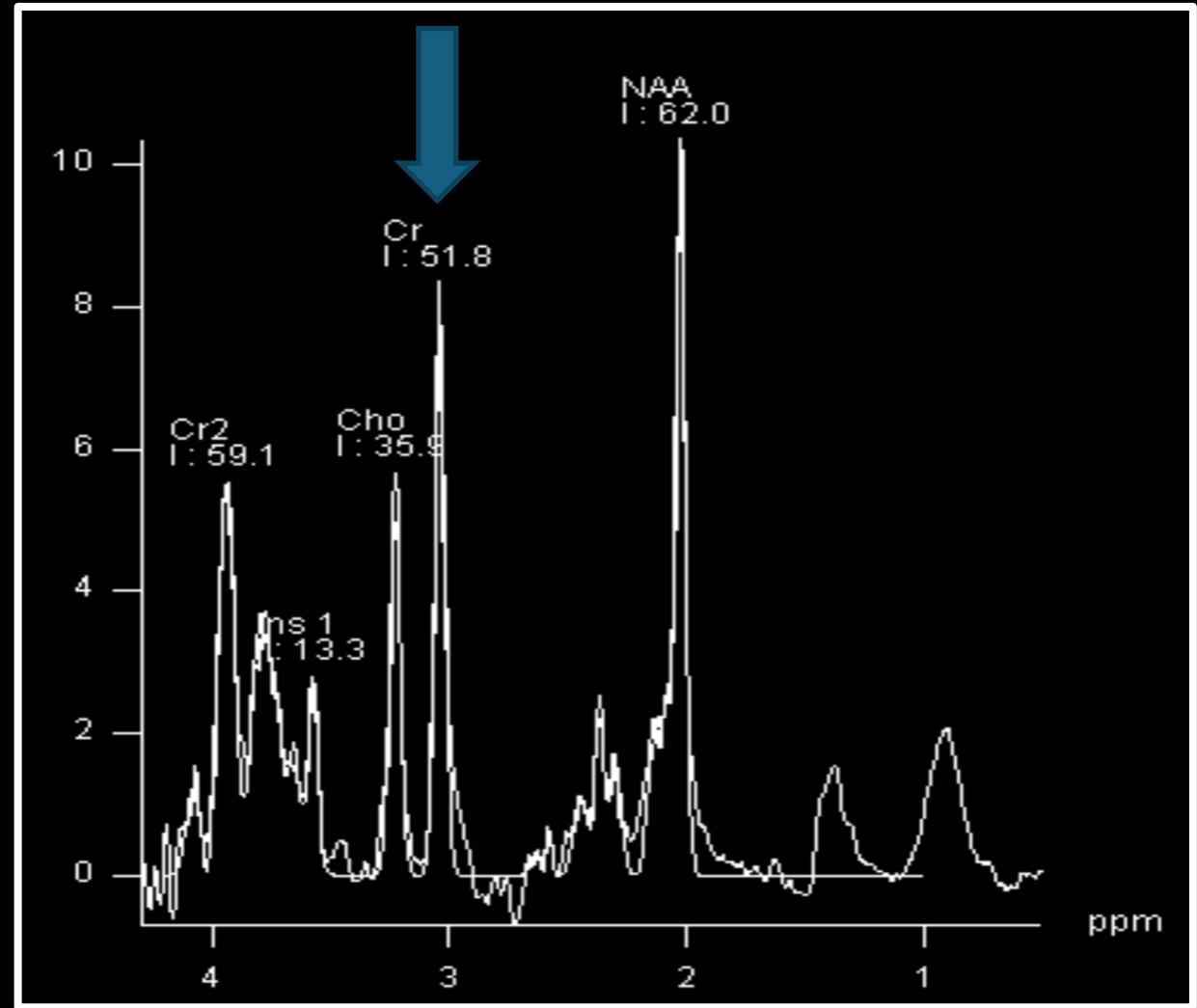
NORMAL



X-linked creatine transporter deficiency- *SLC6A8* path. variants



NORMAL



Creatine Deficiency Disorders

Feature	GAMT Deficiency ¹	AGAT Deficiency ²	CRTR Deficiency ³
DD & cognitive dysfunction ⁴	●●●	●●●	●●●
Speech-language disorder	●●	●●	●●
Seizure	●●	●	●●
Epilepsy	●●	NR	●●
Behavior problems	●●	●	●●
Muscle weakness / Myopathy	NR	●●	NR
Hypotonia	●	●	●●
Movement disorder	●	NR	●

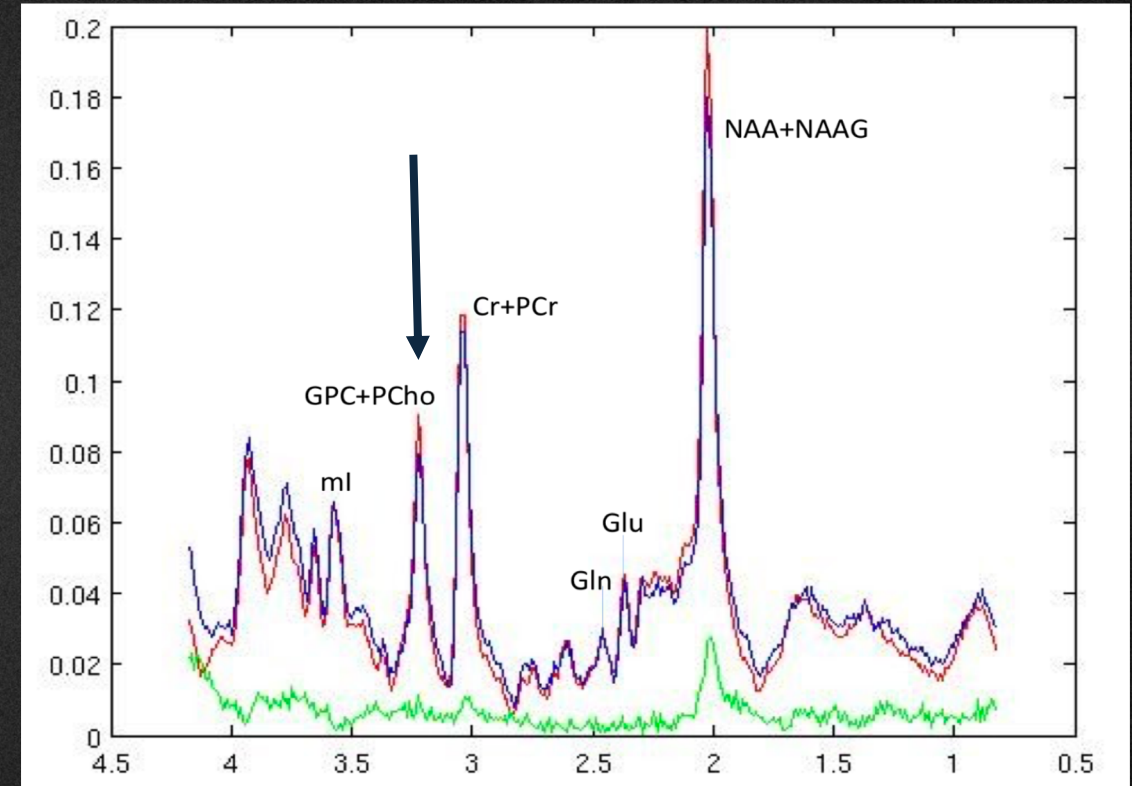
1. Creatine biosynthesis disorders Guanidinoacetate methyltransferase (GAMT) deficiency

2. L-arginine: glycine amidinotransferase (AGAT) deficiency

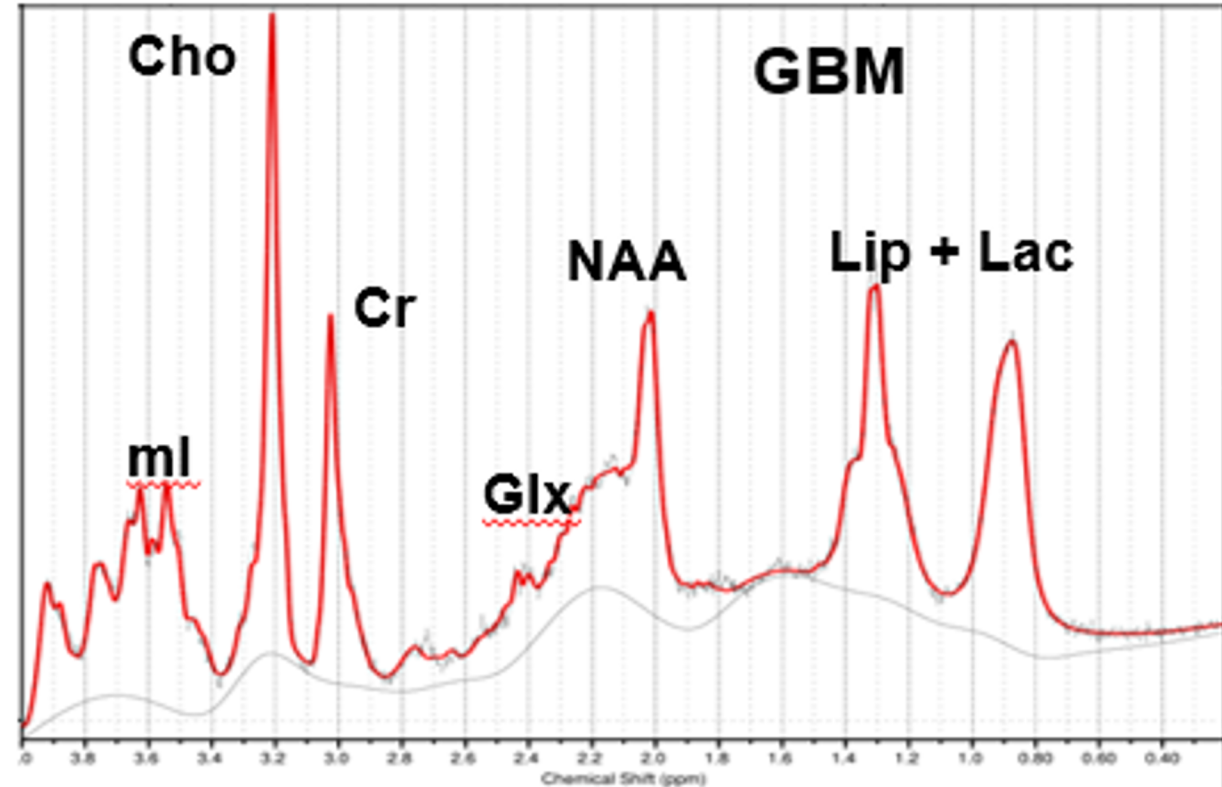
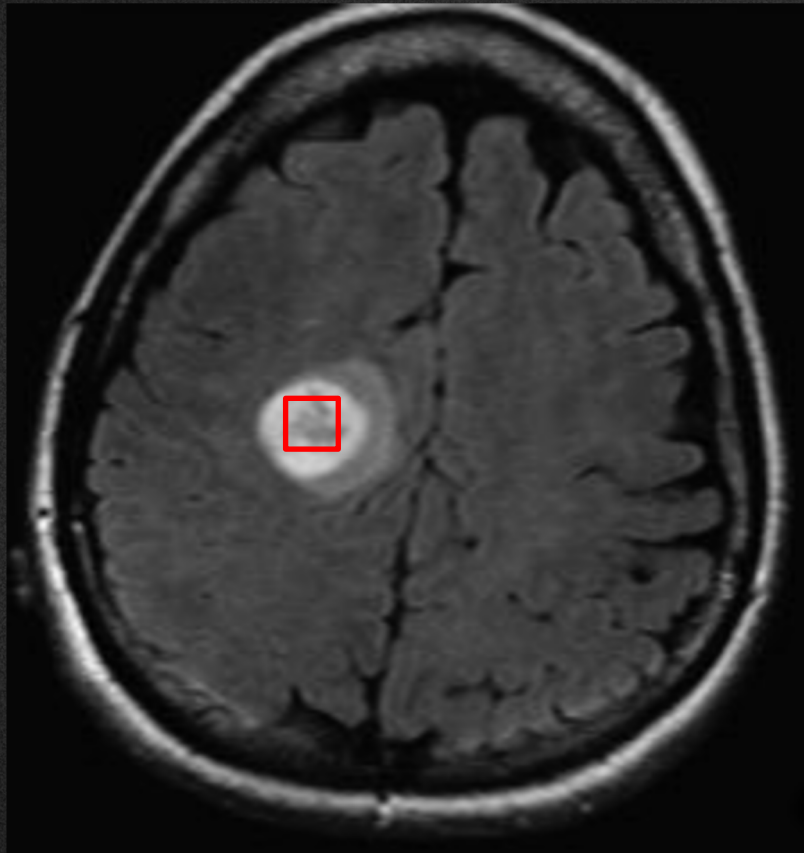
3. Creatine transporter (CRTR) deficiency (X-linked) *SLC6A8 path. variants*

Choline

- Resonates at 3.2 ppm chemical shift.
- **Marker of cellular membrane turnover**
- Elevated in neoplasms, demyelination, inflammation, and gliosis.
- High choline peaks in infant's brain due to active myelination



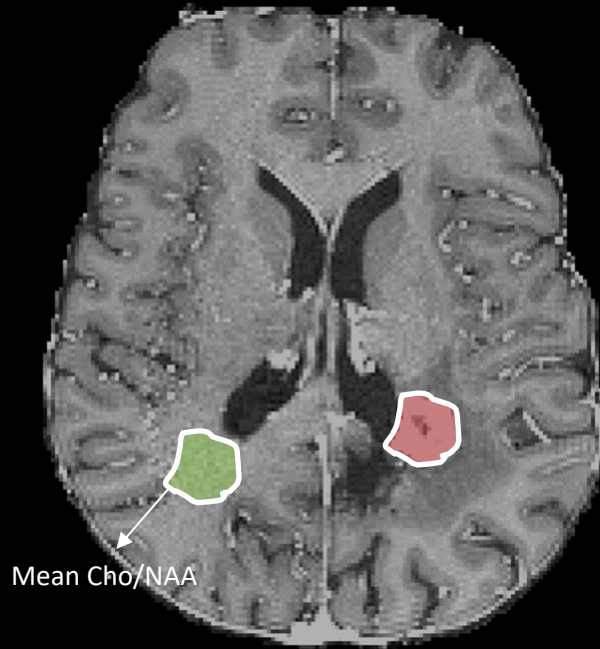
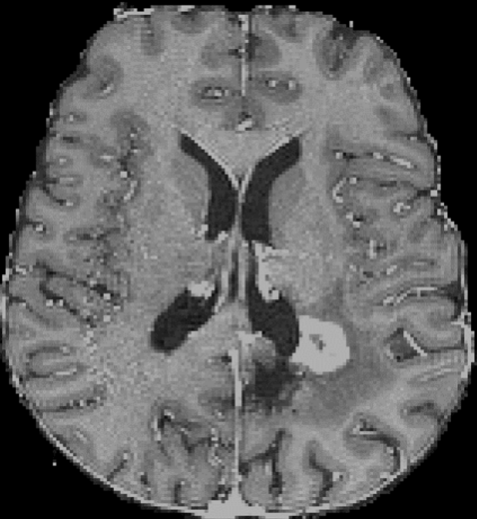
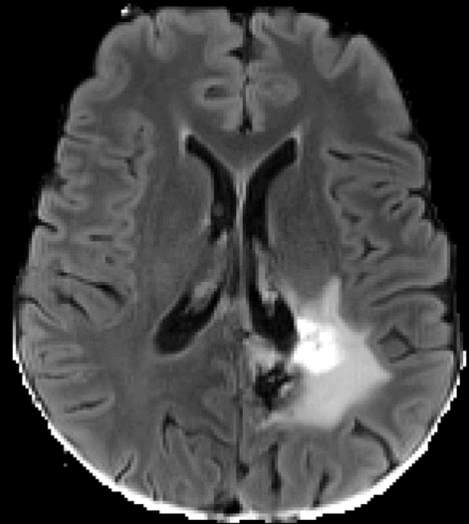
MRS- Brain Tumor



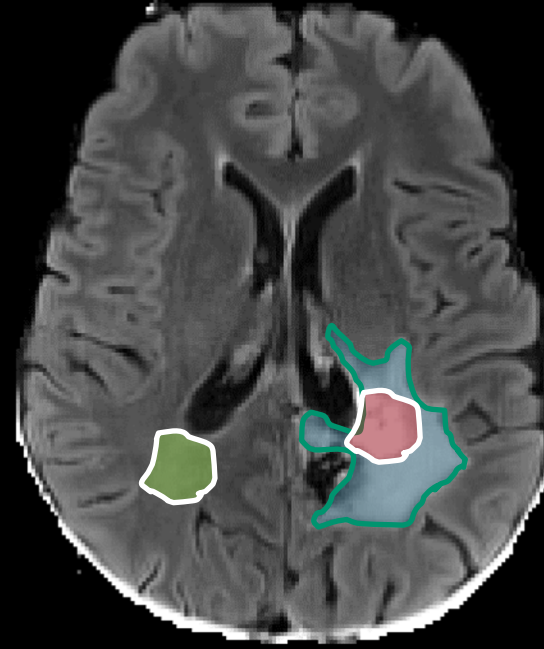
Metabolite pattern of a high-grade glioma: Elevation in choline, decrease in NAA and variable alterations in the signals of lipids + lactate

MRS- Brain Tumor Progression

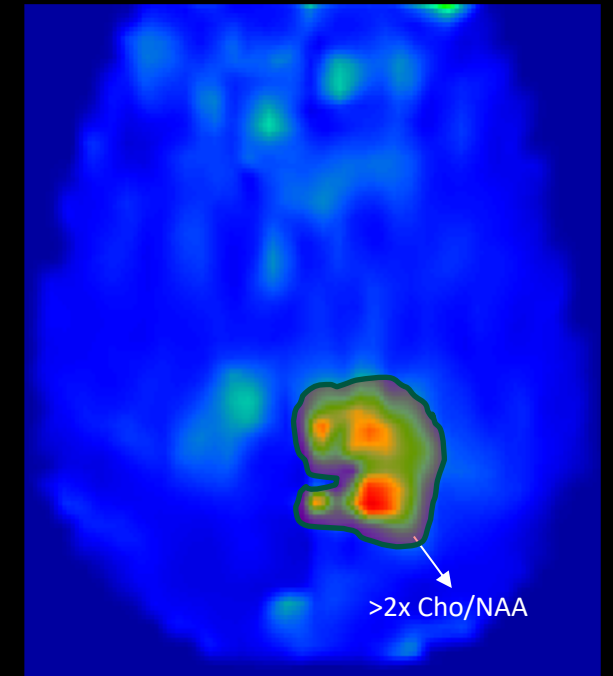
European Course on
Pediatric Neuroradiology in
Latin America (ECPNR-LATAM)
3rd Cycle - Module 1



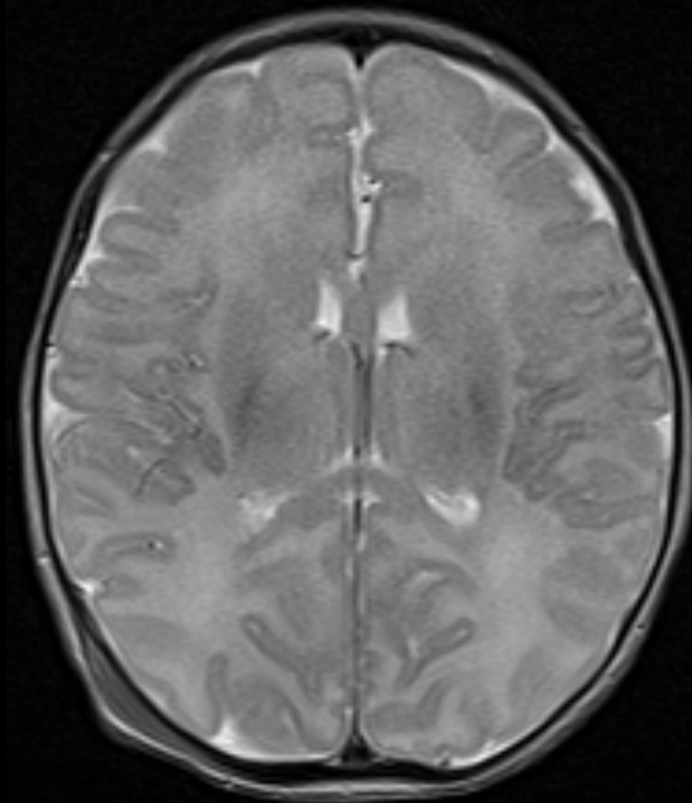
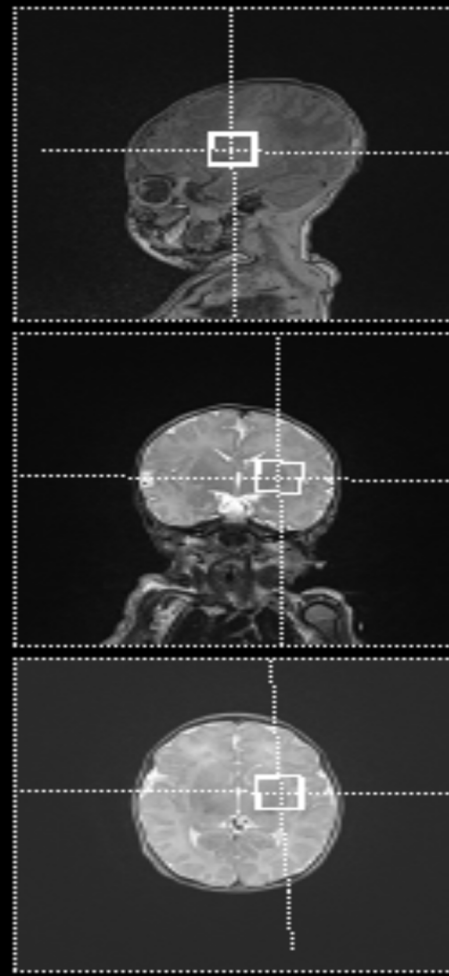
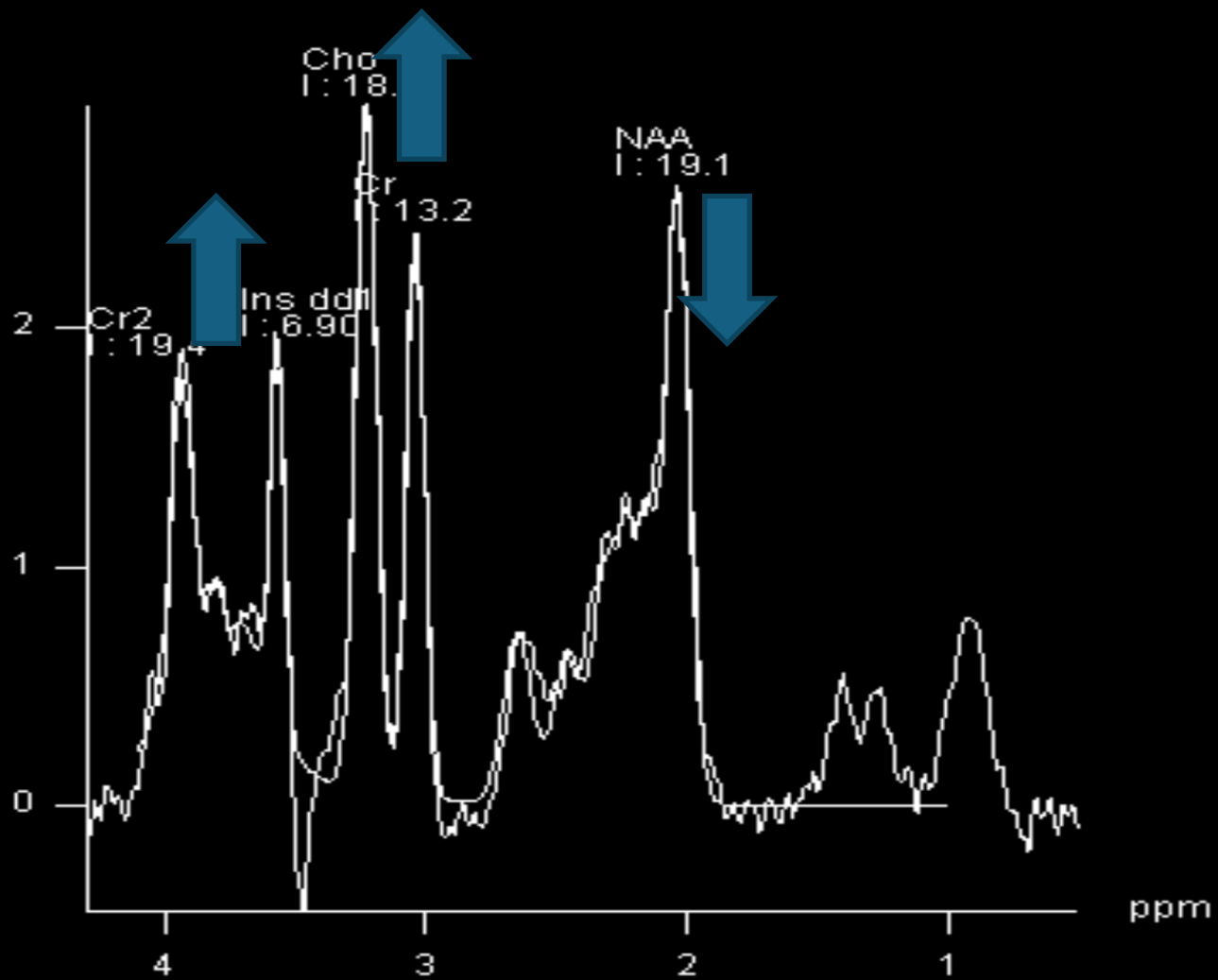
Tumor mask



Metabolic mask



NEWBORN- NORMAL

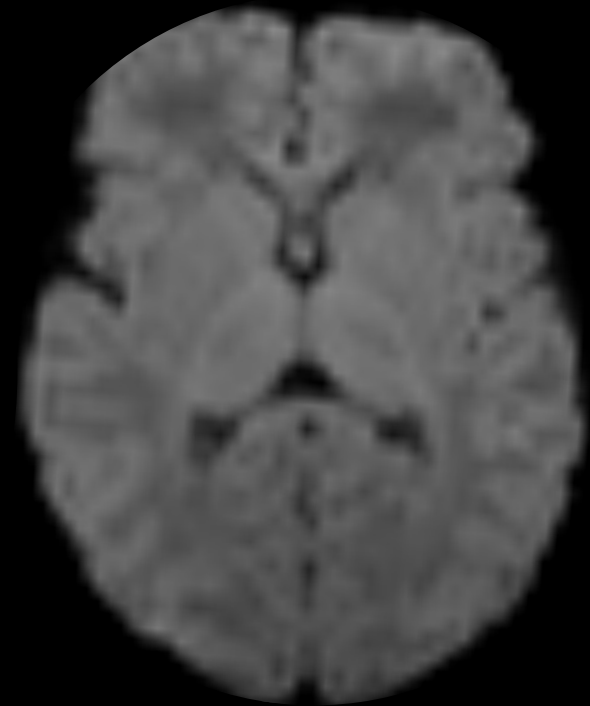
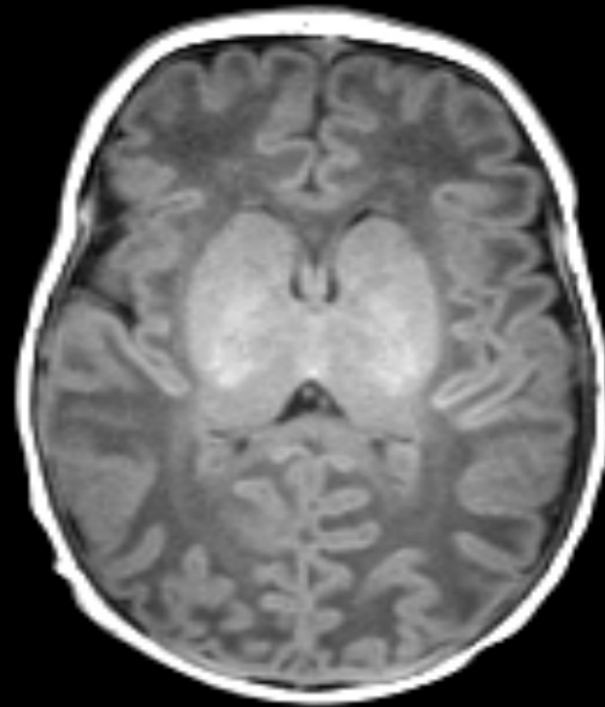
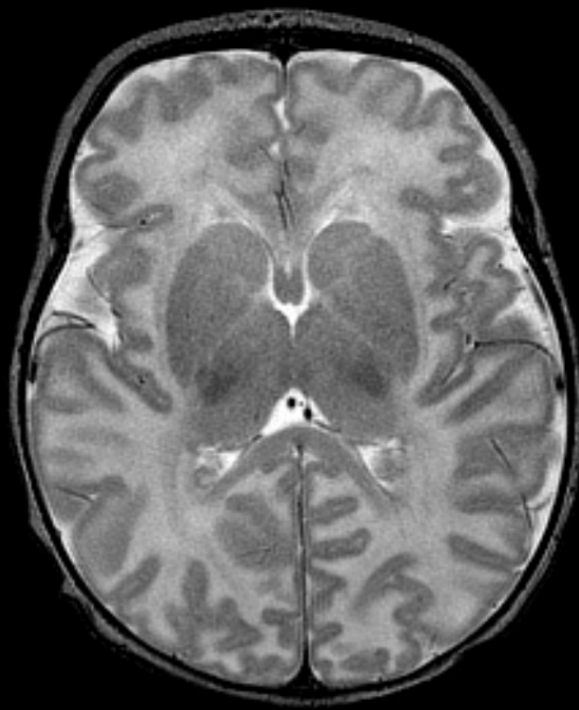
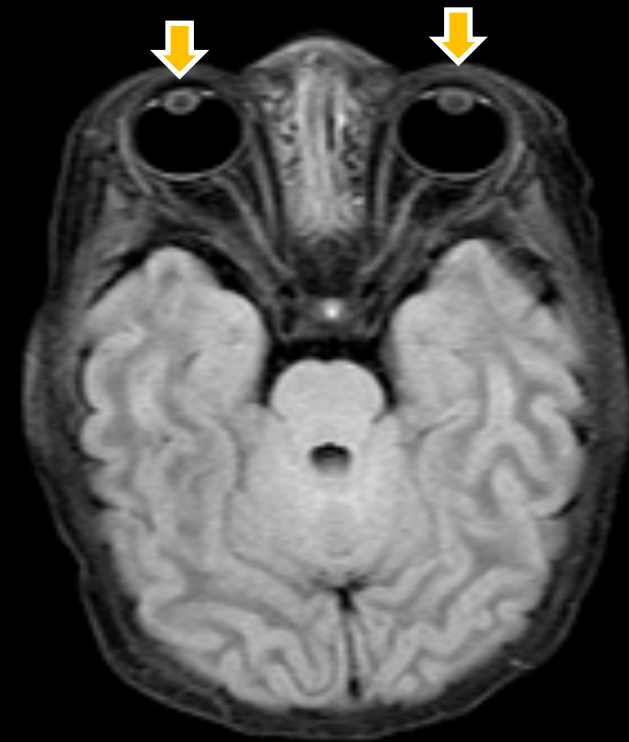


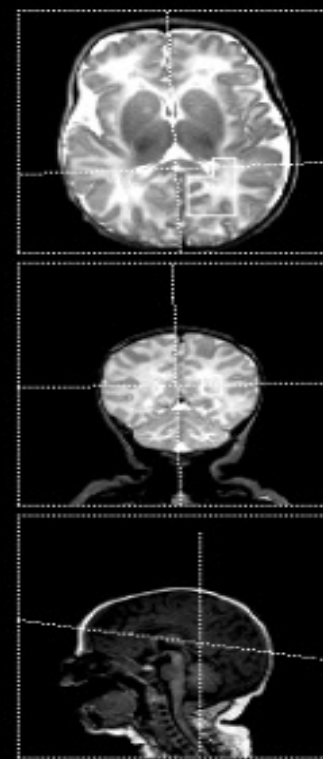
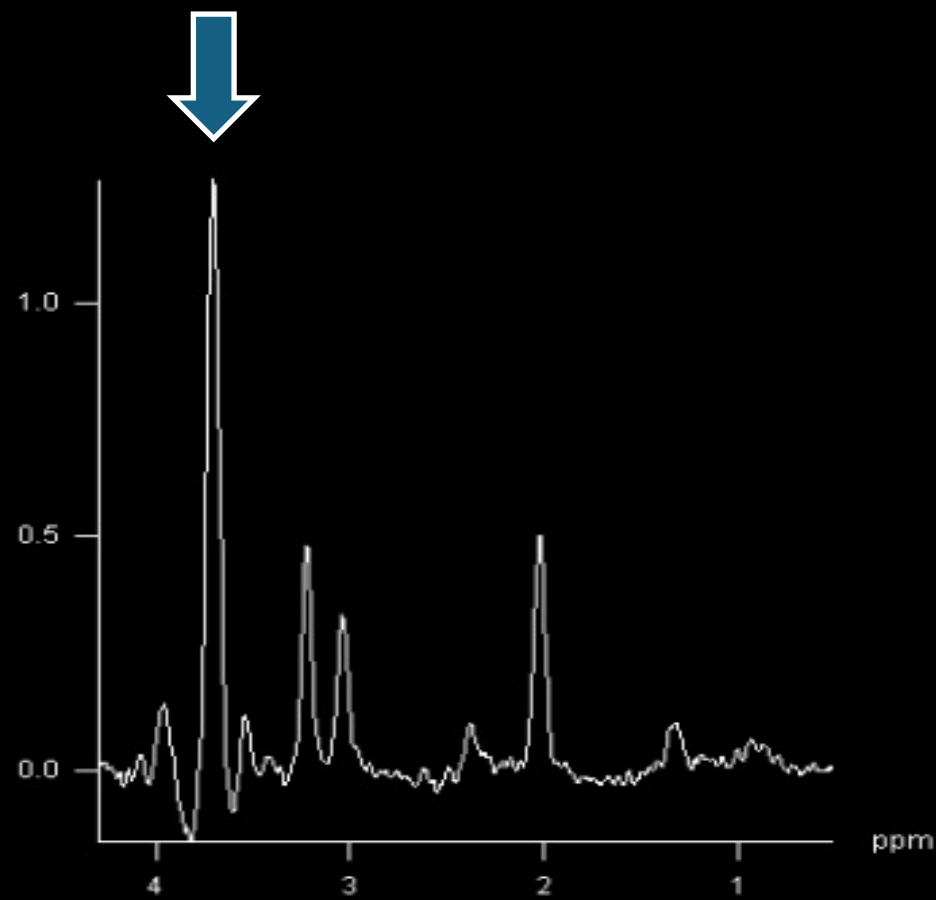
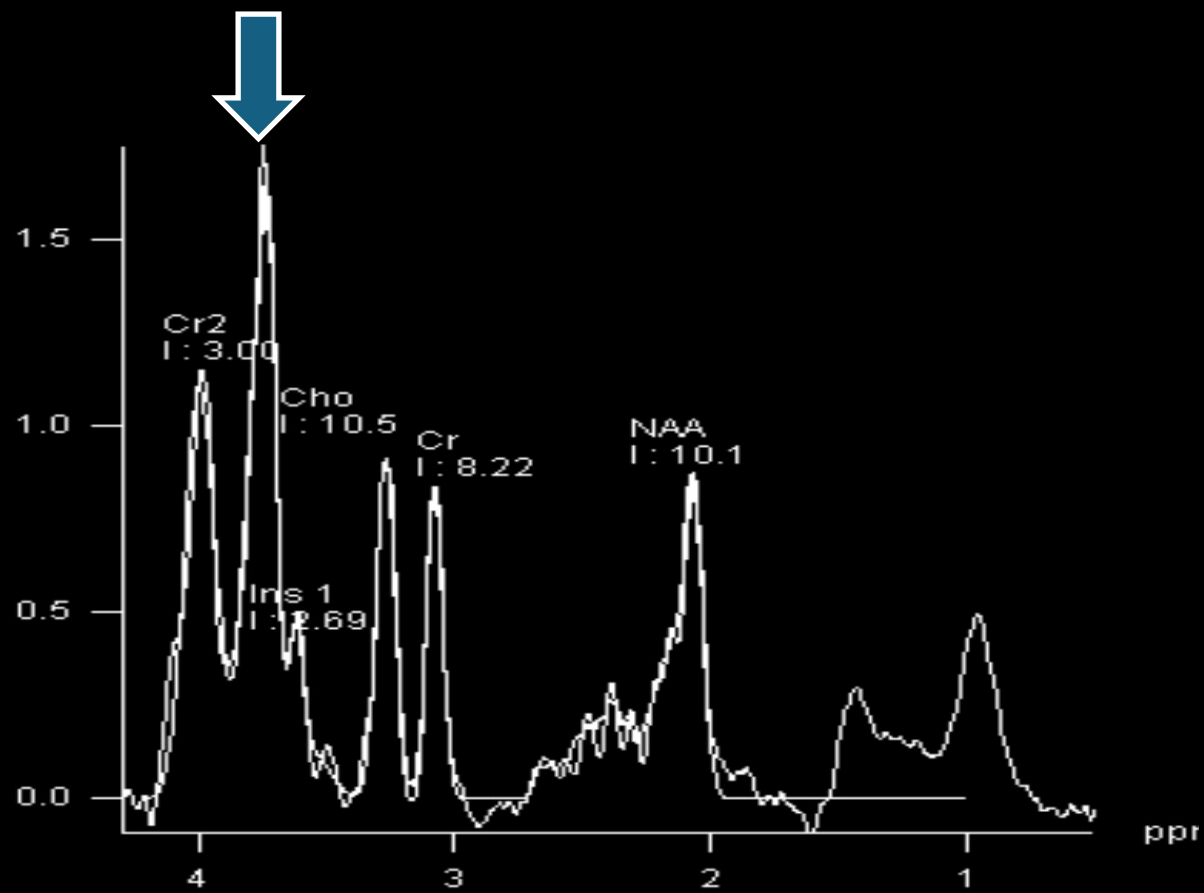
NEUROMETABOLIC DISORDERS WITH ABNORMAL PEAKS

CASE 3

- 1 month-old female patient: loses appetite, cataracts, and vomiting

Cataracts



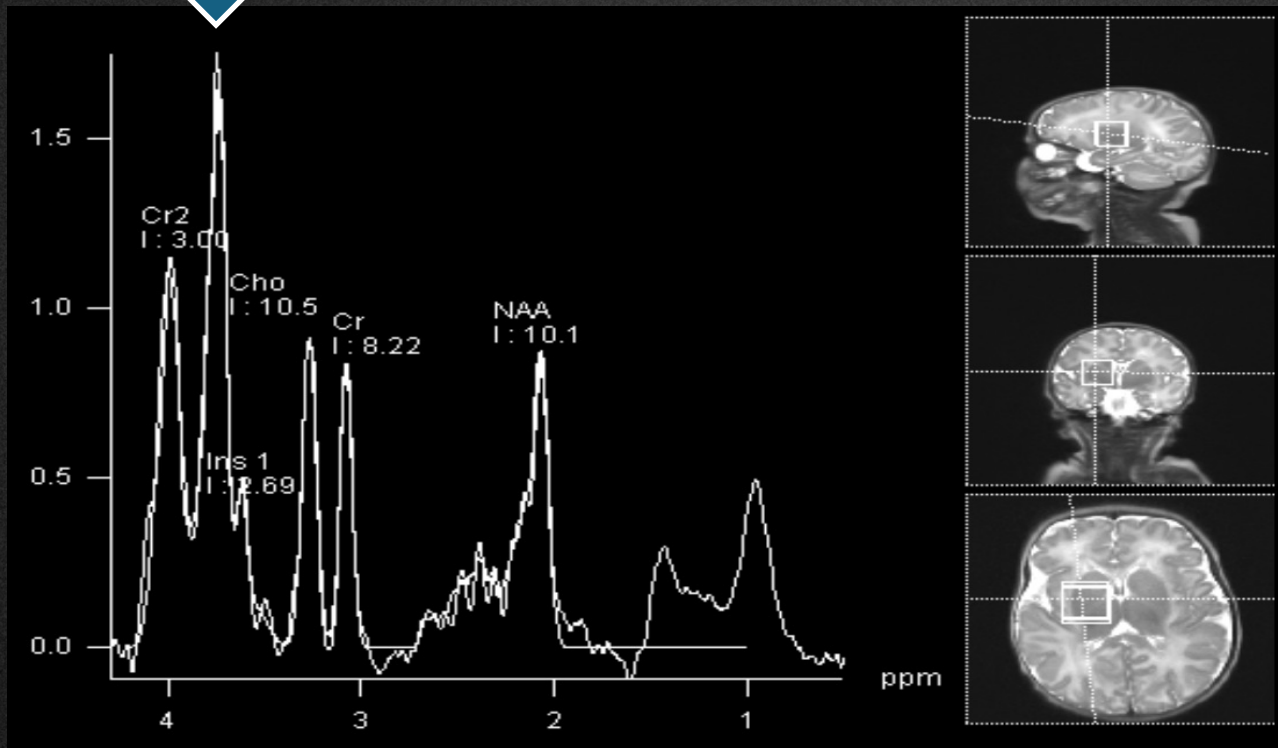


Galactosemia

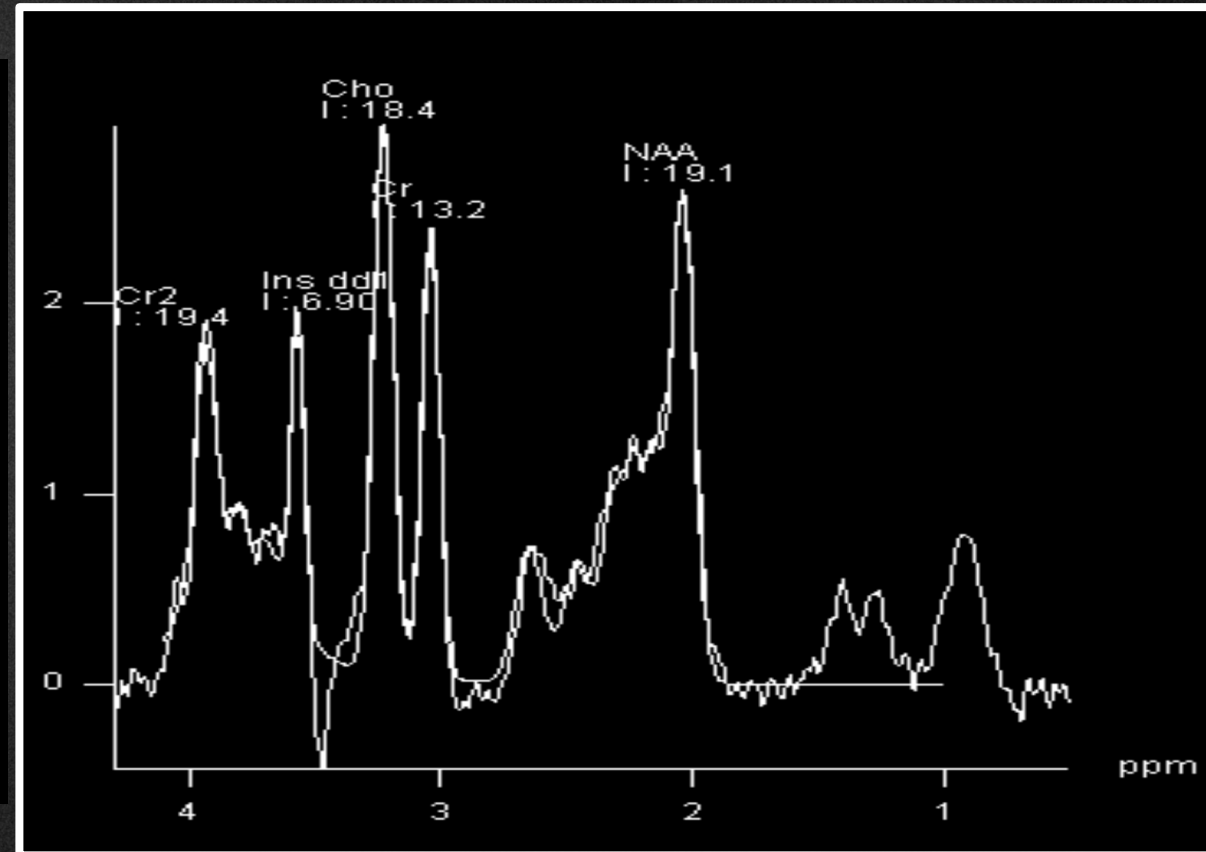
(aldose reductase deficiency)



Galactitol peak



NORMAL- Neonate



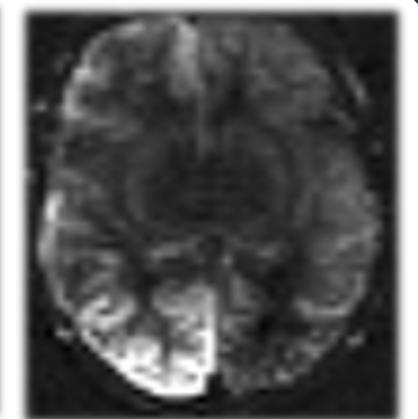
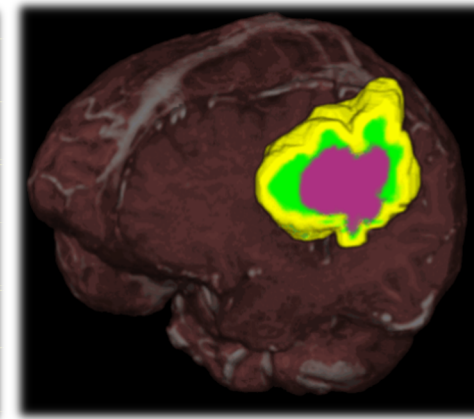
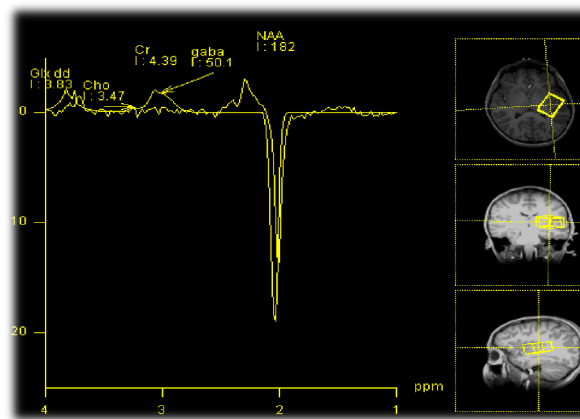
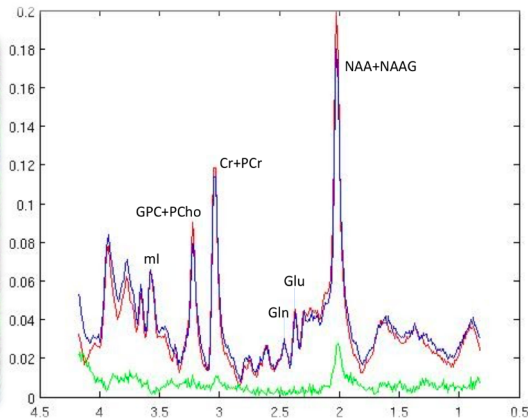

MRI from Microstructure to Function: *DTI, Perfusion, ASL, MRS*

European Course on
Pediatric Neuroradiology in
Latin America (ECPNR-LATAM)
3rd Cycle - Module 1

DTI

MRS

ASL



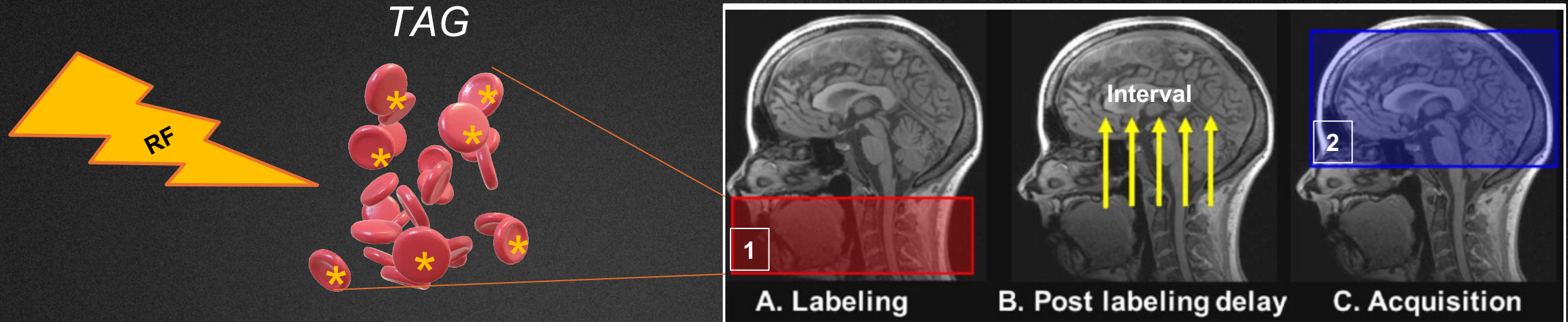
Technique

Non-Invasive technique to evaluate cerebral blood flow without use of contrast agents.

NEAR-INFRARED SPECTROSCOPY

SONOGRAPHY + CEUS

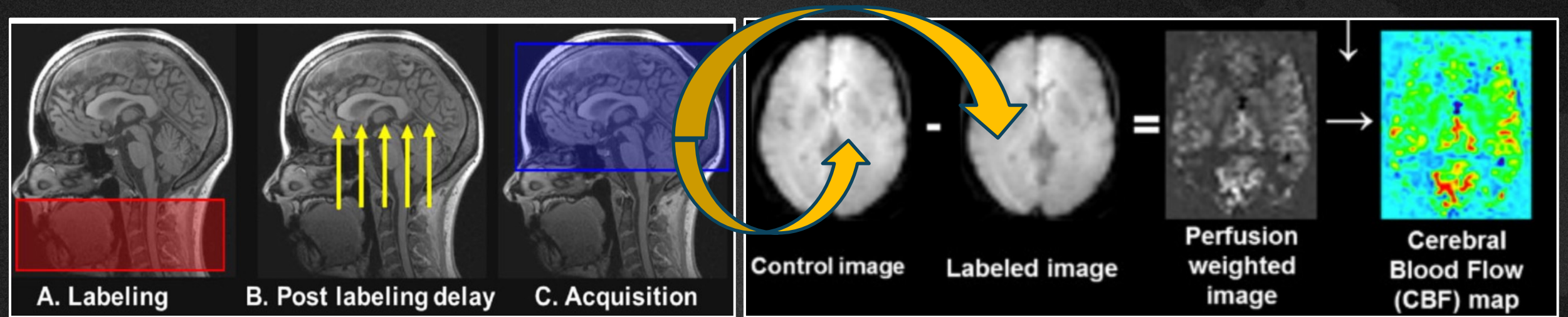
Arterial Spin Label (ASL)



Ferre, J et. A. Arterial spin labeling (ASL) perfusion: Techniques and clinical use. *Diagnostic and Interventional Imaging*, 2013. 10.1016/j.diii.2013.06.010


- Continuous ASL
- Pulsed ASL
- Short-TR ASL
- Velocity selective ASL
- Multi-PLD ALS
- **pCASL (Pseudo-Continuous)- higher signal to noise ratio and better labeling efficiency compared to earlier ASL techniques**

Arterial Spin Label (ASL)



Ferre, J et. A. Arterial spin labeling (ASL) perfusion: Techniques and clinical use. *Diagnostic and Interventional Imaging*, 2013. 10.1016/j.diii.2013.06.010

LOW SIGNAL RATIO



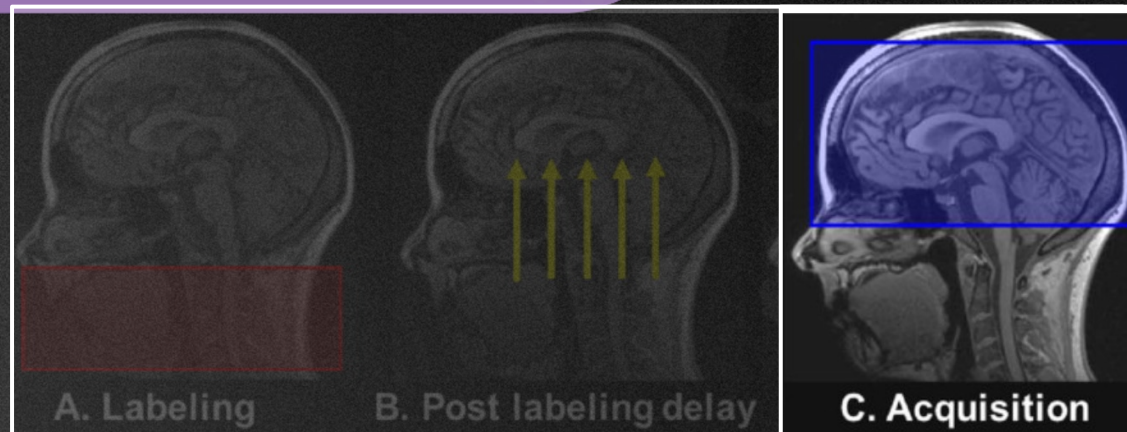
MULTIPLE REPETITIONS

3T > 15.T

ASL- AGE: DIFFERENT PARAMETERS

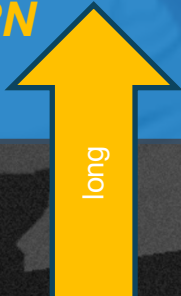
POST-LABELING TIME

Alsop, D.C. et al., 2015. Magn. Reson. Med.



pcASL

NEWBORN
2000 ms



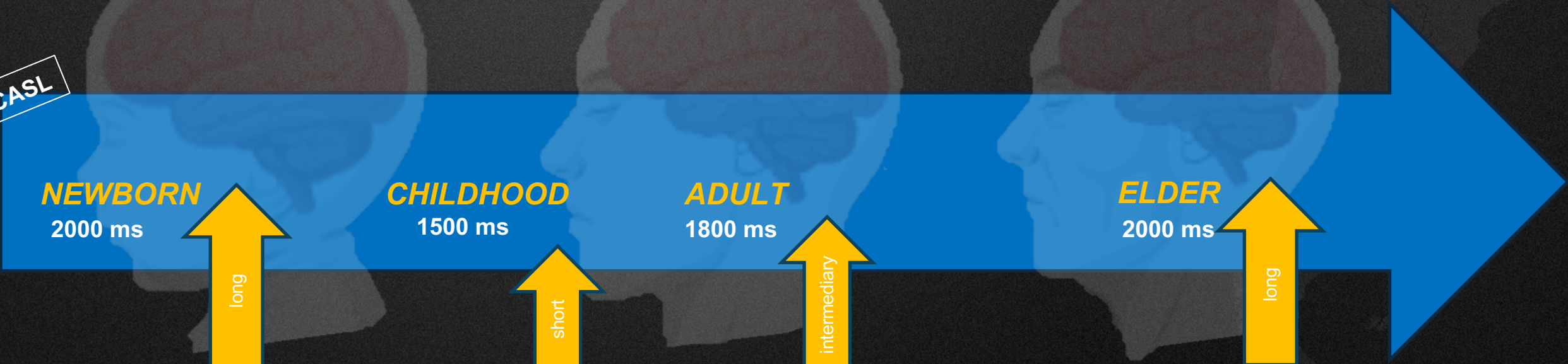
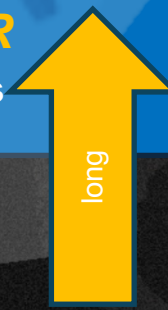
CHILDHOOD
1500 ms



ADULT
1800 ms



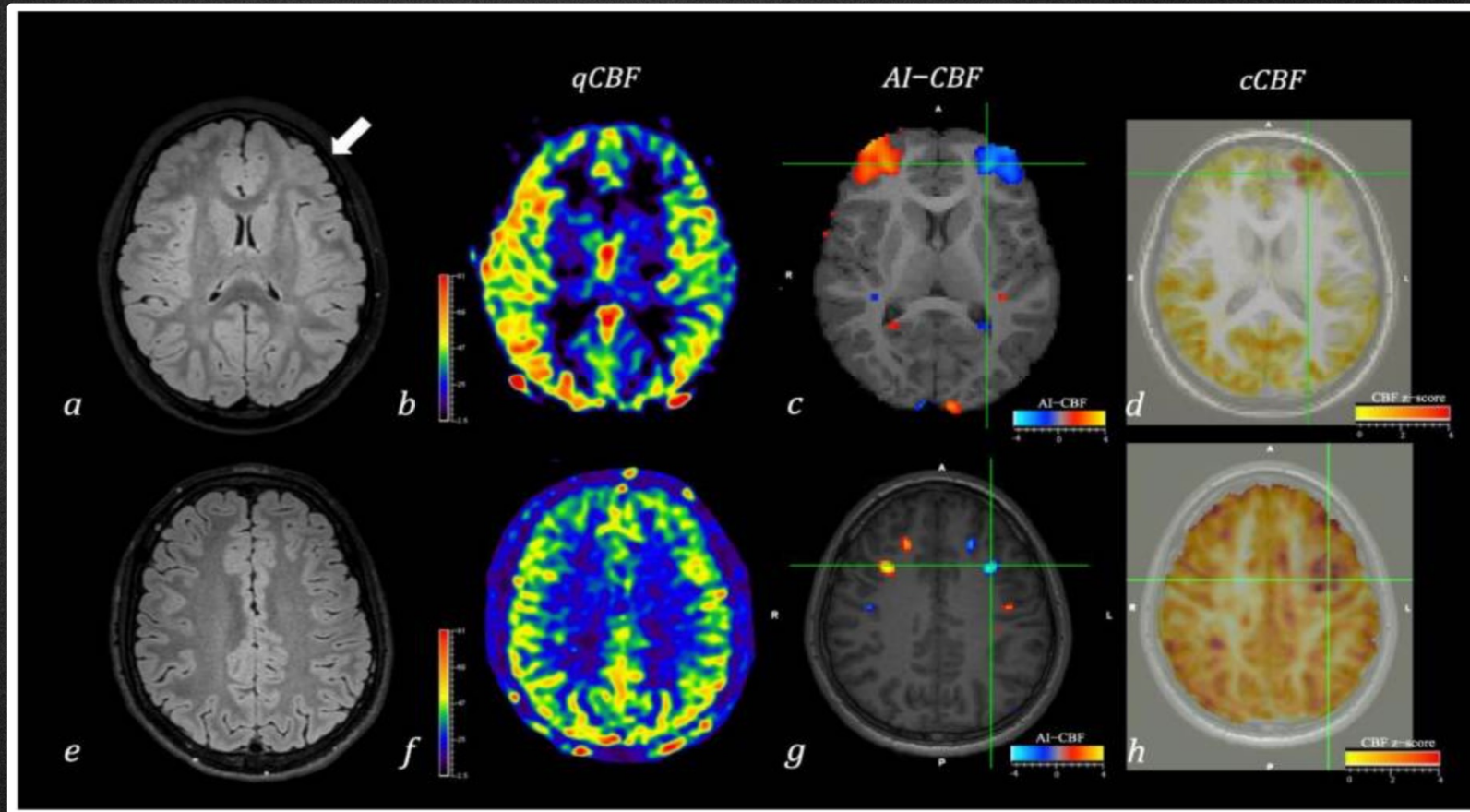
ELDER
2000 ms



Arterial Spin Label (ASL)

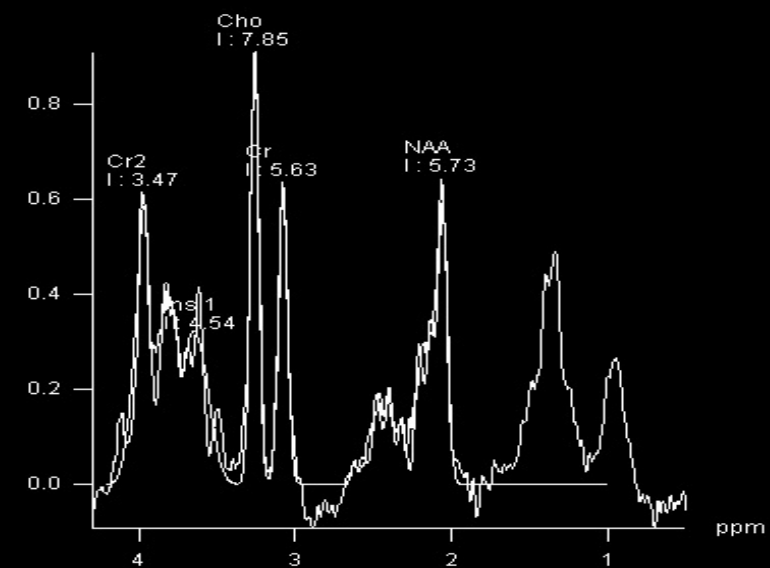
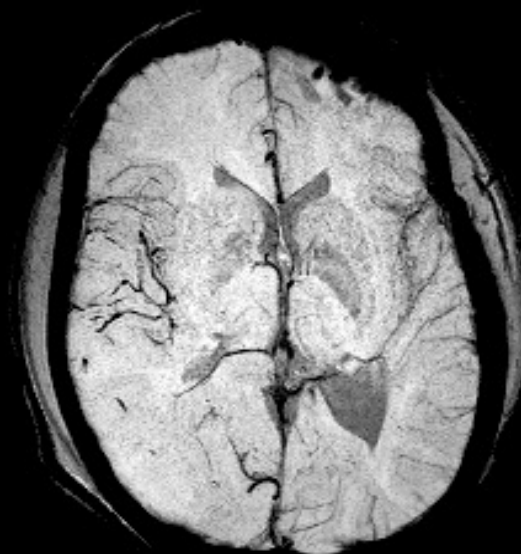
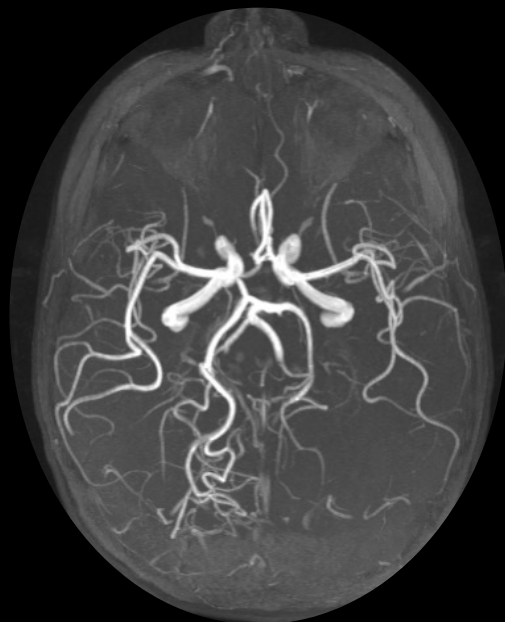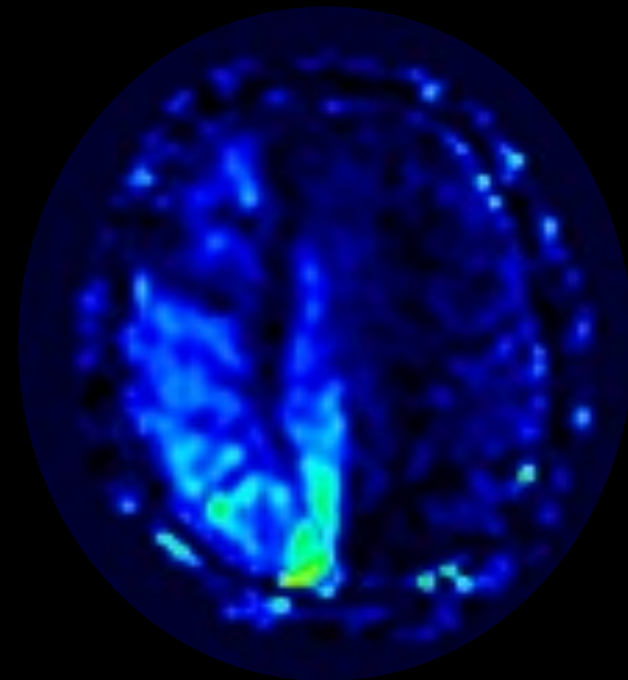
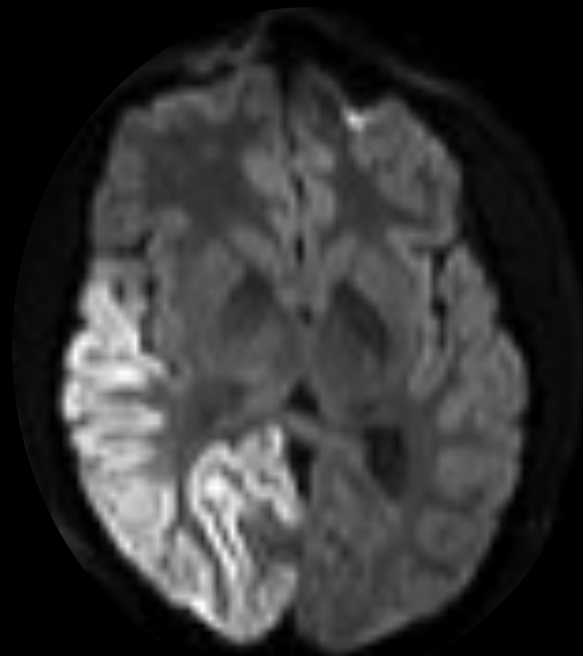
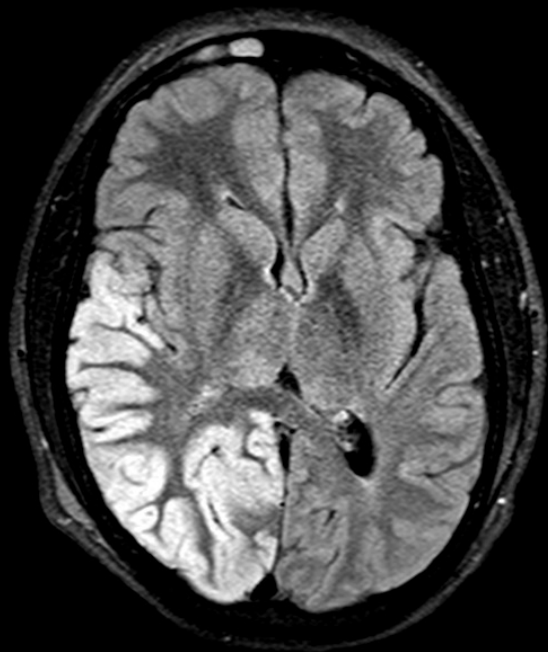
Qualitative VS Quantitative Analyses

MR-Arterial Spin Labeling Perfusion Data Pediatric Patients with Focal Epilepsies



CASE 1

Male, 8 years old developmental delay, hypotonia and new vision loss with suggestive acute stroke-like episode



MELAS Synd.

Mitochondrial Encephalopathy, Lactic Acidosis, and Stroke-like episodes

= ***MT-TL1; 3243 A>G***

6 months later

STABLE CLINICALLY BUT RECENT VISUAL WORSENING

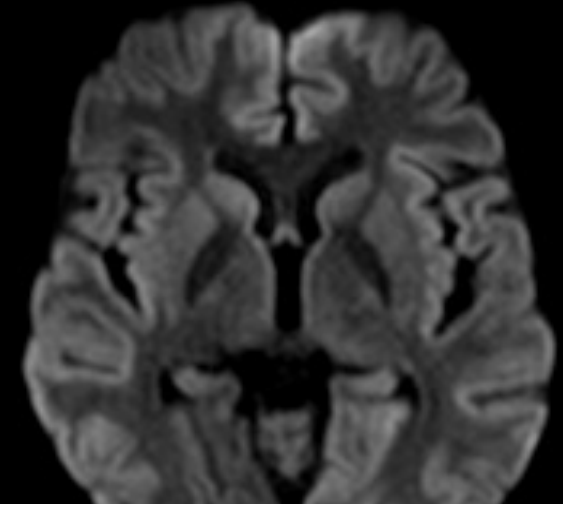
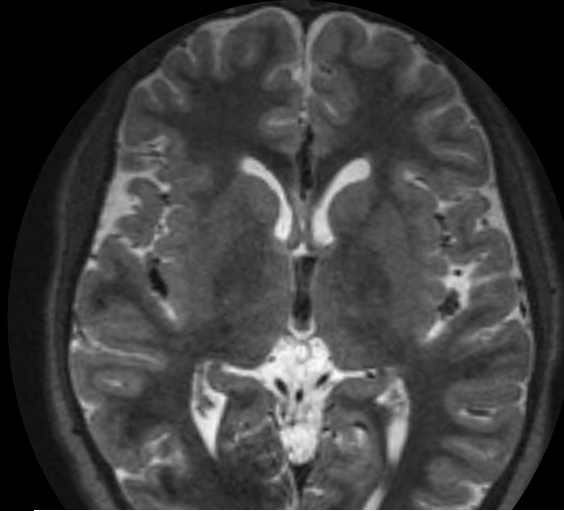
6 months later

“IS THIS PATIENT CLINICALLY STABLE OR IN CRISIS?”

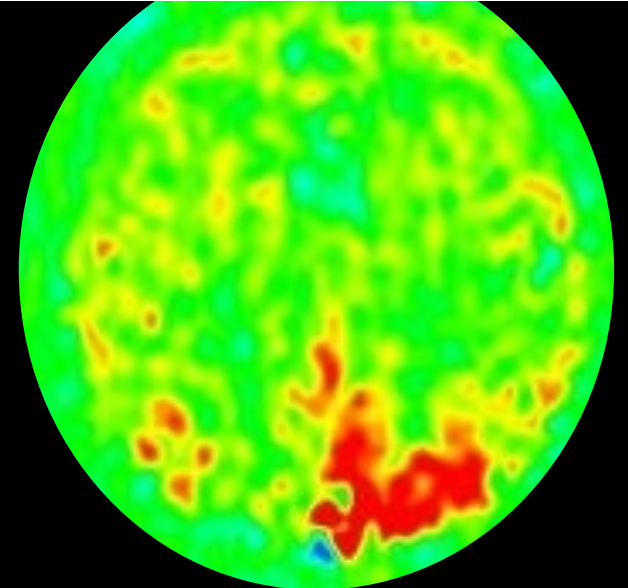
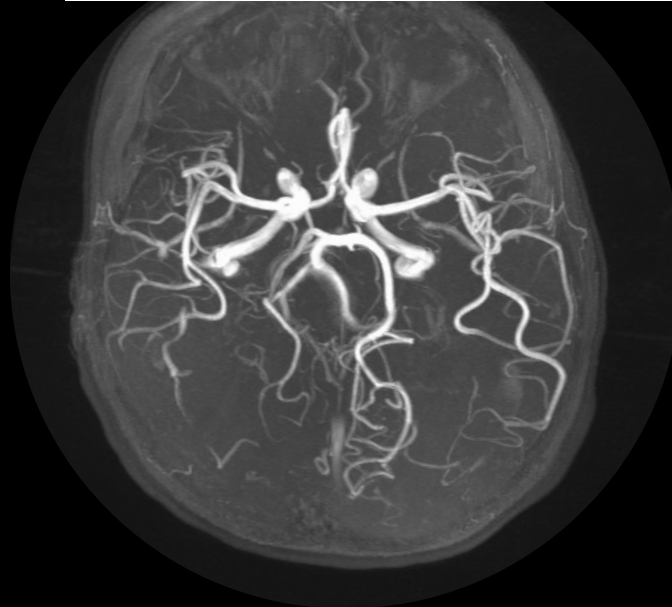
“SHOULD WE CONSIDER START SOME TREATMENT i.e. ARGININE?”

MELAS Synd.- Mitochondrial Encephalopathy, Lactic Acidosis, and Stroke-like episodes

FU: 6 months later –stable but now with
Questionable new visual abnormality

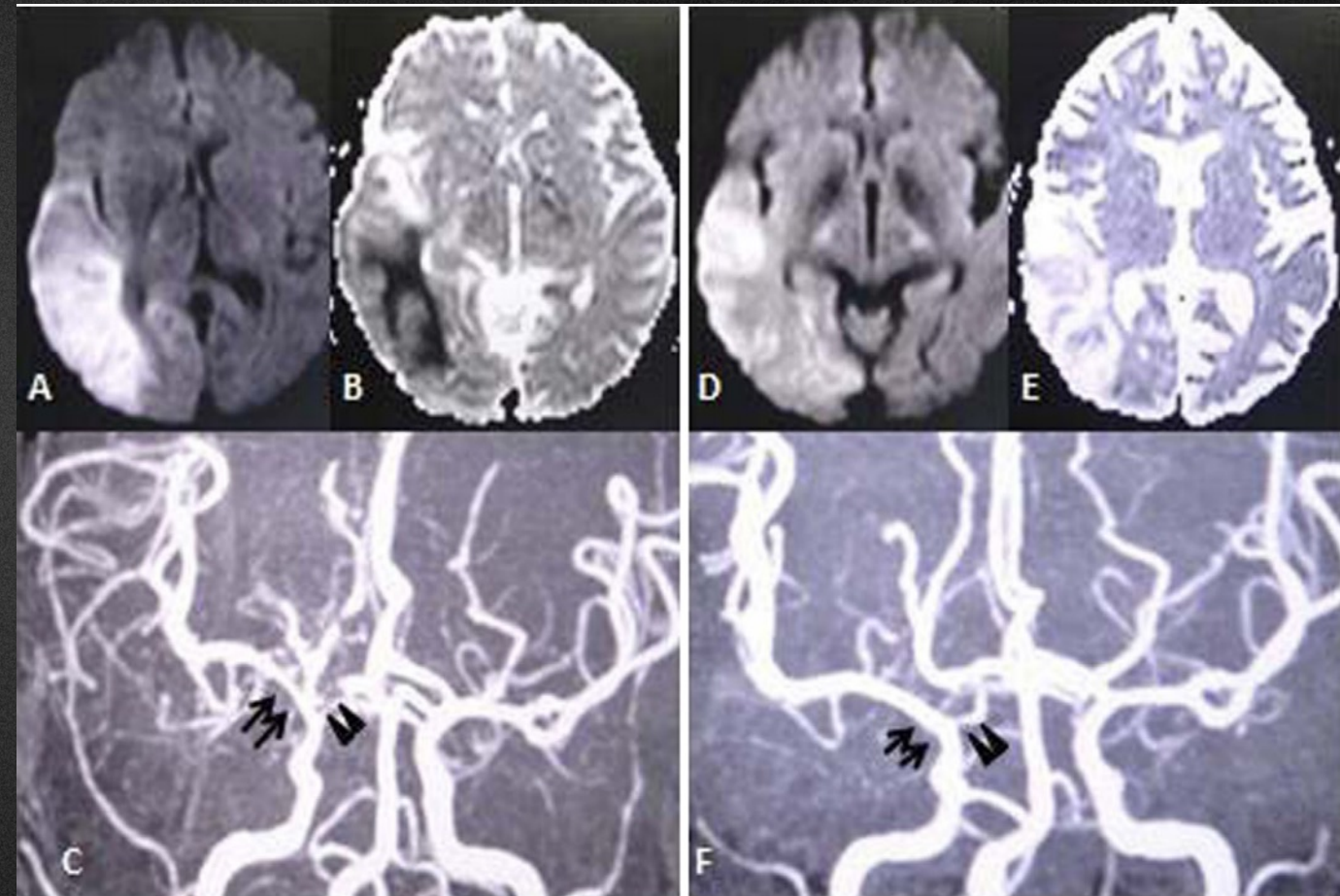
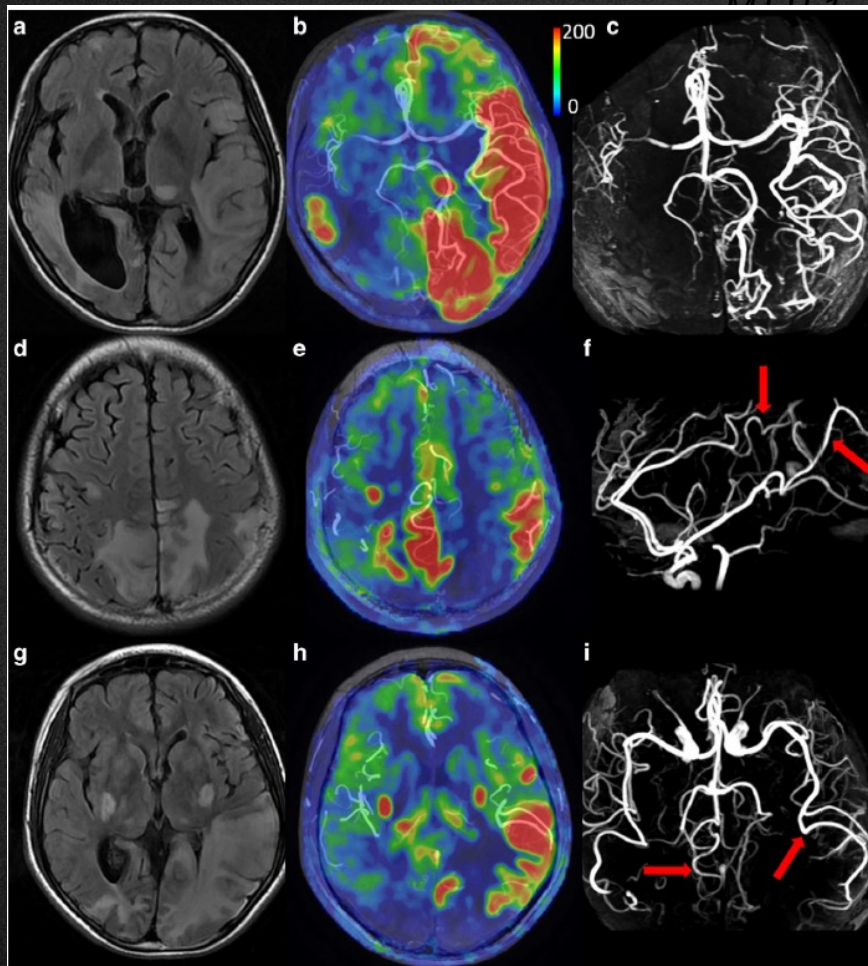


Recent disease activity



MELAS Syndrome

European Course on
Pediatric Neuroradiology in
Latin America (ECPNR-LATAM)
3rd Cycle - Module 1



European Course on
Pediatric Neuroradiology in
Latin America (ECPNR-LATAM)
3rd Cycle - Module 1

Cesar.Alves@childrens.harvard.edu

Idealização:



Organização:

