


Magnetic Resonance Spectroscopy in Children With Developmental Delay: Time to Look Beyond Conventional Magnetic Resonance Imaging (MRI)

Journal of Child Neurology
2021, Vol. 36(6) 440-446
© The Author(s) 2020
Article reuse guidelines:
sagepub.com/journals-permissions
DOI: 10.1177/0883073820978006
journals.sagepub.com/home/jcn


Nikhil Rajvanshi, MBBS¹ , Rahul Bhakat, MD¹, Sudhir Saxena, MD, FICR, PhD², Jitendra Rohilla, MD³, Sriparna Basu, MD, MAMS, FRCPI, FRCPC⁴ , Khanak Kumar Nandolia, MD², Sonam Agrawal, MD¹, Nowneet Kumar Bhat, MD¹, and Swathi Chacham, MD, DM, MNAMS, PhD¹ 

Abstract

Developmental delay (DD) is an important long-term neuromorbidity owing to various insults to the developing brain and neuroimaging plays a key role in evaluating these children. Magnetic resonance spectroscopy (MRS) is the only noninvasive method to determine the levels of various metabolites in the brain which aids in delineating the underlying abnormalities. A total of 48 children aged between 6 months to 6 years with developmental delay were included and evaluated with neuroimaging in our study. Sensitivity of MRS in children with DD and DD plus (DD along with seizures, abnormal motor findings, behavior, brainstem evoked response audiometry, visual assessment, and microcephaly) was 81.2% and 89.6% respectively. 86.6% of children with microcephaly had abnormal MRS. MRS detected abnormalities in two-thirds of children with normal magnetic resonance imaging (MRI). Children with behavioral abnormalities had significantly lower *N*-acetyl aspartate (NAA)–creatinine and NAA–choline ratios on MRS. Thus, MRS is additive to MRI in delineating the underlying pathophysiology in children with DD.

Keywords

choline, developmental delay, magnetic resonance imaging (MRI), magnetic resonance spectroscopy (MRS), myo-inositol, NAA

Received September 18, 2020. Received revised October 31, 2020. Accepted for publication November 10, 2020.

Developmental delay (DD) is an outcome of multiple neurologic adverse events to the developing brain in infants and children, with a reported prevalence of 2% in children below 2 years of age.¹ Globally, around 5% of children younger than 14 years have childhood disability or DD per the World Health Organization (WHO).¹ Significant developmental delay is described as developmental quotient (DQ) more than 2 standard deviations below the mean for age in 1 or more of the following domains: gross/fine motor; speech/language; social/personal; cognition and activities of daily living.² Global developmental delay (GDD) is confirmed when 2 or more domains are affected. Perinatal asphyxia, metabolic abnormalities, cerebral dysgenesis, can potentially lead to DD with low quality of life, which in turn adversely influences social status and family welfare.³ The utility of detecting an underlying etiology in a child with global developmental delay lies in treating a potentially curable cause (eg, metabolic diseases), estimating the ultimate developmental potential of the child and prognosticating the parents.^{4,5} Neuroimaging plays a pivotal role in evaluating a child with DD by delineating distinctive

structural and functional abnormalities.⁶⁻⁹ Early neuroimaging curtails other needless investigations, helps in surveillance of known complications, timely initiation of specific intervention and family support.¹⁰ Neuroimaging gives essential cognitive approach to establish the relationship between brain and behavior in the developmental disorders. Current guidelines recommend magnetic resonance imaging (MRI) as the primary

¹ Department of Pediatrics, All India Institute of Medical Sciences, Rishikesh, Uttarakhand, India

² Department of Radio-Diagnosis & Imaging, All India Institute of Medical Sciences, Rishikesh, Uttarakhand, India

³ Department of Psychiatry, All India Institute of Medical Sciences, Rishikesh, Uttarakhand, India

⁴ Department of Neonatology, All India Institute of Medical Sciences, Rishikesh, Uttarakhand, India

Corresponding Author:

Swathi Chacham, MD, DM, MNAMS, PhD, Department of Pediatrics, All India Institute of Medical Sciences, Rishikesh, Uttarakhand, India.
Email: swathi.m.lahiri@gmail.com

neuroimaging modality that was found to have better diagnostic yield when DD is coupled with specific neurologic signs.^{7,8,10} Recent studies suggest that children with DD and normal MRI can benefit from second-line neuroimaging tools involving complex MRI protocols like proton magnetic resonance spectroscopy (MRS).^{8,10} MRS is the single noninvasive tool to depict a range of metabolites in the brain, thus standing superior to MRI among neuroimaging tools, especially in children with mild DD.¹¹⁻¹⁴ Metabolites that are quantified in MRS comprise amino acids (*N*-acetyl aspartate [NAA], alanine, and glutamate [Glu]), amines (glutamine [Gln], choline [Cho], and creatine [Cr]), sugars (myo-inositol [mIns] and glucose), alongside compounds implicated in high-energy metabolism (Cr and lactate) in brain parenchyma, comparing the distinctive ratios of these metabolites in MRS aids in determining functional impairment of brain parenchyma and assessing the severity, normal frontal lobe functioning, myelination of white matter, in addition to MRI that detects major structural alterations of brain.¹⁵⁻¹⁸ Filippi et al¹⁷ found decreased NAA/Cr and Cho/Cr ratios in children aged more than 2 years of age with DD. Similarly, Hashimoto et al¹⁸ also reported low NAA/Cr ratios in children with DD. Studies have shown decreased levels of NAA in conditions associated with neuronal injuries or neuronal loss.^{19,20} MRS has been found to be efficacious in detecting hypoxic-ischemic encephalopathy, intracranial infection (TORCH infection), mitochondrial encephalopathies, metabolic causes (mucopolysaccharidosis, creatine deficiency syndrome, gangliosidoses, glycosylation disorders), and neoplasms.²¹⁻²⁴ Previous studies reported variations in NAA/Cr and Cho/Cr ratios in abnormal myelination.^{19,25}

There is a paucity of data regarding abnormal metabolites in MRS and its correlation with clinical features that has led to the present study aimed to distinguish MRS abnormalities in children with DD and to correlate with clinical manifestations.

Subjects and Methods

This was a hospital based prospective study, done in Department of Pediatrics of a tertiary care hospital in northern India, from June 2018 to January 2020 over a period of 18 months.

All consecutive children aged between 6 months and 6 years (corrected chronological age till 2 years) with DD were enrolled after obtaining written informed consent from parents or guardians. The estimated sample size of $n = 50$ was calculated based on the 12% prevalence of significant findings on MRS in children with DD as in previous study, with a precision of 10% and allowing up to 20% margin for loss due to missing data or operator error.²⁶ Overall, 60 children were eligible for enrollment in the study after excluding children with acute neurologic illness, Glasgow Coma Scale (GCS) score ≤ 8 , known brain neoplasm, or gross congenital brain malformations. Out of these 60 children, 6 parents refused consent, and 4 children were unfit for general anesthesia; thus, a total of 50 children were enrolled. Clinical data including history and clinical examination findings were recorded in a predesigned pretested proforma along with necessary investigations (brainstem evoked response audiometry [BERA]). Children were evaluated for the cause of DD, which included case-based specific laboratory investigations and

neuroimaging, that is, MRI and MRS. Children with seizure disorder along with DD were evaluated with electroencephalography (EEG). Fifty children underwent MRI and MRS was done in 48 patients and could not be done for 2 patients due to technical issues.

Neuroimaging

All participants were studied by 1.5-tesla (T) (Siemens Magnetom Aera, M. No. 10432914, S. No. 52230) equipment and proton MR spectroscopy using chemical shift imaging sequence under general anaesthesia after taking written informed consent. Multivoxel grids were placed in bilateral sub cortical white matter in frontal and parieto-occipital regions at the level of atrium as well as specific involved region of the brain as delineated by MRI. Concentrations of metabolites, that is, NAA, choline, creatine, myo-inositol, and lipids/lactate were calculated by their peaks in MRS and from these peak amplitude values, ratios were calculated (including NAA/Cho; NAA/Cr; Cho/Cr; mIns/Cr) along with lipid/lactate peak values. MRI findings in children with DD in our study were also delineated. Age-matched reference values were obtained from the metabolite ratios of the control group from the peer-reviewed published literature (supplementary file).^{17,27,28} (This was approved by the Institute's research advisory committee). Depending on this comparison, with age-matched controls from literature, metabolite values were classified as normal or abnormal. Presence of lipid or lactate peak was considered abnormal. If ratio under consideration was abnormal in any of the above-mentioned region (bilateral frontal and parieto-occipital regions and other regions of abnormality on MRI) of the brain; overall values of that particular ratio was taken as abnormal for that patient. We also correlated clinical presentation of the children with MRI findings and metabolite values/ratios on MRS.

Statistical Analysis

Data were coded and recorded in MS Excel spreadsheet program. SPSS, version 23 (IBM Corp, Armonk, NY) was used for data analysis. Descriptive statistics were expressed as means \pm standard deviations and medians and interquartile range (IQR) for continuous variables, and frequencies and percentages for categorical variables. Group comparisons for continuously distributed data were made using independent samples *t* test when comparing 2 groups. If data were non-normally distributed, appropriate nonparametric tests in the form of Wilcoxon test was used for these comparisons.

Chi-square and Fisher exact test were used for group comparisons for categorical data. Logistic regression analysis was done to see whether abnormal clinical findings or brainstem evoked response audiometry can predict the abnormalities on MRS. Statistical significance was kept at *P* value $< .05$.

Results

Baseline descriptive characteristics of the participants are presented in (Table 1). Nearly half of children had seizures and behavioral abnormalities (47.9%, $n = 23$). 10.4% children had previous central nervous system (CNS) infection.

MRS depicted abnormalities in 81.2% children (39/48), with the most frequent abnormal ratios being NAA/Cr, mIns/Cr and lipid/lactate (62.5%; $n = 30$, each) followed by NAA/Cho levels (52.1%, $n = 25$) and Cho/Cr ratios (35.4%, $n = 17$). Out of total 14 children with normal MRI, 64.3% of children

Table 1. Baseline Descriptive Characteristics of the Study Children.^a

Parameter	Mean \pm SD/n (%)
Age, mo	31.19 \pm 20.31
Male	28 (58.3)
Delayed milestones	
Gross motor	41 (85.4)
Fine motor	27 (56.2)
Language	34 (70.8)
Social	15 (31.2)
Preterm and small for gestational age	5 (10.4)
Delayed cry at birth	19 (39.6)
NICU admission	14 (29.2)
Neonatal seizures	10 (20.8)
Microcephaly	15 (31.2)
Overall DQ <50	36 (75.0)
Abnormal motor system examination	31 (64.6)
Abnormal EEG	20 (41.7)
Moderate hearing loss on BERA	9 (18.8)
Abnormal vision	38 (79.2)

Abbreviations: BERA, brainstem evoked response audiometry; EEG, electroencephalography; NICU, neonatal intensive care unit; DQ, developmental quotient; SD, standard deviation.

(n = 9) had abnormal MRS (eg, Figure 1). Children with DD and normal MRI had significantly higher Cho/cr ratio (mean \pm SD values: 1.52 \pm 0.38) as compared to reference values. This points toward impaired myelination or early demyelination which MRI could not detect. Combining history and examination findings with abnormal MRS diagnosed following etiologies in these 9 children with normal MRI. Four children: sequelae of neonatal meningitis; 3 children: sequelae of small for gestational age with perinatal insult with microcephaly; and 2 children: sequelae of neonatal hyperbilirubinemia with abnormal brainstem evoked response audiometry. Being a functional neuroimaging, in children with DD and specific clinical findings, MRS could detect abnormalities at an earlier stage as compared to MRI. Follow-up MRI may be useful in these children for further evolution of long-term sequelae. Thus, abnormal MRS findings in these children aid in early intervention and necessitate frequent follow-up and monitoring.

Cho/Cr ratio were significantly low in children (with abnormal motor examination (mean \pm SD values: 1.12 \pm 0.37) with a *P* value <.014. The Cho/Cr ratio for children with normal motor examination was comparable to that of normal historical controls (mean \pm SD values: 1.38 \pm 0.30) (Supplementary Table).

Hence, MRS can pick up changes in the metabolism of brain parenchyma in the presence of specific clinical manifestations with enhanced sensitivity to assess the abnormal brain function. MRS was abnormal in 81.2% and 89.6% of children with DD and DD plus (DD along with seizures, abnormal motor findings, behavior, brainstem evoked response audiometry, visual assessment, and microcephaly), respectively. MRS showed the highest sensitivity for behavioral abnormalities (91.3%) followed by hearing deficit (89.5%) and visual abnormalities

(84.2%). MRS had highest positive predictive value (PPV) for occurrence of vision abnormalities (82.1%) in children with developmental delay. MRS had highest diagnostic accuracy for vision abnormalities (72.9%).

NAA/Cr ratios were significantly lower in more than half of the children with seizures and abnormal EEG as compared to children without seizures and normal EEG. Lipid values were also significantly higher (*P* < .04) in children with seizures than children without seizures (Table 2). These findings further denote more neuronal damage and anaerobic metabolism in brain parenchyma with seizure activity. Also, one-third of children with seizures and abnormal EEG had abnormal NAA/Cho ratio (*P* < .01).

MRS findings were evaluated with specific underlying etiologies as delineated by MRI and other relevant investigations (Table 3). MRS as a diagnostic tool added valuable information in 75% children with hypoxic-ischemic encephalopathy as the underlying etiology and all the children with non-hypoxic-ischemic encephalopathy causes (Figures 2 and 3, Table 3). MRS was abnormal in 75% (n = 15/20) of children with hypoxic-ischemic encephalopathy changes on MRI. The most frequent abnormal ratio among these children was the NAA/Cr ratio, suggestive of neuronal injury and reduced dendritic proliferation (seen in 65%; n = 13/20). In children with non-hypoxic-ischemic encephalopathy etiology on MRI as with degenerative and metabolic diseases, abnormal lipid and lactate peaks were present in 100% of children, suggestive of glial cell injury. Metabolic/degenerative diseases in our cohort (Table 3) included Van der Knaap disease, adrenoleukodystrophy, Leigh disease, and 2 cases of metachromatic leukodystrophy. MRS is an effective tool to delineate the resultant injury to neurons as well as neuroglial cells with prognostic implication.

Discussion

Among 48 children with DD, MRS demonstrated abnormalities in 81.2%. Moreover, 9 of 14 children (64.3%) with normal MRI brain had specific abnormalities on MRS. MRS showed overall higher sensitivity as compared to MRI in the current study in children with DD plus. As the optic pathway is highly sensitive to environmental insults and denotes more of a functional abnormality rather than structural, MRS had high PPV for visual impairment compared with MRI in our study.

These findings are consistent with the study by Chellathurai et al²⁶ in 424 children, wherein MRS was abnormal in 73 children with normal MRI. Verbruggen et al²⁹ found MRS to be of additional value in 3 of 108 children (2.7%) with abnormal neurologic findings and was diagnostic in 1 child. MRS was of additional value in 9% of cases in children with DD. This conclusion is supported by Filippi et al,¹⁷ Fayed et al,³⁰ and Hashimoto et al,¹⁸ who found statistically significant differences in various metabolite ratios in children with developmental delay compared with controls, suggesting the utility of MRS as an add-on diagnostic modality in children with DD.

NAA/Cr and mIns/Cr ratios and lipid/lactate peaks were abnormal in two-thirds of children in the current study followed

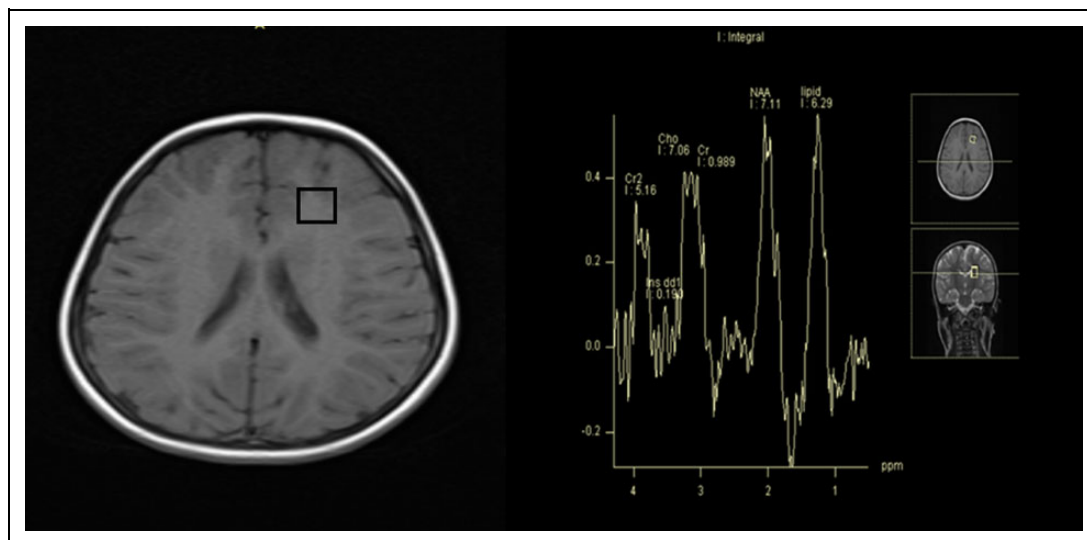


Figure 1. Normal magnetic resonance imaging (MRI) with magnetic resonance spectroscopy (MRS). Axial T1-weighted MR image at the level of bodies of lateral ventricles show normal signal and morphology of parenchyma. MRS voxel (black square) placed in the left frontal lobe shows elevation of choline and lipid peaks.

Table 2. Correlation Between Clinical Features and Abnormal Metabolites Values on MRS (N=48).

Parameters	Seizures: present (n = 24)	Seizures: absent (n = 24)	P value	Motor system examination: normal (n = 17)	Motor system examination: abnormal (n = 31)	P value
NAA/Cr (RF)	1.74 ± 0.39	1.97 ± 0.45	.02 ^a	2.01 ± 0.41	1.77 ± 0.42	.102 ^a
NAA/Cr (LF)	1.67 ± 0.40	2.09 ± 1.16	.01 ^a	2.15 ± 1.32	1.73 ± 0.49	.429 ^a
NAA/Cr (RPO)	1.79 ± 0.84	2.19 ± 0.39	.006 ^a	2.28 ± 0.72	1.84 ± 0.61	.097 ^a
Lipid level (LPO)	0.12 ± 0.29	0.08 ± 0.22	.04 ^a	0.04 ± 0.08	0.13 ± 0.31	.235 ^a
Cho/Cr (RPO)	1.13 ± 0.43	1.30 ± 0.27	.105 ^b	1.38 ± 0.30	1.12 ± 0.37	.014 ^b

Abbreviations: Cho, choline; Cr, creatinine; LF, left frontal; LPO, left parieto-occipital; MRS, magnetic resonance spectroscopy; NAA, N-acetyl aspartate; RF, right frontal; RPO, right parieto-occipital.

^aWilcoxon test.

^bt test.

Table 3. Findings on MRS in Children With Different Underlying Etiology of Developmental Delay on MRI in the Study Children (n = 34).

Disease pattern	Overall abnormal metabolite ratios on MRS, n (%)					
	NAA/Cho	NAA/Cr	Cho/Cr	Ins/Cr	Lipid/lactate peaks	Overall MRS
Overall abnormal MRI (n = 34)	20 (58.8)	23 (67.6)	12 (35.3)	22 (64.7)	22 (64.7)	30 (88.2)
Hypoxic-ischemic encephalopathy (n = 20)	8 (40)	13 (65)	5 (25)	9 (45)	10 (50)	15 (75)
Metabolic and degenerative diseases (n = 5)	3 (60)	4 (80)	1 (20)	3 (60)	5 (100)	5 (100)
Congenital and developmental disorder (n = 4)	4 (100)	2 (50)	1 (25)	4 (100)	4 (100)	5 (100)
Neuroinfection (n = 2)	1 (50)	1 (50)	0 (0)	1 (50)	2 (100)	2 (100)
Traumatic and neurovascular cause (n = 2)	1 (50)	1 (50)	2 (100)	2 (100)	2 (100)	2 (100)
Obstructive hydrocephalus (n = 1)	1 (100)	1 (100)	1 (100)	1 (100)	1 (100)	1 (100)

by NAA/Cho ratios and Cho/Cr ratio. Hashimoto et al¹⁸ also concluded that NAA/Cr ratios were significantly lower in children with DD as compared to normal controls whereas no significant difference was present in Cho/Cr ratios in both the groups. The study conducted by Fayed et al³⁰ also showed no significant difference in Cho/Cr ratios in cases compared with

the control group whereas NAA/Cr, NAA/Ch, and NAA/mIns were significantly lower in cases. Filippi et al¹⁷ also found decreased Cho/Cr ratio in DD compared with the control group.

MRS showed significant abnormalities involving various metabolites in children with different underlying etiology for the DD. Previous studies by Venkataraman et al³¹ in traumatic

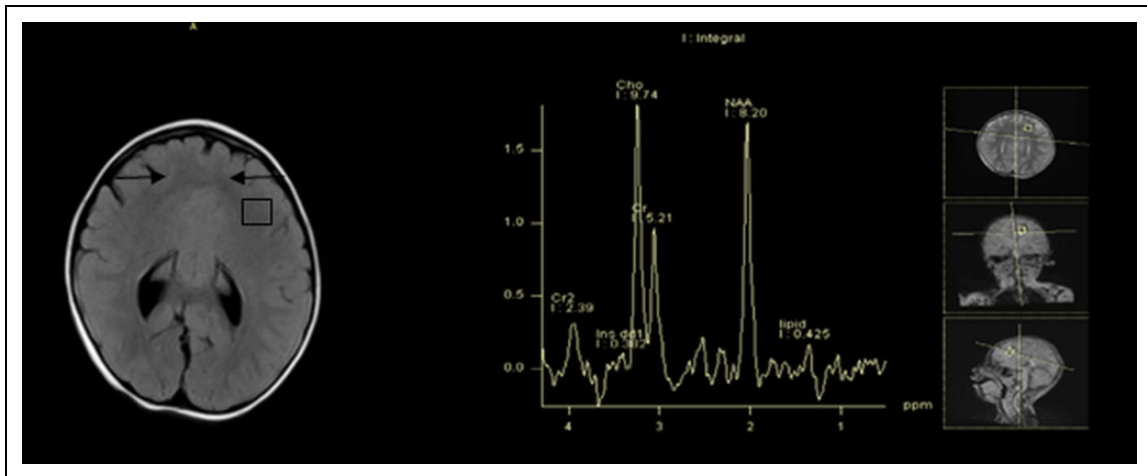


Figure 2. Semilobar holoprosencephaly image. Axial T2-weighted fluid attenuated inversion recovery image at the level of atrium of lateral ventricle shows anteriorly fused frontal lobes (black arrows) and deficient anterior falx. Magnetic resonance spectroscopy voxel (black square) in the frontal lobe white matter shows elevated choline peak and reduced NAA peak. NAA, *N*-acetyl aspartate.

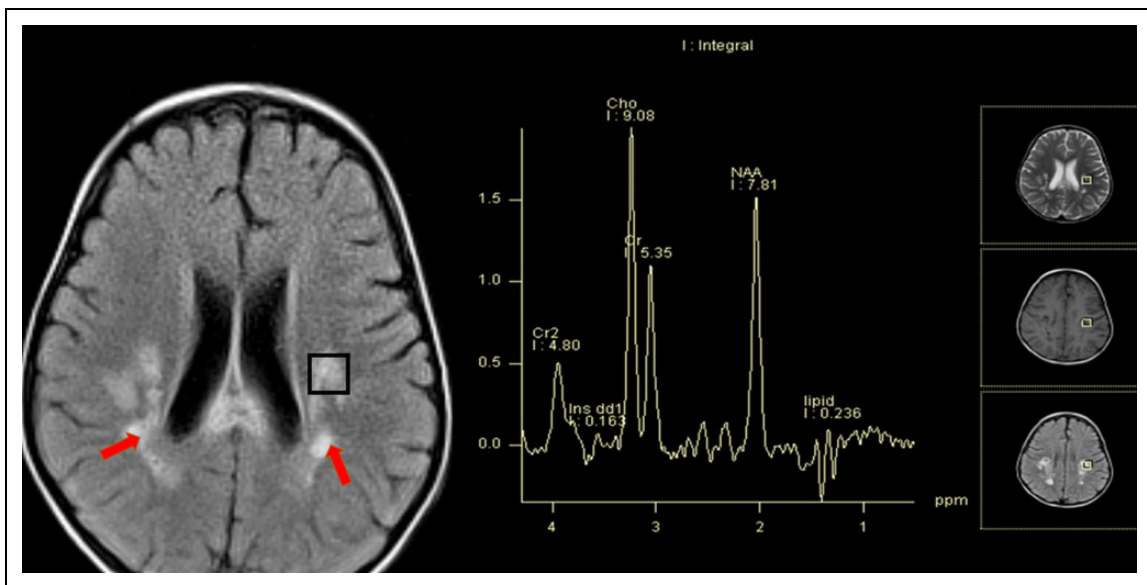


Figure 3. Adrenoleukodystrophy. Axial T2-weighted fluid attenuated inversion recovery image at the level of bodies of lateral ventricles show symmetrical hyperintensities involving deep and subcortical and periventricular parietal white matter (red arrows) and splenium of the corpus callosum. MRS voxel (black square) placed in the abnormal white matter of left parietal lobe shows elevated choline peak and reduced *N*-acetyl aspartate (NAA).

or neurovascular disease also demonstrated abnormal MRS findings in the form of elevated lactate peak along with decreased NAA, creatinine, and choline peaks in the region of infarct as delineated by MRI findings. Similarly, in a child with adrenoleukodystrophy, MRS revealed abnormal NAA/Cho, NAA/Cr, and mIns/Cr ratios along with a lipid peak. These findings were consistent with the previous studies as done by Cecil et al³² Similarly, 2 children with metachromatic leukodystrophy showed diminished NAA/Cho and NAA/Cr ratio with lactate peaks in both the cases. This was also in concordance with the findings of Abdelsalam et al,³³ which

demonstrated decreased NAA/Cr with NAA/Cho peaks in these children. It shows the reliability of spectral patterns seen on the MRS in various underlying diseases leading to the developmental delay.

In the study by Verbruggen et al,²⁹ among the total 108 children, MRI and/or MRS were diagnostic in 9% cases, all of whom had abnormal neurologic findings on clinical examination. In our study also, MRS was abnormal in the majority (91.3%) of the children with abnormal behavior followed by three-fourths of the children with seizures (75%). DQ values were lower in the children having abnormal MRS findings

(mean \pm SD: 40.90 \pm 13.85 in abnormal MRS vs 42.45 \pm 7.83 in normal MRS). Of the total of 15 children with microcephaly, 86.6% children had abnormal MRS findings. Moreover, children with abnormal behavioral, vision, and hearing problems along with seizures and microcephaly had higher odds of having abnormal MRS findings on logistic regression analysis. So MRS is of additional diagnostic value in children with DD as 9 children in our study with normal MRI had abnormal MRS with prognostic value. The sensitivity of MRS in children with DD and DD plus ranged from 81.2% to 89.6%. Specific MRS findings such as elevated choline peaks plus decreased NAA/Cho ratio in a child with adrenoleukodystrophy and lactate peaks in a child with Leigh disease. Similarly, 2 children with metachromatic leukodystrophy showed characteristic diminished NAA/Cho and NAA/Cr ratios with lactate peaks. Moreover, the rate of abnormalities detected on ophthalmologic evaluation were higher in children with abnormal MRS findings (82.1% vs 66.7%). Abnormal MRS findings were significantly associated with higher hearing loss. So clinical clues should also be considered for proper patient selection, if MRS is not feasible in every child with DD, as in resource-poor settings with long waiting time and high cost of investigations.

So, all these findings suggest that while evaluating any child of DD with neuroimaging (MRI and MRS), it is very crucial to take the clinical history and examination findings into consideration as well as the underlying pathophysiology behind that specific clinical finding as it would help to detect particular abnormalities in the specific regions on MRI and MRS and it would help to further increase the yield of neuroimaging by detection of subtle changes. As no previous data are available regarding correlation of specific abnormal clinical findings with specific neuroimaging findings as per our current knowledge, more studies are needed in this context to establish the findings of our study as it would have a great impact on the evaluation of children with DD with neuroimaging and in the prognostication of these children.

Conclusions

Our study emphasizes the additional diagnostic utility of MRS over MRI in children with DD and hence recommends possible inclusion of MRS as a diagnostic modality in children with developmental delay alongside MRI. Overall, 64.3% of children with normal brain MRI had some abnormalities on MRS. The most common abnormal metabolites were NAA/Cr, mIns/Cr, and lipid/lactate. In addition, 10.4% children had an MRS pattern suggestive of metabolic/degenerative disorders. Clinical findings coupled with neuroimaging would further increase the yield of MRS.

Acknowledgment

We thank all the children and their parents and guardians for their consent to participate in the study.

Author Contributions

NR, RB, KKN, SA: acquired the data, review of literature, statistical analysis, drafting the manuscript. SS, JR, SB, NKB, SC: conceived the study, statistical analysis, critically reviewed the manuscript, edited the final version of the manuscript. All the authors approved the final version of the manuscript.




Declaration of Conflicting Interests

The authors declared no potential conflicts of interest with respect to the research, authorship, and/or publication of this article.

Funding

The authors received no financial support for the research, authorship, and/or publication of this article.

ORCID iDs

Nikhil Rajvanshi, MBBS  <https://orcid.org/0000-0002-0787-8815>
Sriparna Basu, MD, MAMS, FRCPI, FRCPC  <https://orcid.org/0000-0001-5048-4849>
Swathi Chacham, MD, DM, MNAMS, PhD  <https://orcid.org/0000-0002-3400-9914>

Supplemental Material

Supplemental material for this article is available online.

Ethical Approval

This study was approved by the institutional ethics committee (IEC/18/555) of AIIMS Rishikesh.

References

1. Institute for Child Development. Developmental delay / delayed milestones. New Delhi: Institute for Child Development. https://www.icddelhi.org/developmental_delayed_milestone.html. Published 2001. Accessed 11 November 2020.
2. Shevell M, Ashwal S, Donley D, et al. Practice parameter: evaluation of the child with global developmental delay: report of the quality standards subcommittee of the American Academy of Neurology and The Practice Committee of the Child Neurology Society. *Neurology*. 2003;60(3):367-380.
3. Hsieh RL, Hsueh YM, Huang HY, Lin MI, Tseng WC, Lee WC. Quality of life and impact of children with unclassified developmental delays. *J Paediatr Child Health*. 2013;49(2):116-121.
4. Lemay JF, Herbert AR, Dewey DM, Innes AM. A rational approach to the child with mental retardation for the paediatrician. *Paediatr Child Health*. 2003;8(6):345-356.
5. Kjos BO, Umansky R, Barkovich AJ. Brain MR imaging in children with developmental retardation of unknown cause: results in 76 cases. *AJNR Am J Neuroradiol*. 1990;11(5):1035-1040.
6. Griffiths PD, Batty R, Warren D, et al. The use of MR imaging and spectroscopy of the brain in children investigated for developmental delay: what is the most appropriate imaging strategy? *Eur Radiol*. 2011;21:1820-1830.
7. Verbruggen KT, Maurits NM, Meiners LC, et al. Quantitative multivoxel proton spectroscopy of the brain in developmental delay. *J Magn Reson Imaging*. 2009;30:716-721.

8. Bouhadiba Z, Dacher J, Monroc M, Vanhulle C, Ménard JF, Kalifa G. MRI of the brain in the evaluation of children with developmental delay. *J Radiol*. 2000;81(8):870-873.
9. Aicardi J. The etiology of developmental delay. *Semin Pediatr Neurol*. 1998;5(1):15-20.
10. Mithyantha R, Kneen R, McCann E, Gladstone M. Current evidence-based recommendations on investigating children with global developmental delay. *Arch Dis Child*. 2017;102(11):1071-1076.
11. Pacheva I, Ivanov I, Penkov M, Kancheva D, Jordanova A, Ivanova M. Creatine deficiency syndrome could be missed easily: a case report of guanidinoacetate methyltransferase deficiency presented with neurodevelopmental delay, seizures, and behavioral changes, but normal structural MRI. *Ann Clin Lab Sci*. 2016;46(5):557-561.
12. Poon JK, Larosa AC, Shashidhar Pai G. Developmental delay: timely identification and assessment. *Indian Pediatr*. 2010;47(5):415-422.
13. Shevell MI. The evaluation of the child with a global developmental delay. *Semin Pediatr Neurol*. 1998;5(1):21-26.
14. Schaefer GB, Bodensteiner JB. Radiological findings in developmental delay. *Semin Pediatr Neurol*. 1998;5(1):33-38.
15. Friedman SD, Brooks WM, Jung RE, et al. Quantitative proton MRS predicts outcome after traumatic brain injury. *Neurology*. 1999;52(7):1384-1391.
16. Ozturk A, Degaonkar M, Matson MA, Wells CT, Mahone EM, Horská A. Proton MR spectroscopy correlates of frontal lobe function in healthy children. *Am J Neuroradiol*. 2009;30(7):1308-1314.
17. Filippi CG, Uluğ AM, Deck MDF, Zimmerman RD, Heier LA. Developmental delay in children: assessment with proton MR spectroscopy. *Am J Neuroradiol*. 2002;23(5):882-888.
18. Hashimoto T, Tayaina M, Miyazaki M, et al. Developmental brain changes investigated with proton magnetic resonance spectroscopy. *Dev Med Child Neurol*. 2008;37(5):398-405.
19. Yeo RA, Hill D, Campbell R, Vigil J, Brooks WM. Developmental instability and working memory ability in children: a magnetic resonance spectroscopy investigation. *Dev Neuropsychol*. 2000;17(2):143-159.
20. Ford CC, Griffey RH, Matwiyoff NA, Rosenberg GA. Multivoxel 1H-MRS of stroke. *Neurology*. 1992;42(7):1408-1412.
21. Jayasundar R, Singh VP, Raghunathan P, Jain K, Banerji AK. Inflammatory granulomas: evaluation with proton MRS. *NMR Biomed*. 1999;12(3):139-144.
22. Rodriguez DP, Poussaint TY. Neuroimaging of the child with developmental delay. *Top Magn Reson Imaging*. 2007;18(1):75-92.
23. Freeze HH, Eklund EA, Ng BG, Patterson MC. Neurological aspects of human glycosylation disorders. *Annu Rev Neurosci*. 2015;38:105-125.
24. Horská A, Barker PB. Imaging of brain tumors: MR spectroscopy and metabolic imaging. *Neuroimaging Clin N Am*. 2010;20(3):293-310.
25. Moore GJ. Proton magnetic resonance spectroscopy in pediatric neuroradiology. *Pediatr Radiol*. 1998;28(11):805-814.
26. Chellathurai A, Ramaswami S, Xavier SA, Thangalakshmi A, Kannappan S. Magnetic resonance spectroscopy in children with non-acute neurological illness. *J Evolution Med Dent Sci*. 2018;7(20):2481-2486.
27. Martin E, Keller M, Ritter S, Largo RH, Thiel T, Loenneker T. Contribution of proton magnetic resonance spectroscopy to the evaluation of children with unexplained developmental delay. *Pediatr Res*. 2005;58(4):754-760.
28. Torres-Ayala SC, Rivera-Morell M, Ayala-Muñiz JA, Garcia-Irizarry LE, Vidal J, Mayaguez. MR proton spectroscopy: a user-friendly approach to interpreting brain MR Proton Spectroscopy. Poster presented at: European Congress of Radiology, Annual Congress of the European Society of Radiology; 2015 March 4-8; Vienna, Austria.
29. Verbruggen KT, Meiners LC, Sijens PE, Lunsing RJ, van Spronsen FJ, Brouwer OF. Magnetic resonance imaging and proton magnetic resonance spectroscopy of the brain in the diagnostic evaluation of developmental delay. *Eur J Paediatr Neurol*. 2009;13(2):181-190.
30. Fayed N, Morales H, Modrego PJ, Muñoz-Mingarro J. White matter proton MR spectroscopy in children with isolated developmental delay: does it mean delayed myelination? *Acad Radiol*. 2006;13(2):229-235.
31. Venkataraman A, Kingsley PB, Kalina P, et al. Newborn brain infarction: clinical aspects and magnetic resonance imaging. *CNS Spectr*. 2004;9(6):436-444.
32. Cecil KM. MR spectroscopy of metabolic disorders. *Neuroimaging Clin N Am*. 2006;16(1):87-116.
33. Abdelsalam EM, Ashamallah GA, Lateef MA, Fathy K. Proton MR spectroscopy in leukodystrophies. *Egypt J Radiol Nucl Med*. 2015;46(4):1091-1097.