





European Course on Pediatric Neuroradiology in Latin America (ECPNA-LATAM)  
3<sup>rd</sup> Cycle - Module 1

# Accidental Pediatric Head Trauma



Idealização:   Organização: 

1




European Course on Pediatric Neuroradiology in Latin America (ECPNA-LATAM)  
3<sup>rd</sup> Cycle - Module 1





**Bernardo Corrêa de Almeida Teixeira**  
MD PhD

Neuroradiologist at Curitiba, Paraná, Brazil, working at:

Pequeno Príncipe Childrens Hospital  
Neurological Institute of Curitiba  
Quanta Diagnostic Imaging

Adjunt Professor of Radiology at  
Federal University of Paraná

Idealização:   Organização: 

2

## Accidental Pediatric Head Trauma

European Course on Pediatric Neuroradiology in Latin America (ECPNA-LATAM)  
3<sup>rd</sup> Cycle - Module 1

There is no conflict of interest in this presentation

3

## Topic for Today

European Course on Pediatric Neuroradiology in Latin America (ECPNA-LATAM)  
3<sup>rd</sup> Cycle - Module 1

- Introduction to Pediatric Head Trauma
- When should Imaging be performed
- Common and uncommon imaging findings
- Complications and diferencial diagnosis
- Abusive Head Trauma

4

## Pediatric Head Trauma - Epidemiology

European Course on Pediatric Neuroradiology in Latin America (ECPNA-LATAM)  
3<sup>rd</sup> Cycle - Module 1

- Traumatic brain injury (TBI) is the leading cause of morbidity and mortality in children → 50% of children with TBI undergoing neuroimaging
- Most cases are uncomplicated and do not require intervention, with 40-60% classified as mild TBI and less than 10% showing lesions on imaging.
- The need for imaging in moderate to severe TBI (GCS ≤ 13) is well established, as the risk of traumatic injury exceeds 20%, which is higher than the risk of radiation exposure.
- Criteria for mild TBI (GCS 14/15) are inconsistent in the literature, with 3-5% showing imaging changes and less than 1% requiring intervention.

Taylor CA, Bell JM, Breiding MJ, Xu L. Traumatic Brain Injury-Related Emergency Department Visits, Hospitalizations, and Deaths - United States, 2007 and 2013. MMWR Surveill Summ 2017;66:1-6.

5

## PECARN Study

European Course on Pediatric Neuroradiology in Latin America (ECPNA-LATAM)  
3<sup>rd</sup> Cycle - Module 1

- Largest study to date on mild TBI → Pediatric Emergency Care Applied Research Network (PECARN) (Lancet, 2009) → 40,000 children (Very low risk → NPV 99-100%);
- Risk of lethal malignancy post-radiation → 1-year-old = 1/1500 – 10-year-old = 1/5000;
- Very low risk (>2 years) + GCS 15 + absence of altered or lost consciousness, clinical signs of base skull fracture, vomiting, headache, or significant trauma mechanism;
- Very low risk (<2 years) + GCS 15 + absence of altered or lost consciousness (>5 seconds), palpable fractures, non-frontal scalp hematomas, acting abnormally according to parents;

**NOTE:** 50% of intracranial injuries do not present associated fractures → X-rays are insufficient and not indicated

KUPFERMANN, Nathan et al. Identification of children at very low risk of clinically important brain injuries after head trauma: a prospective cohort study. **The Lancet**. v. 374, n. 9696, p.1160-1170, 2009.

6

### Minor Head Trauma Criteria

European Course on Pediatric Neuroradiology in Latin America (ECPNR-LA/ITAM) 3<sup>rd</sup> Cycle - Module 1

**Appendix 1: Pediatric Emergency Care Network (PECARN) Clinical Criteria for Minor Head Trauma**

	Child 2 years of age or older	Child less than 2 years of age
<b>Very Low Risk</b>	GCS = 15 with none of the following: Signs of basilar skull fracture, any loss of consciousness, vomiting, severe injury mechanism, severe headache, or other signs of altered mental status.*	GCS = 15 with none of the following: Palpable skull fracture, nonfrontal scalp hematoma, loss of consciousness of 5 seconds or more, severe mechanism of injury, not acting normally per parents, or other signs of altered mental status.*
<b>Intermediate Risk</b>	GCS = 15 with any of the following: History of any loss of consciousness, vomiting, severe mechanism of injury, or severe headache; No altered mental status or signs of basilar skull fracture.	GCS = 15 with any of the following: Nonfrontal scalp hematoma, loss of consciousness of 5 seconds or more, severe mechanism of injury, not acting normally per parents. No other signs of altered mental status or palpable skull fracture.
<b>High Risk</b>	GCS = 14 or with other signs of altered mental status*, or signs of basilar skull fracture.	GCS = 14 or with other signs of altered mental status*, or signs of basilar skull fracture.

GCS = Glasgow Coma Scale  
\*Other signs of mental status include agitation, somnolence, repetitive questioning, or slow response to verbal communication.

KUPPERMANN, Nathan et al. Identification of children at very low risk of clinically-important brain injuries after head trauma: a prospective cohort study. *The Lancet*. v. 374, n. 9696, p. 1160-1170, 2009.

7

### Minor Head Trauma Criteria

European Course on Pediatric Neuroradiology in Latin America (ECPNR-LA/ITAM) 3<sup>rd</sup> Cycle - Module 1

**< 2 yo**

**> 2 yo**

KUPPERMANN, Nathan et al. Identification of children at very low risk of clinically-important brain injuries after head trauma: a prospective cohort study. *The Lancet*. v. 374, n. 9696, p. 1160-1170, 2009.

8

### ACR Appropriateness Criteria (2019)

European Course on Pediatric Neuroradiology in Latin America (ECPNR-LA/ITAM) 3<sup>rd</sup> Cycle - Module 1

American College of Radiology  
ACR Appropriateness Criteria<sup>®</sup>  
Head Trauma-Child

Scenario 1 + Mild acute closed TBI (very low risk PECARN)  
**NO IMAGING STUDIES**

Scenario 2 + Mild acute closed TBI (intermediate risk PECARN)  
**CT SCAN +/-**

Scenario 3 + Mild acute closed TBI (high risk PECARN)  
**CT SCAN**

Scenario 4 + Moderate/severe closed TBI (GCS ≤ 13) acute  
**CT SCAN**

Scenario 5 + Subacute closed TBI with neurological signs  
**CT SCAN OR MRI**

Scenario 6 + Chronic closed TBI with new neurological signs  
**CT SCAN OR MRI**

<https://www.acr.org/Clinical-Resources/ACR-Appropriateness-Criteria>

9

### PECARN Online Algorithm

European Course on Pediatric Neuroradiology in Latin America (ECPNR-LA/ITAM) 3<sup>rd</sup> Cycle - Module 1

**MDCALC.COM**  
<https://www.mdcalc.com/pecarn-pediatric-head-injury-trauma-algorithm#use-cases>

10

### Normal Imaging Findings CT

European Course on Pediatric Neuroradiology in Latin America (ECPNR-LA/ITAM) 3<sup>rd</sup> Cycle - Module 1

M, two, minor head trauma

PURUSHOTHAMAN, Bangarajan et al. Utility of three-dimensional and reformatted head computed tomography images in the evaluation of pediatric abusive head trauma. *Pediatric radiology*. p. 1-12, 2021.

11

### Linear Fracture

European Course on Pediatric Neuroradiology in Latin America (ECPNR-LA/ITAM) 3<sup>rd</sup> Cycle - Module 1

M, 3yo, fall from the park bench

M, 2mo, fall from parents arms

**SKULL FRACTURES**

- Common + 2% overall (11% < 2 years of age) - 60% parietal bone
- Sensitivity + X-rays (60%) and 3D CT (88% < 2 years)
- Types + Linear (75%), Flattening (Depression), Diastatic, and Base of the skull

12

**Linear Fracture + Epidural Hematoma**

European Course on Pediatric Neuroradiology in Latin America (ECPNR-LATAM) 3<sup>rd</sup> Cycle - Module 1

M, 5mo, grandpa fall from the chair with him, no neurological signs

M, 9do, roll from parents bed

40-100% of traumatic brain injuries have fractures

13

**TYPES OF FRACTURE**

Disjunction/Diastasis + Subdural/Subgaleal Hematomas

European Course on Pediatric Neuroradiology in Latin America (ECPNR-LATAM) 3<sup>rd</sup> Cycle - Module 1

M, 14yo, skateboard fall without helmet

**DIASTASIS FRACTURE**

- Subgaleal hematomas (95%)
- Epidural hematomas (75%)
- Linear fractures (50%)

14

**TYPES OF FRACTURE**

Depressed "Ping Pong"/"Greenstick"

European Course on Pediatric Neuroradiology in Latin America (ECPNR-LATAM) 3<sup>rd</sup> Cycle - Module 1

M, 3do, fall from bed height

Sprenger et al. Radiografias de crânio e sua relevância em um hospital universitário: um ensaio iconográfico. JPR 2019

15

**Birth Trauma – Caput Succedaneum**

European Course on Pediatric Neuroradiology in Latin America (ECPNR-LATAM) 3<sup>rd</sup> Cycle - Module 1

M, 2do, vaginal birth with forceps

**BIRTH TRAUMA**

- 1-2% of mortality in newborns
- 26-63% with asymptomatic minor subdural hemorrhages (<3mm, resolves in one month)

Sprenger et al. Radiografias de crânio e sua relevância em um hospital universitário: um ensaio iconográfico. JPR 2019

16

**Birth Trauma – Cephalohematoma**

European Course on Pediatric Neuroradiology in Latin America (ECPNR-LATAM) 3<sup>rd</sup> Cycle - Module 1

F, 3mo, calcified cephalohematoma

F, 2mo, calcified cephalohematoma

M, 2do, bilateral fracture+hematoma

M, 6mo, calcified cephalohematoma

**CEPHALOHEMATOMA**

- Subperiosteal hemorrhages (do not cross sutures) DDX (subgaleal)
- 1-2% of deliveries First pregnancy and use of forceps
- Calcify at 2-3 weeks

Sprenger et al. Radiografias de crânio e sua relevância em um hospital universitário: um ensaio iconográfico. JPR 2019

17

**INTRACRANIAL LESIONS**

(Fracture+Hematoma+Contusion)

European Course on Pediatric Neuroradiology in Latin America (ECPNR-LATAM) 3<sup>rd</sup> Cycle - Module 1

M, 12yo, fall from the horse with loss of consciousness

M, 9 years old, car rollover without belt with loss of consciousness

**SEVERE TRAUMA**

- Coup/Contrecoup Lesions
- Diffuse Axonal Injury

18

**INTRACRANIAL LESIONS**  
(Subdural Hematoma + Arachnoid Cyst)

European Course on Pediatric Neuroorology in Latin America (ECPNR-LATAM) 3<sup>rd</sup> Cycle - Module 1

M, 10yo, minor head trauma with loss of consciousness

MRI previous to the trauma

- Higher chances of intracranial hemorrhage
- Higher chances of bigger hematomas
- Higher chances of midline shift

19

**Leptomeningeal Cyst "Growing Fracture"**

European Course on Pediatric Neuroorology in Latin America (ECPNR-LATAM) 3<sup>rd</sup> Cycle - Module 1

M, 4mo, car accident was in mother's lap

M, 11mo

Follow-up with 14mo

- Fracture augmentation secondary to adjacent encephalomalacia area
- <3 years, just 1% of fractures

20

**Occipitotemporal Fractures - Sinus Lesion**

European Course on Pediatric Neuroorology in Latin America (ECPNR-LATAM) 3<sup>rd</sup> Cycle - Module 1

M, 7yo, fall from skateboard

M, 13yo, sweep kick in Scholl, subdural hematoma

21

**Occipitotemporal Fractures**

European Course on Pediatric Neuroorology in Latin America (ECPNR-LATAM) 3<sup>rd</sup> Cycle - Module 1

M, 12yo, fall from skateboard in high speed

M, 10yo, fall from the park slide with unilateral otorrhea and hearing loss

- Transverse Mastoid Fracture
- Incudostapedial Dislocation

22

**The Value of Magnetic Resonance**

European Course on Pediatric Neuroorology in Latin America (ECPNR-LATAM) 3<sup>rd</sup> Cycle - Module 1

M, 3yo, fall of ten steps

M, 12yo, subacute confusional state, encephalitis/meningitis?

MRI → Subacute Trauma and Clinical Symptoms not fully explained by CT findings

Hidden trauma → Subacute Brain Contusions

23

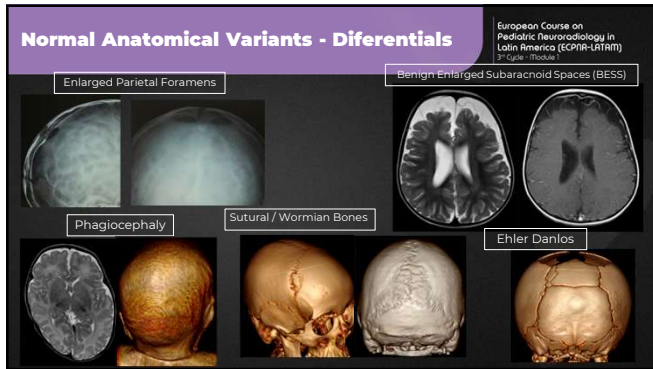
**The Value of Magnetic Resonance**

European Course on Pediatric Neuroorology in Latin America (ECPNR-LATAM) 3<sup>rd</sup> Cycle - Module 1

M, 2mo, fall from mother's arms with parietal trauma

MRI → Better detection of Subdural Hematomas, Subarachnoid Hemorrhage and Parenchymal Lesion

24



25

**Take Home Points**

European Course on Pediatric Neuroradiology in Latin America (ECPNR-LATAM)  
3<sup>rd</sup> Cycle - Module 1

- Stratify brain injury risk (low, moderate, high) and (><2 years) PECARN calculator;
- Do not request cranial X-rays;
- Low risk without imaging; high risk with imaging; moderate risk individualize;
- Attention to later traumas and their complications;
- Always consider (but not overdo it) the suspicion of mistreatment.

26

European Course on Pediatric Neuroradiology in Latin America (ECPNR-LATAM)  
3<sup>rd</sup> Cycle - Module 1

**Contact**  
[bernardo.teixeira@ufpr.br](mailto:bernardo.teixeira@ufpr.br)

**Thank you for your attention!**

Idealização:    Organização: 

27